

Clinico-Pathological Profile of Patients with Bullous PemphigoidAthira Sudhesan¹, Anjana Suresh², Athira Mohan³, Keerthy Joy Irimpan⁴,
Amitha N. P⁵¹Assistant Professor, Department of Dermatology, GTDMCA, Vandanam, Kerala, India²Senior resident, Department of Dermatology, GTDMCA, Vandanam, Kerala, India³Senior resident, Department of Dermatology, GTDMCA, Vandanam, Kerala, India⁴Senior resident, Department of Dermatology, GTDMCA, Vandanam, Kerala, India⁵Senior resident, Department of Dermatology, GTDMCA, Vandanam, Kerala, India

Received: 15-04-2022 / Revised: 20-05-2022 / Accepted: 05-06-2022

Corresponding author: Dr Athira Sudhesan

Conflict of interest: Nil

Abstract

Bullous pemphigoid (BP) is the most common subepidermal immunobullous disorder, classically manifests with tense blisters on skin accompanied by intense pruritus. Many co-morbidities have reported to be associated with Bullous pemphigoid. A wide variety of atypical presentations can occur in this condition. Aim of the study was to find out the clinico-pathological profile of patients with Bullous pemphigoid.

Materials and Methods: This record based descriptive study was done on 62 patients admitted with Bullous pemphigoid in the department of Dermatology and Venereology of a tertiary care hospital during 5 years. The diagnosis of BP was made by clinical, histopathological and immunofluorescence study. Data was collected by reviewing the hospital's medical records. Clinical profile and investigation results were collected from case notes.

Results: The study highlights the atypical presentations of Bullous pemphigoid, and associated co-morbidities.

Conclusion: There are a variety of atypical presentations of Bullous pemphigoid, and much co-morbidity is associated with it. Bullous pemphigoid may be a differential diagnosis of itchy or bullous skin conditions in the elderly with eosinophilia. Awareness about the atypical presentations and co-morbidities will be helpful to avoid delay in diagnosis and to reduce the healthcare costs.

Keywords: Bullous pemphigoid, co-morbidities, Neurological diseases, Eosinophilia.

This is an Open Access article that uses a fund-ing model which does not charge readers or their institutions for access and distributed under the terms of the Creative Commons Attribution License (<http://creativecommons.org/licenses/by/4.0>) and the Budapest Open Access Initiative (<http://www.budapestopenaccessinitiative.org/read>), which permit unrestricted use, distribution, and reproduction in any medium, provided original work is properly credited.

Background

Bullous pemphigoid (BP) is a subepidermal blistering skin disease which typically affects the elderly population between the ages of 60 to 80 years. It classically manifests with tense blisters over normal skin or erythematous background on trunk and extremities, accompanied by intense pruritus. Mucosal involvement is reported in 10 – 30 % of

the cases. Many co-morbidities have reported to be associated with Bullous pemphigoid, including multiple sclerosis, dementia, Parkinson's disease, epilepsy and stroke [1]. Bullous pemphigoid is caused by autoantibodies against various adhesion proteins in the hemidesmosome and basement membrane zone. Auto-reactive IgG1 and IgG4 antibodies target

BP antigen 1 (BP230) and BP antigen 2 (BP180, also known as collagen XVII) [2].

The diagnosis of Bullous pemphigoid is based on the combination of the clinical presentation, histopathological evaluation demonstrating sub-epidermal detachment with eosinophils and other inflammatory cells and immunofluorescence microscopy. Demonstration of linear deposits of complement 3 (C3) and /or immunoglobulin G (IgG) at the dermal-epidermal junction of patients' perilesional skin by direct immunofluorescence (DIF), and circulating IgG autoantibodies binding to the epidermal side of 1 M NaCl-split skin by indirect immunofluorescence (IIF) microscopy confirms the diagnosis of Bullous pemphigoid. Measurement of circulating autoantibodies against BP180 and BP230 antigens by enzyme-linked immunoassay (ELISA) is also helpful for diagnosis [3].

Treatment of Bullous pemphigoid is challenging due to old age and comorbidities of affected patients. Treatment aims to arrest the development of new lesions and enable cutaneous healing and control of pruritus. High potency topical steroids and systemic steroids are the current mainstay of therapy. Adjuvant treatment with Tetracycline, Nicotinamide, Dapsone and immunosuppressants like Azathioprine, Mycophenolate mofetil are also used.^[1] Rituximab, a chimeric IgG monoclonal antibody against CD20 surface antigen on B-lymphocytes found to be useful in some patients. Omalizumab, a humanized monoclonal anti-IgE antibody has been found to have role in severe or recalcitrant bullous pemphigoid with increased serum levels of IgE and / or eosinophilia.

The incidence of BP has increased over the past decades due to multiple factors [4].

A wide variety of atypical presentations can occur in BP, that sometimes make it a diagnostic challenge. More cases are being reported in young individuals. There can

be regional variations in clinical behavior and course of the disease. In the present study, we have attempted to study the clinical profile of patients with bullous pemphigoid, including comorbidities, histopathology and Direct Immunofluorescence (DIF) findings of these cases. An awareness regarding the atypical presentations and co-morbidities will be helpful to avoid delay in diagnosis and to reduce the healthcare costs. The epidemiology of BP is well described in the Caucasian population with limited data available in the Asian population. There are only a few Indian studies conducted to assess the same.

Materials and Methods

This record based descriptive study was done on 62 patients admitted with Bullous pemphigoid in the department of Dermatology and Venereology of a tertiary care hospital in Kerala, South India during 5 years, from January 2015 to December 2019. All patients admitted with Bullous pemphigoid during the study period were included in the study. Aim was to study the clinical, histopathological and direct immunofluorescence findings in these patients. Institutional research committee and Ethics committee approval were taken. Data collection and analysis was done from January 2020 to July 2021. Patients admitted with the diagnosis of BP during the study period were identified by reviewing the hospital's medical records. Age, gender, clinical features, comorbidities and investigation results were collected from case notes.

The diagnosis of BP was made if the patient fulfils the following 3 criteria^[5].

1. Clinical findings consistent with BP – that is, tense blisters arising from erythematous or urticated skin.
2. Histopathological findings of a subepidermal detachment with eosinophils, neutrophils and fibrin in the blister cavity, and dermal inflammatory infiltrate.

3. Direct immunofluorescence (DIF) findings consistent with Bullous pemphigoid.

Direct immunofluorescence (DIF) is performed in a sample obtained from perilesional skin. Linear deposits of IgG and/or C3 along the basement membrane zone (BMZ) is consistent with the diagnosis of BP [1].

Data regarding treatment modalities, treatment response, and mortality during hospital stay were also collected. Collected data was analyzed in terms of frequency, proportions and percentage by appropriate statistical test using SPSS software (unpaired T-test).

Results

The female to male ratio was 1.2:1. The patients' age ranged from 19 to 90 years (Mean age 63.3 years). The cutaneous manifestations were highly polymorphic. [Table -1]. 59 out of 62 patients had blistering and erosions. In addition to this, urticated plaques [Figure - 1] eczematous lesions, periorbital erythema and edema, string of pearl arrangement of blisters [Figure - 2] were seen. Oral mucosal lesions were seen in 24% of patients. Vesicular type of BP and dyshidrosiform type of BP [Figure - 3] were seen in 2 patients each.

Table 1: Various manifestations of bullous pemphigoid

Skin lesions	No. of patients (Total – 62)
Blistering & erosions	59
Urticated plaques	15
Oral mucosal involvement	15
Eczematous lesions	9
String of pearl arrangement	9
Periorbital erythema & edema	1
Vesicular type of BP	2
Dyshidrosiform type	2

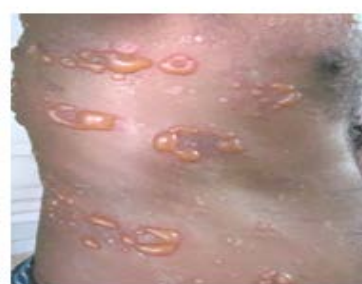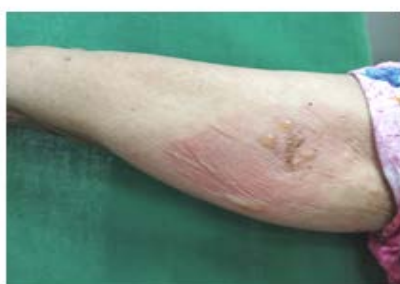


Figure 1: Urticated plaque with blister, Figure 2: String of pearl arrangement

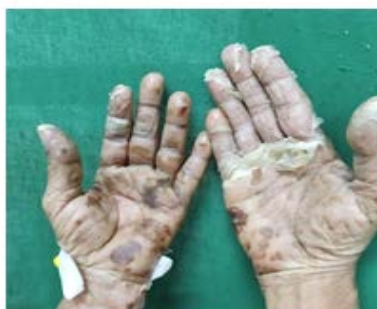

Figure 3: Dyshidrosiform type of BP

Most of our patients had lesions on the trunk and/or the limbs. Other than the classical sites, involvement of some atypical sites like face, scalp palms and soles, interdigital space were observed. [Table - 2], [Figure - 4]

Table 2: Atypical sites of involvement in Bullous Pemphigoid

Atypical sites	No. of patients (Total – 62)
Face	21
Scalp	15
Inter-digital space	13
Palms	8

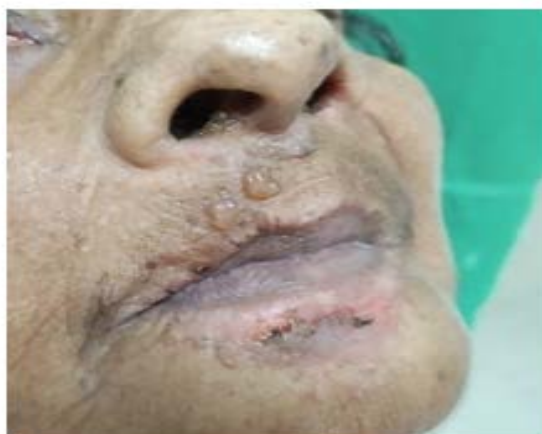

Figure 4: Facial involvements in BP

32% of patients gave history of chronic drug intake. 23% of them were on multiple drugs (antihypertensives, oral hypoglycemic agents and statins). 6% of patients were on Amlodipine alone and 3.6% of patients were on Glimipiride.

Associated diseases

Various co-morbidities observed in our study is summerised in Figure - 5. The neurological diseases that we observed were stroke, dementia and parkinsonism. There were no cases associated with malignancy.

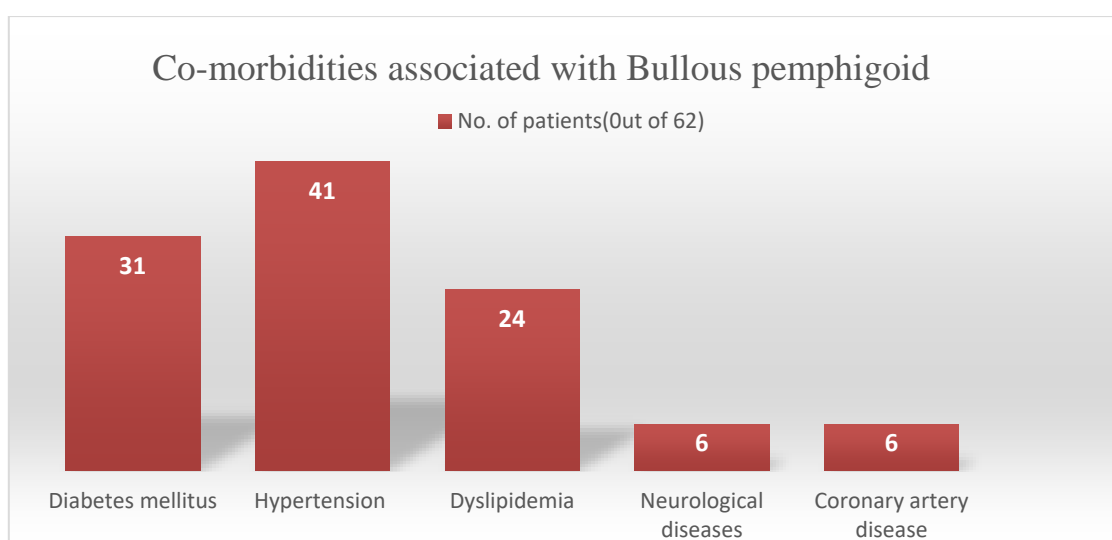


Figure 5: Co-morbidities in Bullous pemphigoid

Investigations

34% patients had peripheral blood eosinophilia. 61 patients had a skin biopsy and DIF done. In Fifty-nine (96.7%) biopsies showed subepidermal bulla. The inflammatory infiltrate was polymorphous, with an eosinophilic predominance. Of the 61 patients who had DIF done, 88% had typical linear deposition of complement 3 (C3) and IgG along the basement membrane. 10% had liner deposits of C3 alone and 2% had IgG alone at the basement membrane zone.

Treatment

Out of the 62 patients, 52 were given systemic steroids. Others were managed with Doxycycline, Nicotinamide, Dapsone, and topical corticosteroids such as betamethasone dipropionate cream or clobetasol propionate cream. The patients who were started on systemic steroids, (equivalent to prednisolone 0.5 to 1.25 mg / kg body weight / day) 83% of them had controls disease within 1 – 2 weeks. 17% required additional immunosuppressants like Azathioprine for disease control. There was no mortality among our patients during hospital stay.

Discussion

The mean age of onset in our patients was 63.3 years. The mean age ranged from 58.4 years to 81 yrs in previous studies [5]. Though more than half of our patients belonged to the age group of 60 - 80 years, 21% of our study population were less than 50 years of age. The youngest patient in our study was 19 years of age. Young patients in our study found to have extensive skin blistering and erosions. A study done in 2005 reported that bullous pemphigoid among young people is more severe and more active than the usual form in the elderly. This could be the result of a higher expression of anti-BP180 autoantibodies, which is considered as a marker of poor prognosis in this disease [6]. In our study, females were affected slightly more than males with a female:male ratio of 1.2:1. This finding

was similar to a study from Singapore. Increased incidence among females may be due to hormonal influences which make them more prone to autoimmune diseases.

Ninety-five percent of our patients presented with blisters and erosions. Other patterns of skin lesions were urticated plaques, eczematous lesions, string of pearl arrangement, periorbital erythema & edema. Vesicular type and dyshidrosiform type of BP were observed in two patients each. Two patients who presented with eczematous lesions, were initially treated for eczema. Itchy rashes in elderly patients that do not improve with emollients or topical steroid may be investigated for the non-bullous phase of BP [5]. Oral mucosal involvement was present in 24% of patients. Prevalence of mucosal lesions in our study was higher than a study from Israel [7]. Among patients with oral lesions, the most involved oral structures were the buccal mucosa, soft palate and hard palate. There were no patients with involvement of other mucosal surfaces in our study. In previous studies, though the most commonly affected mucosa was oral mucosa, involvement of genital and laryngeal mucosal surfaces is also reported [7]. Another study has showed that mucosal lesions are clinically related to disease severity and immunologically to the absence of anti-BP230 antibodies [8].

We could find some atypical presentations of BP, which has to be differentiated from other skin diseases. Facial lesions similar to Pemphigus foliaceus, vesicular BP similar to Dermatitis herpetiformis were observed. We considered erythema multiforme and dyshidrosiform eczema as differential diagnoses for cases in which lesions were limited to palms and soles. Bullous lesions in the interdigital space has to be differentiated from bullous scabies. Bullous scabies can also mimic both in histology and DIF findings of BP [9]. A case of localized Bullous pemphigoid was initially misdiagnosed as herpes simplex virus infection, later skin

biopsy and DIF study revealed the correct diagnosis.

There was high prevalence of hypertension (66%) diabetes mellitus, (50%) and hyperlipidemia (24%) in our study population. This is probably because of elderly population and also because of high prevalence of non-communicable diseases in our part of the country. As the mainstay treatment for Bullous pemphigoid is systemic corticosteroids, it is important to screen the patients for these co-morbidities.

32% of our patients had history of chronic drug intake, 23% of whom were on multiple drugs. 6% of patients were on Amlodipine alone and 3.6% of patients were on Glimipiride. Drug-associated bullous pemphigoid (DABP) is a term used for cases of Bullous pemphigoid demonstrating clinical, histological, or immunopathological features similar to the idiopathic form of bullous pemphigoid, associated with the systemic intake or topical application of drugs. The strongest evidence for drug induced Bullous pemphigoid is seen with gliptins, programmed death-ligand 1 (PD-L1) inhibitors, loop diuretics and penicillin [10]. Identification of the medications associated with bullous pemphigoid enables clinicians to identify cases of drug induced Bullous pemphigoid earlier and stop the offending medication at the earliest.

There are multiple reports indicating strong association between neurological diseases and BP. Specific associations have been suggested between BP and dementia, stroke, parkinson's disease, epilepsy, and multiple sclerosis. In our study, 6 patients (9.68%) had neurological disorders which included Parkinsonism, stroke and dementia. All of them developed Bullous pemphigoid after the onset neurological disease. The prevalence of neurological disorders was less compared to a previous study [11]. Studies have shown that patients who are affected

by BP and neurological diseases have immunogenic BPAG1 in their skin and also in their brain. It has been suggested that alterations of the central nervous system could expose the neural isoforms of BPAG1. Autoantibodies against these antigens in the brain can cross react with antigens in the skin.

34% of our patients had peripheral blood eosinophilia. It has been reported previously that peripheral eosinophilia occurs in 50 – 60% of patients with bullous pemphigoid (BP) and correlated positively with disease severity. Another recent study has showed that patients with BP with serum eosinophilia were older and had higher palmoplantar involvement, and those with a normal eosinophil count were younger and presented more frequently with atypical clinical manifestations^[12]. Such a correlation was not found in our study.

We could not find any case of Bullous pemphigoid associated with malignancy in this study.

Conclusion

This study highlights the atypical presentations of Bullous pemphigoid in terms of site and morphology of the lesions, it's occurrence in younger individuals and associated co-morbidities. Nearly 10 % of patients had associated neurological disorders.

Limitations of the study

The small sample size of the study might not have revealed all the atypical presentations and co-morbidities of Bullous pemphigoid.

References

1. Miyamoto D, Santi CG, Aoki V, Maruta CW. Bullous pemphigoid. *An Bras Dermatol*. 2019;94(2):133-46.
2. Patel F, Wilken R, Patel FB, Sultani H, Bustos I, Duong C et al. Pathophysiology of Autoimmune Bullous Diseases: Nature Versus

- Nurture. *Indian J Dermatol.* 2011; 62(3): 262-7.
3. Otten J V, Hashimoto T, Hertl M, Payne A S et al. Molecular diagnosis in autoimmune skin blistering conditions. *Curr Mol Med.* 2014; 14(1):69-95.
 4. Kridin K, Ludwig RJ. The Growing Incidence of Bullous Pemphigoid: Overview and Potential Explanations. *Front Med* 2018 Aug 20;5:220
 5. Tan SK, Tay YK. Bullous pemphigoid: Profile and outcome in a series of 100 cases in Singapore. *J Dermatol Dermatol Surg* 2018;22:12-5.
 6. Lanoy E B, Roujeau JC, Joly P, Guillaume JC et al. Bullous pemphigoid in young patients: a retrospective study of 74 cases. *Ann Dermatol Venereol.* 2005; 132(2): 115-22.
 7. Kridin. K, Bergman R. Assessment of the Prevalence of Mucosal involvement in Bullous pemphigoid. *JAMA Dermatol.* 2019; 155(2):166-71
 8. Clape A, Muller C, Gatouillat G, Jan SL et al. Mucosal involvement in Bullous pemphigoid is mostly associated with disease severity and to absence of Anti-BP230 autoantibody. *Front Immunol.* 2018;9:479
 9. Cohen P R. Scabies masquerading as Bullous pemphigoid: scabies surrepticius. *Clin Cosmet Investig Dermatol.* 2017;10: 317-24
 10. Verheyden M J, Bilgic A, Murrell D F. A systematic review of drug-induced Pemphigoid. *Acta Derm Venereol.* 2020; 17: 100(15)
 11. Khosravani S, Handjani F, Alimohammadi R, Saki N. Frequency of Neurological disorders in Bullous pemphigoid patients: A cross-sectional study. *Int Sch Res Notices.* 2017; 2017: 6053267.
 12. Kridin K. Peripheral eosinophilia in Bullous pemphigoid: Prevalence and influence on the clinical manifestation. *Br J Dermatol.* 2018; 179(5):1141-7