

Illustrated handbook of Ophthalmology

Rudolf Sachsenweger

*Professor and Doctor of Medicine,
Director of the Eye Hospital,
Karl Marx University, Leipzig*

Translated from the German by
Elizabeth Julius, MA (Oxon.)

Translation Editor:

J. C. DEAN HART, MD, BSc, MBBS, FRCS, DO
*Head of the Department of Ophthalmology,
University of Bristol*



BRISTOL • JOHN WRIGHT & SONS LTD., 1980

German edition © VEB Georg Thieme, Leipzig, 1975
English translation © John Wright & Sons Ltd. 1980

CIP Data

Sachsenweger, Rudolf

Illustrated handbook of ophthalmology.

I. Eyes – Diseases and defects

I. Title II. Julius, Elizabeth

617.7 RE 46

ISBN 0-7236-0494-0

Printed in the German Democratic Republic

Preface

The aim of this book is, by means of a short text and a large number of illustrations, to facilitate the student's understanding of ophthalmology, to further his mastery of an increasing mass of subject matter which has recently become available and to permit intensive study, revision and preparation for examinations. Efforts have been made to present essential information in a concise form, omitting superfluous detail and providing a convenient work of reference for individual study and for those engaged in general practice. Both text and illustrations have been thoroughly vetted by medical students and junior doctors.

Drawings have, in many instances, been given preference over photographs because they are frequently more instructive. References to drugs according to national or brand names are avoided as far as possible.

In the choice of both text and illustrations particular emphasis has been laid on the links between ophthalmology and other medical disciplines.

I am deeply indebted to all those who have helped me in the preparation of this book.

Ophthalmology differs in many respects from other fields of medicine. It is concerned with an organ in which varied kinds of tissue are situated in extremely close proximity to each other, contained within a very small space, the eyeball. The globe has attained its definitive size and efficiency by the sixth year of life, i.e. earlier than any other part of the human body, and both the appositionally growing lens and the vitreous retain the oldest structures of any organ.

It is relatively easy to carry out clinical and experimental observations on the eye in a manner which is impossible in nearly all other branches of medicine, because of the transparency of its refractive media. Historically, instruments to view the fundus and microscopes to magnify the ocular tissues have been employed for about one hundred and fifty years, i.e. since the time when ophthalmology was beginning to emerge as a separate branch of medicine. This has meant that extremely accurate examinations and observations could be made, and pathological processes, often only visible microscopically, have been recognized in many instances for well over a century.

There are many close links between ophthalmology and other branches of medicine, especially internal medicine, because the eye may become involved in the vast majority of systemic diseases. Equally important are the links with neurology, since part of the eye is an extension of the brain, and over half of all cranial nerves lead either exclusively or indirectly to the eye. In addition, there is much common ground with otolaryngology, because of the nearness of the eye to the nasal sinuses, and with dermatology, obstetrics, and hygienic, social and industrial medicine.

The eye, with an approximate weight of 7.5 g, is a relatively small organ. However, the consequences of incorrect diagnosis or treatment of eye disease may be disastrous. A pathological process which at first appears trivial and circumscribed is liable to spread quickly and cause serious loss of vision.

The faculty of sight is of immense importance to human beings for their education, development and work. Good vision is of paramount importance in every human society, at all social levels. Blindness is often regarded as a worse fate

than severe systemic illness or death, and every doctor should be aware of his obligations to his patient and to human society as a whole, for preservation of sight is indeed a heavy duty.

Rudolf Sachsenweger.
Leipzig, May 1974.

Foreword to the English Translation

I have attempted to preserve the flavour and objectives of Professor Sachsenweger's work, in spite of problems arising from translation from the German into the English language. Some modification and reorganization of the text were thought desirable so as to update and rearrange certain sections and to bring other chapters, especially on social ophthalmology and the measurement of visual function, more within the framework adopted by ophthalmologists working in the United Kingdom.

A small textbook of ophthalmology cannot possibly cover the full range of the subject and a didactic approach to controversial aspects is necessary for reasons of brevity, but efforts have been made to retain the strong bias towards medical, as opposed to surgical, ophthalmology adopted by the author. Hopefully this book will appeal to medical and ophthalmic optic undergraduate students receiving instruction in the clinical practice of ophthalmology.

I wish to thank Mrs. Julius for the high quality of her translation and Mrs. Roach for her indefatigable and patient secretarial assistance.

J. C. Dean Hart,
Head of the Department of Ophthalmology,
University of Bristol.

1. Eyelids

General considerations

The successive layers from the exterior to the interior surface are composed as follows (Fig. 1): skin of the lid containing sweat and subcutaneous glands (glands of Zeis and Moll) → loose subcutaneous tissue → circular sphincter muscle (orbicularis oculi muscle supplied by the 7th nerve) → tarsus with meibomian sebaceous glands → conjunctiva fused with tarsus. The upper lid is elevated by the levator palpebrae muscle (supplied by the 3rd nerve) and by the smooth tarsal muscle of Müller (supplied by the sympathetic autonomic system). A number of

tendinous fibres run into the skin of the lids to form the tarsal fold. Orbital septa extend between the orbital margins and the tarsal plates. When the elasticity of these structures is reduced, e.g. in old age, prolapse of orbital fat into the lower lids can occur (Fig. 2d). The loose nature of the subcuta-

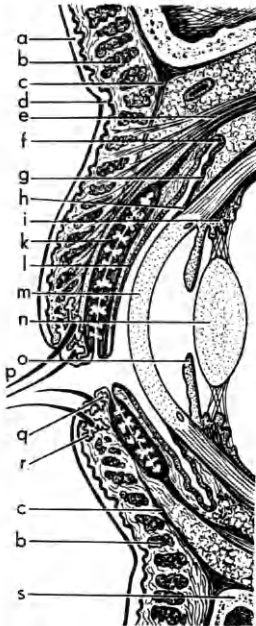


Fig. 1. Cross-section of lid: a skin; b orbicularis oculi muscle (7th nerve); c orbital septum between lid and orbit; d tarsal fold; e tendon and superior levator palpebrae muscle (3rd nerve and sympathetic nerve); f superior fornix; g bulbar conjunctiva; h corneal limbus; i ciliary body; k tarsal plate with sebaceous glands; l tarsal conjunctiva; m cornea; n lens; o iris; p eyelashes; q sebaceous glands; r sweat glands; s orbital bone

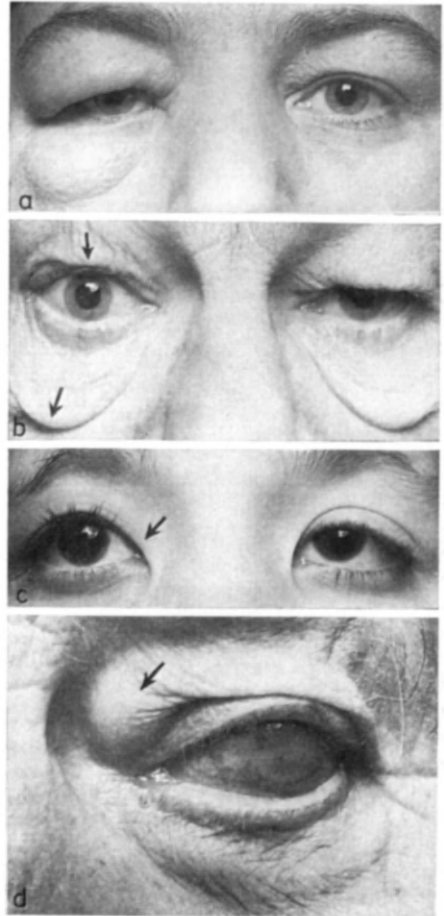


Fig. 2. a Allergic oedema of right lid; b blepharochalasis; c epicanthus; d superior medial fatty herniation (disciform keratitis of the cornea is present)

neous tissue permits oedema fluid to collect (Fig. 2a), and haematoma formation to develop in this layer. The sensory nerve supply of the upper lid is derived from the ophthalmic nerve (1st branch of the 5th nerve), and the lower lid is supplied by the infra-orbital nerve from the maxillary nerve (2nd branch of the 5th nerve).

Protective function of the lids: The lids promote moistening and cleansing of the cornea and act as a movable barrier against dust and sweat. The meibomian glands of the lid prevent over-rapid tear evaporation by secreting an oil film over the watery lacrimal gland secretion. Reflex closure of the lids occurs in response to potential trauma or irritation of the cornea or conjunctiva. At the same time the eyeball moves upwards as the lid becomes closed (Bell's phenomenon).

Examination procedures

The width of the palpebral fissure and the lid-opening ability should be assessed. Complete closure of the lids is impossible in peripheral paresis of the facial nerve, as the orbicularis oculi muscle fails to act (see Fig. 10a). With mild 7th nerve lesions there is a failure to bury the eyelashes on forced lid closure.

To examine the inferior fornix the lower lid is pulled down (Fig. 3a). For eversion of the upper lid (for example, to locate subtarsal foreign bodies) the patient is asked to look down; the examiner takes hold of the eyelashes, presses with a finger, glass rod or match against the superior border of the tarsus 1.5 cm above the lid margin and folds up the upper lid (Fig. 3b-c). To visualize the superior fornix double eversion is carried out by using a blepharostat (Figs. 3d-e, 4).

Palpebral fissure: This is wide in thyrotoxicosis, in exophthalmos (forward protrusion of the globe), when the globe is enlarged, i.e. congenital glaucoma, and in facial paresis. The palpebral fissure is narrowed by ptosis (drooping of the upper lid), enophthalmos (retraction of globe back

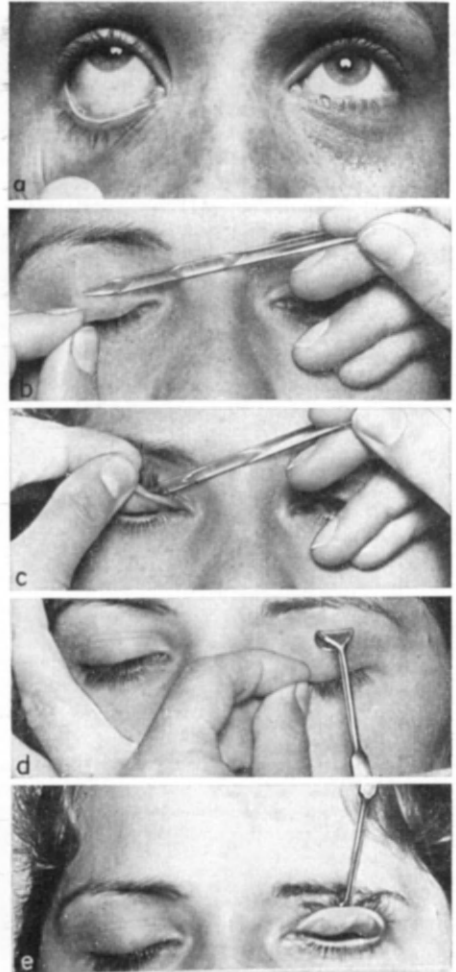


Fig. 3. a Eversion of lower lid with patient looking up; b-c eversion of upper lid using a rod with patient looking down; d-e double eversion using blepharostat

into the orbit), microphthalmos (small eye) and in blepharochalasis (redundancy of the upper lid tissues), which is often a feature of old age (see Fig. 2b).

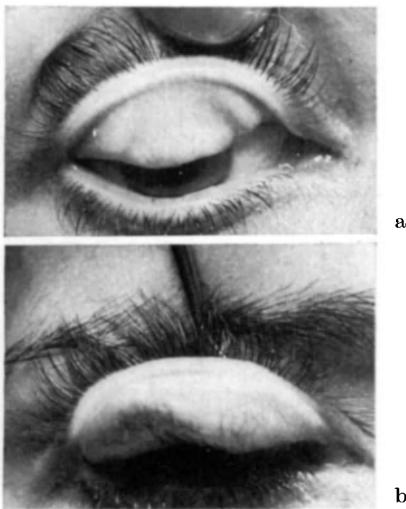


Fig. 4. a Everted upper lid; b doubly everted upper lid using blepharostat

Motility disturbances

Ptosis

Ptosis, unilateral or bilateral, occurs as a feature of 3rd nerve dysfunction (Fig. 5a), resulting, for example, from vascular disease, encephalitis, meningitis, multiple sclerosis, infectious diseases, tumours or

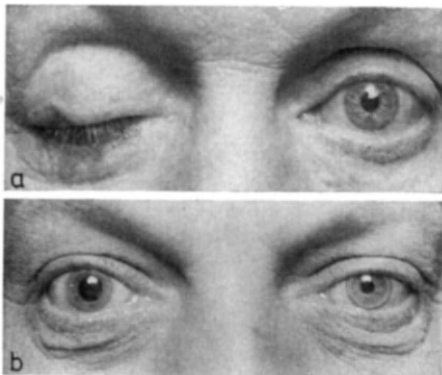

Fig. 5. a Oculomotor paralysis with ptosis (right eye); b Horner's syndrome (left eye)

trauma. Ptosis may also be a feature of neuromuscular diseases such as myasthenia gravis, or occur as a direct result of trauma following section of the levator muscle tendon. Congenital ptosis is usually due to defective development of the levator muscle (Fig. 6a), and the superior rectus muscle may also occasionally be involved in this process; under these circumstances elevation of the eye is impaired. In sympathetic paralysis inaction of the tarsal muscle of Müller produces a mild ptosis, associated with miosis of the pupil and apparent enophthalmos (Horner's syndrome, Fig. 5b).

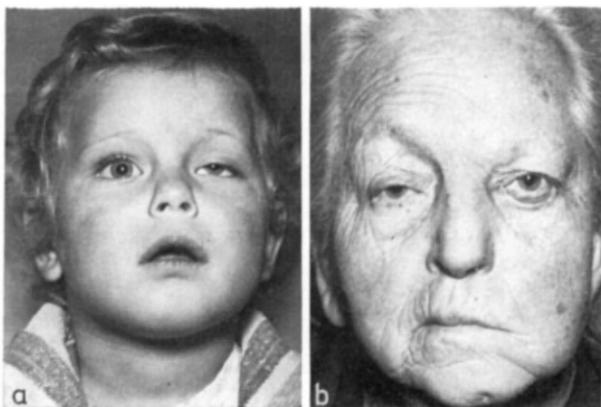

Fig. 6. a Congenital unilateral ptosis with characteristic backwards tilt of head; b left facial paresis with paralytic ectropion

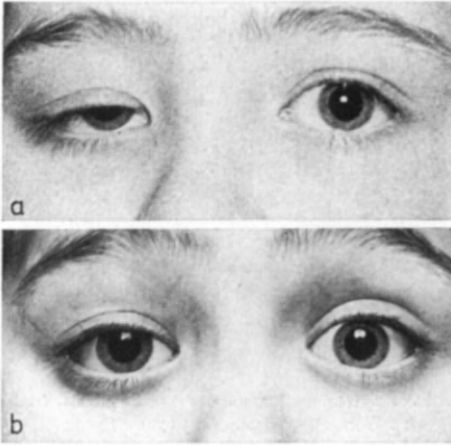


Fig. 7. Congenital ptosis before and after shortening of levator muscle

Treatment of congenital ptosis: If required, this consists of surgical shortening of the levator muscle and/or the tarsus (Fig. 7). Sutures can also be inserted to elevate the lids. In the rare case of complete congenital ptosis, surgery should be performed in infancy to prevent amblyopia (see Chapter 19), resulting from non-use of the eye. Otherwise an operation is delayed until the lid tissues have developed sufficiently to aid identification of structures.

Pseudo-ptosis occurs as a result of inflammatory swelling of the lids, or lack of lid support, e.g. in enophthalmos and microphthalmos.

Lagophthalmos is inadequate closure of the lids due to facial paralysis (Fig. 6b), or scarring of the lids, and is often complicated by exposure keratitis resulting from drying of the cornea (see Chapter 5). **Treatment:** Initially, instillation of eye ointment to reduce drying of the cornea, and placement of a Buller's shield which will also help to prevent corneal desiccation (see Fig. 43d). Tarsorrhaphy or plastic surgery may be necessary to overcome the corneal exposure.

Blepharospasm: This term describes contraction of the lid muscles following irrita-

tion or inflammation of the conjunctiva or cornea (supplied by the 1st branch of the 5th nerve). It disappears rapidly when organic disease is present if the mucous membranes are anaesthetized, except where there is irritation of the 7th nerve, for example in cerebellopontine angle tumour. In a large number of cases blepharospasm is functional in nature, rather than a result of organic disease.

Disturbances of the lid margins

Entropion (rolling in of the lid margin) causes the eyelashes to rub against the cornea (trichiasis), producing ocular discomfort and abrasions or ulceration of the cornea. Senile entropion of the lower lid (Fig. 8a) is due to increased tonus of the fibres of the orbicularis oculi muscle nearest to the lid margin and slackening of connective tissue supports of the lid. Entropion may also be congenital (Fig. 8b). Cicatricial entropion of the upper and lower lids follows scarring of the tarsal conjunctiva, e.g. following chemical burns, mucous membrane syndromes and infections such as trachoma. *Treatment of senile entropion:* A strip of adhesive plaster is applied to pull down the lid (Fig. 9). If the mal position of the lower lid is a constant feature, surgery is required

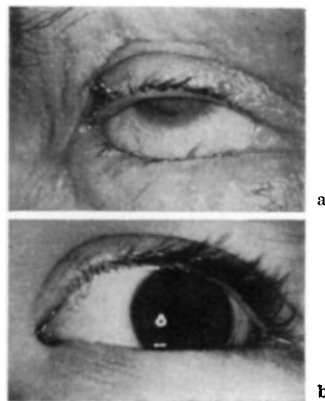


Fig. 8. a Senile entropion; b congenital entropion

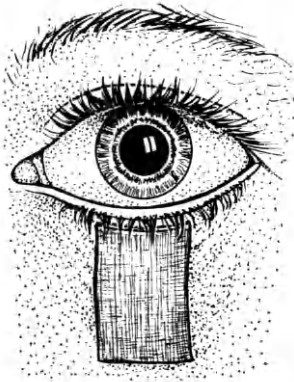


Fig. 9. Strip of adhesive tape for temporary treatment of lower lid entropion

(Fig. 11 a). (Cuneiform tarsal excision from the upper lid is shown diagrammatically in Fig. 13 f–g.) In cicatricial entropion plastic surgery should be contemplated to reconstruct the lid.

Ectropion (outward displacement of the lid margin) causes permanent tearing and chronic conjunctivitis. Paralytic ectropion occurs following 7th nerve paralysis (Fig. 6 b). Senile atonic ectropion (Fig. 10 b–c) is due to decreased tonus of the orbicularis oculi muscle nearest to the lid margin, combined with laxity of the supporting connective tissue structures. Thickening of the lids from chronic conjunctivitis develops with permanent tearing. Cicatricial ectropion arises as a result of traction exerted by scarring of the skin of the lids (Fig. 10 d–e), e.g. following thermal and chemical burns, chronic atopic eczema or inadequate surgical treatment of penetrating lid wounds.

Treatment: (Surgery (Fig. 11 b); skin grafting may be necessary (Fig. 12).

For abnormal variations in the position of the eye lashes, see Fig. 13.

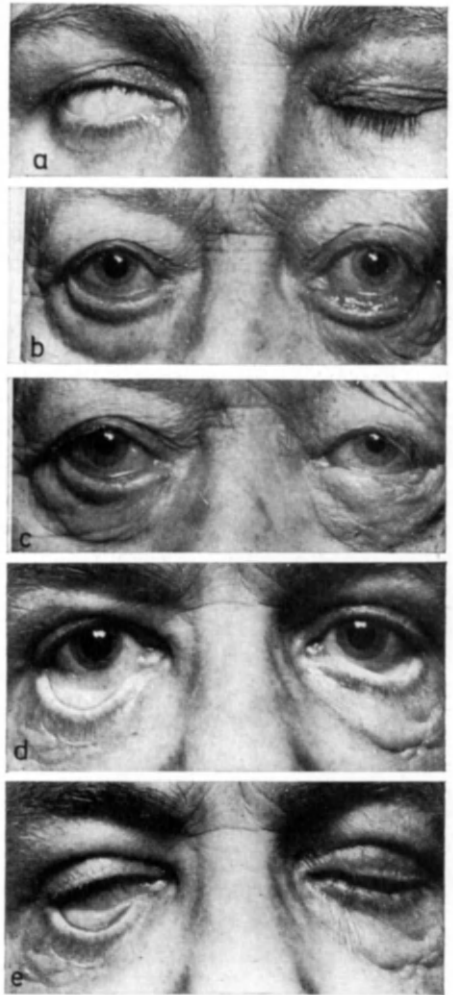


Fig. 10. a Incomplete closure of lids in facial paresis of right eye; b–c senile ectropion of left eye, before and after surgery; d–e cicatricial ectropion of both lower lids following windscreen injury, with incomplete closure of right eye

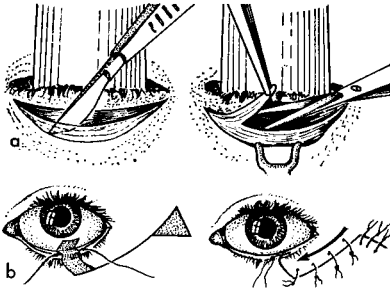


Fig. 11. a Surgical treatment of senile ectropion by excision of fibres of the orbicularis oculi muscle close to lid margin; b surgical treatment of ectropion by shortening the lower lid margin

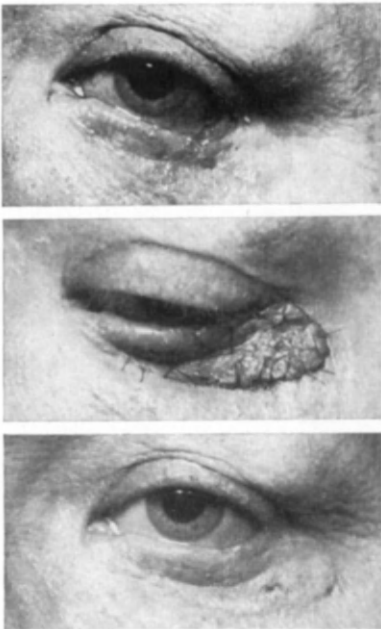

Fig. 12. Treatment of cicatricial ectropion by means of skin graft after a thermal burn to lid: a preoperative appearance; b skin graft with sutures; c appearance 6 months after operation

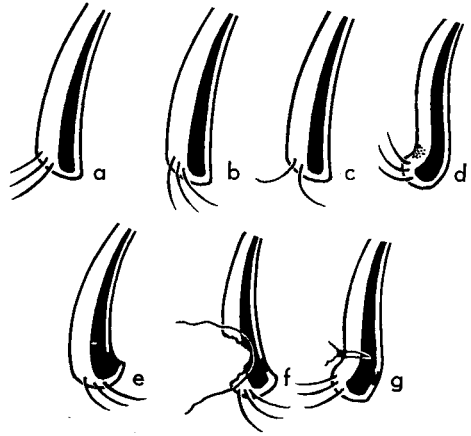


Fig. 13. Variations in position of the eyelashes of the upper lid: a normal; b trichiasis; c distichiasis; d cicatricial ectropion; e cicatricial entropion; f-g cuneiform tarsal excision as surgical treatment of a cicatricial entropion

Lid inflammations

Bacterial infections

Hordeolum (stye): The patient complains of localized pain in the lid. On examination there is redness and swelling of the lid and pus can often be seen pointing towards the skin or the conjunctiva. An external hordeolum is the result of bacterial infection involving the sweat and sebaceous glands in the lid margin area, and an internal hordeolum occurs following infection of the Meibomian glands (Fig. 14a and b). Frequent recurrence of these conditions is known as hordeolosis, and any patient who has repeated styes of the lids should be checked for Diabetes mellitus. **Treatment:** Warm compresses and antibiotic ointment to prevent infection spreading to other secretory ducts. Incision and drainage of pus is rarely necessary, and systemic antibiotics are not required unless the inflammation spreads to involve the whole lid.

Chalazion: A chronic inflammation of the Meibomian gland which produces a round,

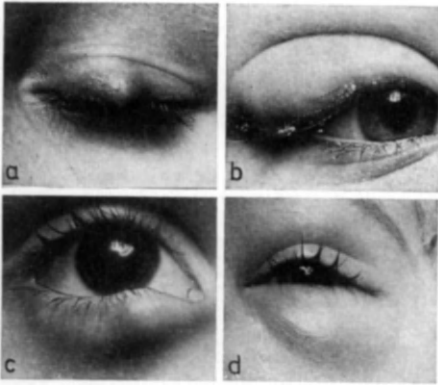

Fig. 14. a External hordeolum; b internal hordeolum; c chalazion; d lid abscess

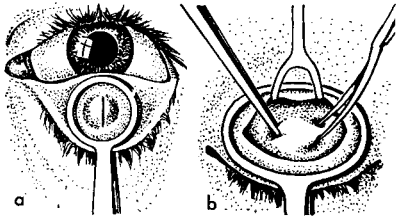


Fig. 15. Chalazion operation from the interior (left) and exterior (right) using a chalazion clamp

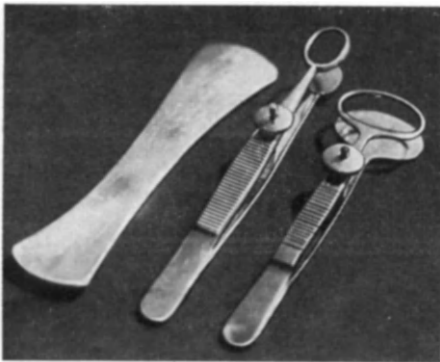


Fig. 16. Left: Guard to protect eye during lid surgery; right: chalazion clamps for holding chalazion and lid so as to prevent bleeding into operation site

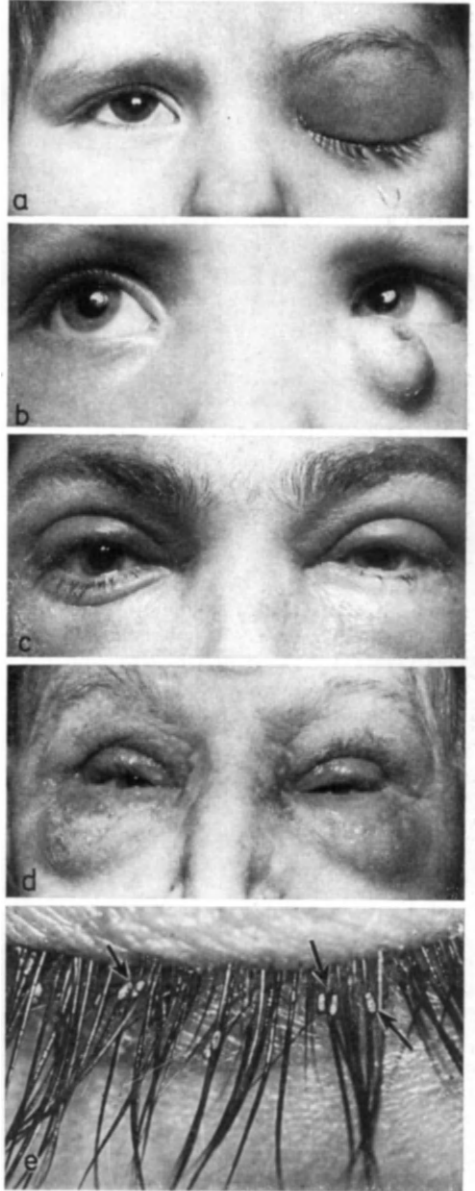

Fig. 17. a Initial stage of lid abscess following hordeolum; b perforated lid abscess following ethmoidal sinusitis; c oedema of lids in allergy to miotics; d lid eczema in allergy to atropine; e lice on eyelashes

non-tender swelling above which the overlying skin is mobile (Fig. 14c). Vision may be somewhat affected by the nodule pressing on the cornea, causing irregular astigmatism (see Chapter 18). **Treatment:** Surgical; incision and curettage may be required (Fig. 15). The chalazion is held in a special clamp to prevent bleeding (Fig. 16), incised from the conjunctival surface and the contents curetted out. **Differential diagnosis:** Malignant tumours of the Meibomian gland. If a recurrence of an apparent chalazion occurs at the same site. Tissue should be sent for histological examination to check that there is no evidence of malignancy.

Lid abscess and lid cellulitis (Figs. 14d, 17a): There is marked redness, swelling and tenderness of the entire lid, and the local lymph nodes may be enlarged. The patient occasionally has a mild pyrexia, but the motility of the eyeball is unimpaired (this is disturbed in cases of orbital cellulitis). **Aetiology:** Spreading infection from styes, sinus infection (Fig. 17b), periostitis, infected wounds or erysipelas of the lids. **Treatment:** Systemic antibiotics and, if there is pus pointing towards the surface, incision and drainage should be considered.

Lid margin inflammations

Blepharitis: This condition is due to bacterial or allergic inflammations and is often a combination of both. **Squamous blepharitis:** Scales develop between the eyelashes and there is a tendency for hordeolosis. Often patients suffer from dandruff. **Ulcerative blepharitis:** Ulceration occurs in the lid margins and this may be followed by scarring, falling out of the eyelashes (Fig. 19a) and distichiasis (Fig. 13c). **Treatment:** Loosening of any scales and crusts with bland ointment, application of local antibiotics and, if necessary, steroid eye ointment. Electrolysis to removed malpositioned lashes.

Viral infections of the lids

Herpes zoster ophthalmicus (shingles): Herpetic vesicles develop unilaterally in the

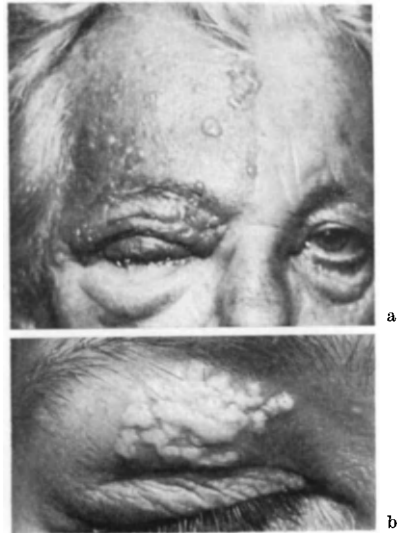

Fig. 18. a Herpes zoster ophthalmicus; b herpes simplex

skin supplied by the 1st branch of the trigeminal nerve (Fig. 18a). The vesicles become crusted and may become secondarily infected. The patient complains of severe unilateral headache; both skin and corneal sensitivity is reduced. Pain frequently persists long after the skin lesions have healed. Herpes zoster ophthalmicus occurs mainly in patients over the age of 45. The upper lids are swollen because of the inflammatory response, and the lower lids often swell as a result of dependent oedema. The virus may affect the cornea, causing a punctate epithelial keratitis or, more rarely, a disciform keratitis (see Chapter 5). Other complications of Herpes zoster ophthalmicus include iritis, in which there is commonly a rise in intra-ocular pressure, scleritis, ischaemic optic neuritis and extra-ocular muscle palsies. Pupillary defects may also be present, and iris atrophy is a common post-inflammatory finding. **Treatment:** Analgesics should be given for the pain. Creams containing antiviral agents applied to the skin may reduce the post herpetic

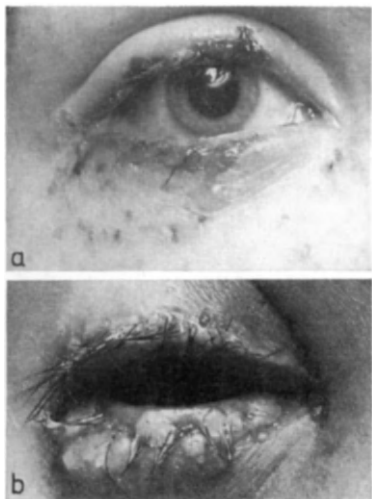


Fig. 19. a Ulcerative blepharitis; b vaccinia pustules (following vaccination)

neuralgia, and topical antibiotics should be instilled into the conjunctival sacs to prevent secondary infection. Mydriatics and local steroids are required if there is any evidence of iritis.

Herpes simplex of the lids (Fig. 18b): Vesicular lesions appear and the lids may be swollen. The disease, if limited to the lids, does not cause any complications and no treatment is necessary.

For corneal lesions see Chapter 5.

Vaccinial blepharitis: Auto-inoculation of the eyelids from primary vaccination sites causes severe lid swelling (Fig. 19b). Corneal opacification and scarring occur if viral particles enter the corneal stroma. **Treatment**: Regular instillation of immune serum into the conjunctival sac is said to be helpful if corneal lesions develop.

Molluscum contagiosum infection: Small umbilicated pearly lesions appear on the lids (Fig. 21d). The patient complains of ocular irritation and, on eversion of the upper lids, a marked follicular conjunctival response is noted. **Treatment**: Removal of the skin lesions by curettage.

Phthiriasis is the invasion of the eyelashes by lice (see Fig. 17e).

Oedema of the lids: This occurs in response to hypersensitivity or allergic reactions (Fig. 17c-d), and is a feature of renal insufficiency, infectious processes in the lids or surrounding areas and eczema of the lid skin. Vision can be temporarily impaired because the patient is unable to open the eyes. **Treatment**: Removal of cause. In allergic or hypersensitivity conditions, antihistaminics or steroid preparations may be helpful.

Tumours

Benign tumours: Of the lids include warts (Fig. 20a), fibromas, xanthelasma, haemangiomas (Fig. 20c-d), varices, epithelial cysts and naevi (Fig. 20b). **Xanthelasma**: Lipid deposits form in individuals usually aged 40 or over (Fig. 20f), but may also appear in younger patients with high serum lipid or cholesterol levels. **Dermoids**: Usually noted at birth and most often found in the superior exterior and interior bone suture areas (Fig. 20e). Surgical removal is indicated if the lesion is cosmetically disfiguring. Histologically, they consist of displaced fragments of skin with epidermis, sebaceous material and hair. **Differential diagnosis**: Encephalomenocele.

Neurofibromatosis (von Recklinghausen's disease, Fig. 20g-h): Apart from the presence of pigmented (**café-au-lait**) spots and fibromas on the body, neurofibromas of the nerves of the lids may cause swelling (Plexiform neuroma). Iris nodules are frequently seen and, more rarely, retinal and optic nerve tumours.

Rarer benign tumours include retention cysts in sweat glands, venous varices, milia and retention cysts in dermal glands (Fig. 21a, b, c and e).

Malignant tumours: **Rodent ulcer** (basal cell carcinoma, Fig. 21f) is the commonest malignant tumour of the lids. The tumour has a raised edge, indurated base and often an

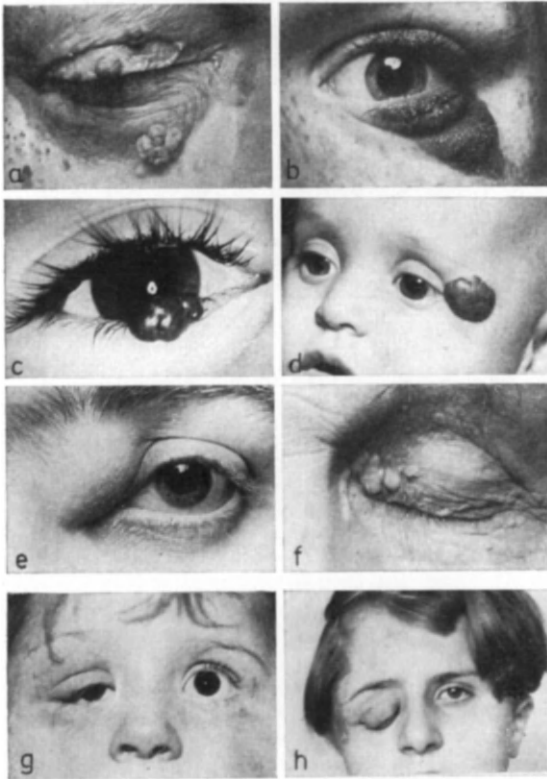


Fig. 20. a Infective warts; b naevus; c-d haemangiomas; e dermoid (right eye, superior nasal); f xanthelasma; g-h plexiform neuroma of right upper lid in a girl with neurofibromatosis at the ages of 4 and 14 years

ulcerated centre with a tendency to bleed. Rodent ulcers tend to occur in the older age group and especially in paleskinned individuals who are engaged in outdoor activities. Progression is local without metastases, but the neoplasm may infiltrate widely if not adequately treated. **Squamous cell carcinoma** (Fig. 22a-b) is highly malignant and spreads via the lymphatic system. It sometimes occurs as a complication of other diseases, such as **xeroderma pigmentosum** (Fig. 22e) but rodent ulcers are more frequent. **Malignant melanomas** are rare tumours of the lids, but readily metastasize, and the overall prognosis for the patient is poor (Fig. 22d). Other malignant tumours, including sarcomas (Fig. 22c),

are very rare. **Treatment:** Malignant tumours of the lids should be excised, after a confirmatory biopsy, ensuring that a rim of at least 3 mm of healthy skin is removed with the tumour. Plastic surgery to fill in defects following removal of the mitotic lesion may be required (Figs. 22f, 23). Radiotherapy is an alternative form of treatment for basal cell carcinoma.

Developmental abnormalities

Ankyloblepharon: The upper and lower lids do not separate completely at birth (Fig. 24b), and it may be possible to divide the adhesions with scissors. **Congenital coloboma** of the lids occurs as a result of de-

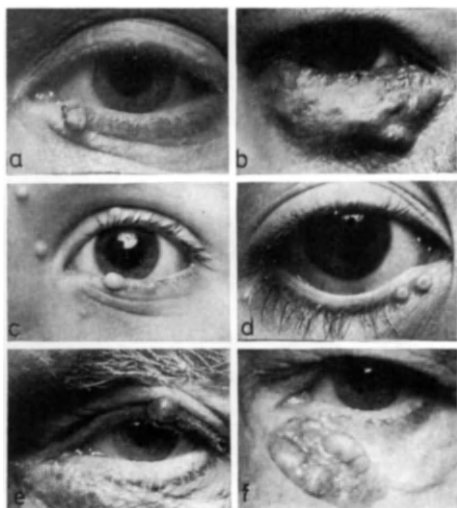

Fig. 21. a Papilloma; b venous varices in lower lid; c milia (retention cysts in dermal glands); d molluscum contagiosum; e retention cysts in sweat gland; f basal cell carcinoma

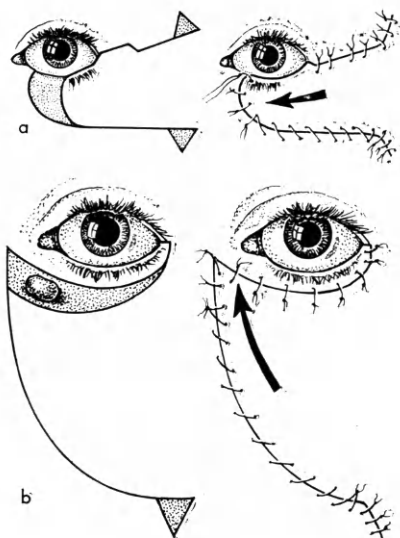


Fig. 23. Plastic surgery to lids after tumour removal: a sliding skin graft from temporal region; b sliding skin graft from cheek

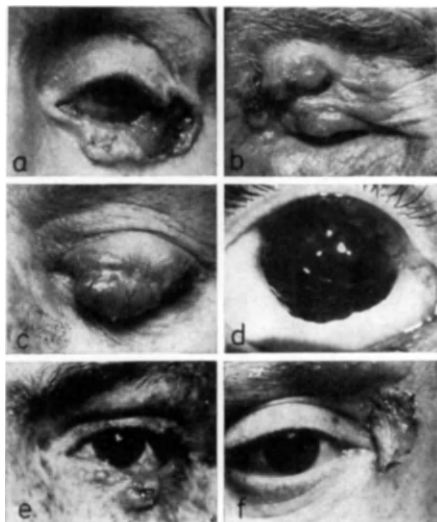


Fig. 22. a-b Squamous cell carcinoma; c fibrosarcoma; d malignant melanoma; e carcinoma associated with xeroderma pigmentosum; f skin graft 6 days after removal of a basal cell carcinoma

fective formation of the lids in utero (Fig. 24a). The eyelids may also be involved in cases of facial cleft syndrome (Fig. 24d). In congenital trichiasis and congenital entropion the lashes rub against the cornea (Fig. 8b). In the latter condition no treatment is necessary as the defect corrects itself spontaneously. Blepharophimosis is a horizontally constricted palpebral fissure (Fig. 24c). Epicanthus is a crescent-shaped fold of skin on the medial side of the palpebral fissure (Fig. 2c), which is often a racial characteristic and may also occur in trisomy 21 (Down's syndrome), as well as in nonmongoloid infants (usually disappearing spontaneously by about the fourth year, as the bridge of the nose develops).

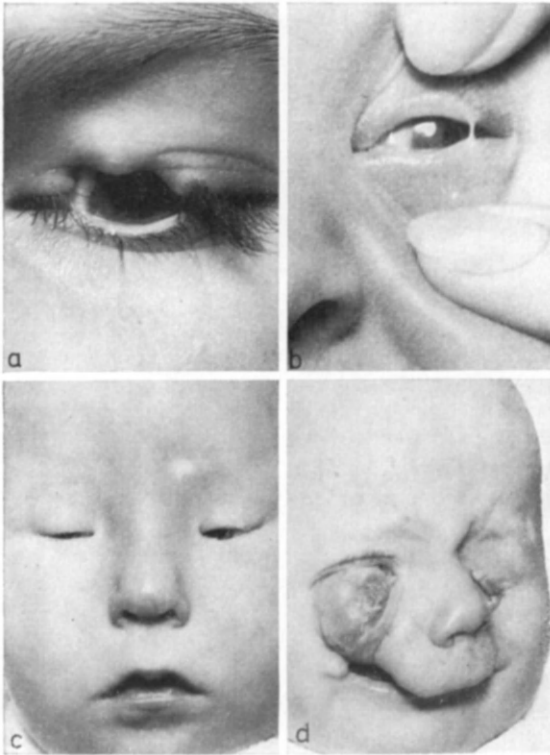


Fig. 24. a Congenital coloboma of upper lid; b ankyloblepharon (partial adhesion of upper and lower lid); c blepharophimosis; d severe bilateral facial cleft defect involving both lower lids

2. Lacrimal Apparatus

General considerations

Lacrimal gland (Fig. 25): The gland is roughly the size of a broad bean, and is situated in the superior temporal aspect of the orbit. It is partially divided by the orbital septum and the tendon of the levator palpebrae muscle into orbital and palpebral lobes. The gland has a tubulo-alveolar structure with numerous lobules (Fig. 26) and is similar in structure to the parotid gland. Secretions from the lacrimal gland drain through twelve secretory ducts. The gland is supplied by parasympathetic, sympathetic and sensory nerves, the last being by the lacrimal nerve (1st branch, 5th nerve). Tears moisten, clean and nourish the cornea, and are bactericidal due to

the action of the enzyme lysozyme. Tear secretion is not normally directly under nervous control, but increased secretion of tears is triggered by stimulation of the trigeminal nerve due to irritation of the cornea or conjunctiva.

Lacrimal drainage system: The tears drain into the inferior and, to a lesser extent, the superior puncta → lacrimal canaliculi → lacrimal sac → nasolacrimal duct (Fig. 27), which opens into the nose beneath the inferior turbinate bone.

Developmental abnormalities include defects of the lacrimal gland (rare), defective development of the canaliculi, fistulas of the lacrimal sac, and obstructions of the nasolacrimal sac.

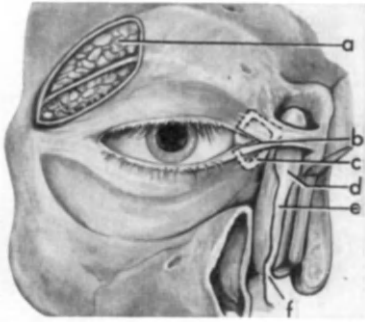


Fig. 25. Lacrimal apparatus: a lacrimal gland with orbital and palpebral lobes; b lacrimal puncta; c lacrimal canaliculus; d lacrimal sac; e nasolacrimal duct; f opening of duct into nasal cavity

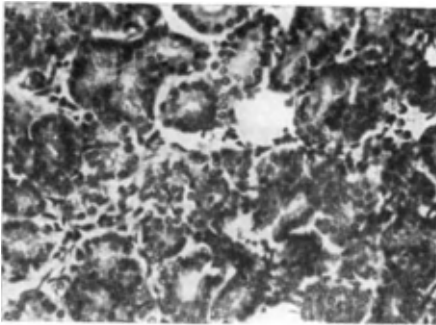


Fig. 26. Tubulo-alveolar structure of lacrimal gland

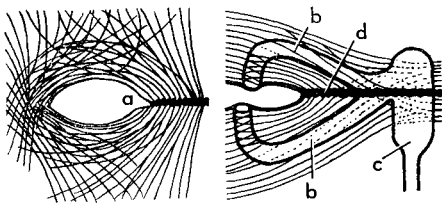


Fig. 27. Suction and pumping mechanism of the lacrimal canaliculi by the orbicularis oculi muscle: a medial canthus; b lacrimal canaliculi; c lacrimal sac; d medial palpebral ligament

Examination procedures

Examination for patency of the lacrimal drainage apparatus: Is performed by instilling drops of sodium fluorescein 2 per cent or saccharin solution into the conjunctival sac. If the drainage pathways are open the dye will appear on tissues when the nose is blown, or the patient tastes the sweet solution. In cases with chronic dacryocystitis, pressure on the skin over the lacrimal sac causes retained pus or mucoid material to be expressed through the puncta (Fig. 28 b). The Schirmer test for measuring tear secretion consists of placing a strip of filter paper 0.5 cm wide inside the lower lid (Fig. 28 a). After 5 minutes it should be wetted over a distance of at least 1.5 cm. If less, there is deficient tear secretion. The patency of the lacrimal drainage system may also be investigated by cannulating the canaliculi and syringing the ducts with normal saline (Fig. 29 a-b). Reflux of fluid from the puncta indicates that an obstruction is present. With an obstruction of the

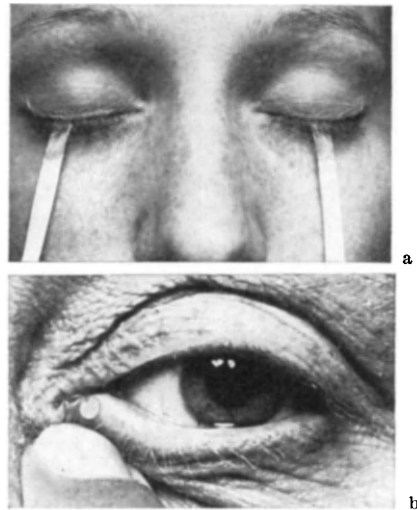


Fig. 28. a Measurement of tear secretion, Schirmer's test; b expression of pus by pressure on lacrimal sac in a case of dacryocystitis

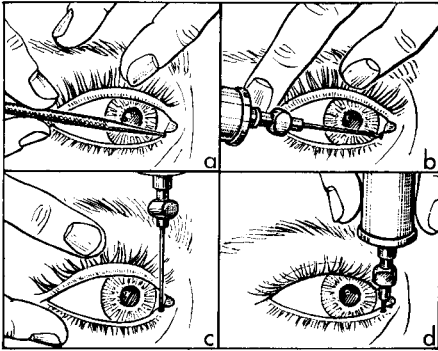


Fig. 29. Probing and irrigation of lacrimal drainage system: a dilatation of lacrimal punctum and canaliculus with a punctum dilator; b insertion of a probe or blunt-ended cannula horizontally into the canaliculus until it touches the bone; c position of probe or cannula when searching for entrance to the osseous canal of the nasolacrimal duct; d deeper probing until the floor of the nasal cavity is reached

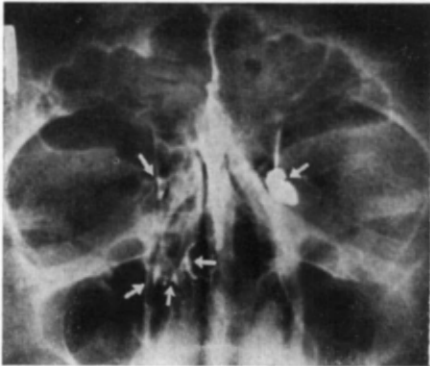


Fig. 30. Contrast X-ray: right lacrimal system is patent; the contrast fluid has reached the nose; left lacrimal system is obstructed, the contrast fluid remains in the lacrimal sac

common canaliculus the cannula cannot be fully advanced, and a tug on the lower lid is felt. In patients where the obstruction occurs at the junction between the nasolacrimal sac and the nasolacrimal duct, the cannula tip can be advanced fully to come

into contact with the medial wall of the sac. X-rays taken after the introduction of radio-opaque material into the sac allow identification of the exact level of any obstruction (Fig. 30).

Causes of tearing

Excessive tear production (lacrimation).

Defective drainage of tears (epiphora).

Hypersecretion of tears from the lacrimal gland is caused by infective, chemical, thermal, mechanical or emotional stimuli. **Treatment:** As to cause.

Epiphora results from drainage defects due to stenosis or obstructions of the lacrimal drainage system (usually located at the entry to and exit from the lacrimal sac); blockage may also be caused by foreign bodies such as eyelashes or fungal growths (dacryoliths) blocking the canaliculi. Epiphora occurs if the lower lacrimal punctum is not in its correct position in relationship to the globe, i.e. ectropion, or if there is notching of the lower lid following trauma, as the tears then flow over the defect.

Treatment: Medications to decrease lacrimal secretion may be tried, but are rarely effective. In congenital obstructions of the nasolacrimal duct following the failure of medical therapy, probing is the treatment of choice. In acquired obstructions of the nasolacrimal drainage apparatus, surgery is always indicated if a cure is to be obtained.

Dry eyes

Hyposecretion of the lacrimal gland is one of the signs of **Sjögren's syndrome** (in which there is generalized hyposecretion of mucous glands). This results in a number of disorders including chronic rhinitis, dry mouth, difficulty in swallowing, achylia, vaginitis and chronic arthritis. Haematological investigations may reveal anaemia and an increase in the blood sedimentation rate. **Mikulicz's syndrome:** Symmetrical painless swelling of the lacrimal and salivary glands, associated with hyposecretion of tears and saliva. **Causes** include leukae-

mias, reticulosis and sarcoidosis. Deficiency of tear formation gives rise to **keratoconjunctivitis sicca**. Superficial punctate or filamentary corneal disturbances develop (see Chapter 5) and patients complain of moderate or severe ocular discomfort. Instillation of Rose Bengal into the conjunctival sac will identify areas of punctate erosion and the presence of any filaments. Tear secretion is reduced if the ducts of the lacrimal glands are obliterated by subconjunctival scarring following infectious diseases such as trachoma, conjunctival burns and mucous membrane diseases (e.g. ocular pemphigoid, Stevens-Johnson syndrome). **Treatment:** Regular instillation of artificial tear solutions prevents corneal drying and allows a protective film to be maintained over the cornea. Surgical obliteration of the lacrimal puncta may be necessary where tear secretion is grossly reduced.

Diseases of the lacrimal gland

Acute dacryo-adenitis is usually unilateral (Fig. 31a-c), occurring in association with mumps, influenza or measles, or following direct spread of bacterial infection from the

lids or surrounding structures. Features include painful swelling, redness and tenderness of the upper lid over the site of the gland. The upper lid margin develops an S shape, and if the lid can be everted the swollen gland may be identified. In rare instances an abscess forms, draining either into the conjunctival sac or externally through the skin. **Differential diagnosis:** Stye (localized in the lid), lid abscess (involving the entire lid), orbital cellulitis (features include fever, reduced globe mobility and exophthalmos). **Treatment:** Warm compresses, antibiotics and incision only if pus can be seen pointing towards the surface.

Chronic dacryo-adenitis: Unilateral or bilateral painless, firm, tumour-like swellings appear in the region of the gland. A sinuous shape of the upper lid margin can develop. **Aetiology:** Syphilis, tuberculosis, sarcoid, benign lymphomas, lymphatic leukaemia and reticulosis. Hyposecretion of tears is often present. **Treatment:** Should be directed towards the underlying cause.

Tumours

Malignant tumours of the lacrimal gland: Approximately 90 per cent of these are due

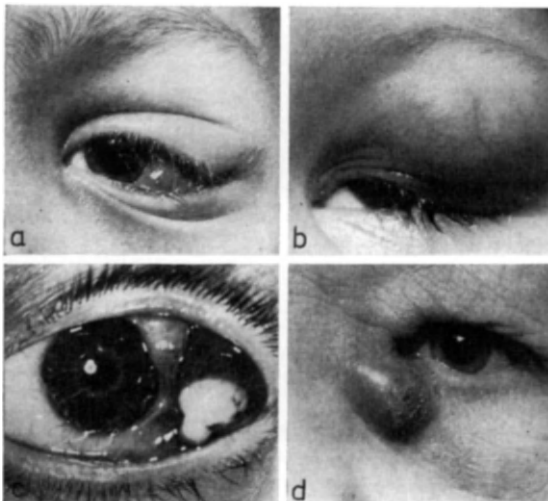


Fig. 31. a Acute dacryoadenitis; b initial stage of lacrimal gland abscess; c lacrimal gland abscess discharging into the conjunctival sac; d acute dacryocystitis

to mixed cell tumours, which are slowly growing and cause downward, nasal and forward displacement of the globe. The patient may complain of diplopia and defective vision (as a result of corneal astigmatism) following pressure by the mass on the globe. **Treatment:** Early and radical surgery is required if a cure is to be obtained. These tumours are extremely radio-resistant. Other, rarer, malignant tumours are adenocarcinomas and cylindromas.

Benign tumours include lymphomas, adenomas and retention cysts (dacryops). Surgery is rarely required.

Diseases of the lacrimal sac

Dacryocystitis

Partial or complete obstructions of the junction between the nasolacrimal sac and the duct cause tears to pool, and retained secretions become infected. The condition is usually seen in the over 40 age group, but also occurs in children as a result of congenital obstruction of the nasolacrimal duct.

Acute dacryocystitis produces swelling, redness of the overlying skin and also pain (Fig. 31d). There is often swelling of the submandibular lymph nodes and, in some cases, a mild pyrexia may be present. Marked swelling of the lids may also be a feature (Fig. 33). Complications include

fistulas between the sac and the overlying skin, dacryocellulitis or orbital cellulitis. **Treatment:** Systemic antibiotics, warm compresses. After the inflammation has subsided in adults the obstruction must be relieved by performing a dacryocystorhinostomy (Fig. 32) so that pooling of tears does not recur.

Chronic dacryocystitis: The patient complains of epiphora, but there is no inflammation or pain. Pressure on the skin over the lacrimal sac causes pus or mucoid material to be expressed through the puncta (Fig. 28 b). **Complications:** Lacrimal sac mucocele, acute dacryocystitis, conjunctivitis and corneal ulcers (**intra-ocular surgery should not be performed where there is evidence of chronic dacryocystitis due to the continuous inundation of the normally sterile conjunctival sac with pathogenic organisms, usually pneumococci**). **Treatment:** Surgical; dacryocystorhinostomy is curative. This operation creates an alternative passage for tear flow, so that the tear secretions enter the nose between the middle and inferior turbinate bones (Fig. 32).

Dacryocystitis of the newborn: The nasolacrimal ducts may not be fully patent at

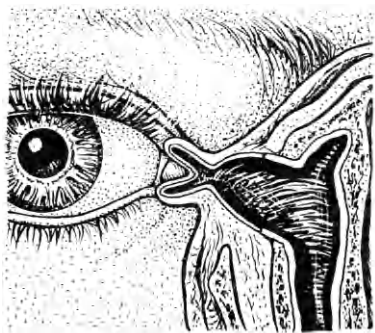


Fig. 32. Schematic cross-section after dacryocystorhinostomy (see text)

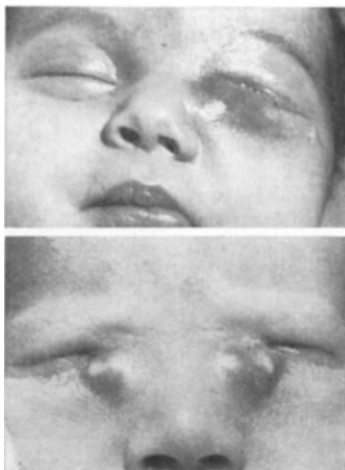

Fig. 33. Unilateral and bilateral dacryocellulitis in infants

birth. This results in stasis of tears → infection → dacryocystitis (Fig. 33), epiphora and chronic conjunctivitis. With growth, the obstructions usually break down spontaneously. Initial treatment is medical, consisting of massage over the nasolacrimal sac, and the instillation of antibiotic drops into the conjunctival sac. If the con-

dition persists, membranes are ruptured by passing a probe under general anaesthesia (Fig. 29a–d).

Bloody tears can result from bleeding tumours of the nasolacrimal drainage apparatus, or from vicarious menses.

Tumours of the lacrimal sac are rare; 50 per cent are similar in cell type to papillomas and transition cell carcinomas of the nose and paranasal sinuses.

3. Eyeball

General considerations

The eyeball is situated in, and protected by, the orbit, where it is suspended by the orbital fascia, four rectus muscles (pulling it backwards) and two oblique muscles (pulling it forwards) (see Fig. 164). The eyebrows protect the eyes from foreign bodies and sweat. Tenon's capsule, an ill-defined connective tissue capsule, is attached to the sclera by fine fibres. The sagittal bulbar axis is approximately 24 mm long in adults (17 mm in newborn infants).

The eye is composed of three layers (Figs. 34, 35), as follows:

1. Tunica fibrosa: The outer coat or protective shell, consisting of the collagenous cornea and sclera, the latter having openings for the optic nerve, four or more vortex veins, the ciliary arteries, ciliary nerves and aqueous veins.

2. Tunica vasculosa: The middle layer or uvea, comprising the choroid, ciliary body and iris.

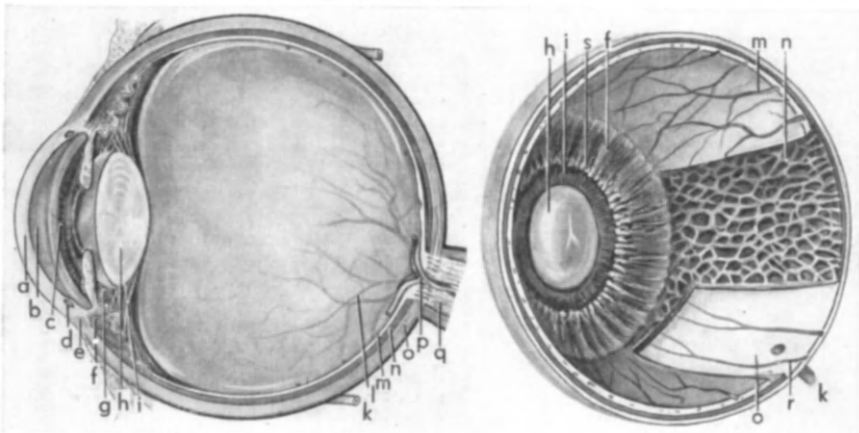


Fig. 34. Left: Cross-section of eyeball; right: opened eye viewed from behind looking towards the ciliary body and lens (note the three layers: sclera, choroid and retina). a Cornea; b interior chamber; c iris; d canal of Schlemm and anterior chamber angle; e corneal limbus; f ciliary body; g posterior chamber; h lens; i zonule; k vortex veins; l vitreous; m retina; n choroid; o sclera; p central retinal artery and vein; q optic nerve; r long ciliary arteries; s ciliary processes

birth. This results in stasis of tears → infection → dacryocystitis (Fig. 33), epiphora and chronic conjunctivitis. With growth, the obstructions usually break down spontaneously. Initial treatment is medical, consisting of massage over the nasolacrimal sac, and the instillation of antibiotic drops into the conjunctival sac. If the con-

dition persists, membranes are ruptured by passing a probe under general anaesthesia (Fig. 29a–d).

Bloody tears can result from bleeding tumours of the nasolacrimal drainage apparatus, or from vicarious menses.

Tumours of the lacrimal sac are rare; 50 per cent are similar in cell type to papillomas and transition cell carcinomas of the nose and paranasal sinuses.

3. Eyeball

General considerations

The eyeball is situated in, and protected by, the orbit, where it is suspended by the orbital fascia, four rectus muscles (pulling it backwards) and two oblique muscles (pulling it forwards) (see Fig. 164). The eyebrows protect the eyes from foreign bodies and sweat. Tenon's capsule, an ill-defined connective tissue capsule, is attached to the sclera by fine fibres. The sagittal bulbar axis is approximately 24 mm long in adults (17 mm in newborn infants).

The eye is composed of three layers (Figs. 34, 35), as follows:

1. Tunica fibrosa: The outer coat or protective shell, consisting of the collagenous cornea and sclera, the latter having openings for the optic nerve, four or more vortex veins, the ciliary arteries, ciliary nerves and aqueous veins.

2. Tunica vasculosa: The middle layer or uvea, comprising the choroid, ciliary body and iris.

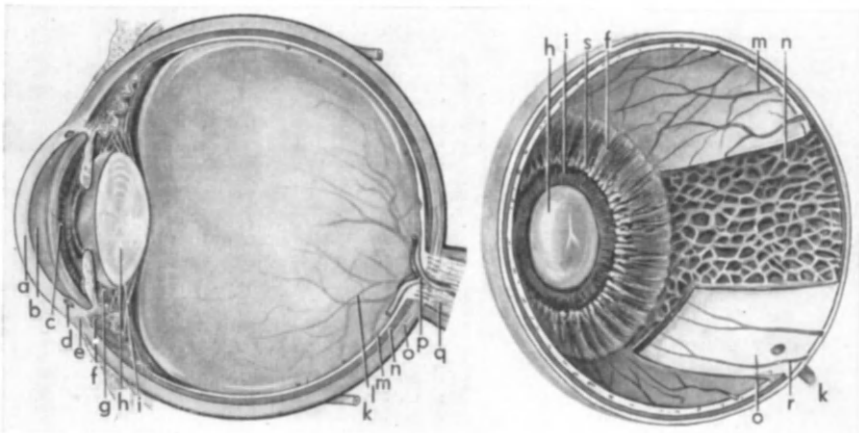


Fig. 34. Left: Cross-section of eyeball; right: opened eye viewed from behind looking towards the ciliary body and lens (note the three layers: sclera, choroid and retina). a Cornea; b interior chamber; c iris; d canal of Schlemm and anterior chamber angle; e corneal limbus; f ciliary body; g posterior chamber; h lens; i zonule; k vortex veins; l vitreous; m retina; n choroid; o sclera; p central retinal artery and vein; q optic nerve; r long ciliary arteries; s ciliary processes

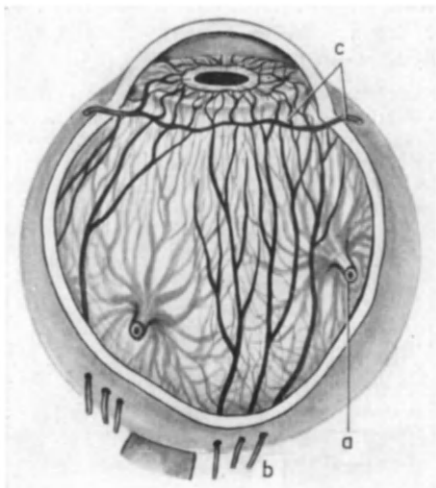


Fig. 35. Arteries and veins of the circulatory network of the uveal tract; **a** vortex vein; **b** posterior ciliary arteries; **c** limbal network

3. Tunica nervosa: The inner lining layer or retina. This tissue transforms light radiation into nervous impulses.

There are three chambers in the eye: the anterior chamber, the posterior chamber and the vitreous cavity.

The optical (refractive) apparatus of the eye consists of the pre-corneal tear film, cornea, aqueous, crystalline lens and vitreous. The retina and optic nerve form part of the receptor (sensory) apparatus. The total refractive power of the eye is approximately 59 dioptres. The power of the cornea is approximately 44 dioptres, and the lens provides some 15 dioptres.

Embryology

As early as the 2 mm stage (Fig. 36), two grooves form on the cerebral plate, which soon develop into the optic pit depressions (a). When the neural tube closes, the optic vesicles (b) are formed. These invaginate to produce the two optic cups (c). A portion of the optic cup grows more slowly than the surrounding tissue, thus creating a choroidal fissure (d), which continues along the optic stalk as a

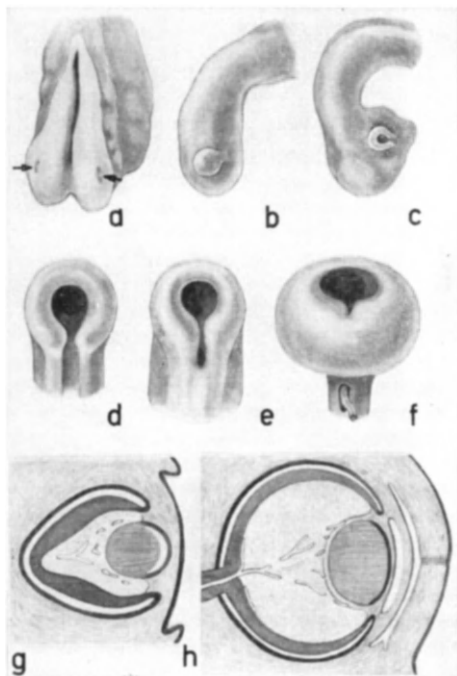


Fig. 36. Embryological development of the eye (see text)

groove (e). The fissure closes in the 4th-5th week of gestation (f). The early internal circulation of the eye is derived by the hyaloid artery, which is a branch from the ophthalmic artery (Fig. 36h); its branches penetrate the vitreous cavity to the posterior surface of the crystalline lens. The hyaloid vitreous, formed by the glial coat of the hyaloid artery, is gradually pushed inwards as the permanent vitreous develops, so that by birth it forms a narrow tube (Cloquet's canal). The hyaloid arterial system atrophies as the retinal circulation starts to appear, at about the eighth month of gestation.

In the third fetal month the ectoderm adjacent to the optic vesicle thickens, eventually invaginating to form the lens vesicle. Mesoderm then pushes between the ectoderm and the lens to produce the corneal stroma (Fig. 36g). In the fourth month of gestation, the mesenchyme of the rim of the optic cup forms the back of the iris, and the anterior chamber becomes apparent at the sixth month.

In the second month lid buds grow towards each other from the forehead and cheek, fusing in the

third month. The palpebral fissure does not reappear until the fifth month.

The nasolacrimal duct does not always canalize completely at birth, and its opening into the nasal cavity may still be obstructed by membranes, which, however, usually rupture spontaneously early in the postnatal period (see Chapter 2).

Identifiable rods and cones appear in the retina at about the sixth month of inter-uterine life.

Developmental abnormalities

Macrophthalmos: An eye may be larger than normal, but without other pathological findings; vision may be normal. Enlargement of an eye can also occur as a result of raised intra-ocular pressure (buphthalmos, Fig. 37e) and high myopia (Fig. 37d).

Microphthalmos: The eye is smaller than normal, usually the result of a developmental abnormality, e.g. following infection in utero (rubella), or due to chromosomal defects (trisomy 16/18), but can also be hereditary (Figs. 37a, 38a); vision is often severely impaired. The growth of the eye is normally completed by the fifth year of life. **Anophthalmos:** The absence of an eye (very rare). **Cryptophthalmos:** A rudimentary eyeball is present, but there are no eyelids. Other developmental abnormalities include orbital cysts (Fig. 38b) and **cyclopia**. The latter is the term used to denote a

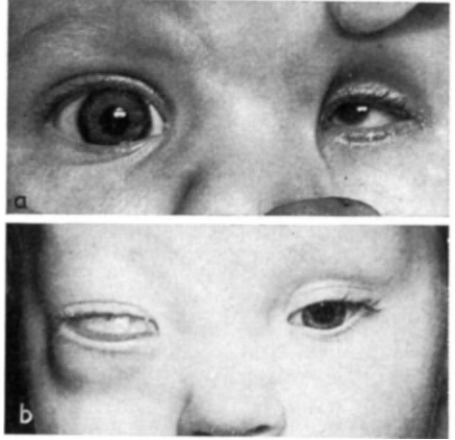


Fig. 38. a Microphthalmos (left); b orbital cyst

midline fusion of the ocular and orbital structures. Fetuses with this condition are non-viable, as it is associated with other severe defects of development.

Surgery

Removal of an eyeball may be necessary if, as the result of intra-ocular pathology, the eye becomes painful and sightless, or there is evidence of a neoplastic lesion which may

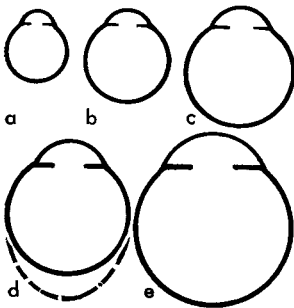


Fig. 37. Relative sizes of eyes: a microphthalmos; b size of the eye at birth; c eye of a 2-year-old child; d normal eye (----- myopic, i.e. elongated, eye); e buphthalmos (congenital glaucoma) (drawings approx. $\frac{2}{3}$ natural size)

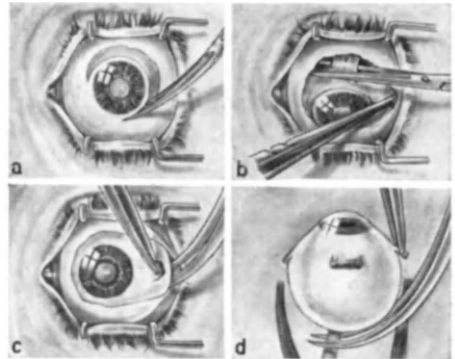


Fig. 39. Enucleation of the eye: a conjunctival incision at the corneal limbus; b cutting the four rectus muscles of the eye; c cutting the optic nerve using curved scissors; d as (c) drawn schematically

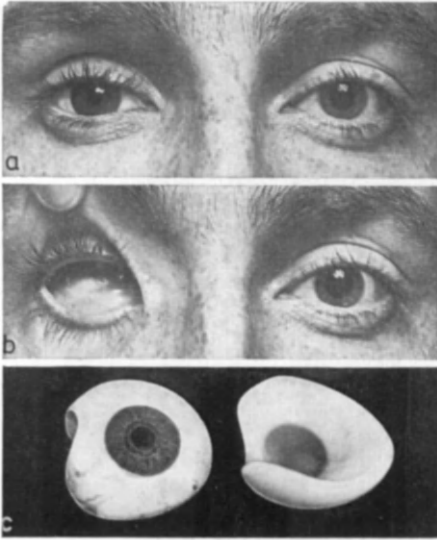


Fig. 40. Patient with (a) and without (b) ocular prosthesis; c ocular prosthesis viewed from the front and back

endanger life if it spreads outside the eye. The term **enucleation** means that the eyeball is removed leaving behind the orbital contents, including the extraocular muscles (Fig. 39). In patients where intra-ocular inflammation has occurred, destroying sight, and has caused perforation of the globe, **evisceration** may be performed. In this procedure the contents of the eyeball are removed, leaving behind the sclera. A shell-like prosthesis is fitted (Fig. 40) following both these operations. When enucleation is carried out in a young child growth of the bony orbit is retarded, and it is important that the prosthesis should be changed frequently and be of sufficient size in order to attempt to stimulate orbital growth. In cases where there is a highly malignant tumour of the orbit, or there has been extra-scleral extension of neoplastic lesions within the eye, **exenteration** of the orbital contents may be necessary (see Fig. 173). This disfiguring and mutilating procedure should only be performed if it will, in the opinion of the surgeon, significantly prolong the patient's life expectancy.

4. Conjunctiva

Anatomy

The tarsal conjunctiva is fused with the tarsus and can be easily inspected by everting the lids (see Fig. 3). The bulbar conjunctiva, only loosely attached to the underlying tissue (the sclera), except at the corneoscleral junction, is easily lifted up by oedema fluid (chemosis of the conjunctiva), or by haemor-

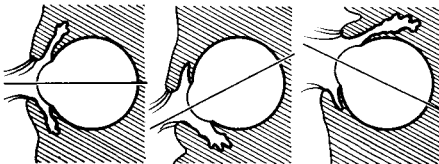


Fig. 41. Function of the fornices in extreme movements of the eye

rhages tracking between the sclera and the conjunctiva. Subconjunctival haemorrhages occur following trauma, excessive straining or coughing, or as a manifestation of blood dyscrasias. Emphysema of the bulbar conjunctiva also develops following a fracture of the ethmoidal bones.

In the superior and inferior fornices the conjunctiva is folded, so there is reserve tissue which permits extreme movements of the eye (Fig. 41). Located at the inner canthus is the plica semilunaris (the rudimentary third eyelid or palpebra tertius of some animals), and the lacrimal caruncle (a small flesh-like epidermoid structure, Fig. 42). The epithelium of the bulbar conjunctiva is composed of several layers of pavement epithelium, beneath which are aggregates of lymphoid tissue which become enlarged in response to inflammatory stimuli. The conjunctiva contains numerous goblet cells that are responsible for the secretion of mucus.

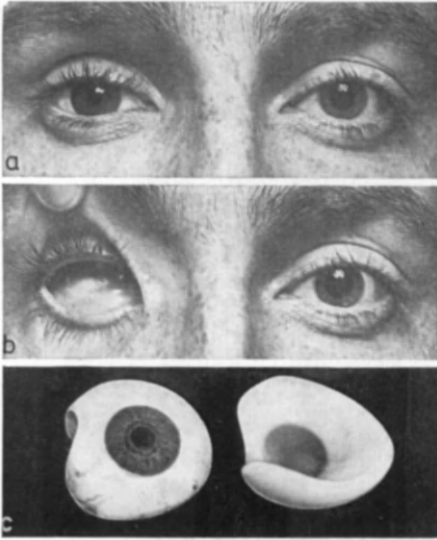


Fig. 40. Patient with (a) and without (b) ocular prosthesis; c ocular prosthesis viewed from the front and back

endanger life if it spreads outside the eye. The term **enucleation** means that the eyeball is removed leaving behind the orbital contents, including the extraocular muscles (Fig. 39). In patients where intra-ocular inflammation has occurred, destroying sight, and has caused perforation of the globe, **evisceration** may be performed. In this procedure the contents of the eyeball are removed, leaving behind the sclera. A shell-like prosthesis is fitted (Fig. 40) following both these operations. When enucleation is carried out in a young child growth of the bony orbit is retarded, and it is important that the prosthesis should be changed frequently and be of sufficient size in order to attempt to stimulate orbital growth. In cases where there is a highly malignant tumour of the orbit, or there has been extra-scleral extension of neoplastic lesions within the eye, **exenteration** of the orbital contents may be necessary (see Fig. 173). This disfiguring and mutilating procedure should only be performed if it will, in the opinion of the surgeon, significantly prolong the patient's life expectancy.

4. Conjunctiva

Anatomy

The tarsal conjunctiva is fused with the tarsus and can be easily inspected by everting the lids (see Fig. 3). The bulbar conjunctiva, only loosely attached to the underlying tissue (the sclera), except at the corneoscleral junction, is easily lifted up by oedema fluid (chemosis of the conjunctiva), or by haemor-

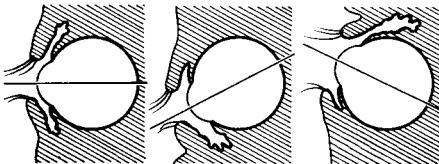


Fig. 41. Function of the fornices in extreme movements of the eye

rhages tracking between the sclera and the conjunctiva. Subconjunctival haemorrhages occur following trauma, excessive straining or coughing, or as a manifestation of blood dyscrasias. Emphysema of the bulbar conjunctiva also develops following a fracture of the ethmoidal bones.

In the superior and inferior fornices the conjunctiva is folded, so there is reserve tissue which permits extreme movements of the eye (Fig. 41). Located at the inner canthus is the plica semilunaris (the rudimentary third eyelid or palpebra tertius of some animals), and the lacrimal caruncle (a small flesh-like epidermoid structure, Fig. 42). The epithelium of the bulbar conjunctiva is composed of several layers of pavement epithelium, beneath which are aggregates of lymphoid tissue which become enlarged in response to inflammatory stimuli. The conjunctiva contains numerous goblet cells that are responsible for the secretion of mucus.

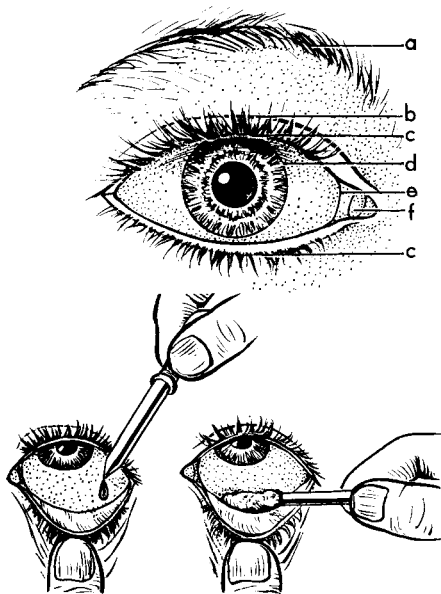


Fig. 42. Above: Anatomy of the inner canthus area. a eyebrow; b tarsal fold; c eyelashes; d corneal limbus; e plica semilunaris; f lacrimal caruncle. Below: Application of eyedrops and ointment

Acute conjunctivitis

Features include conjunctival vascular dilatation; the conjunctiva looks red (Figs. 43 a, 59 b); conjunctival oedema (chemosis) and small conjunctival haemorrhages may also be present (especially if the organism responsible for the inflammation is virulent); membranes are formed on the tarsal conjunctiva in the now rare diphtheritic conjunctivitis (Fig. 43 b). Slight swelling of the lids is sometimes present and the preauricular and submandibular lymph nodes may be enlarged. Secretions are purulent in bacterial infections, and watery mucoid or mucopurulent in viral diseases. After sleep the lids are often stuck together and there is difficulty in opening the eyes on waking. The patient complains of irritation, but not of ocular pain. There may be mild photophobia, but no loss of vision.

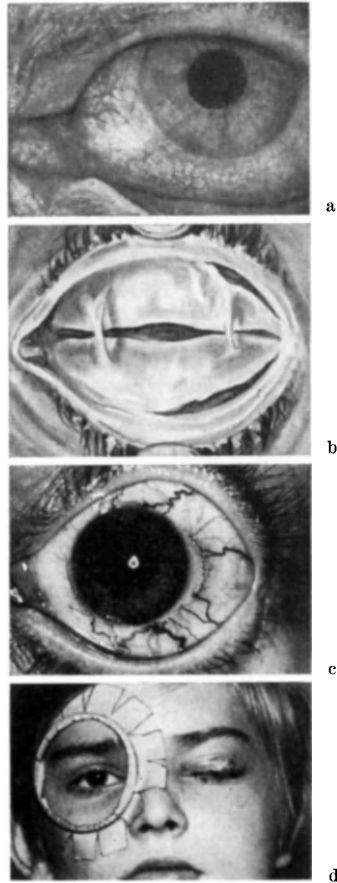


Fig. 43. a Acute conjunctivitis; b diphtheritic conjunctivitis; c congested conjunctival vessels in carotico-cavernous fistula; d Buller's shield

The prognosis in acute conjunctivitis is good, although marginal infiltration of the cornea, superficial punctate keratitis and definitive ulceration of the cornea occur as complications.

Aetiology: In cases with suspected bacterial conjunctivitis (Fig. 44) an epithelial smear can be made. Common pathogens include staphylococci, streptococci, pneumococci and, more rarely, Koch-Weeks bacilli. Non-pathogenic bacteria are also isolated on

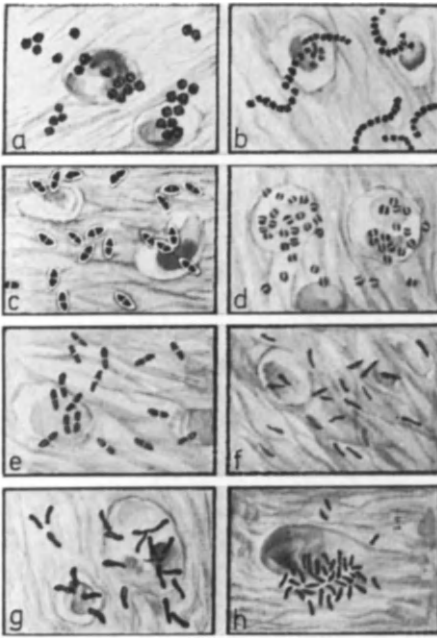


Fig. 44. Bacteria associated with infectious conjunctivitis: a staphylococci; b streptococci; c pneumococci; d gonococci; e Morax-Axenfeld diplobacilli; f Koch-Weeks bacilli; g diphtheria bacilli; h xerosis bacilli

occasions, such as diphtheroids or xerosis bacilli.

Viruses causing conjunctivitis include the Adenovirus group, including Type 8 (epi-

demio keratoconjunctivitis), herpes simplex, herpes zoster, measles, varicella and molluscum contagiosum.

Patients with suspected transmissible infective conjunctivitis should be given instructions concerning personal hygiene. There should be no family sharing of towels or toilet articles. Medical staff must wash their hands and clean all optical instruments after completing an examination of a case with conjunctivitis of infective origin. Conjunctival inflammation also occurs as a sensitivity response to eye ointments, e.g. atropine, and in atopic conditions (hay fever and asthma). Other causes of conjunctival inflammation include chemical and thermal burns and ultraviolet radiation.

Differential diagnosis: The blood vessels overlying the white sclera (Table 1) are injected in the following conditions: acute glaucoma, iridocyclitis, episcleritis and scleritis, and in cases with a caroticocavernous sinus fistula (Fig. 43 c).

Treatment: Bacterial infection should be treated by local application of broad spectrum antibiotics in the form of ointment or eye drops. No dressings are used, so as to allow a free flow of tears. Eye ointment must be applied directly from the tube, or by means of a glass rod, into the conjunctival sac with the lower lid pulled down. To instil eye drops the patient is asked to look up and the lower lid is pulled down (see Fig. 42) to make a receptacle for the eye drops. In allergic conjunctivitis the allergen should be isolated and withdrawn.

Table 1. Differential diagnosis between conjunctival and ciliary injection

	Conjunctival	Ciliary
Position and colour	Superficial injection. Vessels of the conjunctiva only are affected. Colour: bright or brick red	Deep injection. Vessels of the ciliary circulatory system are affected. Colour: blue-red
Localization	Whole conjunctiva, fading off in limbal region	Subconjunctival, pericorneal only
Mobility of vessels	Dilated vessels can be moved with the conjunctiva	Vessels cannot be moved with the conjunctiva

Individual forms of acute conjunctivitis

Gonococcal ophthalmia of the newborn: Infection, usually bilateral, takes place during birth, the eyes being infected as the head passes down the infected maternal birth canal, and conjunctivitis occurs from 1 to 4 days later. The lids are firm, swollen and stuck together by discharge. Purulent material builds up in the conjunctival sac and may spurt out when the lids are forced open, making it advisable for medical staff handling the baby to take extreme care to avoid being contaminated themselves. There is marked conjunctival chemosis.

Complications: Enzymes liberated by the inflammatory process and the pressure of the purulent material acting on the blood supply to the peripheral cornea may lead to corneal ulcers, abscesses, corneal perforation and panophthalmitis.

Gonococcal ophthalmia of the newborn used to be a common cause of blindness. Credé's prophylaxis (administration of 1 per cent silver nitrate drops immediately after birth) was effective and, until recently, demanded by law. In suspected cases of gonococcal ophthalmia in neonates, swabs must be taken in an attempt to isolate the organism as the disease is notifiable. **Treatment:** Penicillin drops are instilled into the conjunctival sac, initially every 5 minutes for 1 hour, subsequently hourly for 6 hours and then at 2 hourly intervals until the inflammation has subsided.

Gonococcal conjunctivitis in adults: The disease occurs through auto-inoculation or from a sexual partner. The incubation period is often only a few hours. **Treatment:** Immediate instillation of penicillin eyedrops is usually curative.

Epidemic keratoconjunctivitis is an infection which involves one or both eyes, and is caused by viruses of the adeno-pharyngo-conjunctival group. The disease is often spread by medical staff who treat infected individuals. Infection reaching epidemic proportions can be disseminated by inadequately sterilized ophthalmic instruments

coming into contact with the eyes. Medical and nursing staff responsible for the treatment of patients with epidemic keratoconjunctivitis must ensure that all proper hygienic precautions are observed. Insignificant breaches of the corneal epithelium (e.g. by foreign bodies, or as a result of tonometry) probably increase the likelihood of infection occurring. **Features:** There is initially acute hyperaemia of the conjunctiva and considerable chemosis, particularly of the plica semilunaris and caruncle, limited to one eye (see Fig. 112b). Lid swelling is present, and small conjunctival haemorrhages and watery or mucoid conjunctival secretions are frequently noted. The second eye is often affected a few days later. The patient experiences intense ocular irritation and photophobia, and work may be rendered impossible. The acute inflammation subsides in approximately 10–16 days, and with Adenovirus Type 8 infections, opacities sometimes appear beneath the corneal epithelium (see Fig. 63d). These frequently persist for 1 or 2 years, but vision is rarely impaired. **Treatment** is directed towards the symptoms, and is palliative rather than curative.

Trachoma (at the present time still the most frequent cause of blindness throughout the world). The disease can be divided into four stages:

First stage: A non-specific conjunctivitis and lymphoid hyperplasia develops.

Second stage: Characteristic formation of lymph follicles, particularly in the superior palpebral conjunctiva and fornix, with development of gelatinous granulations of unequal size. The trachomatous pannus (infiltration of the cornea with blood vessels) starts superiorly (Figs. 45b, 58c), and then spreads over the cornea from all sides.

Third stage: Conjunctival fibrosis occurs (Fig. 45a).

Fourth stage: The scars gradually curve the lower tarsus margin inwards, giving rise to cicatricial entropion and trichiasis (rubbing of the lashes against the cornea). There is often a trachomatous

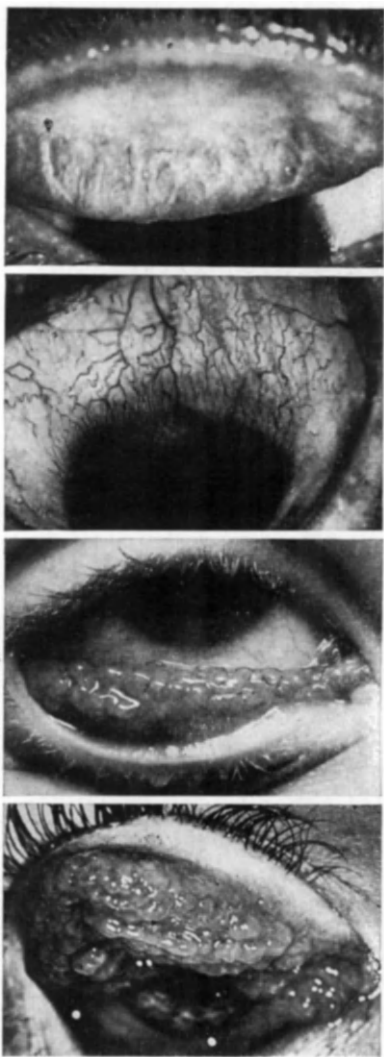

Fig. 45. a Scarring of tarsal conjunctiva following trachoma; b trachomatous pannus; c inclusion conjunctivitis; d swimming-pool conjunctivitis

ptosis due to thickening of the tissues of the upper lid. In the late stage decreased lacrimal secretion causes conjunctival drying.

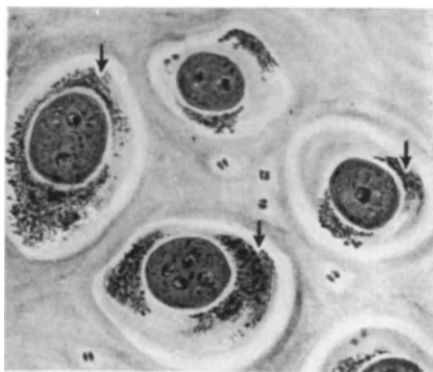

Fig. 46. Inclusion bodies in trachoma

Aetiology: This is a chlamydial disease. Halberstadt-Prowazek inclusion bodies are to be seen in cells obtained by scraping (Fig. 46), as is the case with paratrachomatous conjunctivitis (inclusion blennorrhoea of the newborn and swimming pool conjunctivitis). The virus is spread by means of washing water, flies, shared cosmetics, etc. Trachoma occurs most commonly in arid areas in the Middle East, Africa and South-East Asia. **Treatment:** Tetracycline or similar broad spectrum antibiotic eye ointment. Surgery is necessary if there is malposition of the lids and rubbing of the eyelashes against the cornea. Preventive treatment includes instructing communities in personal hygiene, ensuring adequate water supplies for washing and control of flies, for example, by positioning refuse tips away from human habitation.

Inclusion blennorrhoea (inclusion conjunctivitis) (Fig. 45c): The infection is caused by a TRIC organism and the initial symptoms closely resemble those of gonorrhoeal ophthalmitis. However, the incubation period is some 5-10 days, and although the duration of the infection may be prolonged, lasting several weeks, the prognosis is good as there are virtually no complications. Identical viruses cause swimming pool conjunctivitis and trachoma inclusion conjunctivitis in adults, which is usually a sexually transmitted disease. The TRIC viruses bear

a close resemblance to the organism responsible for trachoma (Fig. 46). **Treatment:** Chloromycetin ointment is effective.

Swimming pool conjunctivitis presents as a conjunctivitis with numerous non-erupting follicles of equal size (Fig. 45d). Moderate mucoid discharge and inclusion bodies are found in conjunctival epithelial scrapes. There may be some degree of malaise, and, as the name implies, the disease is obtained from contaminated swimming pools. Chlorination prevents the spread of the disease.

Chronic conjunctivitis

Chronic forms of conjunctivitis may be of infectious or non-infectious origin, or begin as an acute form and become chronic later.

Chronic (catarrhal) conjunctivitis: There is mild conjunctival injection, frequently associated with blepharitis. Slight enlargement of the conjunctival follicles is often seen and moderate secretion detected, so that the eyelids are stuck together on waking. The patient complains of a foreign body sensation, with itching and burning of the lids. **Aetiology:** Exogenous thermal or chemical irritation, e.g. dust, wind, smoke, cold or dry air, ultraviolet radiation, chronic staphylococcal infection, and allergies. **Treatment:** Astringent eyedrops, local antibiotics or, if an allergic or hypersensitive element is thought to exist, topical steroid therapy. **Note:** Prolonged use of topical steroids in the treatment of conjunctivitis may cause a rise of intra-ocular pressure or predispose to the development of herpes simplex or fungal keratitis. Preparations containing local steroids should not be instilled unless medical staff have ready access to slit lamps for corneal inspection and are able to carry out accurate measurements of the intra-ocular pressure.

Vernal conjunctivitis (Spring catarrh), which, in spite of its name, may occur at any time of the year, but is often worse in the spring and summer months. A milky conjunctival pseudomembrane may be present. Secretions are mucoid and tenuous.

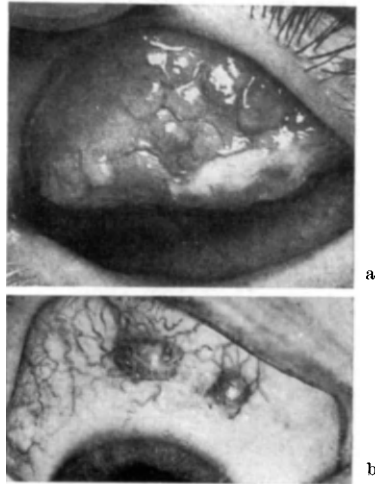


Fig. 47. a Vernal conjunctivitis (spring catarrh); b conjunctival phlyctenules

There are large cobblestone papillae in the palpebral conjunctiva (Fig. 47a), and similar changes may be noted at the limbus. Conjunctival scrapings may reveal the presence of eosinophils. The patient, usually in the younger age group, complains of ocular irritation and itching. Eversion of the upper lid shows the characteristic appearances of this disease. **Aetiology:** Unknown, but is thought to be a manifestation of atopic disease. **Treatment** should be directed towards relieving the symptoms, since cure cannot be obtained. Local astringent eye medication or steroid therapy is often useful in relieving symptoms. The overall prognosis is good. **Complication:** Ulceration of the upper part of the cornea.

Phlyctenular keratoconjunctivitis occurs mainly in young undernourished children living in poor conditions. **Features:** Individual phlyctenules (yellowish-white sub-epithelial nodules, Fig. 47b) or multiple grain of sand phlyctenules are seen in the corneolimbal area and give rise to marginal corneal ulceration. Symptoms include pronounced photophobia and blepharospasm; recurrences are common and scrofulous

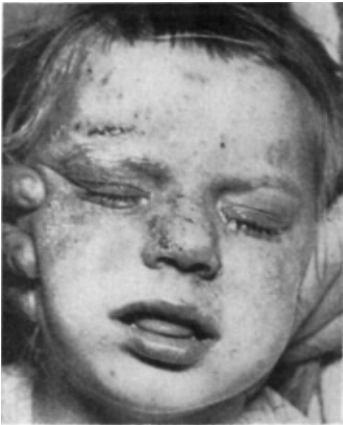
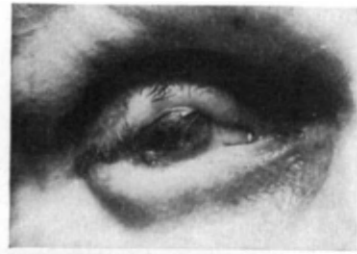
Fig. 48. Facial eczema with marked photophobia in scrofulosis

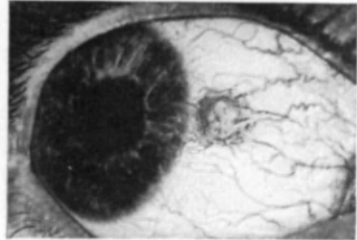
facial eczema is often a feature (Fig. 48). **Aetiology:** Unknown, but it is possibly a hypersensitivity reaction to bacterial toxins. **Treatment:** Local antibiotics, including sulphonamides, or cortico-steroids may be helpful. An improvement in general health and, if possible, in living conditions should be sought.

Less common conjunctival diseases

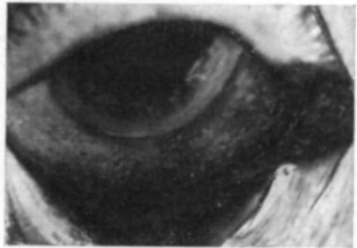
Mucocutaneous shrinkage syndromes (Fig. 49a), i.e. ocular pemphigoid, Stevens-Johnson syndrome. These conditions are characterized by a gradual shrinkage of the bulbar conjunctiva, so that the fornices become obliterated. Subconjunctival scarring leads to reduced lacrimal secretion, and thence to drying of the cornea (*keratitis sicca*). The cornea is therefore more susceptible to infections, and ulceration frequently occurs. **Treatment:** Attempts to arrest the conjunctival shrinkage are rarely effective, although topical steroids, mucous membrane grafts and the insertion of large contact lenses have all been tried. The condition is progressive and the prognosis for sight is poor. **Aetiology:** Unknown. It has been suggested that in certain cases a hypersensitivity reaction to certain drugs exists (Stevens-Johnson syndrome). A similar condition may be produced following the systemic use of certain beta-blocking agents for the treatment of systemic vascular hypertension.



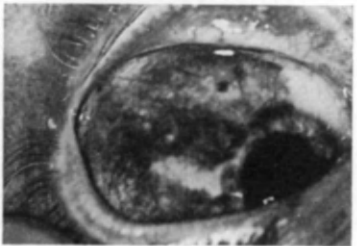
a



b



c



d

Fig. 49. a Conjunctival pemphigoid; b pinguecula; c an extreme case of conjunctival argyrosis; d conjunctival melanosis

Degenerative diseases

Pingueculae are yellowish hyaline deposits on the conjunctiva in the palpebral area, and appear most commonly in older patients who had have prolonged exposure to

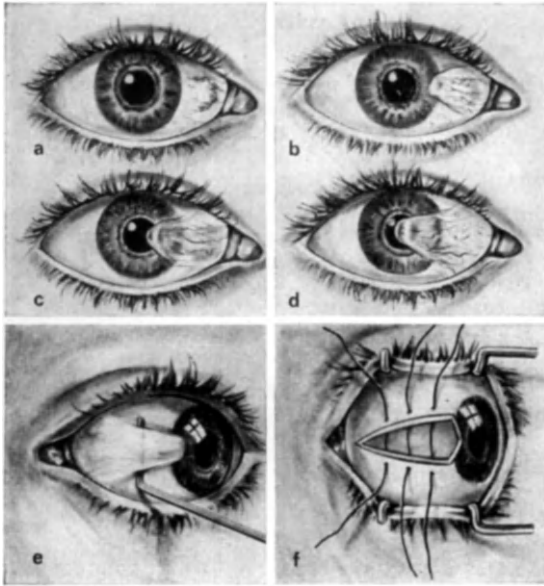


Fig. 50. Growth stages of pterygium: a initial stage; b encroachment on limbus; c pupillary area has been affected and vision reduced; d growth into central pupillary area, vision greatly impaired; e-f surgical method of removing a pterygium

outdoor conditions (Fig. 49b). The condition does not progress, and no treatment is required.

Pterygium: A leash of vessels arising in the conjunctiva which encroach on the cornea, usually from the nasal side, with a gelatinous tip, and eventually progress over the cornea on the pupillary area, thus affecting vision (Fig. 50). **Aetiology:** Uncertain, though exposure to actinic light for prolonged periods may be an important factor. If the pterygium shows evidence of enlargement, surgical removal, including superficial keratectomy, is indicated (Fig. 50e-f). Following burns or injuries to the conjunctiva or cornea pseudo- or cicatricial pterygium may occur.

Calcareous deposits often develop in the tarsal conjunctivae of older patients, owing to a blockage of secretions from conjunctival glands. These deposits erode through the conjunctiva and may give rise to a foreign body sensation. The calcareous material is easily removed by scraping the conjunctiva with the tip of a surgical blade. **Xerosis of the conjunctiva (vitamin A defi-**

ciency): Whitish foamy patches (Bitot's spots) appear in the palpebral aperture. The conjunctiva is dry and dull and has reduced sensitivity. Xerosis bacilli (see Fig. 44h) are frequently present. If the condition is severe keratomalacia develops (softening of the cornea). Other complications include secondary infection, corneal staphylococcal infection, and corneal perforation. Night blindness is an important early symptom. **Treatment:** Medication with large doses of vitamin A, taken orally, is curative. Topical antibiotics may be necessary to clear any secondary infection.

Pigmentation of the conjunctiva: Argyrosis of the conjunctiva is characterized by the presence of brownish-black silver salt deposits, due to the prolonged use of eye drops containing silver (Fig. 49c). Black discrete pigmentation of the conjunctiva occurs following the use of epinephrine drops, for example, in glaucoma, and pigmentation is also a frequent feature of Addison's disease. Conjunctival pigment deposits may also be noted in women following the over-enthusiastic use of eyelid cosmetics, and

in patients exposed to explosions, where dust particles become embedded in the conjunctiva.

Tumours

Naevus: A benign, slightly raised, brownish mobile tumour of the conjunctiva (Fig. 51a), or caruncle. Pigmentation may be widespread (Fig. 49d), producing melanosis of the conjunctiva. **Differential diagnosis:** Malignant melanoma; foreign body. Naevi should be examined periodically for malignant change, which is characterized by spread of the pigmented areas, elevation of the tumour and increased vascularity. Photographs or topographic sketches are useful to provide an accurate record.

Dermoids: These are congenital yellowish-white tumours varying from the size of a lentil to that of a pea. They are usually located at the corneal limbus area (Fig. 51c) and consists of epithelial cells, hairs and sebaceous and fatty tissue. Dermolipomas consist of fat only (Fig. 51b). Surgery is often required as these tumours are cosmetically disfiguring.

Other benign tumours include haemangiomas, inclusion cysts (Fig. 51d-e), papillomas and lymphangiomas.

Malignant tumours: **Squamous carcinoma:** A pale, fleshy, elevated tumour which gradually encroaches on the cornea. **Malignant melanoma** (Fig. 51f). **Treatment:** If the tumour is small, complete surgical removal is often curative; if large, radiotherapy may be used.

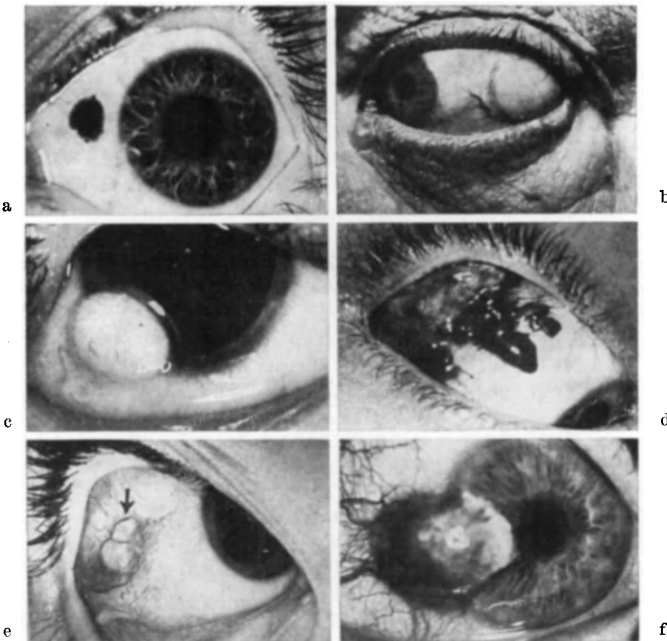


Fig. 51. a Conjunctival naevus; b dermolipoma; c dermoid on corneal limbus; d vascular tumour; e conjunctival cyst; f malignant melanoma of the conjunctiva invading the cornea

5. Cornea

General considerations

The diameter of the cornea is approximately 11.5 mm (a range of 10–13 mm in adults, 8–10 mm at birth). The average radius of curvature is 7.7 mm, and the refractive power about 44 dioptres. Its apical thickness is 0.8 mm, and at the periphery 1 mm. The vascular network at the corneal limbus supplies nutrients to the cornea by means of diffusion, but the corneal metabolism is also supported by the tears and aqueous humour. The layers of the cornea from the external to the internal surface are shown in Fig. 52 above. The corneal stroma consists of regularly orientated collagen fibrils embedded in a mucopolysaccharide matrix, which is maintained in a dehydrated state by the activity of the corneal endothelium. Hydration of the cornea causes transparency to be lost because the regular orientation of the collagen fibrils becomes disturbed.

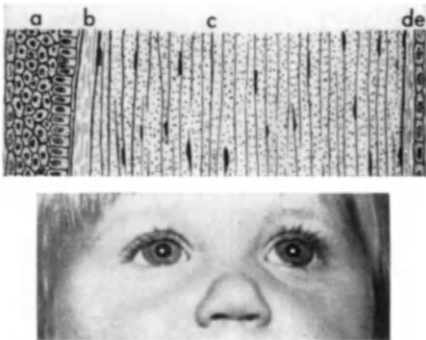


Fig. 52. Above: Layers of the cornea: a epithelium; b anterior limiting lamina (Bowman's membrane); c corneal stroma with lamellae and corneal corpuscles (forms 9/10 of the thickness of the cornea); d posterior elastic lamina (Descemet's membrane); e endothelium (single cell layer). Below: Megalocornea

Abnormalities in the size of the cornea

Megalocornea: The corneal diameter in this condition is over 13 mm. It is a congenital abnormality, usually with no other pathological consequences (Fig. 52 below), and may be associated with megalophthalmos. **Differential diagnosis:** Buphthalmos (congenital glaucoma).

Microcornea denotes a corneal diameter of less than 10 mm in an adult and is a congenital, often hereditary, abnormality, which may be unilateral or bilateral; usually associated with microphthalmos and impaired visual acuity.

Examination procedures

The corneal curvature is evaluated by means of a Placido's disc (keratoscope, Figs. 54, 55), and the surface can also be assessed by observing the reflected image of a cross-bar (window frame) on the cornea (Fig. 56).

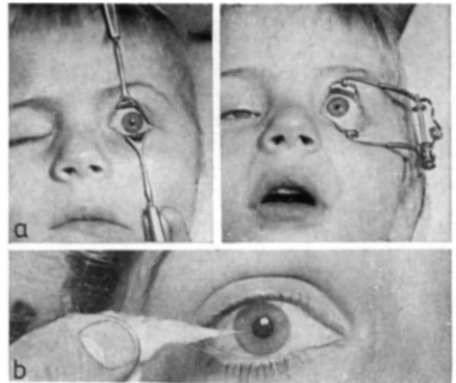


Fig. 53. a Examination of cornea under local anaesthesia: left with Desmarre's blepharostat; right with lid retractors; b testing corneal sensitivity with pulled-out piece of cottonwool




Fig. 54

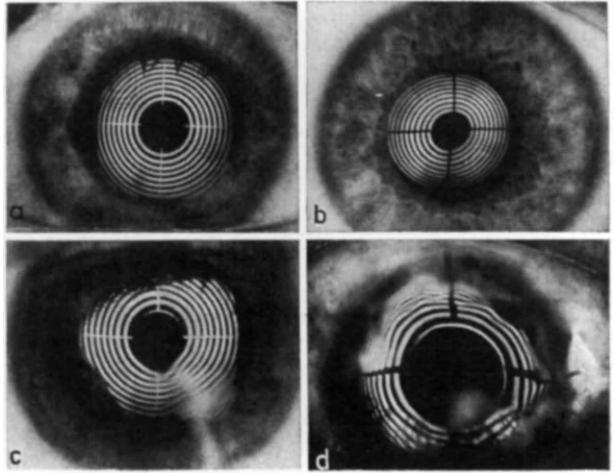


Fig. 55

Fig. 54. Keratoscope (Placido's disc)

Fig. 55. Reflected images using a keratoscope: a normal curvature; b regular corneal astigmatism; c effect of scar at 5 o'clock; d scarring of cornea with severe irregular astigmatism

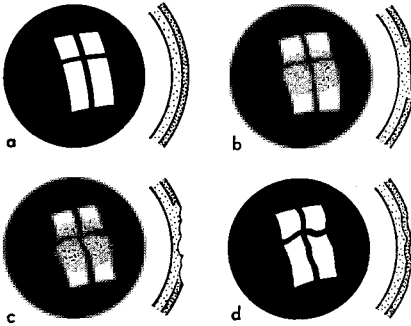


Fig. 56. Reflected images of cross-bar (window-frame) on the cornea: a normal cornea; b dull and lustreless due to defective epithelium; c lustreless and distorted due to defective corneal stroma; d distorted and shiny due to defect covered by new epithelium

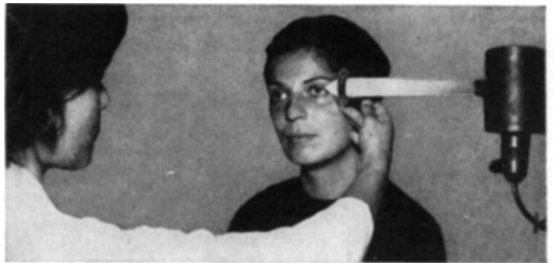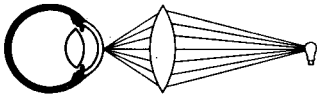


Fig. 57. Examination by means of focal illumination

Examination, carried out by transmitted light with an ophthalmoscope, allows the observer to visualize corneal opacities as spots against the red pupillary reflex. Using a 12–20 dioptre convex lens (loupe) and a strong oblique focal illumination (Fig. 57), not only may opacities, epithelial defects, etc., be more easily distinguished, but also the iris and lens be observed. The slit lamp provides the best method of examining the cornea and permits the exact site and extent of any lesion within the cornea to be identified. Epithelial defects (erosions) (see Fig. 58) stain greenish-yellow when 2 per cent fluorescein dye is applied (Fig. 64a). Corneal sensation is tested with a piece of cottonwool pulled out to a point, and a comparison made with the healthy eye (Fig. 53b). If there is blepharospasm as a result of corneal disease, or the cornea has to be touched, local anaesthetics should be instilled into the conjunctival sac, e.g. amethocaine 1 per cent. Cocaine drops should only be used for operative procedures, since the corneal epithelium may be

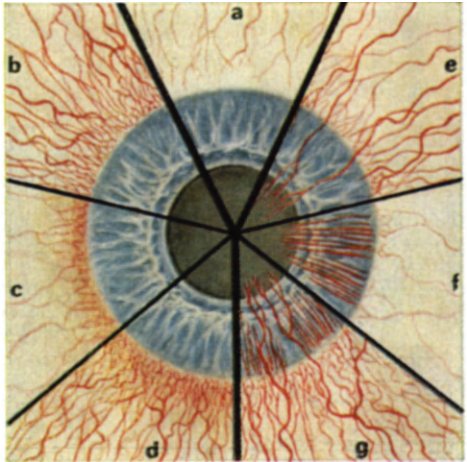


Fig. 59. Conjunctival and ciliary injection: a normal appearance; b conjunctival injection with bright red, movable blood vessels due to pathology of the conjunctiva; c deep ciliary injection with diffuse dull red colouring in area of limbal vessels due to iridocyclitis; d mixed (conjunctival and ciliary) injection in case of superficial and deeper pathology; e superficial corneal vascularization (the conjunctival blood vessels extend in a branch formation over the cornea); f deep corneal vascularization (the blood vessels grow like a birch-broom out of the ciliary circulatory system from the limbus into the deep layers of the cornea); g mixed (superficial and deep) corneal vascularization

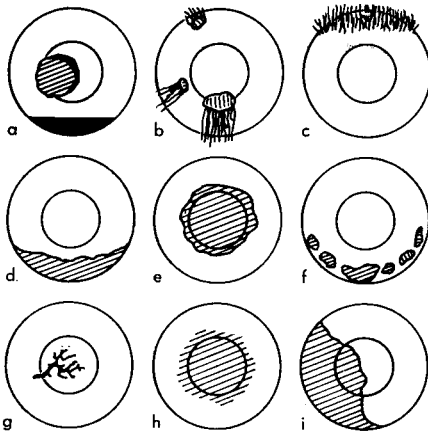


Fig. 58. Topography of corneal diseases: a serpiginous ulcer; b rosacea keratitis; c trachomatous pannus (corneal vascularization) d ulcer following lagophthalmus; e neuroparalytic keratitis; f marginal ulcers; g dendritic keratitis; h disciform keratitis; i sclerosing keratitis

damaged by this agent. **Anaesthetic agents should never be given to a patient to take away from the hospital, as unsupervised use can mask further pathology.**

Corneal examination is often difficult in small children where there is blepharospasm. However, the cornea is readily made accessible to inspection after pulling back the lid by means of retractors, following the instillation of a local anaesthetic (Fig. 53a).

Vascularization of the cornea is always a sign of underlying pathology (Fig. 59e–g). **Superficial vascularization** indicates damage to the more external layers of the cornea, when the conjunctival vessels encroach on the cornea. **Deep vascularization** occurs in processes involving the inner layers of

the corneal stroma. Such vessels are derived from the ciliary circulatory network at the limbus. Mixed vascularization is a combination of both these forms.

Bacterial and mycotic diseases

The first indication of corneal infection is lack of lustre of the corneal reflex due to oedema and cellular infiltration; subsequently, a corneal ulcer with loss of the corneal stroma develops. The body's own defence mechanism, plus timely medical treatment, generally results in healing of the ulcer (Fig. 56). However, corneal scarring and vascularization are often permanent sequelae. If the infection is virulent and treatment is delayed a serpiginous (spreading) ulcer may develop.

Bacterial infections

Features of a serpiginous corneal ulcer: A rapidly progressing corneal ulcer, usually central or paracentral in location, with a yellowish infiltrated background.

Additional features include:

Progressive loss of corneal substance (Figs. 60 a–b, 61 a).

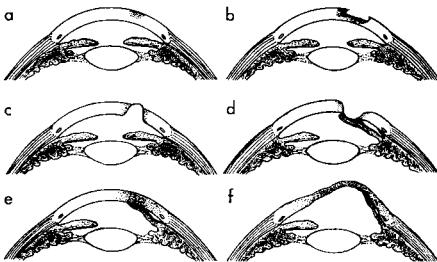


Fig. 60. Stages of progression of serpiginous corneal ulcer: a corneal infiltration; b ulcer with its edge progressing to the left; c bulging of Descemet's membrane shortly before perforation; d closing of the perforation by the iris; e anterior synechiae; f corneal staphyloma

Ciliary or conjunctival injection (Fig. 59b). Fibrinogen and cells appearing in the anterior chamber as a result of toxins diffusing from the cornea.

Keratic precipitates (accumulation of aggregates of leucocytes on the interior surface of the cornea, see Fig. 91).

More rarely, hypopyon (development of pus, initially in the lower half of the anterior chamber, see Figs. 58a, 61b, 62b).

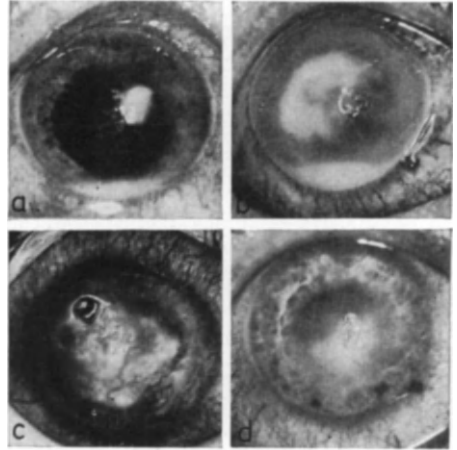


Fig. 61. a Initial stage of serpiginous ulcer; b advanced serpiginous ulcer with hypopyon; c corneal ulcer with hernia-like bulging of Descemet's membrane at 11 o'clock; d scar following healing of corneal ulcer

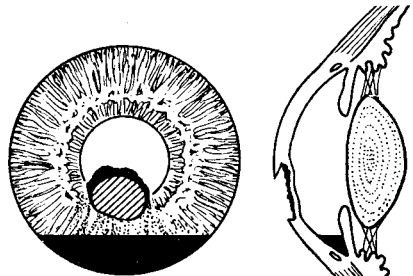


Fig. 62. Serpiginous ulcer with hypopyon, front view and cross-section

Posterior synechiae (adhesions between the pupil margin and the anterior capsule lens) forming as a result of the inflammatory process in the anterior chamber (see Fig. 90 c-d and Chapter 8).

If the pathogenic organisms are extremely virulent, or medical treatment is delayed, the ulcer deepens and corneal perforation occurs. Before this happens, a hernia-like bulging of the elastic Descemet's membrane (keratocele) forms (Figs. 60c, 61e). Following corneal perforation, aqueous humour escapes from the anterior chamber, with shallowing of this space and prolapse of the iris into the defect (Fig. 60d). Because the intra-ocular contents are now directly open to invasion by pathogenic organisms, panophthalmitis becomes a possibility. Permanent corneal scarring occurs when a corneal ulcer heals. If corneal stromal damage has been mild, opacities are superficial and cloud- or spot-like (Fig. 63 a-b).

With more severe infections the opacities are denser (Figs. 61 d, 63 c). In cases where corneal perforation has occurred and the defect subsequently healed, anterior synechiae (adhesions between the back of the cornea and the iris) are often present (Fig. 60e). Severe corneal infections can also lead to

marked corneal thinning → partial or total staphylomas (Figs. 60f, 67a).

Aetiology: Bacteria commonly causing corneal ulcers include pneumococci, streptococci, staphylococci, pseudomonas and proteus organisms. **Treatment:** Topical broad spectrum antibiotics should be instilled at regular intervals. Atropine 1 per cent is used to dilate the pupil to combat accompanying iritis. If there is a likelihood of perforation, after infection has been brought under control keratoplasty may be necessary as an emergency procedure (see Fig. 70). Panophthalmitis (generalized intra-ocular infection) which does not respond to medical therapy (high doses of topical and systemic broad spectrum antibiotics) may require removal of the eye, since the intra-ocular contents are readily destroyed by the presence of bacteria within the eye itself.

Keratomycosis (fungal keratitis) is rarely seen in temperate climates, but should be suspected in people coming from tropical areas, or in cases where the ulcer fails to respond to the treatment outlined. Round, yellowish infiltrations appear in the cornea, usually in the central region (Fig. 63e). Corneal scrapings should be taken in cases of suspected keratomycosis and examined

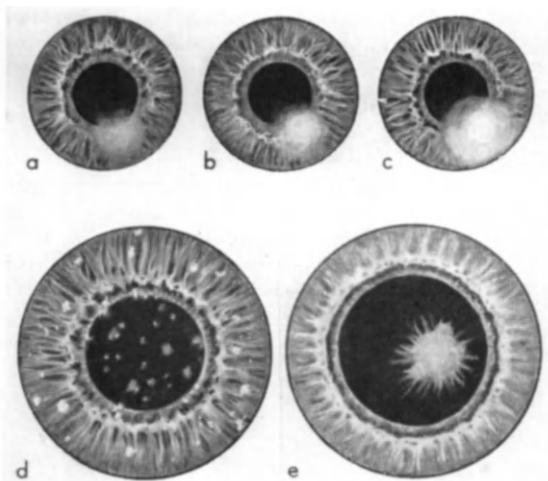


Fig. 63. Above: Corneal scars of increasing density. a nebula; b macula; c leucoma. Below: d Opacities following Adenovirus Type 8 keratoconjunctivitis e keratomycosis

for fungal elements. There is gradual shedding of the affected corneal parenchyma with scar formation, and perforation and panophthalmitis may occur. Keratomycosis is more likely to develop in patients who have been using local corticosteroids for a long period of time. **Treatment:** Eye drops containing antimycotic agents (Amphotericin B) should be instilled at regular intervals. Steroid preparations are contraindicated.

Viral diseases

Herpes simplex keratitis: This is probably the most serious disease of the outer eye in the Western world. Initially, small vesicles appear in the corneal epithelium that rupture within a short space of time and form small ulcers which unite to produce a typical dendritic or branch-shaped pattern (Fig. 58g). The ulcer stains green with fluorescein dye (Fig. 64a). There is often ciliary injection, and corneal sensitivity is reduced. Ul-

cers usually clear up in 1 or 2 weeks, leaving faint superficial corneal scarring. The patient complains of deteriorating vision, redness of the eye but only mild ocular irritation, though photophobia and lacrimation are often prominent features. The inflammation may, however, progress to involve the corneal parenchyma, resulting in opacification and vascularization (disciform keratitis, Fig. 58h). The cornea becomes oedematous and therefore thickened, and evidence of inflammatory changes in the anterior chamber are frequently noted on slit lamp examination. Visual acuity is severely impaired, and unless active treatment is instituted early on, visual function will be permanently reduced. Patients who have developed herpes simplex keratitis frequently suffer from recurrences, so that corneal scarring and vascularization are often progressive. **Treatment:** The virus may be eliminated by painting the ulcer margins with phenol solution under slit lamp control. Alternatively, 5-iodo-2'-deoxyuridine (IDU) ointment five times a day or one of the newer antiviral agents is prescribed. These preparations block the formation of DNA by denying nucleotides to the virus particles for replication. In the presence of an active disciform keratitis, weak solutions of topical steroids may be employed, but only if covered by adequate antiviral therapy, in an attempt to reduce the inflammatory process and subsequent corneal scarring. In patients who have developed dense corneal scars, sight will only be restored by performing a keratoplasty.

The use of cortico-steroids alone in patients who develop herpes simplex keratitis is contraindicated, as they enhance virus reduplication; herpetic ulcers become geographical in distribution → corneal liquefaction → corneal perforation.

Herpes zoster ophthalmicus keratitis: Vesicles develop in the corneal epithelium which rupture and produce punctate epithelial erosions. Corneal sensitivity is reduced. Disciform keratitis occasionally develops later. For other complications see

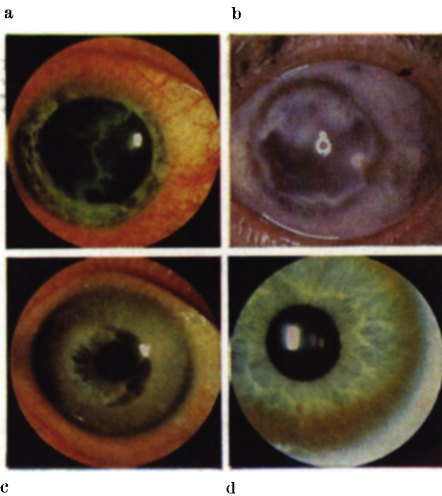


Fig. 64. a Dendritic keratitis; b sclerosing keratitis (viewed in blue light); c corneal graft in a case with corneal dystrophy; d Kayser-Fleischer ring in Wilson's disease

Chapter 1. **Treatment:** Topical mydriatics and corticosteroids to combat the anterior uveitis, and antibiotic eye ointment to prevent any secondary infection.

Epidemic keratoconjunctivitis (see Chapter 4): In some cases small snowflake-like opacities form during the later stages of the disease and may remain present in the cornea for several years (Fig. 63d).

Endogenous diseases

Interstitial keratitis due to congenital syphilis: Occurs mainly in children aged from 5 to 15 years; the course is protracted. Both

eyes are affected, but not usually at the same time or to the same degree.

The stages of the disease are as follows:

First stage: Opacification of the corneal parenchyma starting from the limbus, with ciliary injection, photophobia and mild iridocyclitis.

Second stage: Deep vascularization of the cornea develops, giving it a pinkish-red tinge (salmon patch).

Third stage: There is partial clearing of the opacities, leaving slight (sometimes more severe) deeply situated feather-like corneal scars, which persist throughout life, containing obliterated ghost vessels. Vision is moderately or severely impaired.

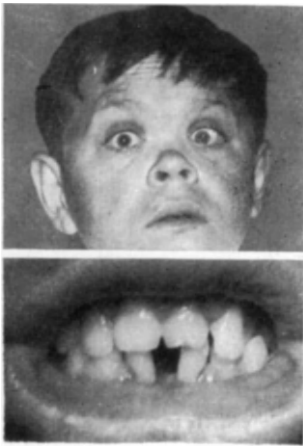


Fig. 65. Saddle-nose and Hutchinson's teeth in congenital syphilis

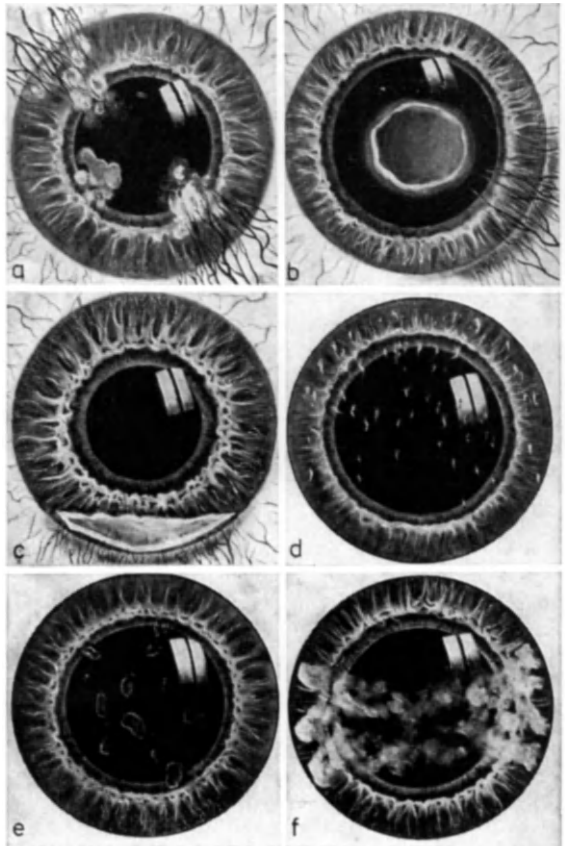


Fig. 66. a Phlyctenular keratoconjunctivitis with old vascularized scars; b neuroparalytic keratitis; c keratitis and lagophthalmos; d filamentary keratitis; e bullous keratopathy; f band-shaped keratopathy

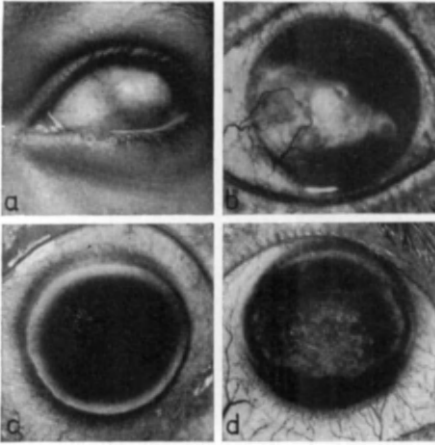


Fig. 67. a Corneal staphyloma; b rosacea keratitis; c arcus senilis; d corneal dystrophy (hereditary)

Aetiology: A late manifestation of congenital syphilis; one of the signs of Hutchinson's triad, together with notched upper incisors (Fig. 65) and inner ear deafness. In addition, the patient may have rhagades at the corner of the mouth, saddle nose and periostitis affecting the tibia. **Treatment:** In the acute phase, local corticosteroids, 1 per cent atropine eye ointment, heat and dark glasses if photophobia is present. If there is severe subsequent scarring, keratoplasty may eventually have to be performed. Interstitial keratitis can also occur in tuberculosis and leprosy.

Phlyctenular keratoconjunctivitis (cf. phlyctenular conjunctivitis, Chapter 4): There is superficial and sometimes deep corneal infiltration, and occasionally pannus-like vascularization develops (Fig. 66a). Complications include corneal ulceration, keratocele, corneal perforation and staphyloma formation (Fig. 67a).

Rosacea keratitis: The patient complains, along with acne rosacea and, occasionally, rhinophyma, of irritation, photophobia and conjunctival injection. Marginal corneal infiltration and ulceration develop (Fig. 58 b), and later the affected areas become vascularized and scarred (Fig. 67 b).

In severe cases calcareous infiltration occurs. Recurrence is frequent and in more severe cases the cornea may perforate.

Treatment: The use of topical corticosteroids or systemic tetracyclines arrests the condition.

Marginal ulceration of the cornea: Crescent-shaped infiltration and ulcers develop in the limbal area (Fig. 58 f). **Aetiology:** Unknown, but it is thought to be a combination of allergic and bacterial toxins acting on the peripheral cornea, possibly leading to an endarteritis of the limbal vessels. Although no systemic disease is found in the majority of patients, it is quite a common presenting feature of collagen disorders.

Treatment: Antibiotic eye ointment and, if necessary, steroids.

Recurrent corneal erosions: The patient complains of a foreign body sensation on waking, accompanied by marked blepharospasm and photophobia. On slit lamp examination soon after the event, an area of epithelial loss is noted. However, the defect soon disappears as new epithelium slides over the area. Patients developing recurrent corneal erosions frequently give a history of previous traumatic corneal abrasions. It seems that the epithelium forms an insufficiently strong bond with Bowman's membrane so that it is easily lifted off when the eyes are opened on waking. **Treatment:** The cornea should be debrided of the defective epithelium. Eye ointment is instilled every night to act as a lubricant.

Neurotrophic diseases

Neuroparalytic keratitis occurs as a result of lesions of the trigeminal nerve, more particularly at the level of the gasserian ganglion, caused by trauma, including surgery, tumours, etc. Corneal sensitivity is reduced unilaterally, the corneal epithelium becomes stippled and oedematous and central opacities appear in the parenchyma (Fig. 58 e). Later, sharply circumscribed corneal ulceration develops (Fig. 66 b). The con-

junctiva is slightly injected, but there is no pain. Thus, usually the patient does not complain of symptoms except defective vision. Unless treatment is instituted promptly the cornea undergoes liquefaction, a keratocele develops and perforation and secondary infection may ensue. **Treatment:** Tarsorrhaphy (sewing together of the lid margins to ensure continuous corneal protection). Antibiotic eye ointments are instilled to prevent secondary infection.

Keratitis e lagophthalmo: Inadequate closure of the lids (e.g. as a result of facial paralysis). The cornea becomes desiccated, especially in the lower half, as it is this area which is exposed during sleep, the eye normally rotating upwards (Bell's phenomenon). Ulceration may rapidly develop in the lower half of the cornea (Figs. 58d, 66c). **Treatment:** Tarsorrhaphy. As immediate preventive therapy a Buller's shield may be placed over the eye (see Fig. 43d), so that the air in contact with the cornea remains fully saturated with water vapour. Local antibiotics should be instilled to prevent secondary infection.

Filamentary keratitis occurs when lacrimal secretion is inadequate (**keratoconjunctivitis sicca**). Tear secretion is mucoid and sticky. This pulls off long filaments of corneal epithelium (Fig. 66d) that stain bright red when Rose Bengal is instilled into the conjunctival sac. Such changes occur in Sjögren's syndrome (see Chapter 2). **Treatment:** Instillation of artificial tears, occlusion of the puncta or the use of hydrophilic contact lenses.

Degenerative conditions

Arcus senilis occurs in the older age groups. Lipids are deposited in the form of a narrow, whitish-yellow ring separated by a defined clear area between it and the marginal zone of the corneoscleral junction (Fig. 67c). No treatment or investigations are necessary. Similar changes develop in younger patients suffering from hyperlipidemia, and any individual with arcus juvenilis

should be investigated from this point of view, as they are liable to develop cystoid vascular disease at an early age unless the lipid disturbances are promptly controlled.

Band-shaped keratopathy (Fig. 66f) occurs as a consequence of long-standing intra-ocular disease (glaucoma, iridocyclitis, trauma and retinal detachment). In children it is a feature of Still's disease (infantile rheumatoid arthritis). Band-shaped keratopathy may also occur in conditions which give rise to a raised serum calcium level, e.g. sarcoidosis, the milk-alkali syndrome, hyperparathyroidism and hypervitaminosis D. Calcium is laid down in Bowman's membrane in the palpebral area, starting at the peripheral part of the cornea, but merging to form a horizontal rectangular area of opacification. Calcium may erode through the corneal epithelium, causing pain, photophobia and lacrimation. **Treatment:** Treat the primary cause and remove calcium with topically applied chelating agents.

Stähli's line is a horizontal line of iron pigmentation noted in old people, running across the lower half of the cornea. No treatment is required and vision remains unimpaired.

Fatty degeneration of the cornea: Lipids are deposited in a damaged cornea following chemical burns, mustard gas keratitis, etc.

Corneal dystrophies

Keratoconus: The central cornea becomes thinned and an anterior protrusion develops (Fig. 68) in the second or third decade of life. Ruptures may occur in Descemet's membrane, so that fluid enters the cornea, rendering it oedematous, and bullae develop in the corneal epithelium which rupture, giving rise to pain (acute keratoconus). The patient becomes progressively myopic due to the increasing curvature of the cornea, and, since the forward protrusion is irregular, develops irregular astigmatism leading to severe loss of acuity. The condition is almost invariably unilateral

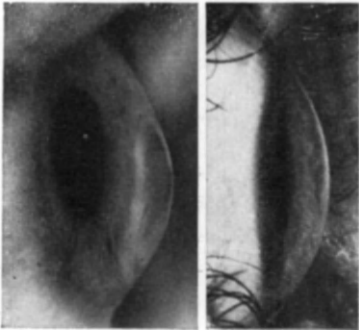


Fig. 68. Left: Keratoconus; right: normal cornea

and the cause is not known. **Treatment:** Initial correction by means of contact lenses. At a later stage penetrating corneal keratoplasty may be necessary (Fig. 70c). *Hereditary corneal dystrophies:* Onset is in childhood or young adulthood; there is no evidence of ocular inflammation. Granular, macular or lattice opacities develop in the corneal stroma (Fig. 67d), giving rise to progressive, but gradual, reduction of visual acuity. **Treatment:** If visual function is severely impaired, keratoplasty is required.

Fuch's endothelial dystrophy occurs in the older age groups. Dystrophic changes develop in the corneal epithelium which in the early stages, may be recognized on slit lamp examination as spots or droplets. Later, because of defective endothelial function, corneal oedema develops, leading to loss of vision. In the later stages the corneal epithelium is raised up in a series of bullae (Fig. 66e), which rupture, causing severe ocular pain. **Treatment:** In the early stages of the disease process, keratoplasty may be effective. In the later stages, however, palliation of the ocular pain is the only therapy available.

Metabolic diseases

Kayser-Fleischer ring is a hallmark of Wilson's disease (hepatolenticular degeneration)

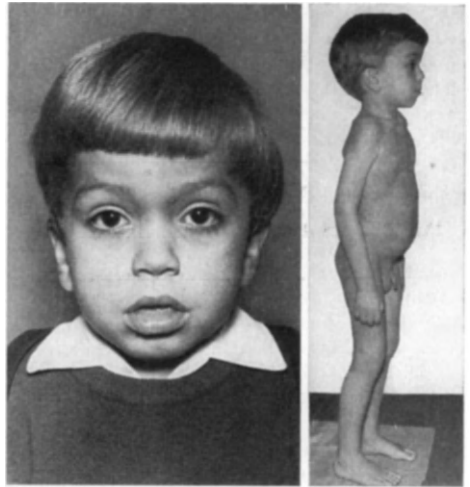

Fig. 69. Hurler's syndrome (gargoylism)

and is caused by the deposition of copper salts in the corneal stroma at the corneal-scleral junction (Fig. 64d). Corneal infiltration also occurs in *cystinosis*, in which crystalline deposits of cystine may be noted. The corneae of patients with **gargoylism** (Fig. 69) are diffusely opaque due to the deposition of mucopolysaccharides on this tissue. **Krukenberg's spindle** is a deposition of pigment on the endothelial surface of the cornea in a triangular distribution with the apex pointing upwards. Such deposits may be seen in diabetes.

Surgery

Keratoplasty: Replacement of a diseased disc of cornea by a clear healthy disc from another individual (homograft). The operation is performed to improve vision, e.g. in keratoconus, corneal dystrophies (Fig. 64c), or to prevent corneal perforation following corneal ulcerations, and is usually carried out under general anaesthesia. The disc of the cornea is removed from the host using a sharp round trephine (Fig. 70a-b). A disc of equal size (diameter 5-9 mm) is cut from the donor eye, placed in the host's

cornea and sutured into place. Keratoplasty may be either **penetrating** (Fig. 70c), when the entire thickness of the cornea is removed, or **lamellar** (Fig. 70d) when only the more superficial layers of the cornea are replaced). **Prognosis:** When performed on patients with good endothelial function who have no evidence of active inflammatory disease and where the cornea is not vascularized, tear secretion is good and intra-ocular pressure is within normal limits, the prognosis is excellent. In patients who have one or more of these adverse factors, the prognosis is less certain. If the graft fails and the cornea becomes opaque and vascularized, vision is again lost. Attempts have been made to insert an artificial lens or prosthesis into the cornea (Fig. 70e-f), but such devices usually preserve vision for only a short period before being rejected.

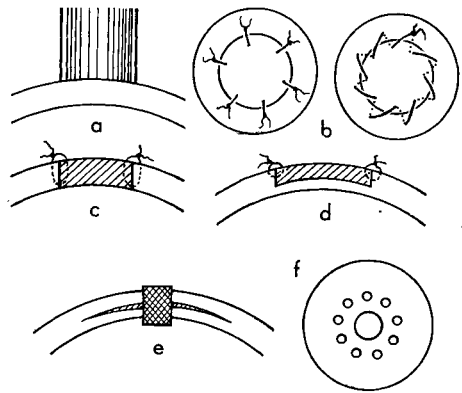


Fig. 70. Keratoplasty: a removal of recipient's cornea using a round trephine; b transplanted cornea in situ, with (left) interrupted and (right) continuous sutures; c penetrating keratoplasty; d lamellar keratoplasty; e-f corneal prosthesis, cross-section and front view

6. Sclera

General considerations

The sclera consists of tough connective tissue containing elastic fibres, and is the stable protective shell of the eye. In old age it is liable to undergo fatty infiltration and become somewhat thinned. Between the sclera and the conjunctiva there is a layer of loose connective tissue, the episclera. The most vulnerable part of the sclera to blunt trauma is the area adjacent to the canal of Schlemm (see Chapter 16).

Diseases

Scleritis and episcleritis appear as raised or flat areas of vascular engorgement, located deeply in the case of scleritis, and superficially in episcleritis. In episcleritis (Fig. 71a) the vessels can be moved over the sclera on applying pressure through the lids. With scleritis, however, the vessels remain immobile and there is bluish-red

ciliary injection. In episcleritis the patient complains of tenderness, but in scleritis the pain is severe and aching in nature. In the latter condition there is often evidence of inflammatory changes in the anterior chamber; such changes are not, however, seen in episcleritis. Later, in some patients with scleritis the sclera becomes transparent and thinned, so that slate-grey discoloration develops. This is due to the dark uvea showing through the thinned sclera (scleromalacia perforans). When the sclera becomes excessively thin a scleral staphyloma (a bulging patch) occurs (Fig. 71b). **Aetiology:** In episcleritis usually no specific cause can be found, but it has been suggested that it is an allergic or hypersensitivity reaction. Patients presenting with scleritis must be investigated for collagen diseases, especially rheumatoid arthritis. Other complications include marginal ulceration of the cornea, sclerosing keratitis (heavy opacification

cornea and sutured into place. Keratoplasty may be either **penetrating** (Fig. 70c), when the entire thickness of the cornea is removed, or **lamellar** (Fig. 70d) when only the more superficial layers of the cornea are replaced). **Prognosis:** When performed on patients with good endothelial function who have no evidence of active inflammatory disease and where the cornea is not vascularized, tear secretion is good and intra-ocular pressure is within normal limits, the prognosis is excellent. In patients who have one or more of these adverse factors, the prognosis is less certain. If the graft fails and the cornea becomes opaque and vascularized, vision is again lost. Attempts have been made to insert an artificial lens or prosthesis into the cornea (Fig. 70e-f), but such devices usually preserve vision for only a short period before being rejected.

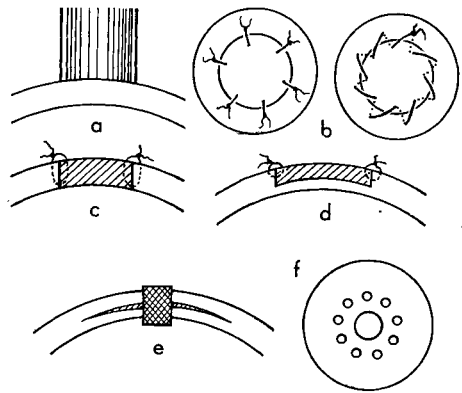


Fig. 70. Keratoplasty: a removal of recipient's cornea using a round trephine; b transplanted cornea in situ, with (left) interrupted and (right) continuous sutures; c penetrating keratoplasty; d lamellar keratoplasty; e-f corneal prosthesis, cross-section and front view

6. Sclera

General considerations

The sclera consists of tough connective tissue containing elastic fibres, and is the stable protective shell of the eye. In old age it is liable to undergo fatty infiltration and become somewhat thinned. Between the sclera and the conjunctiva there is a layer of loose connective tissue, the episclera. The most vulnerable part of the sclera to blunt trauma is the area adjacent to the canal of Schlemm (see Chapter 16).

Diseases

Scleritis and episcleritis appear as raised or flat areas of vascular engorgement, located deeply in the case of scleritis, and superficially in episcleritis. In episcleritis (Fig. 71a) the vessels can be moved over the sclera on applying pressure through the lids. With scleritis, however, the vessels remain immobile and there is bluish-red

ciliary injection. In episcleritis the patient complains of tenderness, but in scleritis the pain is severe and aching in nature. In the latter condition there is often evidence of inflammatory changes in the anterior chamber; such changes are not, however, seen in episcleritis. Later, in some patients with scleritis the sclera becomes transparent and thinned, so that slate-grey discoloration develops. This is due to the dark uvea showing through the thinned sclera (scleromalacia perforans). When the sclera becomes excessively thin a scleral staphyloma (a bulging patch) occurs (Fig. 71b). **Aetiology:** In episcleritis usually no specific cause can be found, but it has been suggested that it is an allergic or hypersensitivity reaction. Patients presenting with scleritis must be investigated for collagen diseases, especially rheumatoid arthritis. Other complications include marginal ulceration of the cornea, sclerosing keratitis (heavy opacification

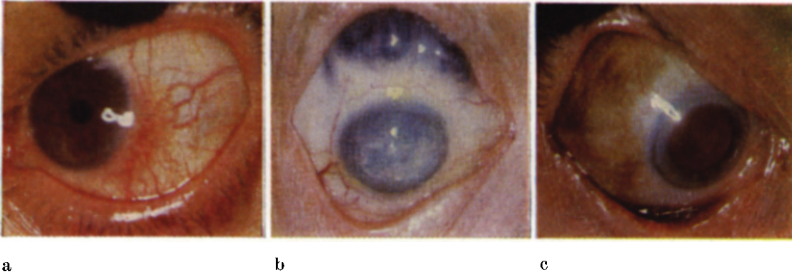


Fig. 71. a Episcleritis; b scleral staphyloma and sclerosing keratitis in chronic recurrent scleritis; c scleral melanosis

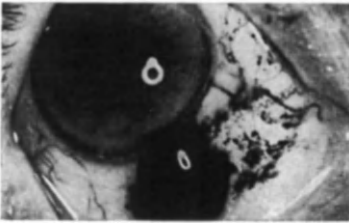


Fig. 72. Malignant melanoma of the choroid

extending over the cornea, leading eventually to porcelain white scars, see Figs. 58i, 64b), glaucoma secondary to uveitis and, if scleritis is located posteriorly, serous retinal detachment. **Treatment:** Should be directed towards the underlying cause. Treatment of scleromalacia perforans is

extremely difficult and unrewarding. Use of topical steroids, scleral patch grafts and more esoteric forms of therapy have not met with widespread success.

Other conditions involving the sclera

Blue sclera syndrome (van der Hoeve's syndrome): Features include abnormal bone fragility and deafness. The sclera is thin, so that the uvea shows through as a darker blue colour; inheritance is usually autosomal dominant.

Scleral melanosis: Patches of pigmentation occur in the sclera (Fig. 71c). These have no clinical significance. Pigmentary deposition also occurs in siderosis, icterus, Addison's disease and argyrosis.

Intra-ocular tumours: Malignant melanomas which have reached an advanced stage may penetrate the sclera (Fig. 72).

7. Lens

General considerations

The lens consists of a capsule, cortex and nucleus. It is formed from ectoderm in the third fetal month, has a biconvex form (the posterior curvature is slightly greater) and contributes about 15 dioptres to the total refractive power of the eye. **Size:** The equatorial diameter is approximately 10 mm, thickness 3.5 mm and weight 0.3 g in an adult. There are no blood vessels or nerves in the crystalline lens.

Nutrition to the lens is provided by the aqueous humour, which is in constant circulation. The epithelium at the equator of the lens contributes to produce new lens fibres throughout life which pile up on top of the old ones, a process known as appositional growth. In old age the nucleus frequently acquires a yellowish or brownish tinge, and at the same time the refractive index of the nucleus increases (nuclear sclerosis), causing lenticular myopia (see Chapter 18). The layers of the lens, with the

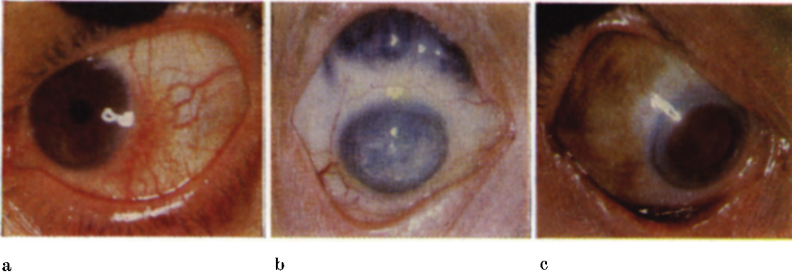


Fig. 71. a Episcleritis; b scleral staphyloma and sclerosing keratitis in chronic recurrent scleritis; c scleral melanosis

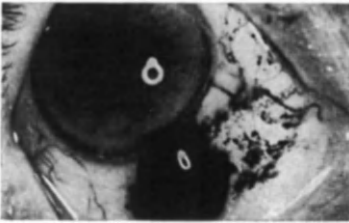


Fig. 72. Malignant melanoma of the choroid

extending over the cornea, leading eventually to porcelain white scars, see Figs. 58i, 64b), glaucoma secondary to uveitis and, if scleritis is located posteriorly, serous retinal detachment. **Treatment:** Should be directed towards the underlying cause. Treatment of scleromalacia perforans is

extremely difficult and unrewarding. Use of topical steroids, scleral patch grafts and more esoteric forms of therapy have not met with widespread success.

Other conditions involving the sclera

Blue sclera syndrome (van der Hoeve's syndrome): Features include abnormal bone fragility and deafness. The sclera is thin, so that the uvea shows through as a darker blue colour; inheritance is usually autosomal dominant.

Scleral melanosis: Patches of pigmentation occur in the sclera (Fig. 71c). These have no clinical significance. Pigmentary deposition also occurs in siderosis, icterus, Addison's disease and argyrosis.

Intra-ocular tumours: Malignant melanomas which have reached an advanced stage may penetrate the sclera (Fig. 72).

7. Lens

General considerations

The lens consists of a capsule, cortex and nucleus. It is formed from ectoderm in the third fetal month, has a biconvex form (the posterior curvature is slightly greater) and contributes about 15 dioptres to the total refractive power of the eye. **Size:** The equatorial diameter is approximately 10 mm, thickness 3.5 mm and weight 0.3 g in an adult. There are no blood vessels or nerves in the crystalline lens.

Nutrition to the lens is provided by the aqueous humour, which is in constant circulation. The epithelium at the equator of the lens contributes to produce new lens fibres throughout life which pile up on top of the old ones, a process known as appositional growth. In old age the nucleus frequently acquires a yellowish or brownish tinge, and at the same time the refractive index of the nucleus increases (nuclear sclerosis), causing lenticular myopia (see Chapter 18). The layers of the lens, with the

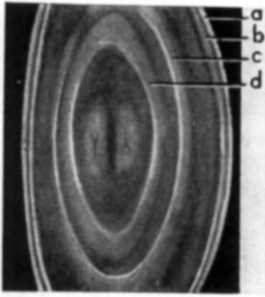


Fig. 73. Layers of the lens in an adult: a capsule; b cortex; c adult nucleus; d embryonic nucleus

divisions between the various zones, can be readily seen on slit lamp examination (Fig. 73). The lens is suspended from the ciliary body at the equator by the suspensory ligaments. **Accommodation** (increase in the refractive power of the eye in order to see near objects): The circular muscular fibres of the ciliary body ring contract, reducing the diameter of the ciliary body. The tension of the zonule is reduced and the plastic lens takes up a more spherical form due to the elasticity of its capsule. With age, the lens becomes less plastic, so that accommodation becomes increasingly difficult (presbyopia: the inability in the older age group to focus on near objects, whilst retaining good distance vision).

Examination procedures

If the lens capsule is damaged from metabolic, toxic or traumatic causes, or ageing processes, etc., opacities (cataracts) develop. Lens opacities may be detected using an ophthalmoscope, since they show up as grey or black shadows against the red pupillary reflex. The location of an opacity within the eye is determined by asking the patient to look up or down. If they move only minimally, or not at all, cataracts are present. Corneal opacities move upwards as the eye is elevated, and opacities in the vitreous move in the opposite direction (Fig. 74). A more accurate method of detecting the localization of cataracts within the lens is by use of focal illumination or slit lamp examination.

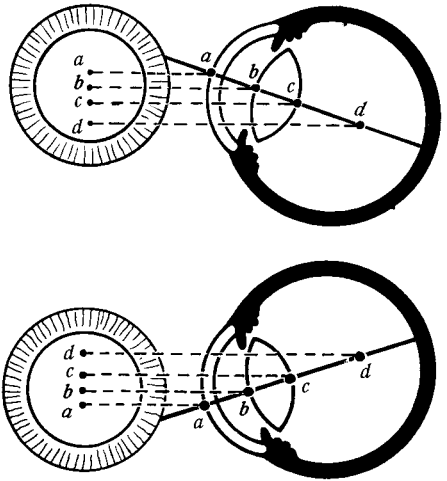


Fig. 74. Changes in the position of corneal, lenticular and vitreous opacities when the eye is raised (above) and lowered (below)

Congenital abnormalities

Congenital cataracts

Actiology: Often hereditary, but developmental disturbances in utero also play a major role, i.e. maternal infections during the first trimester of pregnancy, especially by viral agents. **Maternal rubella** is the most important of these. The virus, transmitted across the placenta membranes, is capable of causing severe damage to the fetus. Ocular disturbances include microphthalmos, cataracts, glaucoma and pigmentary disturbances of the retina. The child may also suffer from cardiac defects, inner ear deafness and mental retardation, which, in combination with impaired sight, pose considerable educational problems. Cataracts are seen in mongolism, galactosemia and Lowe's syndrome (amino-aciduria hyporeflexia and mental deficiency).

If the lens opacities are extremely dense (Fig. 75a) and bilateral the infant develops a pendular nystagmus, because the development of visual function is grossly impeded (see Chapter 19). Occasionally, spon-

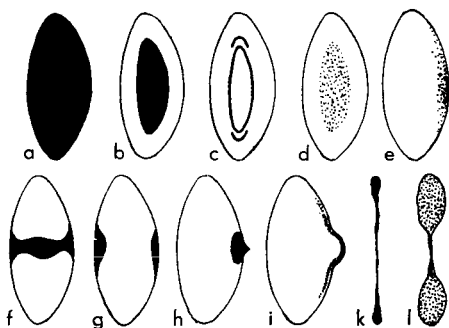


Fig. 75. Types of cataract: a total cataract; b nuclear cataract; c zonular cataract; d punctate cataract; e posterior cortical cataract; f axial cataract; g posterior and anterior pole cataracts; h pyramidal cataract; i posterior lenticonus; k membranous cataract; l ring cataract

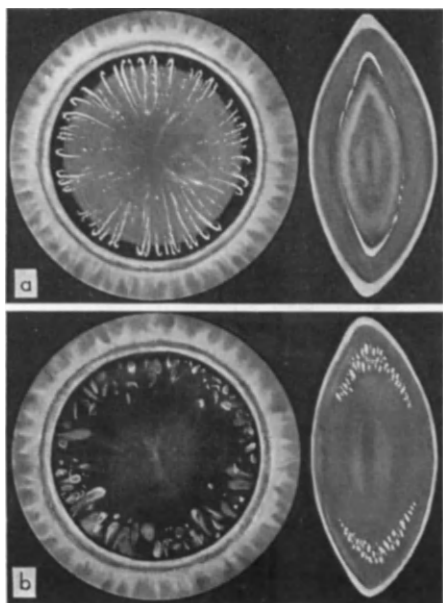


Fig. 76. a Zonular cataract; b coronary cataract (front views and in cross-section)

taneous resorption of lens material occurs, leaving behind the capsular membrane (membranous cataract, Fig. 75k). Coronary cataracts (Fig. 76b), punctate opacities (blue dot cataracts), nuclear and posterior cataracts (Fig. 75d-g) are occasionally seen in newborn infants. Many do not progress and cause little in the way of visual disturbances.

Zonular cataracts (Figs. 75c, 76a), usually bilateral, may be congenital or acquired, occurring following trauma, in tetany and with many other generalized disease processes. Visual impairment varies according to the location of the opacities, and since progression is usually absent or very slow, surgery should not be attempted unless the cataract is causing considerable visual problems.

Pyramidal cataract probably occurs following perforating corneal ulcers (e.g. ophthalmia neonatorum). Temporary adhesion of the capsule to the inflamed cornea causes a cataract to form and the anterior curvature of the lens to be distorted when the anterior chamber re-forms and the lens moves away from the cornea (Fig. 75h).

Posterior polar cataracts (Fig. 75e) may only cause a very slight reduction in vision; usually an anterior remnant of the hyaloid artery is present.

Anterior polar cataracts are frequently associated with partial persistence of the pupillary membrane, which continues to adhere to the anterior surface of the lens. Very rarely, when both anterior and posterior opacities develop in utero (Fig. 75g), an axial opacity joining the two is formed (Fig. 75f).

Other congenital abnormalities

Lens coloboma: The equator of the lens is indented and this defect may be associated with an iris coloboma. Defects of the suspensory ligaments lead to a spherical lens (spherophakia), which is a feature of Marfan's syndrome and homocystinuria. The patient's refraction is myopic due to the increased refractive power of the lens (lenticular myopia). **Lenticonus** is a conical protrusion from one or other pole of the lens (Fig. 75i).

Displacement of the crystalline lens

Luxation or subluxation of the lens into the vitreous (Figs. 77, 78 a) is accompanied by quivering of the iris (iridodonesis), as the iris is not supported by the anterior lens capsule. The edge of the lens may bisect the pupil, so that the patient suffers from monocular diplopia (seeing two images with one eye), due to the differing refraction in the parts of the pupil which contain the lens and those which do not (Fig. 77e), and, for similar reasons, on ophthalmoscopic examination the optic disc may appear to be double (Fig. 79). Because of the lack of tension in the suspensory ligaments, the lens assumes a spherical shape (spherophakia). Luxation of the lens into the anterior chamber (Fig. 78 b) or constriction of the pupil with miotics may result in rises in intra-ocular pressure. **Aetiology:** Blunt trauma, Marfan's syndrome (features include unusually long growth of the fingers, funnel chest, winged scapula, high arched palate and dissecting aneurysms of the aorta, Figs.

78 a, 80) and homocystinuria (inborn error of metabolism) resulting from absence of cystathionine synthetase, causing disturbance of gait, mental deficiency and thrombotic and embolic phenomena.

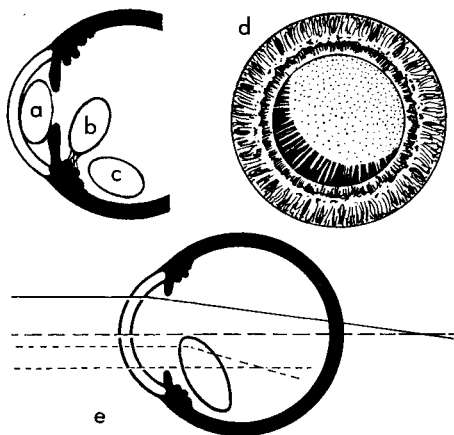
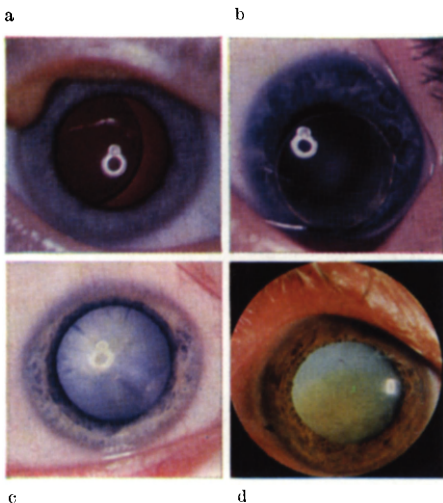


Fig. 77. Displacement of the lens: a into the anterior chamber; b subtotal (subluxation); c total luxation into the vitreous; d subluxated lens from the front; e difference in refraction in subluxation of the lens (above hyperopia due to aphakia, below myopia as a result of pronounced bulging of the lens)

Fig. 78. a Subluxation of the lens in Marfan's syndrome; b lens which has luxated into the anterior chamber; c mature cataract; d hypermature cataract with displaced nucleus inferiorly

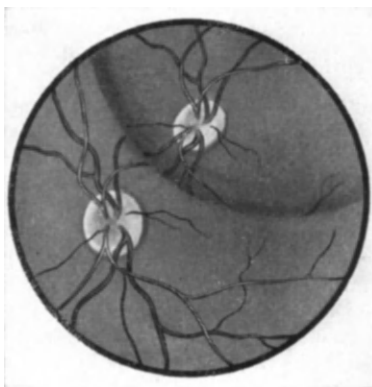


Fig. 79. Ocular fundus with a subluxated lens: Monocular diplopia

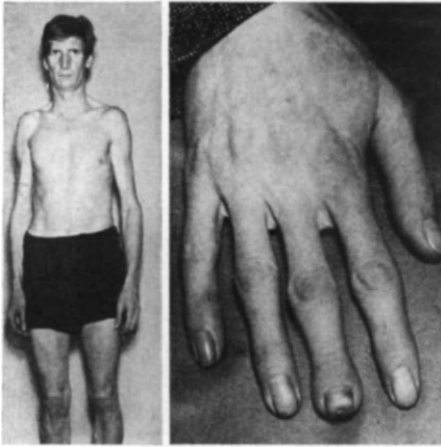

Fig. 80. Marfan's syndrome (increased length of long bones, arachnodactyly)

Treatment of congenital cataracts

Surgery should only be performed when vision is severely impaired, or swelling of a lens is about to produce angle closure glaucoma (see Chapter 10). No operation should be attempted if the cataract is unilateral and the other eye is normal. In infants lens material is fluid and readily aspirated by introducing a wide bore needle attached to a syringe through the cornea after rupturing the anterior capsule of the lens; any remaining lens material usually absorbs spontaneously. In older children it may be necessary to incise the anterior lens capsule with a sharp knife introduced through the cornea (discission of the lens, Fig. 85c), allowing the lens proteins to degrade and become more fluid, and later express the lens material through an opening in the cornea (linear extraction). Also see p. 51 concerning phaco-emulsification.

In a child born with bilateral dense congenital cataracts, one eye is usually operated upon within the first few days of life and a constant wear contact lens inserted to correct the refractive error. In patients with central lens opacities, pupillary dilatation

with mydriatics frequently allows a sufficiently clear image to be formed for useful vision to develop. Alternatively, an optical iridectomy, where a piece of iris is removed within the palpebral aperture, provides a permanent method of achieving the same aim.

Senile cataracts

Senile cataracts are classified according to the position of the lenticular opacities. **Posterior cortical cataract** (Fig. 81a) often renders near vision difficult because the associated miosis with accommodation reduces the amount of light falling on the retina. **Nuclear cataract** (Fig. 75b): The nucleus becomes denser, causing the refractive index of this part of the lens to increase \rightarrow lenticular myopia, often permitting a patient to read without glasses when they were previously required. In many cases both posterior cortical and nuclear cataracts coexist. Vision is often better in dim light owing to widening of the pupil and because there is less scattering of light as it passes through the cloudy lens. In normal daylight, cataracts cause dazzle, so that patients find relief from wearing dark glasses. Water vacuoles or clefts appear in early cataracts between the lens fibres, which can be detected on slit lamp examination (Fig. 81b).

Degree of opacification: Distinction is made according to the degree of opacification between incipient, moderately advanced, intumescent (swollen lens), premature, mature (Fig. 78c) and brunescent (deposition of brownish pigment) types of cataracts. When the cortical material has disintegrated into a pulp and the nucleus fallen inferiorly, the condition is known as Morgagnian cataract (Figs. 78d, 81c). The lens capsule is often under considerable tension in such circumstances and may rupture spontaneously.

Progression: Increased opacification of the crystalline lens does not always take place at a regular rate, and it may be many years

before the opacities severely impair visual acuity. Even in the case of a dense cataract the direction of incipient light is discernible, and the pupillary responses to light are not impaired unless there is ocular pathology behind the lens.

Aetiology: The exact mechanism is unknown, but it occurs as part of the general body ageing processes. Most patients by the age of 70 have evidence of lenticular opacities. Members of certain families develop cataracts earlier than the norm, suggesting a familial factor, and some races are more prone to develop cataracts at an early age. Exposure to strong actinic light and other geographical factors may have some relevance.

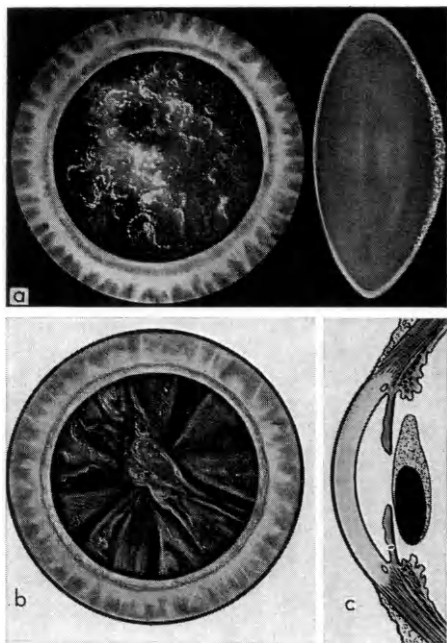


Fig. 81. a Posterior cortical cataract; b cataract with water clefts; c Morgagnian hypermature cataract with nucleus fallen inferiorly

Cataracts associated with systemic diseases

Diabetic cataract: Diabetics tend to develop senile cataracts at an earlier age than the general population. In young patients with marked hyperglycaemia, punctate cortical opacities can develop very rapidly (snowflake opacities, Fig. 82a). These may disappear if the diabetes is brought under control.

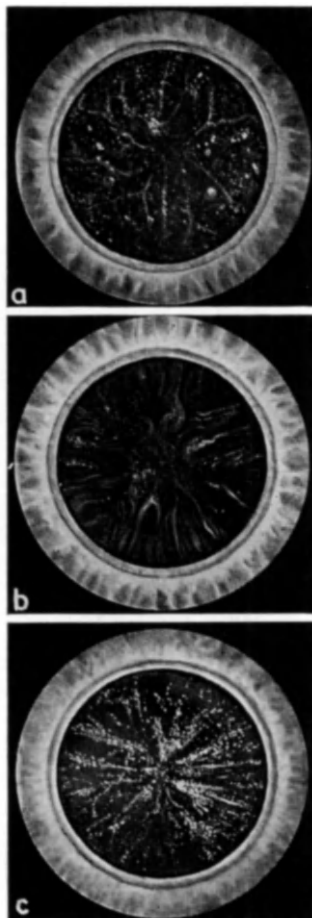


Fig. 82. a Diabetic cataract; b tetanic cataract; c myotonic cataract

Tetanic cataract results from idiopathic hypofunction or following the accidental removal of the parathyroid glands in goitre surgery. Flat lens opacities, often star- or rosette-shaped, appear under the lens capsule, particularly at the posterior pole (Fig. 82 b).

Myotonic cataract occurs in dystrophia myotonica (a hereditary disease which, apart from myotonia, is characterized by frontal baldness, testicular atrophy and cataracts). The lens changes are similar to those of tetanic cataract, but in addition there may be numerous glistening crystal-like spots in the lens cortex (Fig. 82 c).

Dermatogenic cataracts develop in chronic atopic eczema, disseminated neurodermatitis and poikiloderma. The opacities begin in the subcapsular anterior cortical layers as radial opacities.

Other forms of cataract

Traumatic and concussive cataracts see Chapter 16.

Radiation cataracts: Cortical opacities, mainly involving the posterior pole, occur in individuals who have had prolonged exposure to infrared radiation, e.g. glass-blowers, chainmakers, blast furnace workers, blacksmiths, etc. Later, desquamation on the anterior surface of the lens occurs (Fig. 83 a). Workers engaged in these occupations must wear goggles containing lenses which filter out infrared rays.

X-ray and radium cataracts appear 2–15 years after exposure to rays (in excess of 400 rad). Patients being treated with therapeutic radiation in the region of the lids should always wear a protective lead contact lens. The condition usually starts with tuft-like opacities at the posterior pole of the crystalline lens (Fig. 83 b).

Toxic cataracts are caused by substances such as thallium, ergotamine and naphthalene.

Complicated cataract is usually a result of prolonged intra-ocular disease, e.g. chronic iridocyclitis or uveitis, long-standing reti-

nal detachments, etc. Opacifications of the lens often begin at the posterior pole, and on slit lamp examination, small glistening areas glowing red, blue or green can be seen (bejewelled cataract).

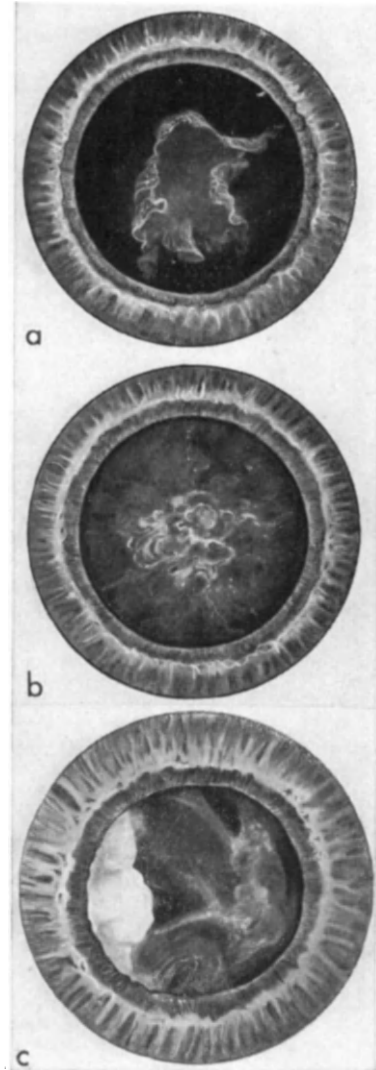


Fig. 83. a Infrared radiation cataract; b X-ray cataract; c secondary cataract

Secondary cataract occurs when the lens capsule has been ruptured and non-absorbed lens material remains with capsule remnants (Figs. 75k, 83c). Occasionally the remaining epithelium forms further aberrant lens fibres to give rise to clear nodular or bubbly excrescences (Elschnig's pearls) or a ring cataract (Fig. 75l).

Cataract surgery in adults

Operations for the removal of opaque crystalline lenses have undergone considerable improvement over the past decade. This has been due to the development of microsurgical procedures, the availability of finer suture materials and more sophisticated methods of extraction such as cryosurgical techniques. Cataract surgery is a relatively safe operation on old people, and surgery may be performed under local or general anaesthesia.

Local anaesthesia: Anaesthesia of the globe and akinesia of the extra-ocular muscles are produced by giving a retrobulbar injection of local anaesthetic, the needle being introduced through the lower lid and passed through the muscle cone behind the globe, where the anaesthetic agent is injected (Fig. 85a). The facial nerve is paralysed by injecting local anaesthetic at the point where it passes over the ramus of the mandible.

General anaesthesia: This should always be employed if the patient is deaf, if there is any reason to believe that the operation may be prolonged or if complications are likely to be encountered. General anaesthesia is certainly desirable when an operating microscope is being used.

Techniques: There are many different techniques for performing cataract surgery but the standard procedure involves making an incision at the corneoscleral junction over an arc of about 160° (Fig. 86a-b). The



Fig. 84. Juvenile cataract in a young tiger

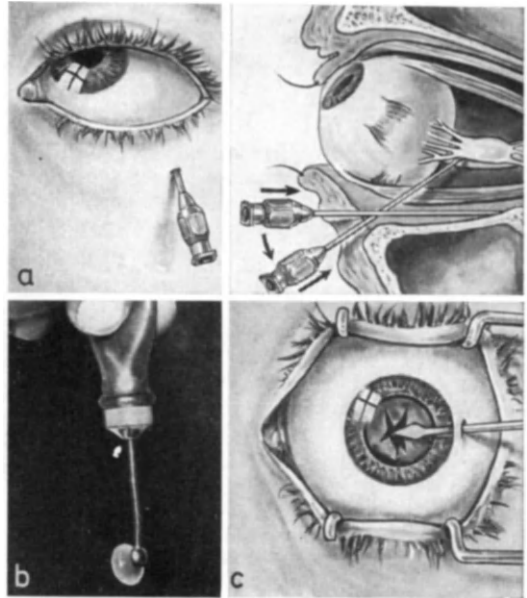


Fig. 85. a Retrobulbar injection in the region of the ciliary ganglion to produce anaesthesia and bulbar akinesia; b extraction using an erisiphake; c rupture of anterior capsule of lens

cornea is then lifted up and the lens, with its capsule, removed (intracapsular cataract extraction) through a pupil which has previously been dilated with mydriatics, by means of a cryoprobe (cryoextraction, Fig. 87), with capsule forceps (Fig. 86 c) or with an erisphake (Fig. 85 b). Intracapsular cataract extraction should not be attempted in patients younger than 35 years, as the vitreous remains adherent to the posterior lens capsule until this age. Removal of the crystalline lens is made easier by introducing the enzyme α -chymotrypsin into the anterior chamber which dissolves zonular

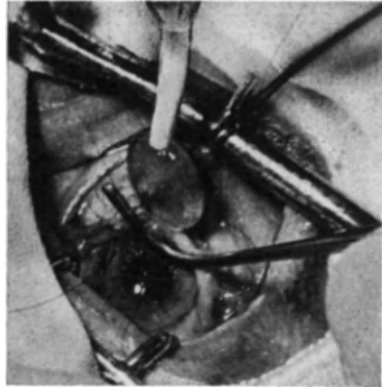


Fig. 87. Extraction of lens with cryoprobe

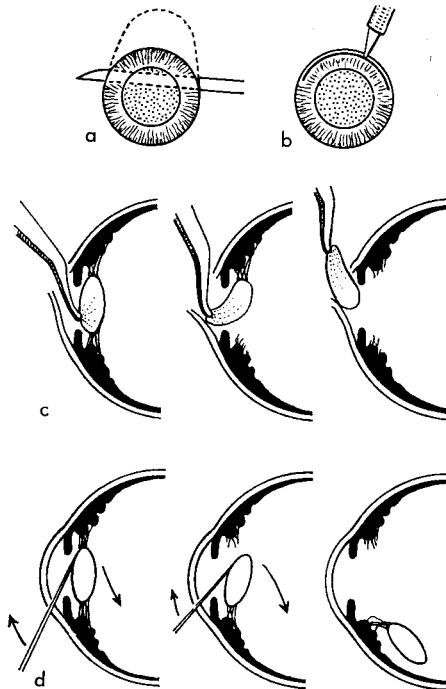


Fig. 86. Cataract operations: a opening the anterior chamber using a Graefe knife, transfixing the cornea and cutting out; b using a scalpel, external approach; c extraction of cataract with forceps; the lens is grasped, tilted and removed; d method used to treat cataracts in the Middle Ages: the lens was luxated into the vitreous with a cataract needle

fibres. If the capsule ruptures, some lens fibres and the posterior capsule may be left behind to form a secondary cataract (Fig. 83 c). Before closing the corneascleral incision a peripheral iridectomy is performed to prevent postoperative pupillary block glaucoma (see Fig. 96 c). More recently, a technique using an ultrasonic probe to break down the lens fibres has been used. After opening the anterior capsule with a pointed knife (Fig. 85 c), the ultrasonic probe is introduced into the anterior chamber through the small incision used previously, and the lens material is disrupted and washed out of the eye, leaving behind the posterior capsule (extracapsular cataract extraction). This technique is highly suitable in cases where an intracapsular cataract extraction is contraindicated, e.g. patients under 35 years of age.

For rays to become focused on the retina after cataract extraction, a hypermetropic correction is required: for distance approximately 11 dioptres and for close-up vision 14–15 dioptres in a previously emmetropic eye. Patients with myopia require a weaker correction, and those with hypermetropia need stronger lenses. Cataract glasses prescribed for the operated eye will cause unilateral image magnification of between 20 and 30 per cent (aniseikonia), see Chapter 18, so if vision in the unoperated eye is

6/24 or better, binocular vision will be impossible, as the images of the two eyes cannot be fused. Binocular vision may be restored using contact lenses, as image magnification is only about 5 per cent. Aniseikonia is reduced to even lower levels if an intra-ocular lenticulus is inserted either at the time of cataract operation or at a later date. After cataract extraction (aphakia, Fig. 92f), the iris quivers (iridodonesis) because no lens is present to support it, the

anterior chamber is deeper than previously and a surgical iridectomy is visible.

Couching of cataracts has been practised for some thousands of years. A needle is introduced through the cornea and the lens dislocated into the vitreous cavity (Fig. 86d). This operation is not now practised because if the lens capsule ruptures at operation, lens material is dispersed within the vitreous, which causes severe intra-ocular inflammation and secondary glaucoma.

Both congenital and senile cataracts develop in many animals, apart from man (Fig. 84).

8. Uveal Tract (Iris, Ciliary Body and Choroid)

General considerations

An arbitrary distinction has been made between the anterior uveal tract (iris and ciliary body) and the posterior uveal tract (choroid). The iris regulating the amount of light which enters the eye belongs to the "diaphragm", composed of the iris and lens (Fig. 88), which divides the anterior chamber from the vitreous cavity and posterior chamber.

Iris: Consists of an anterior mesodermal layer (with numerous chromatophores in dark-eyed people) and a posterior pigment layer derived from ectoderm. For the muscles of the iris, see Fig. 98. Blood vessels are not normally visible on the surface of the iris, but if present are usually a sign of intra-ocular pathology.

Ciliary body: Contains the ciliary muscles (longitudinal, lateral and meridional) employed for accom-

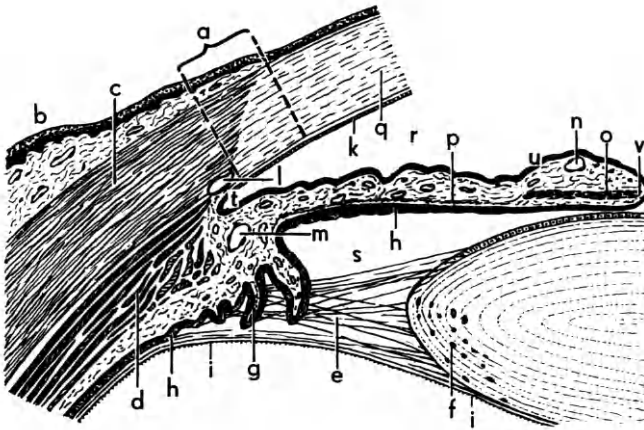


Fig. 88. Cross-section through the iris-lens diaphragm: a corneal limbus area; b bulbar conjunctiva; c sclera; d meridional and circular muscle fibres of the ciliary body; e zonule; f lens; g ciliary processes; h pigment epithelium and posterior surface of iris; i anterior vitreous limiting membrane; k Descemet's membrane and endothelium; l canal of Schlemm; m major arterial circle of iris; n minor arterial circle of iris; o sphincter pupillae muscle; p dilator pupillae muscle; q cornea; r anterior chamber; s posterior chamber; t anterior chamber angle with corneoscleral trabeculum; u stroma of iris; v pupil margin

6/24 or better, binocular vision will be impossible, as the images of the two eyes cannot be fused. Binocular vision may be restored using contact lenses, as image magnification is only about 5 per cent. Aniseikonia is reduced to even lower levels if an intra-ocular lenticulus is inserted either at the time of cataract operation or at a later date. After cataract extraction (aphakia, Fig. 92f), the iris quivers (iridodonesis) because no lens is present to support it, the

anterior chamber is deeper than previously and a surgical iridectomy is visible.

Couching of cataracts has been practised for some thousands of years. A needle is introduced through the cornea and the lens dislocated into the vitreous cavity (Fig. 86d). This operation is not now practised because if the lens capsule ruptures at operation, lens material is dispersed within the vitreous, which causes severe intra-ocular inflammation and secondary glaucoma.

Both congenital and senile cataracts develop in many animals, apart from man (Fig. 84).

8. Uveal Tract (Iris, Ciliary Body and Choroid)

General considerations

An arbitrary distinction has been made between the anterior uveal tract (iris and ciliary body) and the posterior uveal tract (choroid). The iris regulating the amount of light which enters the eye belongs to the "diaphragm", composed of the iris and lens (Fig. 88), which divides the anterior chamber from the vitreous cavity and posterior chamber.

Iris: Consists of an anterior mesodermal layer (with numerous chromatophores in dark-eyed people) and a posterior pigment layer derived from ectoderm. For the muscles of the iris, see Fig. 98. Blood vessels are not normally visible on the surface of the iris, but if present are usually a sign of intra-ocular pathology.

Ciliary body: Contains the ciliary muscles (longitudinal, lateral and meridional) employed for accom-

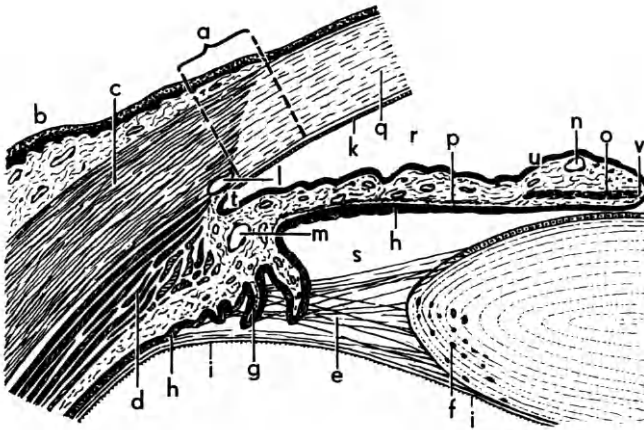


Fig. 88. Cross-section through the iris-lens diaphragm: a corneal limbus area; b bulbar conjunctiva; c sclera; d meridional and circular muscle fibres of the ciliary body; e zonule; f lens; g ciliary processes; h pigment epithelium and posterior surface of iris; i anterior vitreous limiting membrane; k Descemet's membrane and endothelium; l canal of Schlemm; m major arterial circle of iris; n minor arterial circle of iris; o sphincter pupillae muscle; p dilatator pupillae muscle; q cornea; r anterior chamber; s posterior chamber; t anterior chamber angle with corneoscleral trabeculum; u stroma of iris; v pupil margin

modation. The ciliary processes secrete the aqueous humour and act as points of attachment for the suspensory ligament of the lens.

Choroid: Has three layers: the *lamina vasculosa* with large blood vessels, the *choriocapillaris* with small vessels which supply nutrients to the outer retinal layers and the *lamina vitrea elastica* which is fused with the outer limiting membrane of the retinal pigment epithelium.

Blood supply (Fig. 89): The choroidal supply is derived from the ophthalmic artery via the short posterior ciliary arteries (a) which pierce the sclera adjacent to the optic nerve, the two long posterior ciliary arteries (b) which pass through the sclera to supply the ciliary body and iris (c), anastomosing in an incomplete arterial circle in the root of the iris, and the anterior ciliary arteries (d) which are branches of vessels supplying the extra-ocular muscles. The anterior ciliary arteries support the limbal

area and anastomose with the conjunctival and long posterior ciliary vessels (e). Venous drainage is effected through four or more vortex veins (f) which pierce the sclera behind the equator and drain into the superior and inferior ophthalmic veins, and thence into the cavernous sinus.

Inflammations of the uveal tract (Uveitis)

Uveitis is arbitrarily subdivided into iritis, cyclitis and choroiditis, depending on which part of the uveal tract is preferentially affected. However, in any inflammatory lesion involving one part of the uvea, one or more of the others is invariably involved.

Iritis and iridocyclitis

Acute and chronic forms are recognized. Acute iritis is characterized by reduced vision due to the presence of fibrin and white cells in the aqueous. These are readily recognized on slit lamp examination, when a fine pencil of light is shone obliquely through the anterior chamber (Tyndall effect). The anterior chamber is normally optically empty.

The patient also complains of: photophobia, lacrimation and dull pain.

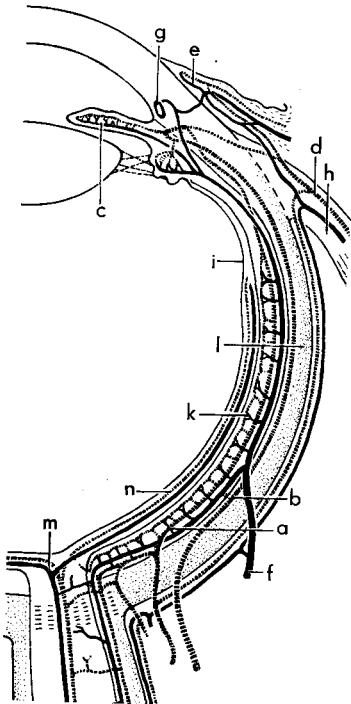


Fig. 89. Uveal circulatory system. a-f See text; g canal of Schlemm; h rectus muscle; i ora serrata; k choriocapillaris; l sclera; m central retinal artery and vein; n retinal veins

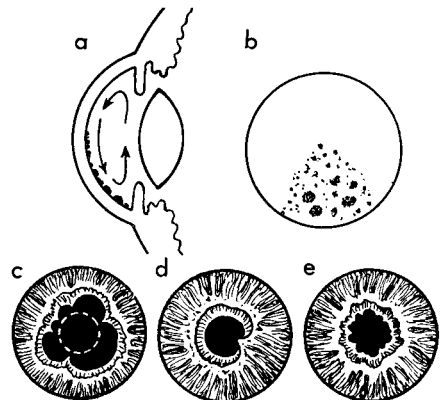


Fig. 90. a Convection current of the aqueous humour in the anterior chamber; b pattern of the keratic precipitates; c-d pointed and peaked synechiae in iritis; e extended near-total synechiae

Signs include:

Ciliary vascular injection (Fig. 59 c).

Hyperaemia of the iris and, occasionally, the presence of iris nodules (this occurs particularly in the granulomatous diseases, e.g. tuberculosis and sarcoid).

The pupil is constricted and reacts poorly to light.

Aggregates of cells form on the corneal endothelium (Fig. 90 a-b, keratic precipitates).

In severe cases of iritis a pus level develops in the anterior chamber (hypopyon, Fig. 91).

Complications: Posterior synechiae formation (adhesions between the posterior surface of the iris and the anterior lens capsule,

Figs. 90 e, 92 b). If adhesions form all around the pupillary margin aqueous humour secreted by the ciliary body cannot enter the anterior chamber. The iris root is therefore pushed forward to come in contact with the corneal periphery (peripheral anterior synechiae), blocking off the drainage angle, and the intra-ocular pressure rises (secondary pupil block glaucoma, Fig. 92 d). Following the use of mydriatics the pupil margin may assume a scalloped contour (Fig. 90 c) in cases where posterior synechiae have formed. If mydriatics are not employed a membrane may occlude the pupil (Fig. 92 e).

Differential diagnosis: Acute angle closure glaucoma, neovascular glaucoma following central retinal vein thrombosis and diabetic angiopathy; conjunctivitis (see Table 2, Chapter 10).

Individual types of iritis:

Fibrinous iritis (Fig. 93a): There is a considerable accumulation of fibrin in the anterior chamber. On slit lamp examination no movement of white cells is seen as the aqueous is too turbid for convection currents to act (Fig. 90a). Patients with this form of iritis are particularly liable to develop hypopyon, posterior synechiae and pupillary occlusions.

Serous iritis: There is minimal or no Tyndall effect. Cells move freely on the convection currents in the anterior chamber. Posterior synechiae are an uncommon complication of this type of iritis.

Nodular iritis: Nodules form on the iris in chronic granulomatous conditions. Large mutton fat keratic precipitates appear on the corneal endothelium. Symptoms may be minimal, but the disease has a chronic course. Patients should be investigated for sarcoidosis and tuberculosis.

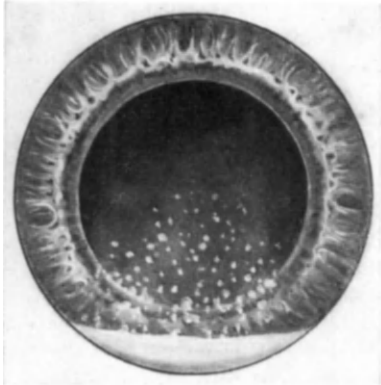


Fig. 91. Fibrinous iritis with numerous keratic precipitates and hypopyon

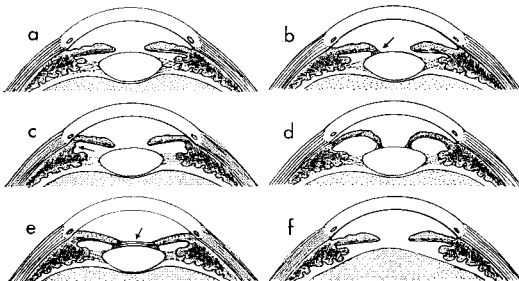


Fig. 92. a Normal iris; b localized synechiae; c anterior chamber angle with peripheral synechiae; d iris bombe (pupillary seclusion); e pupillary occlusion; f aphakia with iridodonesis (quivering iris), when the eye moves since the iris is no longer supported by the lens

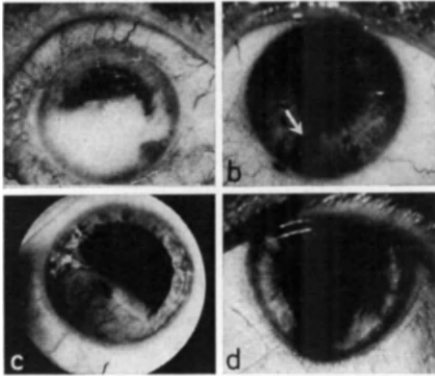


Fig. 93. a Severe iritis with large amount of fibrin in the anterior chamber; b naevus of the iris; c melanoma of the iris; d coloboma of the iris

Cyclitis

Inflammation, generally chronic, of the ciliary body. Features include dull pain and reduced accommodation, and the course is often unrelenting. Fine precipitates are present on the posterior surface of the cornea, examination of the anterior chamber shows flare and cells and there is moderate or heavy cellular activity in the vitreous. In the later stages secondary glaucoma may occur, because of the involvement of the trabecular meshwork, which becomes swollen. Secondary cataracts often develop, and macular oedema may cause central vision to become severely depressed. Examination of the ciliary body with a mirror contact lens often shows exudates over the pars plana, extending towards the insertion of the retina at the ora serrata. Later the eye becomes blind, painful and shrunken (phthisis bulbi).

Choroiditis

Inflammation of the choroid, which almost invariably spreads to the retina (choroidoretinitis, see Chapter 12).

Aetiology

Exogenous: Following perforating injuries, toxins liberated from corneal ulceration, chemical burns, etc.

Endogenous: Unknown in the majority of cases. Choroidoretinitis occasionally occurs as a result of septic emboli, arising elsewhere in the body, lodging in these tissues.

Uveitis commonly occurs in the following systemic diseases: the collagenoses, particularly the juvenile and adult forms of rheumatoid arthritis, ankylosing spondylitis, in association with gonococcal arthritis, Reiter's disease (non-specific urethritis, conjunctivitis or iritis, arthritis and plantar fasciitis), ulcerative colitis, tuberculosis, secondary syphilis, sarcoidosis, yaws, Behçet's disease (hypopyon iritis, aphthous ulceration of the mouth and ulcerative lesions of the genitalia), brucellosis, toxoplasmosis and toxocariasis.

Treatment

Where possible isolate the cause and treat accordingly. Cycloplegics and mydriatics are used to relieve pain from ciliary spasm and to dilate the pupil to prevent the formation of posterior synechiae; topical steroids reduce the intra-ocular inflammatory response and, hence, excessive damage to intra-ocular tissues. In severe fibrinous iridocyclitis, subconjunctival injections of steroids must be given in order to attain a sufficiently high steroid level within the eye. Care should always be taken when a patient is placed on longterm topical steroid therapy, as steroids themselves can cause an elevation of intra-ocular pressure in susceptible individuals.

Other types of uveal inflammation

Heterchromic iritis: An ill-understood condition which is unilateral and chronic. The iris of the affected eye is lighter in colour. Small keratic precipitates appear on the back of the cornea, but there is no pain or iris hyperaemia, and posterior synechiae do not develop. Cellular opacities are present in the anterior vitreous. Later there is iris atrophy and secondary cataracts develop. Examination of the iridocorneal angles shows small dilated vessels at this location.

Treatment is usually unnecessary until cataract extraction is required.

Sympathetic ophthalmitis see Chapter 16.

Lens-induced uveitis: Lens protein is locked away from the rest of the body before the clones develop. If, as a result of rupture of the lens capsule, lens proteins leak into the anterior chamber, these are not recognized by the body's immune mechanisms, and an auto-immune inflammatory response is produced, which may be severe.

Tumours

Benign naevi frequently occur in both the iris and the choroid (Figs. 93b, 97b). Iris nodules are a common finding in neurofibromatosis.

Malignant melanomas of the iris and ciliary body (Figs. 93c, 94, 97a): Although iris tumours may show evidence of slow growth, it is usually unnecessary to consider surgical removal as their cellular pathology is

well differentiated and they very rarely metastasize or extend into adjacent ocular tissues. **Treatment**: If growth has been clearly documented and there is danger of the tumour growing into the ciliary body, removal of the tumour and the surrounding healthy iris is all that is required. Malignant melanomas of the ciliary body are much more aggressive and require urgent treatment. When the tumour has not spread to the choroid or through into the anterior chamber, localized removal may be considered (cyclectomy).

Malignant melanomas of the choroid see Chapter 12.

Secondary tumours: Carcinomatous deposits from the breast or lung may involve the uveal tract. In the majority of such cases death is likely to occur within a period of months, and enucleation should therefore not be performed. These tumours respond well to radiation therapy. Leukaemic deposits may also appear in the iris, and accumulations of leukaemic cells may detach, falling into the lower part of the anterior chamber, mimicking the appearance of an hypopyon.

Developmental abnormalities

Albinism: This may involve all the body tissues, or be confined to the eye itself (ocular albinism). The iris appears pink because of the absence of pigment, and examination of the retina reveals that the choroidal vessels stand out prominently owing to the absence of pigment in the retinal pigment epithelium. Patients have poor vision, often pendular nystagmus and marked photophobia.

Congenital colobomas of the iris: These are usually found in the inferonasal quadrant (Figs. 93d, 96a), and may sometimes be associated with colobomas of the ciliary body and choroid (Fig. 95). The cause is thought to be impaired closure of the fetal cleft in utero. **Differential diagnosis**: Full thickness iris defects (Fig. 96).

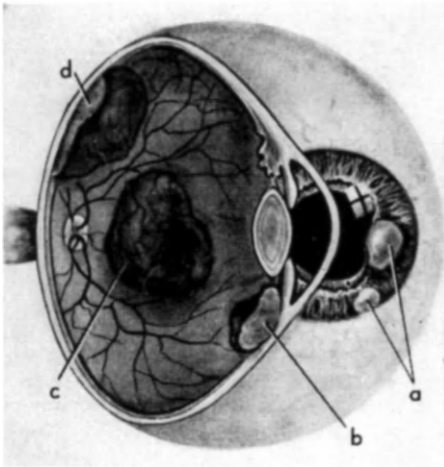


Fig. 94. Frequency of distribution of malignant melanomas of the uveal tract: a tumours of the iris 5 per cent; b tumours of the ciliary body 10 per cent; c tumours posterior to the equator 60 per cent; d tumours of the remaining parts of the uveal tract 25 per cent

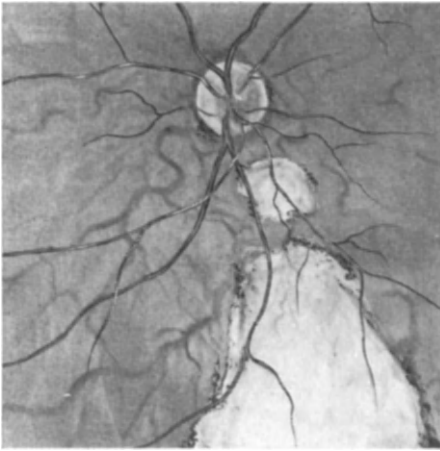


Fig. 95. Coloboma of the choroid

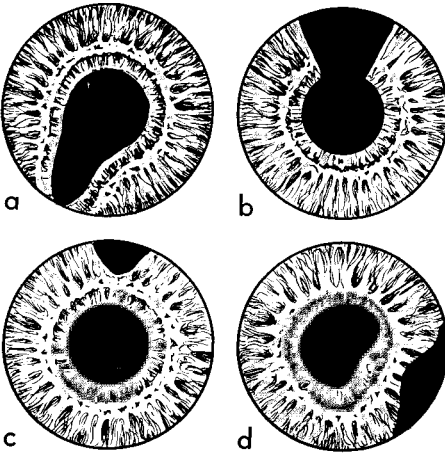


Fig. 96. Differential diagnosis of full thickness iris defects: **a** congenital iris coloboma (usually medial and inferior); **b** surgically performed total iridectomy; **c** surgically performed peripheral iridectomy; **d** traumatic tear in the iris (iridodialysis)

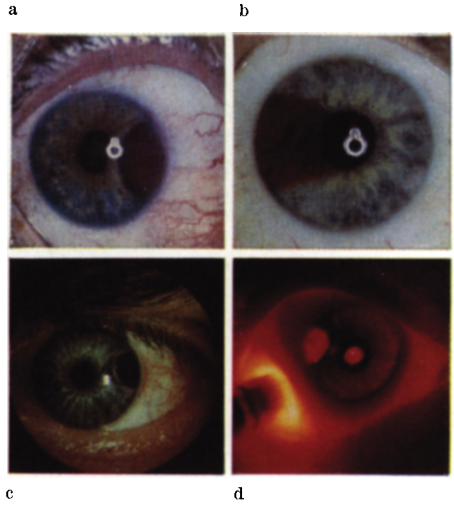


Fig. 97. **a** Malignant melanoma of the ciliary body extending into the anterior chamber; **b** iris melanoma; **c** iris cyst; **d** trans-illuminated iris cyst

Iris cysts are somewhat rare, congenital tumours, and are almost invariably benign (Fig. 97 c–d). Persistent pupillary membrane forms a network in front of the pupil; strands run between the iris and the anterior lens capsule. This condition occurs as a result of incomplete reabsorption of the fetal capillary vascular system, and has no other pathological significance.

Aniridia (absence of the iris): This is rarely complete, as examination of the iridocorneal angles shows remnants of iris tissue. Patients almost invariably develop glaucoma, which is extremely refractory to treatment. In some children aniridia is associated with a Wilm's tumour of the kidney.

Essential iris atrophy: This is a unilateral progressive condition, beginning not earlier than the third decade of life. The iris undergoes atrophy and becomes translucent, and secondary glaucoma is a frequent and serious complication.

Iridoschisis occurs in old age. There is atrophy of the iris stroma, and the anterior portion splits off from the posterior.

9. Pupil

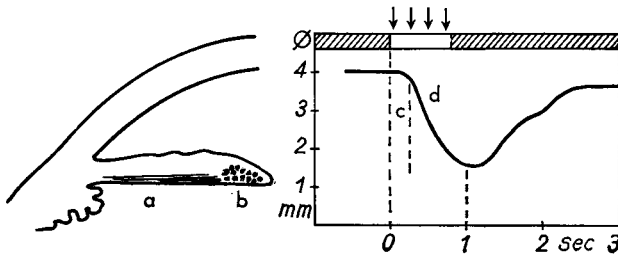


Fig. 98. Left: Muscles of the iris: a radiating dilator pupillae; b circular sphincter pupillae. Right: Pupillographic curve showing reaction to light: c latent time; d contraction time; Ordinate: width of pupil

General considerations

Dual nerve supply

Pupillary constriction: The parasympathetic nervous system activates the circular sphincter muscle of the pupil. **Pupillary dilatation** is brought about by contraction of the radiating dilator pupillary muscles supplied by the sympathetic nerve supply (Fig. 98, left).

Pupillary reflex pathways (Fig. 99)

Light reflex: Afferent arc: retina (a) → optic nerve (b) → optic chiasm (axons from nasal retina cross, axons from temporal retina remain uncrossed) (c) → optic tract (d) → just before the lateral geniculate body (f), the fibres subserving the light reflex leave the main body of afferent visual fibres (e) and synapse in the pretectal nuclei (h). This centre receives impulses from other sensory centres (k). Fifty per cent of the afferent light reflex fibres to cross the midline in the posterior commissure (g) to the opposite pretectal nucleus; the second order neuron passes to the pupilloconstrictor nucleus of Edinger-Westphal (i). The efferent pupillary parasympathetic nerves join with the somatic motor fibres of the 3rd nerve adjacent to the 3rd nerve nucleus in the brain-stem and, after leaving the mid-brain, are located initially on the medial side of this nerve (l) → ciliary ganglion (m) → ciliary nerves (n) → sphincter pupillae muscle (o). Rate of constriction of a normal pupil to light stimulation, see Fig. 98, right. **Sympathetic nervous system:** Hypothalamus → ciliospinal centre in the 8th cervical segment → sympathetic chain (p) → superior cervical ganglion (q) → sympathetic plexus of the internal carotid artery and thence on to the ophthalmic artery (r) → ciliary ganglion in the orbit (m) → ciliary nerves (n) → dilator pupillae muscle (s).

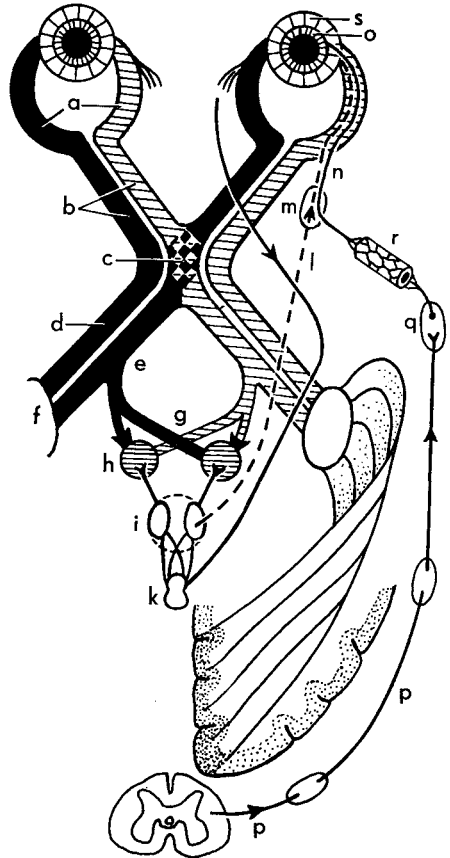


Fig. 99. Diagram of pupillary pathways (see text)

Near reflex pathway: Visual fibres from retina → occipital cortex. Efferent nerve fibres follow the same pathways as those concerned with occipital control of extra-ocular movements (following and fixation reflexes, see Chapter 19) → Edinger-Westphal nucleus → pathway as for a parasympathetic pupillary light reflex.

Pupillary disorders

Differences in size of the two pupils are due to **efferent** pupillary defects or to **local iris** pathology. Pupils are always equal in size in lesions of the afferent pupillary pathways. This is because an equal number of fibres project to both sides of the brain-stem. Accordingly, the direct light reflex and the consensual (reaction of the opposite pupil) light reactions are of equal amplitude in a healthy individual. In patients with a massive retinal lesion or an optic nerve defect (on looking into the distance to avoid accommodation miosis), a bright light shone into the uninvolved eye causes a brisk direct and consensual reflex. Transferring the light to the eye with a lesion of the retina or optic nerve causes the pupil to dilate against the light (swinging flashlight test).

Miosis (constricted pupil) occurs in bright illumination, in sleep, in old age, in forced lid closure and as a result of miotic therapy. The iris is also constricted in iritis, pontine brain-stem or cervical sympathetic chain lesions, morphine addiction, etc.

Mydriasis (dilated pupil) occurs in poor illumination, following emotional stimuli

or pain, after the administration of mydriatics, in 3rd nerve disturbances (raised intracranial pressure with tentorial coning), toxic and infective conditions, e.g. botulism, diphtheria.

Other acquired pupillary defects

Argyll-Robertson pupil is characterized by the absence of pupillary response to photic stimulation, although the near reaction is unimpaired. There is miosis, iris atrophy, an irregular pupil margin and poor dilatation of the pupils to mydriatics. The condition is an important sign in tertiary syphilis. The exact site of the lesion or lesions responsible for an Argyll-Robertson pupil remains controversial.

Absolutely fixed pupil: The direct, consensual and near reflex responses are all absent. **Aetiology:** Lesions of Edinger-Westphal nucleus, of the third oculomotor nerve or the ciliary ganglion. Fixed pupils also occur following bulbar contusion injuries (due to rupture of the sphincter pupillae), in acute angle closure glaucoma (because the blood supply to the iris has become impaired) and as a result of miotic or mydriatic drops being instilled into the conjunctival sac. The pupils become unreactive after death.

Tonic pupil: There is unilateral mydriasis (a) (Fig. 100, left), an extremely sluggish pupillary response to light and dilatation in the dark (b) and delayed, but definite, near reflex response (c). Dilation of the pupil

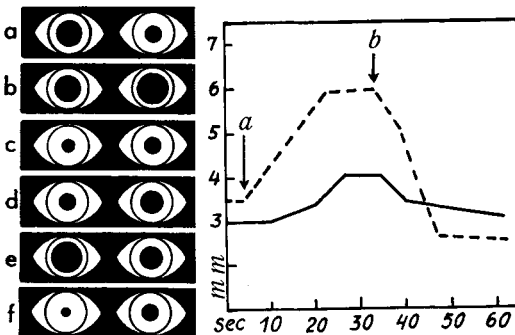


Fig. 100. Left: Tonic pupil of right eye (Adie's syndrome) (see text). Right: Pharmacological test in a case with a tonic pupil (----- left eye with tonic pupil; ——— right eye with normal response). a Instillation of 2 per cent cocaine eye drops; b instillation of 0.1 per cent pilocarpine eye drops

when looking again into the distance is slow (d). Vermiform movements of the edge of the pupil are a regular feature on slit lamp examination. The pupil shows further dilatation after the instillation of cocaine drops (Fig. 100e) and marked meiosis with weak concentrations of pilocarpine (Fig. 100f). **Aetiology:** A localized inflammatory lesion at the level of the ciliary ganglion. The condition usually resolves spontaneously. In some patients absent knee and ankle jerks are a feature (Adie's syndrome).

Pharmacology

Drugs affecting the parasympathetic system:

As adrenergic and cholinergic actions of drugs are mutually antagonistic, comparable effects result from inhibition of one (lytic effect) or stimulation of the other (mimetic effect). Drugs are classified according to whether they act directly on the sphincter receptors (direct acting) or inhibit destruction or cause liberation from nerve endings of natural effector chemicals (indirect acting).

Parasympathomimetics induce pupillary constriction (meiosis). Direct acting or cholinergic agents include acetylcholine, carbachol and pilocarpine. Indirect acting drugs which have a reversible action are eserine and edrophonium, and those with

an irreversible action include echothiophate and isofluorophate.

Parasympatholytics induce mydriasis: atropine sulphate 1 per cent as a solution (drops) or ointment paralyzes accommodation for about 10 days and is the best medication for inducing cycloplegia to assay refractive errors in squinting children. Scopolamine 0.5 per cent causes accommodation paralysis for 4-6 days, and homatropine 1 or 2 per cent for 1 or 2 days. Short acting mydriatics, including cyclopentolate, interfere with accommodation for approximately 12 hours. *Drugs affecting the sympathetic system:* **Sympathomimetics** induce mydriasis, and are administered as eye drops, or may be injected subconjunctivally. Direct acting agents include epinephrine and phenylephrine. Indirect acting agents are ephedrine and cocaine, which is also a potent mucous membrane anaesthetic. **Sympatholytic** drugs cause miosis: guanethidine, dibenzylamine and tolazoline.

Diagnostic mydriasis: In order to observe the fundus, short acting sympathomimetics or mild parasympatholytics, which do not cause accommodation paralysis for long periods of time, are administered. In using these drugs, however, there is a slight risk of inducing attacks of angle closure glaucoma, particularly if the anterior chamber is narrow.

10. Anterior Chamber and Glaucoma

General considerations

Intra-ocular pressure is normally maintained at between 10 and 20 mm Hg (average pressure 15 mm Hg). Glaucoma is defined as a state in which there is a raised intra-ocular pressure, resulting in damage to intra-ocular structures. If the pressure is elevated beyond 21 mm Hg, glaucoma should be suspected, but where the intra-ocular pressure is between 21 and 30 mm Hg and investigations show no evidence of

intra-ocular changes the term "ocular hypertension" is often employed. The intra-ocular pressure is subject to diurnal fluctuations of the order of about 4 mm Hg, often peaking in the morning and being lowest in the afternoon. Raised intra-ocular pressure is mainly due to decreased drainage, rather than to increased production of aqueous.

Aqueous humour (Figs. 101a, 102): A secretion of the ciliary body epithelium (rate approximately 2 μ l/min). The aqueous passes between the suspen-

when looking again into the distance is slow (d). Vermiform movements of the edge of the pupil are a regular feature on slit lamp examination. The pupil shows further dilatation after the instillation of cocaine drops (Fig. 100e) and marked meiosis with weak concentrations of pilocarpine (Fig. 100f). **Aetiology:** A localized inflammatory lesion at the level of the ciliary ganglion. The condition usually resolves spontaneously. In some patients absent knee and ankle jerks are a feature (Adie's syndrome).

Pharmacology

Drugs affecting the parasympathetic system:

As adrenergic and cholinergic actions of drugs are mutually antagonistic, comparable effects result from inhibition of one (lytic effect) or stimulation of the other (mimetic effect). Drugs are classified according to whether they act directly on the sphincter receptors (direct acting) or inhibit destruction or cause liberation from nerve endings of natural effector chemicals (indirect acting).

Parasympathomimetics induce pupillary constriction (meiosis). Direct acting or cholinergic agents include acetylcholine, carbachol and pilocarpine. Indirect acting drugs which have a reversible action are eserine and edrophonium, and those with

an irreversible action include echothiophate and isofluorophate.

Parasympatholytics induce mydriasis: atropine sulphate 1 per cent as a solution (drops) or ointment paralyzes accommodation for about 10 days and is the best medication for inducing cycloplegia to assay refractive errors in squinting children. Scopolamine 0.5 per cent causes accommodation paralysis for 4-6 days, and homatropine 1 or 2 per cent for 1 or 2 days. Short acting mydriatics, including cyclopentolate, interfere with accommodation for approximately 12 hours. *Drugs affecting the sympathetic system:* **Sympathomimetics** induce mydriasis, and are administered as eye drops, or may be injected subconjunctivally. Direct acting agents include epinephrine and phenylephrine. Indirect acting agents are ephedrine and cocaine, which is also a potent mucous membrane anaesthetic. **Sympatholytic** drugs cause miosis: guanethidine, dibenzylamine and tolazoline.

Diagnostic mydriasis: In order to observe the fundus, short acting sympathomimetics or mild parasympatholytics, which do not cause accommodation paralysis for long periods of time, are administered. In using these drugs, however, there is a slight risk of inducing attacks of angle closure glaucoma, particularly if the anterior chamber is narrow.

10. Anterior Chamber and Glaucoma

General considerations

Intra-ocular pressure is normally maintained at between 10 and 20 mm Hg (average pressure 15 mm Hg). Glaucoma is defined as a state in which there is a raised intra-ocular pressure, resulting in damage to intra-ocular structures. If the pressure is elevated beyond 21 mm Hg, glaucoma should be suspected, but where the intra-ocular pressure is between 21 and 30 mm Hg and investigations show no evidence of

intra-ocular changes the term "ocular hypertension" is often employed. The intra-ocular pressure is subject to diurnal fluctuations of the order of about 4 mm Hg, often peaking in the morning and being lowest in the afternoon. Raised intra-ocular pressure is mainly due to decreased drainage, rather than to increased production of aqueous.

Aqueous humour (Figs. 101a, 102): A secretion of the ciliary body epithelium (rate approximately 2 μ l/min). The aqueous passes between the suspen-

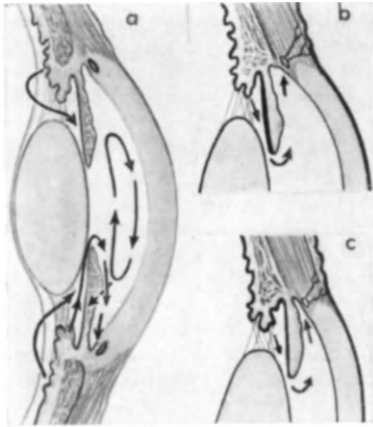


Fig. 101. a Aqueous drainage with convection current in anterior chamber; b open anterior chamber angle; c narrow anterior chamber angle

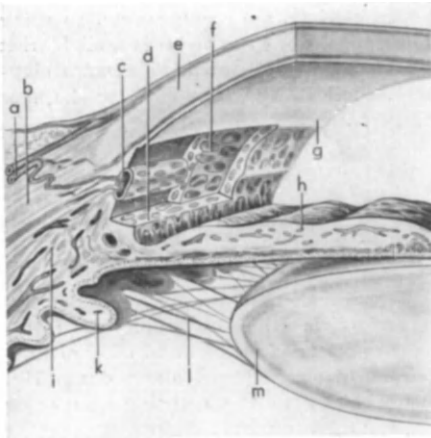


Fig. 102. Anterior chamber angle and surrounding structures. a aqueous veins; b sclera; c Schlemm's canal; d ciliary body; e cornea; f trabecular meshwork; g Schwalbe's line (denoting end of corneal endothelium); h iris; i ciliary muscle; k ciliary processes; l zonule; m lens

sory ligaments of the lens → through the pupil → anterior chamber, where it circulates due to convection currents (the iris is warmer than the cornea which is exposed to the outside air) → corneoscleral trabecular meshwork (Fig. 105) → Schlemm's canal → 20–30 aqueous veins → episcleral veins, which contain both blood and aqueous (Fig. 103, below).

Anterior chamber angle (iridocorneal angle) is obscured by the overhanging corneoscleral junction and only made visible by using a gonio contact lens (Fig. 103, above). The iridocorneal angle is made more acute as the lens enlarges and/or the iris root is pushed towards the peripheral cornea. Iridocorneal contact causes angle closure glaucoma (Fig. 104, below right). Aqueous outflow is also impeded by the development of peripheral synechiae following iritis (Fig. 104, above 3), if pores in the trabecular meshwork are narrowed following sclerotic changes (primary open angle glaucoma), in lens-induced glaucoma where macrophages carrying lens material get stuck in the trabecular meshwork or after severe haemorrhage in the anterior chamber following trauma (see Chapter 16).

Measurement of intra-ocular pressure (tonometry) is normally carried out using a Goldmann applanation tonometer. The cornea

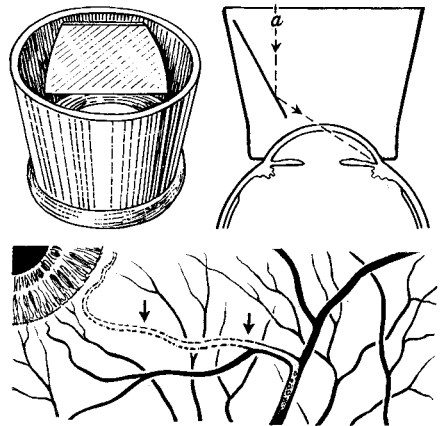


Fig. 103. Above: Gonioscopic lens seen from above and in cross-section; a path of observation. Below: Aqueous vein

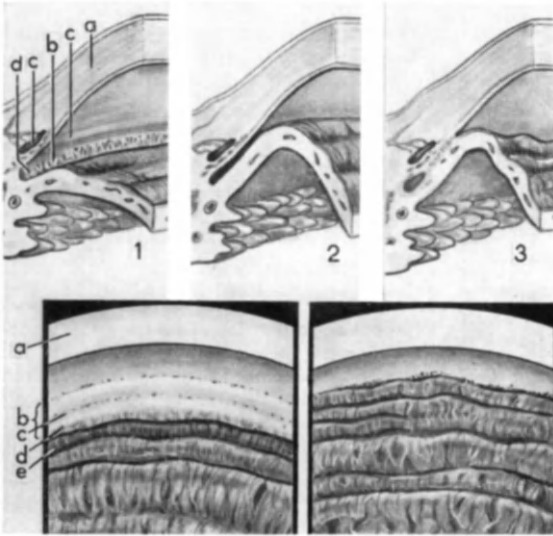


Fig. 104. Above: Cross-section of anterior chamber angle. 1 Normal; 2 narrow anterior chamber angle; only a part of the trabecular meshwork is visible gonioscopically; 3 anterior synechiae; the flow of aqueous into Schlemm's canal is impaired. Below: Wide (left) and narrow (right) anterior chamber angles viewed gonioscopically. a Cornea; b trabeculum; c Schlemm's canal; d ciliary body; e root of iris

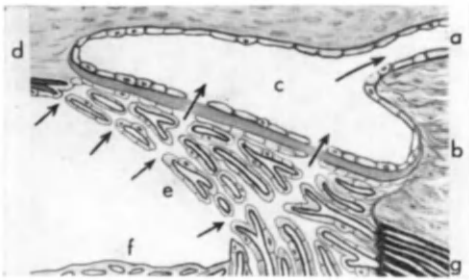


Fig. 105. Trabecular meshwork, Schlemm's canal and aqueous veins in schematic presentation: a aqueous veins; b sclera; c Schlemm's canal; d cornea; e trabecular meshwork; f iris; g ciliary muscle

is flattened by a small flat disc attached to a tension spring. The harder the eyeball, the more tension is required to achieve a standard area of flattening. Intra-ocular pressures may also be determined by means of a Schiötz tonometer (Fig. 106a). The cornea is indented by a plunger and the

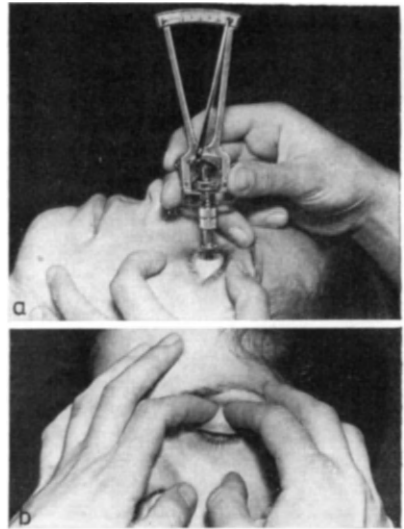


Fig. 106. a Measurement of intra-ocular pressure with a Schiötz tonometer; b estimating intra-ocular pressure by palpation

softer the eyeball, the deeper the plunger will indent the cornea. Applanation tonometry is the more accurate method of assessing intra-ocular pressures, as with in-

dentation tonometry assumptions have to be made concerning the rigidity of the ocular coats which are not always valid. Local anaesthetic agents are applied to the cornea before tonometry is carried out.

Tonography is the study of aqueous outflow dynamics. A fixed weight (indentation tonometer) is applied to the cornea for a period of several minutes, during which time the aqueous humour is forced out of the eye, owing to the elevation of the intra-ocular pressure. Pressure recordings taken during the period of time that constant weight is applied provide an indication of the resistance of outflow of aqueous humour (Fig. 107). This technique has been used as an early diagnostic test for open angle glaucoma, and to determine the extent of iridocorneal contact remaining after medical treatment of angle closure glaucoma (Fig. 108).

A very rough estimation of intra-ocular pressure can be made by palpation (Fig. 106b). The patient looks down and the ex-

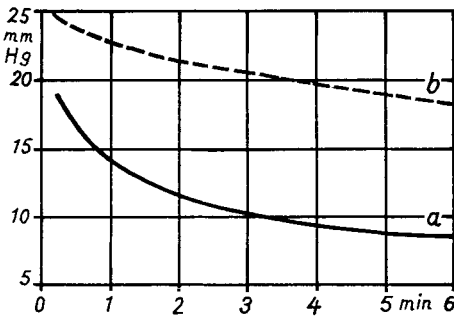


Fig. 107. Tonography curve: a normal; b glaucoma with increased resistance to outflow

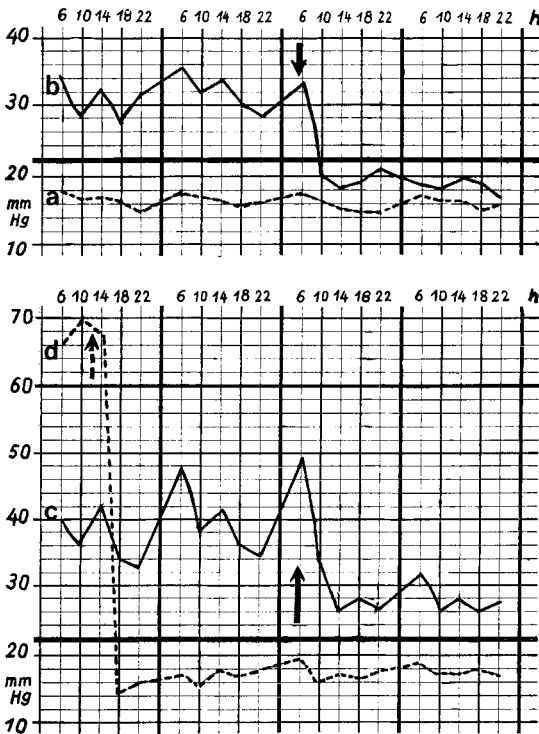


Fig. 108. Intra-ocular pressure recordings over 4 days: a normal; b open angle glaucoma; c chronic closed angle glaucoma; d acute glaucoma attack. ↓ Start of treatment

miner palpates the globe through the upper lid, using both index fingers and comparing it with the other eye. Accuracy better than 10 mm Hg cannot be achieved even by an experienced examiner.

Primary glaucomas

Chronic open angle glaucoma

Chronic open angle glaucoma is characterized by defective drainage of aqueous humour through the anterior chamber angle, which, on gonioscopic examination, shows no narrowing or other abnormal features.

Incidence: Occurs in approximately 2 per cent of the population from the fourth decade of life onwards, and the main feature is **progressive**, but **painless**, loss of visual fields. In the initial stages the diurnal variations of intra-ocular pressure are increased. Later the intra-ocular pressures become permanently raised up to 50 mm Hg. The condition may remain undiagnosed for many years owing due to the preservation of central vision, slow constriction of the visual fields and absence of pain. During this period, however, the optic disc becomes excavated and undergoes atrophy, and the visual fields, once lost, cannot be restored.

Pressure recordings should be performed on all patients over the age of 40 attending for an ocular examination, and fundus inspection should be carried out about every 2 years.

Provocative tests: In patients found to have raised intra-ocular pressure, or suspected glaucomatous cupping of the disc, provocative tests may be performed. **Water drinking test:** The patient is required to drink 1 litre of water in 5 minutes. Intra-ocular pressure recordings are then taken during the following hour, and a rise in pressure of 8 mm Hg confirms that the resistance to aqueous outflow is at a pathological level.

Field changes: If the intra-ocular pressure is allowed to remain at a pathological level, arcuate visual field defects develop (Fig. 109) in both the superior and inferior fields.

These extend out towards the periphery, giving rise to peripheral field loss. Later, only central vision remains, albeit with good visual acuity (gun-barrel vision). Finally, central vision is lost and the patient becomes totally blind. Fundus examination in an early case of open angle glaucoma

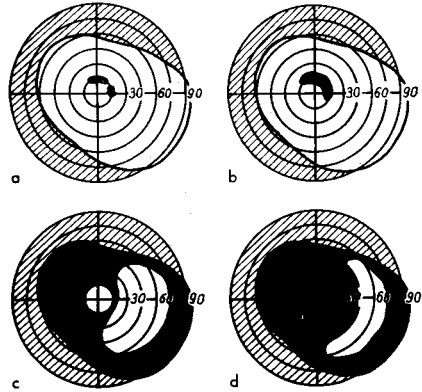


Fig. 109. Progression of visual field loss in open angle glaucoma. a Extension of blind spot; b arcuate scotoma; c nasal visual field defect with central island of vision remaining; d temporal remnant of visual field

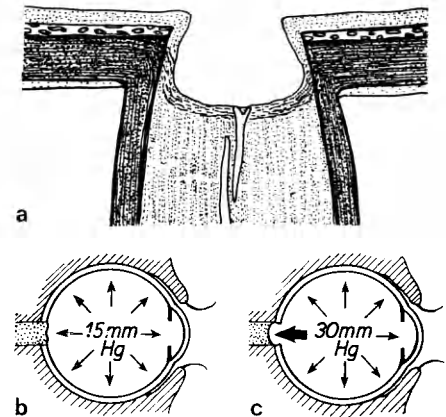


Fig. 110. Glaucomatous cupping. a Cross-section; b effect of increased pressure

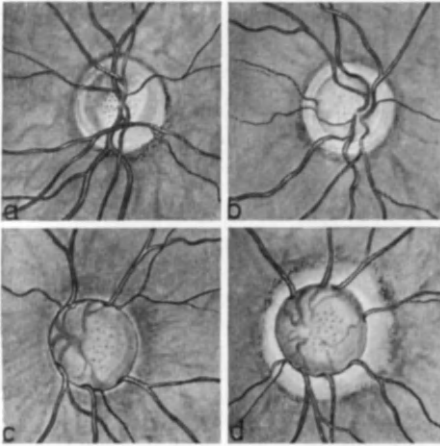


Fig. 111. Cupping of the optic disc. Physiological: a shallow excavation; b larger excavation. Pathological: c cupping extends to the edge of the disc; vessels are sharply kinked; d glaucomatous halo

reveals nasal displacement of the vessels (Fig. 111 c-d); the disc is initially cupped nasally, but later the whole circumference becomes involved. Optic atrophy develops, the apertures in the cribriform plate become apparent, and a glaucomatous halo may appear (pressure atrophy of the choroid). **Aetiology:** Open angle glaucoma is often familial. Cupping of the optic disc and field loss are probably due to raised intra-ocular pressure compressing the pressure-sensitive blood vessels supplying the optic nerve head, with subsequent atrophy of neurons and supporting glia. **Treatment:** In patients where the intra-ocular pressure is found to be above 30 mm Hg, there is evidence of glaucomatous cupping or visual field defects, the intra-ocular pressure should be lowered to less than 20 mm Hg (Fig. 108 b). The main treatment for open angle glaucoma is the use of agents which, by increasing the tone in the longitudinal fibres of the ciliary body, probably cause the apertures in the trabecular meshwork to open, and thereby reduce the resistance to aqueous outflow. Effective lowering of the intra-ocular pressure to below 20 mm Hg

throughout the day arrests the visual field changes in the large majority of cases. Initially, the patient is started on 1 per cent pilocarpine drops, which are instilled into the conjunctival sac four times a day (the effect of pilocarpine, which is normally well tolerated by the patient, lasts for approximately 4-5 hours). If the desired lowering of intra-ocular pressure is not achieved, then 2, 3 up to 6 per cent concentration of pilocarpine drops may be employed. Reduced secretion of the ciliary epithelium is achieved by using carbonic anhydrase inhibitors: acetazolamide orally in doses ranging from 125 mg twice a day to 250 mg four times a day. Epinephrine is also of value, since this drug reduces secretion from the ciliary body, increases the facility of outflow and counteracts the miotic action of pilocarpine. A prolonged pharmacological effect is produced by cholinesterase inhibitors, which inhibit the breakdown of acetylcholine, and thus reinforce parasympathetic action, but over a prolonged period of time these tend to produce iris cysts.

Complications of miotic therapy: The use of miotics initially causes injection of the conjunctiva, ciliary pain due to ciliary spasm and, in older patients with central lens opacities, a reduction in visual acuity. The patient's pupils are unable to dilate in dim illumination, so that night driving is difficult, and refraction may be made more myopic. **Adrenaline-related drugs (Eppy) should not be used if there is a narrow irido-corneal angle,** or if the patient has a history of angina or cardiac infarction. Side-effects of acetazolamide include tingling of the extremities of the limbs, loss of appetite, potassium depletion and, occasionally, renal calculi.

Surgical treatment, when medical therapy has failed, see below.

Acute angle closure glaucoma

Acute angle closure glaucoma occurs mainly in the over 60 age group; males and females are equally affected. During life the crys-

talline lens gradually increases in size, so that in small volume (hypermetropic) eyes, the anterior chamber angle becomes progressively narrowed and the iris bowed forwards. A slightly increased pressure in the posterior chamber is required to force aqueous between the forward displaced iris and the lens into the pupillary aperture. Under conditions of dim illumination the pupil is semi-dilated and the iris root lax. The iris root then becomes bowed forwards and comes into contact with the back of the cornea. Contact with the iris root over the whole circumference effectively prevents aqueous humour getting to the drainage meshwork, so that the intra-ocular pressure rises.

Prodromal symptoms: Iridocorneal contact causes a rise of intra-ocular pressure in patients about to develop an acute angle closure attack, and the cornea becomes oedematous because the endothelium is unable to keep the cornea in a dehydrated state. Refraction rays of light in the water clefts so formed in the cornea are perceived by the patient as haloes around lights. However, the attack may abort if the pupil miosis in response to brighter levels of illumination, as the iris root is then dragged away from the cornea and aqueous drainage becomes re-established. During sleep angle closure attacks do not occur because the pupil constricts.

Provocative tests: **Mydriatic test:** Dilatation of pupils in patients liable to develop angle closure glaucoma may result in a rise of pressure in excess of 8 mm Hg in 1 hour, because of iris bunching into the angle thereby occluding aqueous outflow. **Prone provocative test:** The patient is requested to lie face down for 1 hour so that the lens iris diaphragm moves forwards. In susceptible cases the angle is occluded, and pressure rises of more than 8 mm Hg indicate a positive test.

Acute angle closure attack: Eventually iridocorneal contact does not resolve spontaneously. Under these circumstances the intra-ocular pressure may rise to as high as 80 mm Hg, and the classic features of acute

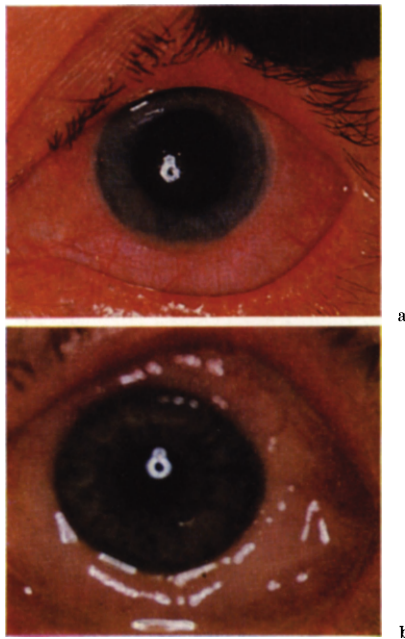


Fig. 112. a Acute angle closure glaucoma; b acute epidemic keratoconjunctivitis

angle closure glaucoma develop, consisting of ocular pain and severe headache, which may be accompanied by nausea and vomiting, thereby mimicking a gastro-intestinal emergency. The cornea becomes oedematous and opaque (Fig. 112a) and vision is severely impaired; the anterior chamber is shallow, and the pupil semi-dilated, irregular and fixed. Pupil changes occur as a result of iris ischaemia induced by the pressure rise. If the intra-ocular pressure is allowed to remain above the perfusion pressure of the retina for any length of time, retinal ischaemic changes also develop, with permanent loss of vision. Examination of the other eye will reveal a narrow anterior chamber and, on gonioscopic examination, an acute iridocorneal angle. The conjunctival and ciliary vessels of the eye with acute glaucoma are injected, and palpation of the eye shows this to be stony hard. For

Table 2. Differential diagnosis between acute glaucoma, acute iritis and acute conjunctivitis

	Acute glaucoma	Acute iritis	Acute conjunctivitis
Symptoms	Sudden onset; severe pain referred to region of temples, back of head or teeth; associated with nausea and sometimes vomiting	Gradual onset; slight pain – constant dull ache; photophobia	Gradual onset; discomfort; foreign body sensation; photophobia
Visual acuity	Much reduced	Slightly or moderately reduced	Normal
Intra-ocular pressure	High (eyeball is stony hard)	Normal or reduced; very occasionally increased	Normal
Conjunctival vessels	Congestive hyperaemia	Mixed or ciliary injection	Conjunctival injection
Cornea	Oedematous, loss of transparency	Keratic precipitates	No signs
Anterior chamber	Shallow	Normal depth	Normal depth
Pupil reaction to light	Fixed to light, dilated and irregular	Miosed; sluggish	Normal
Iris structure	Faded	Faded	Normal
View of retina	Not seen	Misty view	Normal

differential diagnosis with acute iritis, see Table 2.

Treatment: A patient with an attack of acute glaucoma must immediately be referred to an eye unit for treatment. Initial treatment is **medical:** Acetazolamide 500 mg is given intramuscularly or intravenously to reduce the secretion from the ciliary body. Pilocarpine 4 per cent is instilled at 10-minute intervals for 1 hour into the glaucomatous eye to attempt to reopen the iridocorneal angle. Pilocarpine 1 per cent four times a day should be instilled into the other eye to prevent an angle closure attack developing in this eye as well. If the pressure cannot be reduced on this regime, oral glycerol (1.5 g/kg body weight) is given with lemon juice to lower the intra-ocular pressure by virtue of its osmotic effect. Alternatively, in nauseous or vomiting patients 20 per cent mannitol, 250–500 ml infused intra-

venously, will normally produce the same effect. Providing the intra-ocular pressure becomes controlled (Fig. 108d), the patient should be continued on gutt. Pilocarpine 4 per cent four times a day and the eye allowed to settle for 3 or 4 days, at the end of which time a peripheral iridectomy (see Fig. 96c) or broad iridectomy (Figs. 96b, 116, above) is performed, thus allowing aqueous humour to enter the anterior chamber from the posterior chamber without passing through the pupil. The iris root cannot now bow forwards to block the anterior chamber angle, and, providing there are no residual adhesions between the iris and the cornea, the intra-ocular pressure will not become re-elevated. Prophylactic iridectomy should be performed on the other eye, since 50 per cent of patients, even if maintained on miotics, develop an angle closure attack within 5 years. After the cornea has

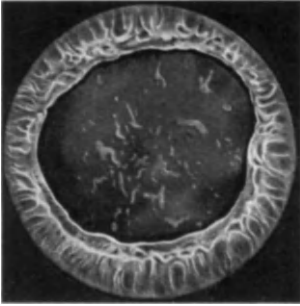


Fig. 113. Glaucomatous subcapsular lens opacities

cleared, anterior subcapsular lens opacities are frequently noted, produced by the effects of pressure on the lens fibres (Fig. 113).

Chronic closed angle glaucoma

If treatment is delayed in patients with acute angle closure glaucoma, permanent adhesions between the iris and the cornea form (peripheral anterior synechiae). Peripheral anterior synechiae may also develop in patients with numerous incipient attacks of acute angle closure glaucoma which abort. Intra-ocular pressure becomes permanently raised, but there is usually little or no pain, and the ocular changes occurring are identical to those described in open

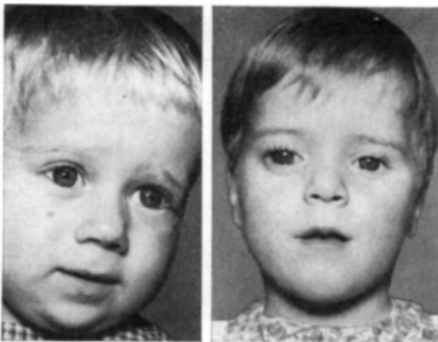

Fig. 114. Children with buphthalmos

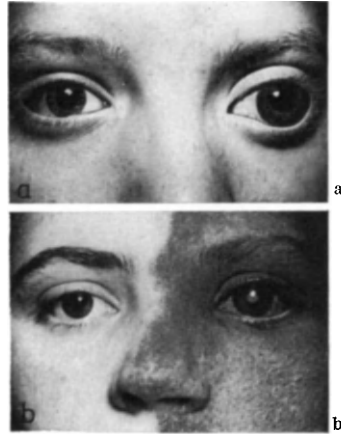

Fig. 115. a Buphthalmos; b cavernous haemangioma of the face; Sturge-Weber syndrome

angle glaucoma, i.e. cupping of disc and progressive peripheral visual field loss. The initial treatment consists of miotic therapy as for chronic open angle glaucoma (Fig. 108c).

Surgical treatment of chronic closed angle glaucoma and chronic open angle glaucoma which have not responded to medical therapy

Filtering operations: A track is opened up between the anterior chamber and the subconjunctival space so that the aqueous humour drains beneath the conjunctiva. **Elliott's operation** (Figs. 116, below, 117a) is performed by trephining a round hole 1.8 mm in diameter approximately at the corneoscleral junction after reflecting the conjunctiva, which is then sewn back in position. **Iridencleisis** is an operation in which part of the iris is drawn up into the limbal incision to act as a wick to promote flow of aqueous humour from the anterior chamber into the subconjunctival space (Fig. 118a, b). In a **trabeculectomy** operation a portion of the trabecular meshwork is

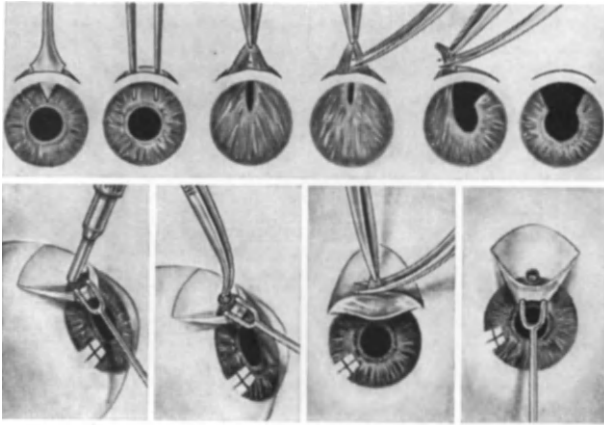


Fig. 116. Above: Total iridectomy (the oldest surgical treatment of glaucoma), showing opening of the anterior chamber, pulling out the iris with forceps and cutting the iris with two scissor cuts. Below: Elliot's trephine operation, showing trephining of tissue in the limbal area, peripheral iridectomy and replacement of conjunctival flap

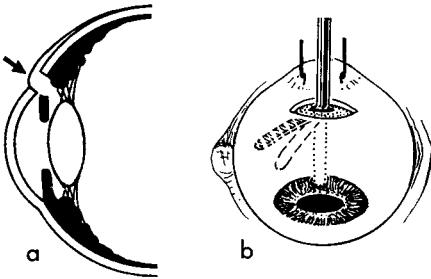


Fig. 117. a Trephine operation (diagrammatic view); b cyclodialysis (detachment of ciliary body using a spatula)

excised, allowing aqueous to filter through the superficial layers of the sclera (Fig. 118d, e) and into the cut ends of the canal of Schlemm.

Other operations

Trabeculotomy consists of inserting a probe into Schlemm's canal and rupturing the trabecular meshwork, which may have become sclerosed (Fig. 118c). This operation is not effective in chronic closed angle glaucoma.

Cyclodialysis (detachment of the ciliary body) is performed primarily in cases of aphakic glaucoma. A track is made be-

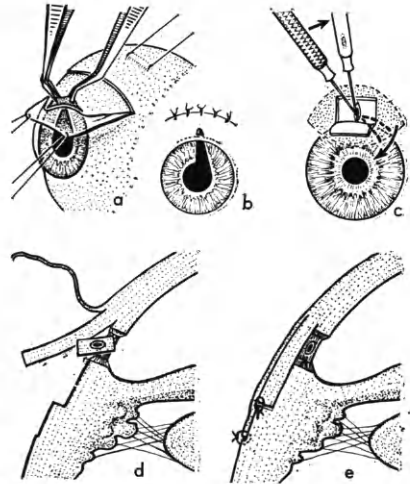


Fig. 118. Microsurgical techniques in the treatment of glaucoma. a-b Iridenleisis; c trabeculotomy; d-e trabeculectomy

tween the detached ciliary body and the anterior chamber, so that aqueous can drain into the suprachoroidal space (Fig. 117b). **Cyclocryosurgery** or **cyclodiathermy** is used to destroy the secretory epithelium of the ciliary body, thus reducing aqueous humour formation.

Secondary glaucomas

Secondary glaucomas occur secondary to other ocular diseases or injuries which cause an obstruction to aqueous outflow. **Secondary open angle glaucoma** may be induced in susceptible individuals following prolonged topical steroid therapy, by blockage of the trabecular meshwork pores with blood, turbid aqueous (for example in iritis), after rupture of the lens capsule (when macrophages enter the anterior chamber, phagocytose lens material and then become stuck in the trabecular meshwork), as a feature of concussive injuries (in which the ciliary body becomes recessed and the trabecular meshwork ruptured), in neovascular glaucoma arising as a complication of ischaemic lesions of the retina (diabetic angiopathy, central retinal vein thrombosis) in which a fibrovascular sheet grows across the iridocorneal angle, blocking aqueous drainage, and after obstruction of the aqueous veins by subconjunctival fibrosis as a result of chemical burns, etc.

Secondary closed angle glaucoma: Peripheral anterior synechiae may develop as a result of iritis, after delayed re-formation of the anterior chamber following intra-ocular surgical procedures as a result of the pupil becoming bound down to the anterior lens capsule or the vitreous face after cataract extraction. **Treatment** is directed towards the underlying cause.

Malignant glaucoma: Defined as a dramatic rise of intra-ocular pressure following glaucoma surgery. The lens probably becomes trapped by the engorged ciliary body, so that flow of aqueous from the posterior to the anterior chamber is obstructed, and the lens iris diaphragm is pushed forwards. **Treatment:** Full dilatation of the pupil and relaxation of the ciliary musculature by powerful mydriatics and cycloplegics. If this fails, lens extraction may be necessary to relieve the block.

Congenital glaucomas

Congenital glaucoma is a common cause of blindness in infants and young children.

Aetiology: In the majority of cases this is due to a developmental abnormality of the anterior chamber formation associated with a persistent membrane stretched across the angle which prevents aqueous coming into contact with the trabecular meshwork and Schlemm's canal. The condition is often familial, and may be unilateral or bilateral. Congenital glaucoma is a feature of Rubella and Sturge-Weber syndromes (Fig. 115b), though adventitious membranes are not usually present in these cases. In young children the ocular coats respond to raised intra-ocular pressure by expanding, giving rise to enlarged eyes (buphthalmos, Figs. 114, 115a). The corneal endothelium is stretched and ruptured, thus permitting fluid to enter the corneal stroma with subsequent loss of transparency. The anterior chamber is deep, and glaucomatous optic disc atrophy occurs. The child is photophobic, often miserable, irritable and continually rubbing the eyes and lacrimating profusely. Ocular examination of children with suspected congenital glaucoma should be performed under general anaesthesia, so that the intra-ocular pressures can be measured accurately and obstructions to the drainage of aqueous treated. **Treatment: Goniotomy:** A

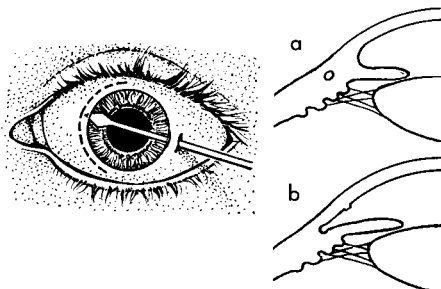


Fig. 119. Goniotomy (the gonioscope required for the operation is not shown). a-b Anterior chamber angle before and after goniotomy in buphthalmos

sharp pointed needle is introduced into the anterior chamber from the temporal side and membranes occluding the trabecular meshwork are ruptured by sweeping the tip

of the needle in a clockwise and an anti-clockwise direction (Fig. 119). More rarely, drainage procedures need to be performed to control the intra-ocular pressure.

11. Vitreous

General considerations

The vitreous cavity occupies two-thirds of the volume of the eyeball, and the vitreous gel consists of a collagen fibril matrix linked together by hyaluronic acid molecules, through which aqueous humour percolates. No blood vessels or nerves are present, except occasional residual traces of the hyaloid artery. The vitreous is firmly attached to the posterior part of the ciliary body at the ora serrata (vitreous base) and in the region of the optic nerve.

Diseases of the vitreous

In old age, or earlier in patients with severe myopia, fluid-filled cavities form in the vitreous, and the posterior vitreous face separates from the retina. Adhesions between the vitreous and the retina, formed as a result of inflammation, etc., may, following vitreous retraction, produce breaks in the retina leading to retinal tears (Fig. 120). *Vitreous floaters* are generally fine opacities consisting of aggregations of condensations of vitreous. The patient is aware of these as spots, rings or clouds appearing in front of the eye. Because of this they are sometimes referred to as *muscae volitantes* (flying flies). Vitreous floaters are identified on slit lamp or ophthalmoscopic examination in a transmitted light, and, if there is no evidence of retinal detachment developing, no further problems are to be anticipated or treatment required. **Synchysis scintillans** is a term given to glistening crystals (usually consisting of cholesterol and calcium) floating freely in the vitreous. Vitreous opa-

cities may also develop when cells enter the vitreous as a result of iridocyclitis or choroïdoretinitis.

Vitreous haemorrhages occur in association with vasoproliferative retinopathies, e.g. diabetic retinopathy, retinal vein thrombosis, retrolental fibroplasia and sickle cell trait. Retinal vessels are often ruptured when vitreous traction tears a hole in the retina. Vitreous haemorrhages are also a feature of blood dyscrasias, and follow blunt or penetrating ocular injuries.

Vitreous abscesses usually develop as a result of infection following perforating injuries or intra-ocular surgery.

The vitreous is normally adherent to the posterior capsule of the lens until the age

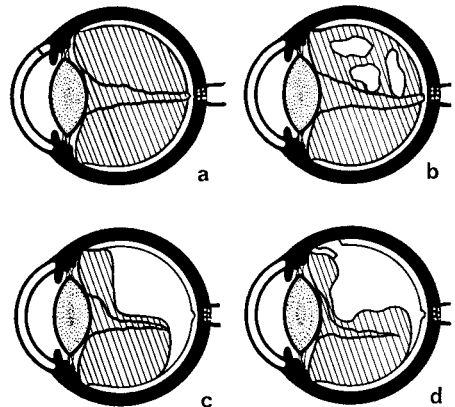


Fig. 120. Development of posterior vitreous detachment and a retinal tear: a normal vitreous with Cloquet's canal; b cavities in the vitreous; c posterior detachment of the vitreous; d retinal tear caused by vitreous traction

sharp pointed needle is introduced into the anterior chamber from the temporal side and membranes occluding the trabecular meshwork are ruptured by sweeping the tip

of the needle in a clockwise and an anti-clockwise direction (Fig. 119). More rarely, drainage procedures need to be performed to control the intra-ocular pressure.

11. Vitreous

General considerations

The vitreous cavity occupies two-thirds of the volume of the eyeball, and the vitreous gel consists of a collagen fibril matrix linked together by hyaluronic acid molecules, through which aqueous humour percolates. No blood vessels or nerves are present, except occasional residual traces of the hyaloid artery. The vitreous is firmly attached to the posterior part of the ciliary body at the ora serrata (vitreous base) and in the region of the optic nerve.

Diseases of the vitreous

In old age, or earlier in patients with severe myopia, fluid-filled cavities form in the vitreous, and the posterior vitreous face separates from the retina. Adhesions between the vitreous and the retina, formed as a result of inflammation, etc., may, following vitreous retraction, produce breaks in the retina leading to retinal tears (Fig. 120). *Vitreous floaters* are generally fine opacities consisting of aggregations of condensations of vitreous. The patient is aware of these as spots, rings or clouds appearing in front of the eye. Because of this they are sometimes referred to as *muscae volitantes* (flying flies). Vitreous floaters are identified on slit lamp or ophthalmoscopic examination in a transmitted light, and, if there is no evidence of retinal detachment developing, no further problems are to be anticipated or treatment required. **Synchysis scintillans** is a term given to glistening crystals (usually consisting of cholesterol and calcium) floating freely in the vitreous. Vitreous opa-

cities may also develop when cells enter the vitreous as a result of iridocyclitis or choroïdoretinitis.

Vitreous haemorrhages occur in association with vasoproliferative retinopathies, e.g. diabetic retinopathy, retinal vein thrombosis, retrolental fibroplasia and sickle cell trait. Retinal vessels are often ruptured when vitreous traction tears a hole in the retina. Vitreous haemorrhages are also a feature of blood dyscrasias, and follow blunt or penetrating ocular injuries.

Vitreous abscesses usually develop as a result of infection following perforating injuries or intra-ocular surgery.

The vitreous is normally adherent to the posterior capsule of the lens until the age

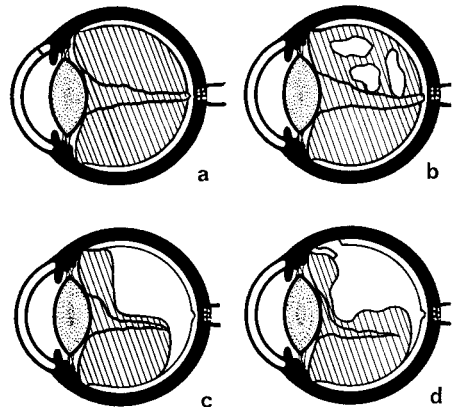


Fig. 120. Development of posterior vitreous detachment and a retinal tear: a normal vitreous with Cloquet's canal; b cavities in the vitreous; c posterior detachment of the vitreous; d retinal tear caused by vitreous traction

of 35 years. Attempts to remove the crystalline lens and its capsule (intracapsular extraction) are likely to produce severe vitreous loss at operation in this age group.

If vitreous adheres to perforating wounds of the cornea, the strands become organized, contract and pull on the vitreous base, and may thereby cause retinal detachments.

12. Retina and Choroid

General considerations

The retina forms the inner layer of the eye. Nourishment of the outer retinal layers is derived from the choroid which, as the middle coat of the eye, really belongs to the uveal tract. Despite this morphological difference the retina and choroid can, in many

aspects, be considered as a single entity from the clinical point of view.

Retinal layers and neural connections (Fig. 121): The sensory epithelial cells (rods and cones) are situated on the outer or choroidal side of the retina, i.e. not facing towards the vitreous (receptor inversion). Neural connections see Fig. 121 A, B, C. The nerve fibres of the second order neurons converge in the

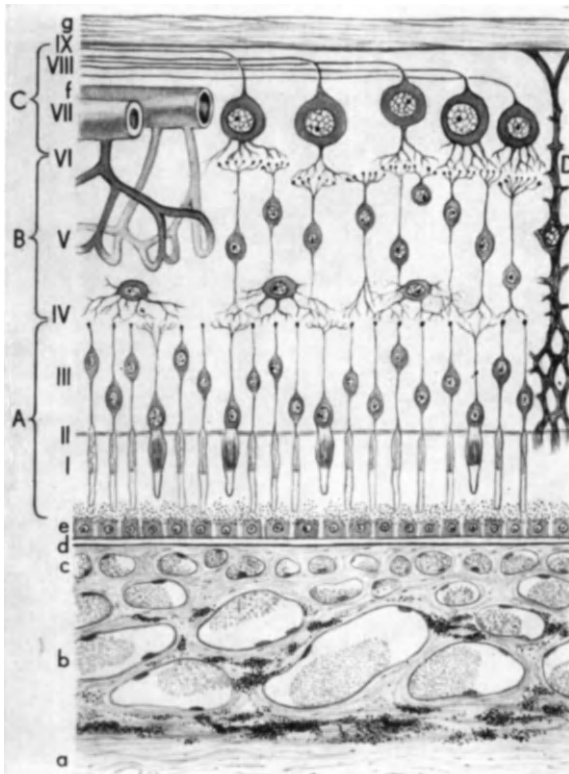


Fig. 121. Layers of the retina: I rod and cone outer segments; II outer limiting membrane; III outer nuclear layer (receptor nuclear layer); IV outer plexiform layer; V bipolar cell layer, nourished by retinal vessels; VI inner plexiform layer; VII ganglion cell layer; VIII nerve fibre layer; IX internal limiting membrane. a Sclera; b vascular layer of the choroid; c choriocapillaris; d Bruch's membrane; e pigment epithelium; f retinal vessels and capillaries; g vitreous. A Retinal pigment and receptor layer; B 1st order neuron; C 2nd order neuron; D sustentacular fibres of Müller

of 35 years. Attempts to remove the crystalline lens and its capsule (intracapsular extraction) are likely to produce severe vitreous loss at operation in this age group.

If vitreous adheres to perforating wounds of the cornea, the strands become organized, contract and pull on the vitreous base, and may thereby cause retinal detachments.

12. Retina and Choroid

General considerations

The retina forms the inner layer of the eye. Nourishment of the outer retinal layers is derived from the choroid which, as the middle coat of the eye, really belongs to the uveal tract. Despite this morphological difference the retina and choroid can, in many

aspects, be considered as a single entity from the clinical point of view.

Retinal layers and neural connections (Fig. 121): The sensory epithelial cells (rods and cones) are situated on the outer or choroidal side of the retina, i.e. not facing towards the vitreous (receptor inversion). Neural connections see Fig. 121 A, B, C. The nerve fibres of the second order neurons converge in the

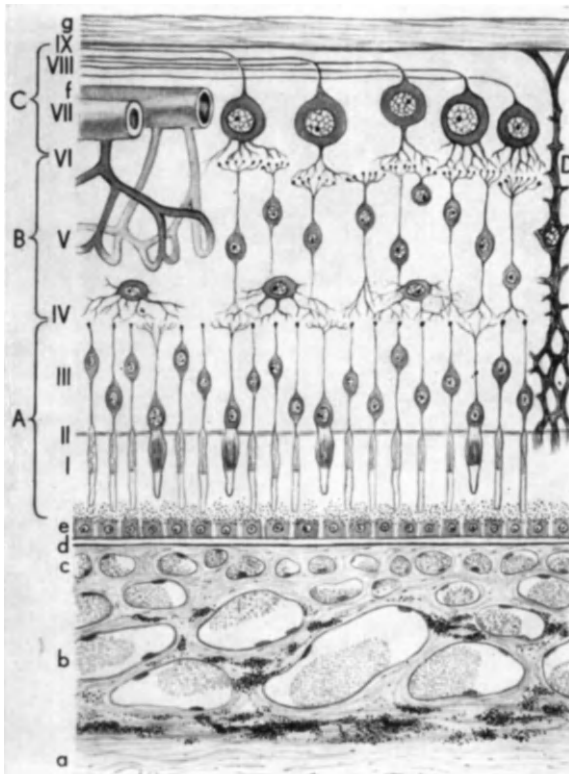


Fig. 121. Layers of the retina: I rod and cone outer segments; II outer limiting membrane; III outer nuclear layer (receptor nuclear layer); IV outer plexiform layer; V bipolar cell layer, nourished by retinal vessels; VI inner plexiform layer; VII ganglion cell layer; VIII nerve fibre layer; IX internal limiting membrane. a Sclera; b vascular layer of the choroid; c choriocapillaris; d Bruch's membrane; e pigment epithelium; f retinal vessels and capillaries; g vitreous. A Retinal pigment and receptor layer; B 1st order neuron; C 2nd order neuron; D sustentacular fibres of Müller

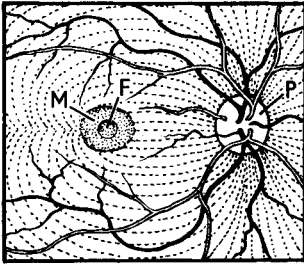


Fig. 122

Fig. 122. Course of nerve fibres in the retina. M Macula; F fovea; P optic disc

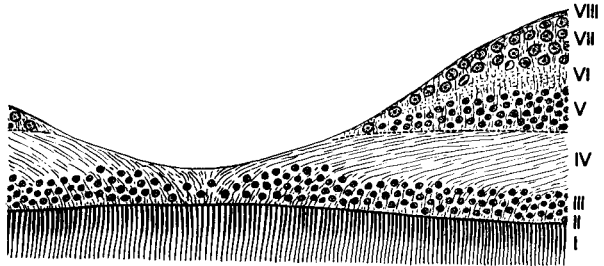


Fig. 123

Fig. 123. Structure of the macula laeta. I-VIII see Fig. 121

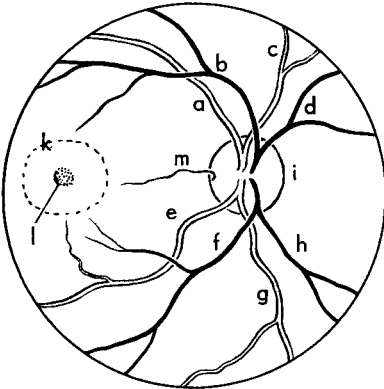


Fig. 124. a-b Superior temporal artery and vein; c-d superior nasal artery and vein; e-f inferior temporal artery and vein; g-h inferior nasal artery and vein; i optic disc; k macula lutea; l fovea; m cilio-retinal artery

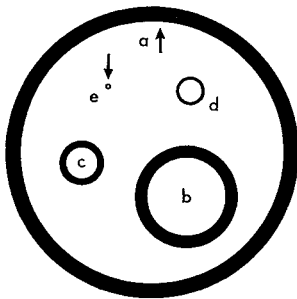


Fig. 125. Relative sizes of arteries: a Aorta; b internal carotid artery; c posterior cerebral artery; d ophthalmic artery; e central retinal artery

retina in a fan-like formation and constitute the innermost layer of the retina (Fig. 122).

There are few rods at the macula lutea (Fig. 123), which is situated approximately 2-3 disc diameters temporal to the optic disc itself. In the fovea (area of greatest visual acuity in daylight) only cones are present (sensory centralization). At this site the inner retinal layers are pushed aside so that the tissue is thinner and light rays are permitted to reach the percipient elements without being scattered. At the fovea each cone synapses with one bipolar cell, which in turn synapses with one ganglion cell (there is a one-to-one relationship). This arrangement permits a high degree of visual discrimination. Away from the fovea the number of cones becomes reduced and that of the rods increased. In the far periphery many sensory cells project to one bipolar cell and several bipolar cells synapse with one ganglion cell. This gives rise to a large sensory field with poor discrimination. Cones are responsible for daylight vision, colour perception and detailed discrimination. Rods come into action for night vision, and are more sensitive in low levels of illumination.

Blood supply: The ophthalmic artery, a branch of the internal carotid artery, passes through the optic foramen, together with the optic nerve, into the orbit. Within the orbit this vessels gives off the central retinal artery, which enters the retina approximately 10 mm posterior to the eyeball and divides at the optic disc into four retinal arterioles (Figs. 124, 125). The branches of the central retinal artery do not anastomose with the choroidal circulation, either at the optic nervehead or in the retina. These vessels supply the nerve fibre layer, ganglion cells and the synaptic layer between these and the bipolar cells. The outer retinal layers are supplied by the choroidal circulation. Blood drains out of the retinal circulation via four retinal veins, which join on the optic disc to form the central reti-

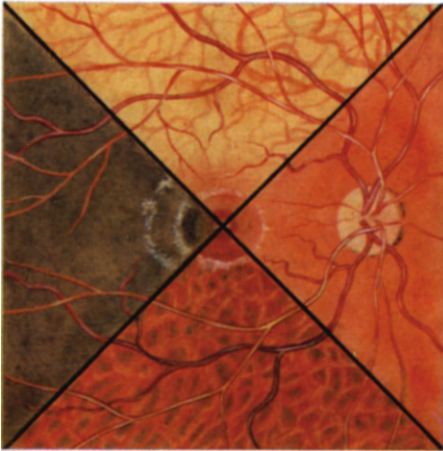

Fig. 126. Patterns of pigmentation in the fundus: **Right** normal; above fundus deficient in pigmentation, especially marked in albinos; left strongly pigmented fundus in dark-skinned races; below tigroid fundus

nal vein. Blood in this vessel passes to the superior orbital vein and thence to the cavernous sinus. The retinal venous system anastomoses with the choroidal circulation at the optic nerve head. The fovea is, from the neurological point of view, the central point of the retina. There are no retinal capillaries overlying this area. In some 50 per cent of individuals a portion of the retina is supplied by a cilio-retinal artery or vein, which is derived from the choroidal circulatory system (Figs. 124m, 151, below right).

The normal fundus: In the younger age groups the optic fundus is highly reflective. The pigment epithelium normally precludes visualization of the choroidal vessels; these may be seen, however, in hypopigmented individuals (Fig. 126, above). In coloured races the retina is highly pigmented (Fig. 126, left).

Embryological development of the retina

Neural layers of the retina are formed from the innermost layer of the optic cup. Differentiation begins at the posterior pole

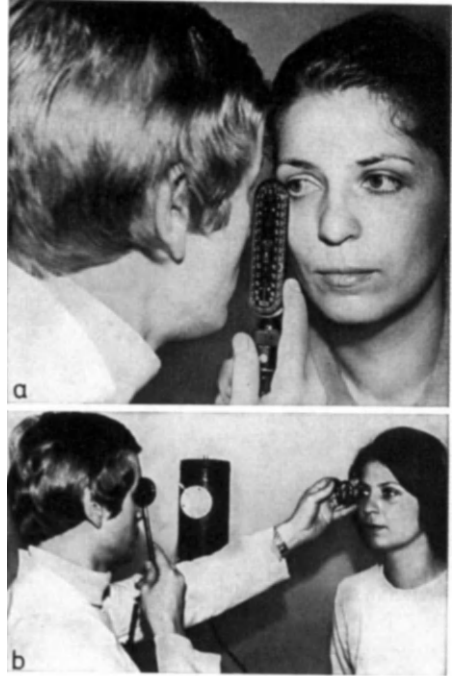

Fig. 127. Fundus examination with (a) direct ophthalmoscope and (b) indirect ophthalmoscope

with the appearance of epithelium composed of columnar cells. Later, ganglion cells and nerve fibres make their appearance, and, finally, the rods and cones differentiate. All the retinal layers are identifiable by the sixth month of gestation. The outer retinal layer forms the pigment epithelium.

Examination procedures

Ophthalmoscopy: Examination of the retina is most easily carried out by using an ophthalmoscope. Employing a direct ophthalmoscope (Fig. 127a), the entry aperture to the instrument should be as close to the patient's eye and the exit aperture as near to the examiner's eye as possible. An upright image with a magnification of approx-



Fig. 128. Dynamometer, showing small pressure plate which is placed on the sclera

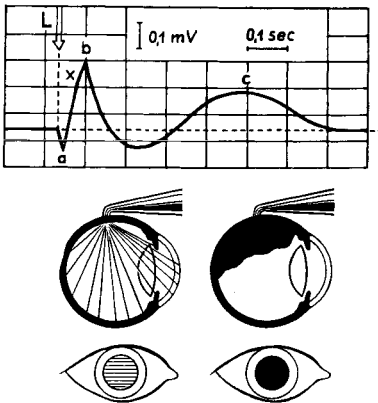


Fig. 129. Above: Normal electroretinogram showing a-, b- and c-waves; ↓ flash stimulus. Below: Trans-scleral illumination; left in normal eye; right in eye with intra-ocular tumour

imately sixteen times is produced. Indirect ophthalmoscopy (Fig. 127b) is performed with the examiner some 40–60 cm away from the patient. By means of a 14–20-dioptre lens placed a few centimetres in front of the patient's eye a virtual inverted image is obtained, giving a magnification of approximately four times. This method of ophthalmoscopy gives a wider field than that of a direct ophthalmoscope.

Dynamometry: An ophthalmodynamometer (Fig. 128) is a spring-loaded device used to exert pressure on the eyeball (sclera), and thus increase the intra-ocular pressure. Combined with ophthalmoscopic examination, this instrument is used to estimate the systolic and diastolic pressures of the retinal arterioles on the optic nerve head. Dynamometry readings are reduced in retinal vascular hypotension, e.g. following carotid insufficiency, and in the presence of raised intra-ocular pressure.

Electroretinography (ERG): Changes in the electrical potential of the retina occur when the retina is exposed to light stimulation. The changes in the electrical activity of the retina are picked up through a contact lens electrode placed on the patient's cornea. After amplification a continuous trace is obtained using a suitable recording device in response to a single flash stimulus. Fig. 129, above, shows a normal electroretinogram. The b-wave component arises at the level of the bipolar cell layer. An early indication of a tapetoretinal degeneration (retinitis pigmentosa) is reduction of the b-wave amplitude, and, as such, is a useful screening method for determining whether siblings of parents with tapetoretinal disturbances have inherited the disease, since ophthalmoscopically visible retinal changes often do not appear until the second or third decade of life. Patients with disturbances of the nerve fibre layer, such as occur in open angle glaucoma, have a normal ERG trace, since the bipolar cells remain intact. Disturbances of the a-wave are recorded in patients with pathological changes in the photoreceptor outer layers.

Ultrasonic examination (echography): When an ultrasonic beam is directed into the eye, echoes return to the sound probe from the limiting surface and are converted into electrical signals, which can be recorded. In a normal scan (Fig. 130) there is no blip between the lens and the posterior surface of the eyeball. The test is of use when corneal or lenticular opacities prevent ophthalmoscopic examination of the fundus where a tumour of the choroid or a retinal detachment is suspected.

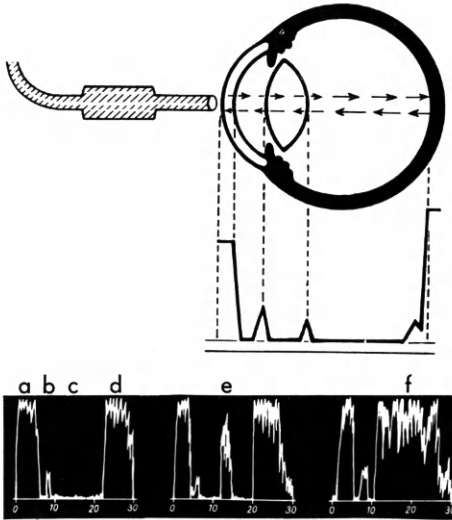


Fig. 130. Above: Ultrasonic probe with schematic echogram. Below: Echograms: a corneal echo; b lens echo; c vitreous area; d echo of posterior surface of eyeball. Left normal, centre showing retinal detachment (e), right showing intra-ocular tumour (f)

Fluorescein angiography: A useful test for investigating pathological changes in the retinal circulation, the choroid and the pigment epithelium. Twenty per cent sodium fluorescein solution is injected intravenously, and the appearance and transit of the dye in the retinal vessels can be recorded photographically using a fundus camera. Fluorescein dye exhibits the property of fluorescence, that is, when illuminated by light of a specific wavelength, light is emitted at a different wavelength to the incident rays. Utilizing a suitable light source and filter combination, only the image of fluorescein dye within the retinal vessels is projected on to the photographic film. Retinal capillaries, unlike capillaries of the skin and gut, have no pores between individual endothelial cells and do not leak out fluorescein dye except when pathological disturbances are present. The choroidal capillaries are porous and fluorescein readily enters the extravascular spaces of this tissue, but is normally prevented from passing into the retina by the tight intercellular connections of the retinal pigment epithelium. The arterial and venous phases of a fluorescein transit are shown in Fig. 131.

Trans-scleral illumination is performed on cases suspected of having a choroidal tumour. A narrow intense beam of light is directed through the sclera into the eye. The pupil normally appears bright red when the inside of the eye is thus illuminated, but if a tumour is present light cannot pass into the eye and the pupil remains black (Fig. 129, below).

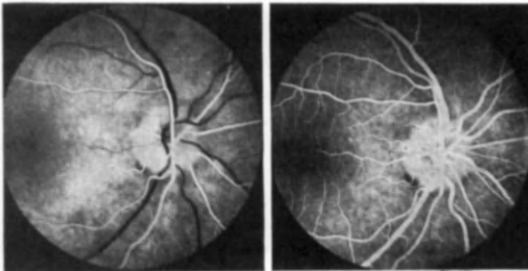


Fig. 131. Fluorescein angiography. Left: arterial phase approx. 10 seconds after injection; right: venous phase approx. 16 seconds after injection

Circulatory disturbances

Occlusion of the central retinal artery

(Fig. 132 a)

Symptoms: Sudden painless loss of vision.

Signs: The pupil does not react directly to light. On ophthalmoscopy performed soon after the event the retina is seen to be cloudy, oedematous and milky in appearance. The macula is seen as a red spot, because the retina is thinner here, and the choroidal reflex continues to show through. Arterioles are attenuated and segmentation of the blood column is sometimes seen. An embolus may be detected at the level of the optic nerve head. After a few days the retinal oedema clears, and within a week or two the optic disc shows evidence of atrophy, due to degeneration of the ganglion cells and their neurons.

An embolus lodging in a branch of the central retinal artery causes changes in the retina to take place only in the area supplied by this vessel, giving rise to a quadrantic visual field defect (Fig. 141 b). If a cilioretinal artery is present supplying the macular area, central vision will be preserved.

Aetiology: Retinal arterial obstructions frequently arise from emboli originating elsewhere in the systemic vasculature. The commonest cause is emboli being shed from atheromatous lesions, and the chief site of emboli formation causing impaired retinal perfusion is at the level of the bifurcation of the common carotid artery. More rarely, emboli arise, from vegetations on heart valves. Central retinal artery occlusions can also occur in collagen diseases, particularly giant cell arteritis, and following trauma, including surgical procedures within the orbit. Air emboli occasionally appear in the retina following surgery to the neck or the heart, and, more rarely, retinal arteriolar occlusions are due to parasitic or malignant emboli.

Treatment of retinal embolization is a matter of urgency. The retina, being central nervous tissue, can only tolerate a limited period of ischaemia (maximum 2 hours) without irreversible changes occurring. The

patient should be made to lie down and re-breathe from a paper bag in order to raise the blood CO₂ levels. A high blood CO₂ is a potent retinal arterial vasodilator. An anterior chamber paracentesis may be performed to reduce the intra-ocular pressure and thereby induce an embolus to move further on in the retinal circulation. An emergency plasma viscosity estimation must always be performed in patients over the age of 55 in order to exclude a diagnosis of giant cell arteritis (see below). Investigations should be put in train to ascertain whether there is arterial disease at the bifurcation of the carotid, and treatment instituted to eliminate further emboli passing up the branches of the internal carotid to the brain. Episodic loss of vision in one eye lasting for several minutes is an important symptom of transient retinal ischaemia. The most common cause of this symptom is emboli arising from the bifurcation of the carotid which break up on passing through the retinal circulation.

Thrombosis of the central retinal vein

The patient complains of painless loss of vision, which may be moderate or severe. On examination the pupil responses to light are rarely grossly impaired, and on initial ophthalmoscopy, diffuse retinal haemorrhages, flameshaped in appearance, can be seen extending over the whole fundus (Fig. 132 b). Veins are engorged, are the optic disc is swollen and its edges so ill-defined. Visual field examination reveals a partial or complete central scotoma, but the peripheral field is often intact. In some cases pale ill-defined areas (soft exudates) are noted, which indicate that there is an arterial component to the obstruction, since these are not exudates but foci of capillary non-perfusion (Fig. 123 c). **Complications:** Neovascular glaucoma (see Chapter 10). When the occlusion is limited to a branch of the central retinal vein, haemorrhages are confined to one quadrant, and a corresponding visual field defect is elicited.

Aetiology: As with venous thrombosis formation elsewhere in the body, retinal

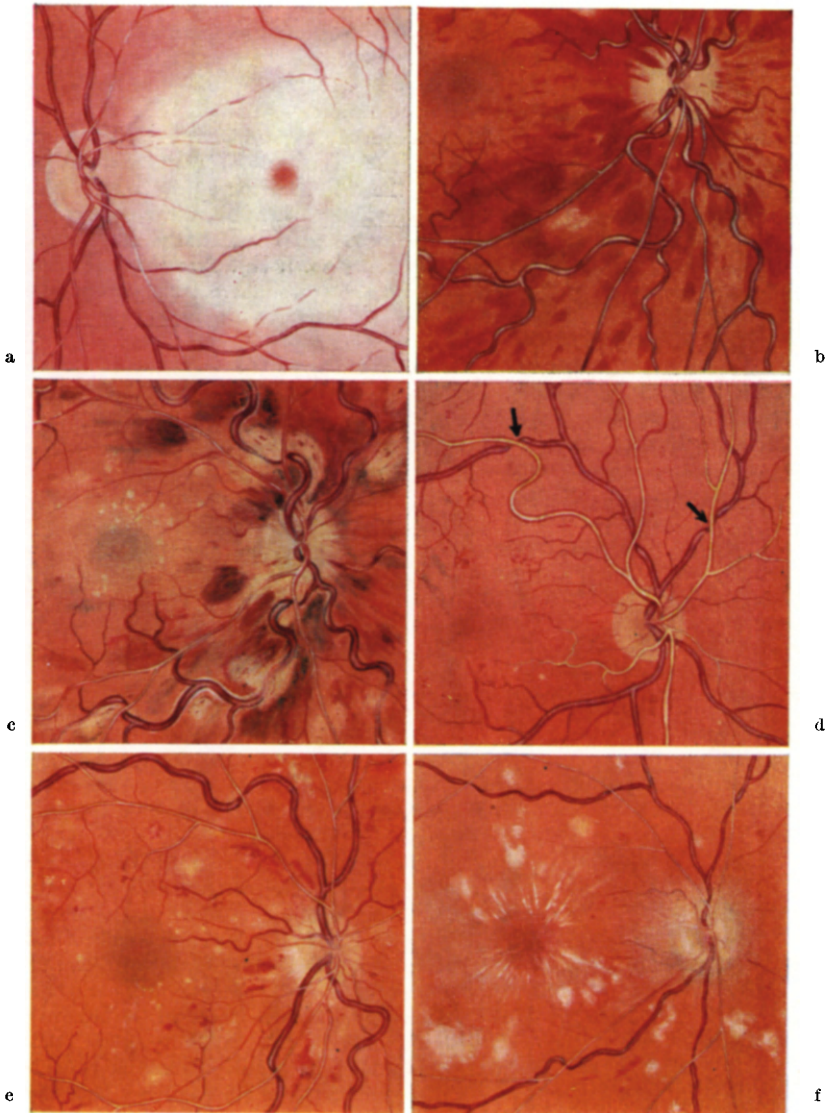


Fig. 132. a Recent embolism of the central retinal artery; **b** recent thrombosis of the central retinal vein; **c** thrombosis of the central retinal vein with an arterial component; **d** hypertensive fundus (early stage, showing 'copper wire' arteries, occasional haemorrhages and arteriovenous nicking; **e** early malignant hypertension; **f** advanced malignant hypertension

venous occlusions develop as a result of slowing down of blood flow and turbulence. Occlusions take place at arteriovenous crossing points and at the optic nerve head. At these sites the arteriole and vein share a common sheath. Narrowing of the arterial lumen → reduced perfusion and thickening of the arterial wall → localized narrowing of the venous internal lumen (Fig. 133) provides the physical factors required for venous thrombosis to develop. Investigations must therefore be performed to exclude generalized systemic vascular disease, i.e. hypertension, arteriolar sclerotic disease, raised intra-ocular pressure (which decreases retinal vascular perfusion), hyperviscosity syndromes (polycythaemia, hyperproteinemia, sickle cell trait, leukaemia, etc.) and diabetes. **Treatment:** Should be directed towards eliminating the predisposing causes. Anticoagulants have not been found effective. **Complications:** Persistent retinal oedema and neovascularization. Retinal photocoagulation may then be of value in certain cases.

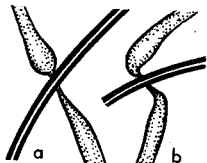


Fig. 133. Arteriovenous nicking

Other vascular disorders

Examination of the retinal blood vessels can supply valuable clues as to the condition of the systemic vascular system.

Benign hypertensive retinopathy

Initial stage (Fig. 132d): The arterioles show up on ophthalmoscopy with yellowish-gold streaky reflections, which are due to thickening of the vessels walls (copper wiring). In the healthy individual the retinal vessels are transparent and the walls invisible.

Owing to the increased external diameter of the arterioles, the veins are pinched at arterio-venous crossing points (A-V nicking, Fig. 133). The optic disc has a normal appearance.

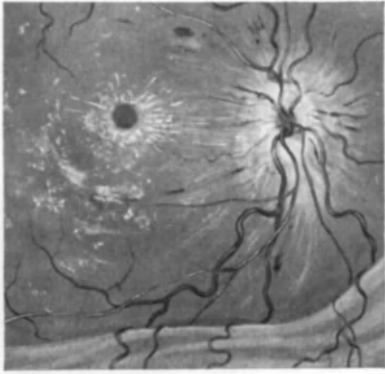
Advanced stage: Marked variation in calibre of the arterioles is apparent and wiring of the arterioles more pronounced. Numerous small superficial retinal haemorrhages are detected, occasionally becoming pre-retinal (Fig. 134b). **Treatment:** Regime to lower the systemic vascular pressure to acceptable levels.

Malignant hypertensive retinopathy

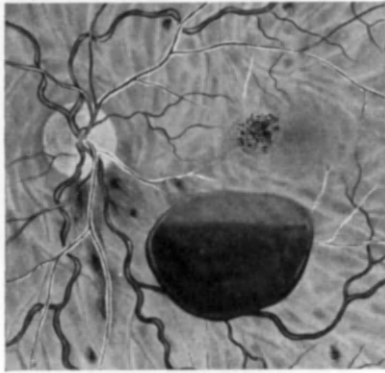
Initial stage (Fig. 132e): The principal feature is that the optic disc is oedematous and blurred. Arterioles are narrowed, irregular in calibre and tortuous. Areas of focal retinal ischaemia (soft exudates) and streaky haemorrhages are present. **Advanced stage** (Fig. 132f): The fundus is somewhat pale, the disc swelling becomes very obvious and the arterioles are grossly attenuated. Macular oedema, with the development of a macular fan, is a common finding. Vision, which remains good in the early stages, may become impaired at this time. **Treatment:** Should be directed towards the underlying cause. Investigate for renal disease, pheochromocytoma, etc. Without urgent treatment, patients with malignant hypertension die from renal disease.

Retinopathy of toxæmia of pregnancy: Changes occurring in the retina are similar to those of malignant hypertensive retinopathy. In very severe cases serous retinal detachments develop (Fig. 134a). The appearance of a retinopathy indicates that the lives of both the mother and the unborn baby are at great risk, and immediate termination of the pregnancy should be considered. The retinal changes resolve spontaneously after birth unless renal complications have occurred.

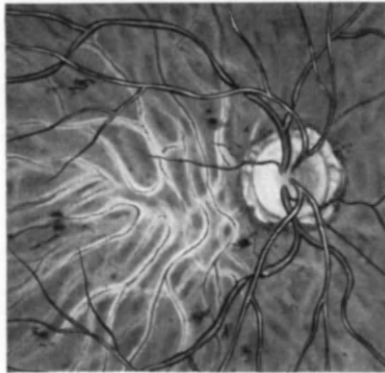
Retinal disturbances rarely occur in **acute nephritis**. **Chronic nephritis** results in oedema of the lids, and conjunctival haemorrhages may appear. The retinopathy is that of malignant hypertension.



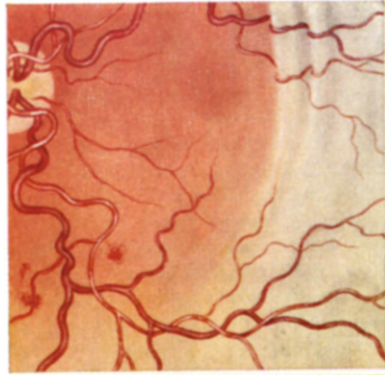
a



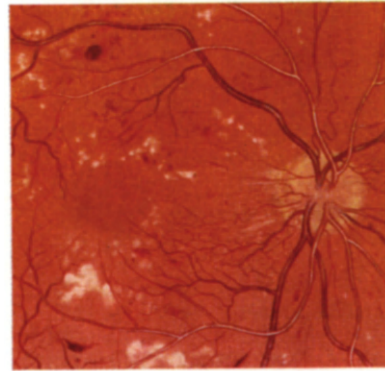
b



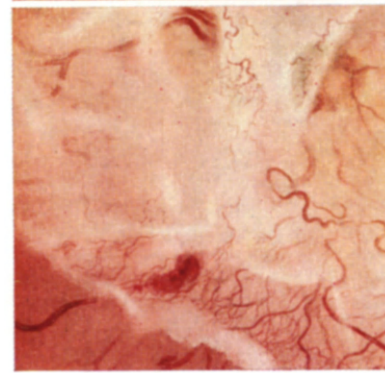
c



a



b



c

Fig. 134. a Retinopathy in toxæmia of pregnancy; **b** hypertensive retinopathy with pre-retinal hæmorrhages, showing blood level; **c** choroidal atrophy

Fig. 135. a Retrolental fibroplasia; **b** vasoproliferative diabetic retinopathy; **c** vasoproliferative diabetic retinopathy with membrane formation

Retroental fibroplasia is very liable to occur in premature infants who require oxygen therapy and weigh less than 1800 g at birth if the arterial oxygen tension is permitted to exceed 90 mm Hg. All premature babies requiring oxygen therapy must have the arterial pO_2 monitored at regular intervals. High oxygen tensions in the arterial blood of these children cause constriction of the peripheral retinal vessels which have yet to reach the retinal periphery. After the child has been removed from the high atmospheric oxygen environment, the peripheral retinal vessels undergo a disordered development, with the formation of aberrant new vessels and fibrovascular proliferation occurs into the vitreous. In very severe cases membranes grow right across the back of the crystalline lens to give a white pupillary reflex. Blindness also occurs from vitreous haemorrhages and because traction of the connective tissue causes retinal detachments (Fig. 135a) and puckering of the macula.

Diabetic angiopathy

Diabetic angiopathy develops in cases of diabetes mellitus of long-standing. The re-

tinal changes do not bear any relationship to the age of the individual at the time of onset of the disease, to its severity or to the type of medication employed. Diabetic angiopathy is now a major cause of severe visual impairment in the 30–60 age group in the Western world.

The retinal changes occurring in this disease are classified in two major groups: **exudative retinopathy**, arising mainly as a result of plasma leaking out from the retinal blood vessels, and **vasoproliferative retinopathy**, which is manifested by the development of new vessels, though the two forms may co-exist in the same retina.

Exudative retinopathy: Is characterized by the appearance of capillary microaneurysms (Fig. 136b), superficial flame-shaped haemorrhages and deep circular haemorrhages (blot and dot retinopathy). Lipid deposits may develop in the form of clearly defined whitish or yellowish exudates, which take up a ring form. Pale ill-defined areas of focal retinal ischaemia (cotton wool spots) are also a feature. The above changes occur mainly at the posterior pole. Loss of vision occurs if the superficial retinal haemorrhages break into the vitreous (vitreous haemorrhage), cotton wool spots involve the perimacular area, hard exudates encroach on the macula or the macula becomes oedematous due to adjacent leaking vessels.

Vasoproliferative angiopathy: New vessels develop initially within the retina (Fig. 135b), but later break through to form vascular leashes over the retinal surface. Vitreous contraction and separation of the posterior vitreous face causes these blood vessels to be pulled forwards. Connective tissue accompanies the vessels and fibrovascular membranes subsequently cover the posterior vitreous face (Fig. 135c). The new vessels are fragile and readily bleed into the vitreous. Contraction of the fibrous bands leads to traction retinal detachments, and, because new vessel formation appears to be related to retinal ischaemia, neovascular glaucoma is an additional complication. Visual loss therefore occurs

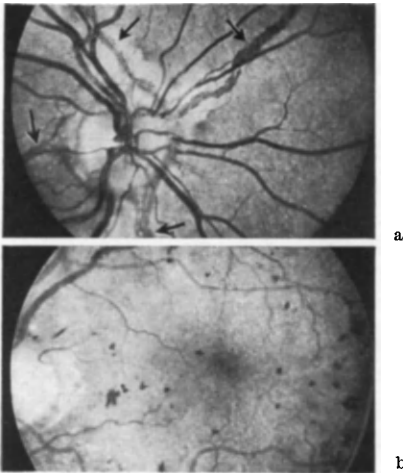


Fig. 136. a Angioid streaks; b diabetic retinopathy (early stage)

as a result of vitreous haemorrhage, membranes preventing light getting to the retina, retinal detachments and the effects of glaucoma. In young uncontrolled diabetics hyperlipaemia may be so marked that the retinal vessels appear as white strands (Fig. 137 b). *Treatment*: Since the basic pathological processes responsible for diabetic angiopathy remain obscure, the results of treatment leave much to be desired. Photocoagulation is effective in sealing the leaking vessels identified by fluorescein angiography, and in the treatment of new vessels, providing they have not proceeded too far forwards. Vitreous surgery has a role when vitreous haemorrhages have occurred, but such surgical techniques remain at an early stage of development. Hypophysectomy may cause early vasoproliferation to regress.

Other changes affecting the visual system brought about by diabetes include extra-ocular muscle palsies (3rd nerve palsy with pupillary sparing), early onset of cataracts, poor dilatation of the pupils due

to the deposition of glycogen in the pigment layers of the iris and hordeolosis.

Blood diseases involving the retina

Partial ischaemia of the retina due to poor perfusion from, for example, carotid stenosis, sickle cell disease and severe anaemias cause superficial and deep retinal haemorrhages to develop. Lipid deposits and areas of focal retinal ischaemia may also appear. In severe anaemias yellowish-white exudative patches with a red surround are a common finding on ophthalmoscopic examination (Fig. 137 a).

Myeloid and lymphatic leukaemia retinopathy: The veins are tortuous and dilated. Disc margins are frequently oedematous and the background fundus shows a yellow hue.

Polycythaemia: Venous congestion, disc oedema and scattered retinal haemorrhages are all features of this disease. **Complications**: Central retinal vein thrombosis. Normal retinal appearances are rapidly restored when the above conditions are actively treated.

Arteriolar sclerosis of the choroid produces atrophy of the choroidocapillaris and disturbances of the retinal pigment epithelium so that on ophthalmoscopy the large choroidal vessels are readily visible (Fig. 134c). Later on there may be complete obliteration of all the choroidal vessels. Impaired perfusion of the choroid causes ischaemic changes to develop in the retinal pigment epithelium and the photoreceptor layer. Visual loss occurs in the involved areas.

Inflammatory disorders (retinitis, choroidoretinitis)

In view of the close topographic and functional relationship between these two layers, choroiditis is always accompanied by retinitis and vice versa. Localized and disseminated forms are described. Features of both types include greyish-white retinal opacities, which in some cases may be accompanied by retinal haemorrhages. After the inflammatory process subsides, pigment atrophy and pigment hypertrophic changes become evident.

Disseminated choroidoretinitis: Yellowish-white or grey patches with blurred edges

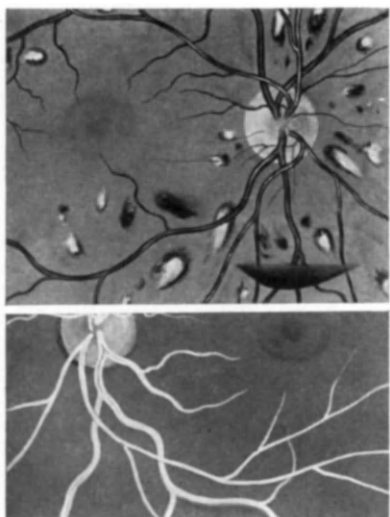


Fig. 137. Retinal changes in (a) pernicious anaemia and (b) lipaemia

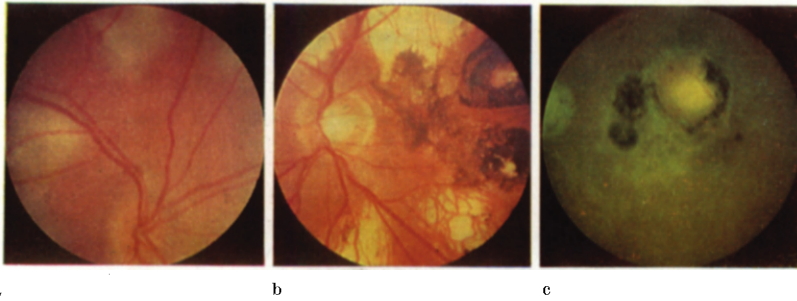


Fig. 138. a Recent foci of choroidoretinitis; b old choroidoretinitis scars; c colour fluorescein angiography in active choroidoretinitis

develop as a result of the retinal oedema produced. The overlying vitreous is hazy (Fig. 138a). The patient rarely complains of much pain, but there is progressive loss of vision due to cellular infiltration of the vitreous and as a result of retinal damage. Inflamed patches leak dye on fluorescein angiography (Fig. 138c). After the inflammation has subsided, areas of choroidal and retinal pigment atrophy appear, and the sclera becomes visible (Fig. 138b). **Aetiology:** As for iritis (see Chapter 8). In addition, in patients coming from the United States, histoplasmosis should be considered. In the majority of cases, however, no cause is found. **Treatment:** Local and subconjunctival steroids.

Purulent choroidoretinitis (Fig. 139a) may be diffuse or localized, and results from generalized bacteraemia, e.g. drug addicts using unsterile needles for intravenous injection. The onset is often marked by haemorrhages (septic retinitis, Fig. 140a). If treatment is not instituted at once, vitreous abscesses and panophthalmitis are likely complications.

Juxtapapillary choroidoretinitis is so named because a focus of infection lies adjacent to the optic nerve head; damage to the optic nerve fibres at this site (Fig. 140b) results in a characteristic visual field loss (Fig. 141a).

Congenital ocular toxoplasmosis: Circular areas of choroidal retinal atrophy are noted surrounded by a ring of hyperpigmentation.

Lesions occur at the posterior pole and frequently involve the macula, so that sight may be permanently impaired (Fig. 142c). Following maternal infection the protozoan **Toxoplasma gondii** readily migrates across the placenta to infect the fetus. Other complications include hydrocephalus, and X-ray examination may show spotty cerebral calcification. Choroidoretinitis due to *Toxoplasma* infection can also develop in adults, but although the lesions appear mainly at the posterior pole, primary involvement of the macula is uncommon, though it may become implicated as a result of spreading infection. **Treatment:** Subconjunctival steroids to cut down the inflammatory response. Light coagulation of active lesions may be effective.

Retinal periphlebitis (Eales's disease) is a disease of unknown aetiology, which mainly occurs in young males; in 40–50 per cent of cases both eyes are involved. The disease is characterized by perivenous and arteriolar sheathing, initially towards the periphery of the retina, associated with microaneurysms, superficial haemorrhages and vascular proliferation (Fig. 139b). In the more advanced stages the posterior pole, including the disc, may become affected, and retinal haemorrhages are prominent and frequently break through into the vitreous, causing sudden marked visual loss. Fibrovascular proliferation develops (Fig. 139c), leading to secondary retinal detach-

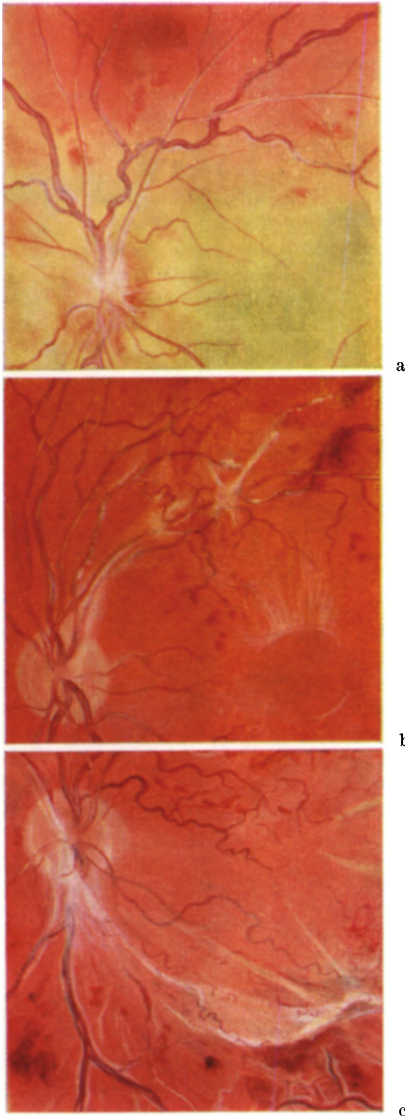


Fig. 139. a Metastatic purulent choroidoretinitis (early stage); b retinal periphlebitis (advanced stage); c retinal periphlebitis with marked retinal fibrosis

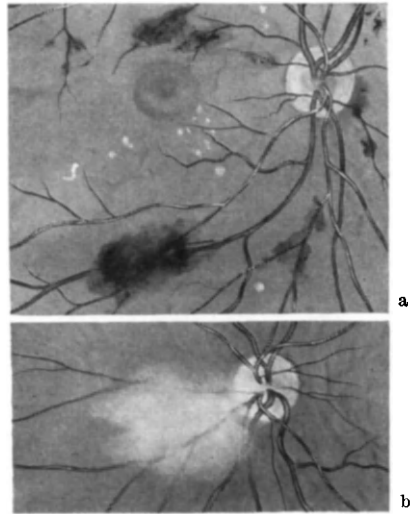


Fig. 140. a Septic retinitis; b juxtapapillary chorioretinitis

ment, secondary haemorrhagic glaucoma and, in the cases with recurrent vitreous haemorrhages, to siderosis due to the deposit of iron salts released from haemoglobin (see Chapter 16). **Treatment:** Peripheral neovascular lesions are amenable to light coagulation therapy (Fig. 142b). Recurrences are common, and regular follow-up of these patients, with thorough retinal examination, is indicated. Retinal vasculitis is associated with other diseases, including periarteritis nodosa and sarcoidosis.

Degenerative retinal disorders

Tapetoretinal degeneration (retinitis pigmentosa) is characterized by the development, in early or middle adult life, of areas of bone spicule retinal pigmentation (Fig. 143a). Inborn defects of the retinal pigment epithelium result in degeneration of the photoreceptor outer elements, leading to the development of a ring scotoma on visual field examination (Fig. 141c) that breaks out

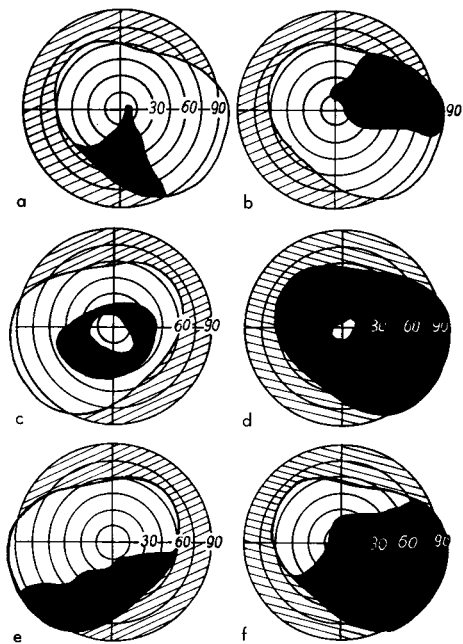


Fig. 141. Visual field loss resulting from retinal damage. a Visual field in juxtapapillary choroidoretinitis; b quadrantic visual field following an embolism in a retinal arteriole; c ring scotoma in retinitis pigmentosa; d gunbarrel loss in open angle glaucoma or advanced retinitis pigmentosa; e-f progressive visual field loss in a superior retinal detachment

towards the periphery and towards fixation, producing progressive constriction of the visual fields → gunbarrel vision (Fig. 141d). Because the rods are preferentially affected, an early symptom is night blindness. The optic disc becomes waxy pale and retinal vessels show extreme attenuation. Good central vision is often retained until a late stage, but eventually complete blindness occurs. The condition is hereditary and transmission to siblings may be autosomal dominant, autosomal recessive or sex-linked. **Treatment:** None available, and the overall prognosis is poor. Patients with retinitis pigmentosa may also suffer from deafness (Usher's syndrome) or from mental retardation, obesity, hypogenitalism and polydactyly (Laurence-Moon-Biedl syndrome).

Other forms of retinitis pigmentosa: Retinal pigmentary degeneration occurs following severe ocular concussive injuries and may mimic the appearance of retinitis pigmentosa. However, the condition is usually unilateral and there is no family history. Certain drugs, especially those used to treat rheumatoid arthritis, chloroquine and hydroxychloroquine, when used in high doses over a prolonged period may cause retinal pigmentary changes, as will certain of the phenothiazine drugs.

Progressive axial myopia: There is progressive increase in the axial length of the eyeball which develops in late childhood and early adulthood. The sclera becomes stretched and thinned, especially at the

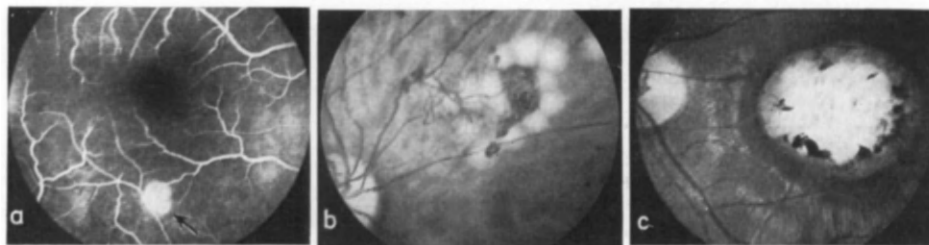
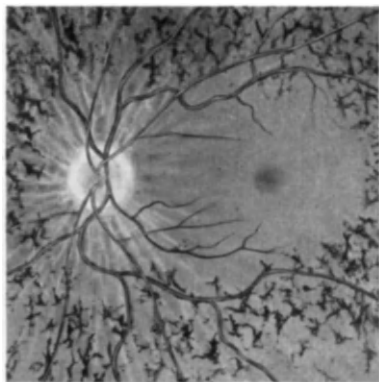
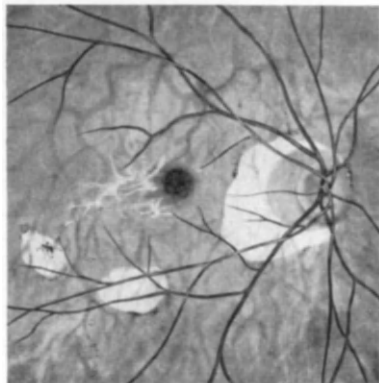


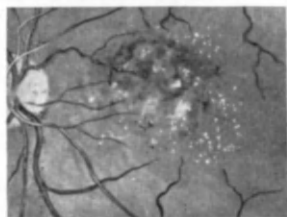
Fig. 142. a Pooling of dye in central serous retinopathy (fluorescein angiography); b photocoagulation reaction around a localized area of periphlebitis; c macular lesion from congenital toxoplasmosis



a



b



c

Fig. 143. a Retinitis pigmentosa; b myopic retinopathy with myopic crescent, peripapillary choroidal atrophy, myopic macular degeneration and choroidal atrophy; c dry form of macular degeneration

posterior pole (scleral staphyloma), the vitreous degenerates, floaters develop and the posterior vitreous face separates from the retina. Crescent-shaped areas of choroidoretinal degeneration appear around the optic disc, initially more prominent on the

temporal side, but eventually completely surrounding the disc (myopic crescent, Fig. 143 b). Degenerative lesions also develop at the macula, with areas of pigmentary atrophy and hypertrophy, and haemorrhages may occur at this site, producing sudden painless loss of central visual acuity (Fuch's spot). Retinal detachments are particularly prone to occur in high myopes because of the degenerative changes which occur in the vitreous and the peripheral retina. **Treatment:** Apart from re-attaching retinal detachments if they occur, no treatment seems capable of arresting the progressive changes in high myopia.

Angioid streaks (Fig. 136a) are due to degenerative changes occurring in Bruch's membrane, and are most frequently associated with **pseudoxanthoma elasticum** (Groenblad-Strandberg syndrome). Pigmented tortuous streaks, somewhat resembling blood vessels, radiate outwards from the optic disc. Exudative disciform degeneration of the macula is a frequent complication, causing severe impairment of central vision in middle age, or earlier if the globe is subjected to a moderate or severe concussive injury (brittle eye syndrome). Angioid streaks have also been reported in Paget's disease and sickle cell trait.

Retinal detachments

Secondary to retinal tears: The patient complains of some or all of the following symptoms: flashing lights (due to vicarious stimulation of the retina following vitreous contraction), spots in front of the eyes appearing suddenly (due to the rupture of a blood vessel as a hole develops in the neural layer of the retina) and progressive, continuous, painless visual field loss (Fig. 141e-f) as though a curtain is spreading across the field of vision. As the retina separates, the photoreceptor layer is drawn away from the choroidal layer supply and is rendered ischaemic. On ophthalmoscopic examination the detached retina is grey-white in colour and shows ripples or folds which undulate when the eye moves, and the retinal blood vessels appear dark or black. One or more retinal holes are seen

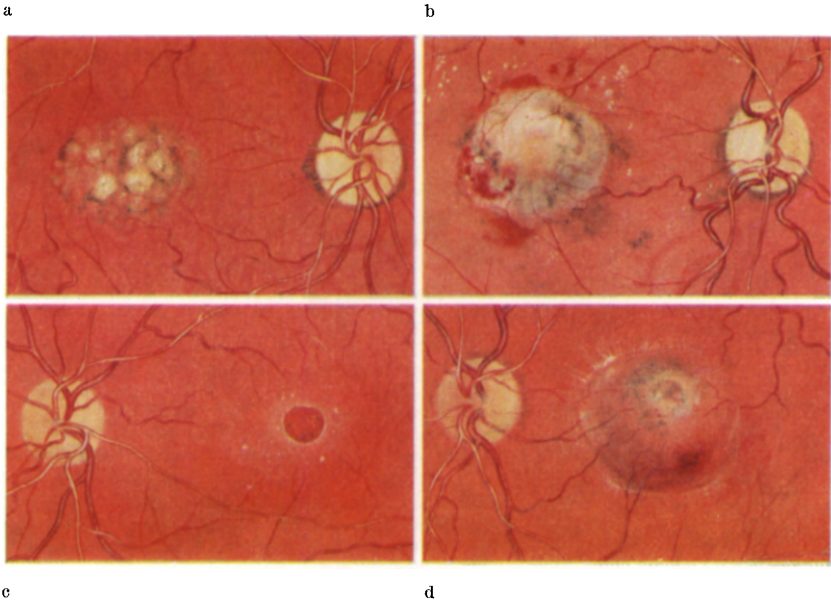


Fig. 144. Changes in the macula; **a** Juvenile degeneration of the macula; **b** exsudative disciform degeneration with scarring of the retina; **c** macular hole; **d** exsudative disciform degeneration

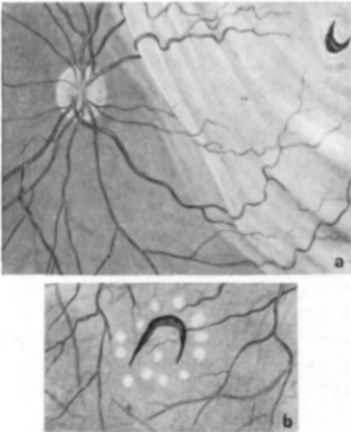


Fig. 145. **a** Retinal detachment with tear; **b** photo-coagulation reaction around a retinal tear with flat surrounding retina

(Fig. 145a), usually located in the equatorial region. These defects appear red due to the choroid showing through the opening. **Aetiology:** Associated with high myopia, aphakia, trauma (see Chapter 16) and degeneration of the peripheral retina associated with pathological changes in the vitreous. Tears produced in the neural layer of the retina permit fluid to form between this layer and the pigment epithelium, so that eventually a total retinal detachment occurs with complete loss of vision in the affected eye. Embryologically, the outer layer of the optic cup forms the pigment epithelium, and the inner layer of the optic cup the neural layer of the retina. In retinal detachments due to holes developing in the neural layer, this line of cleavage is re-established.

In long-standing retinal detachments retinal fibrosis develops, inflammation occurs

and the lens becomes cataractous. **Differential diagnosis:** **Serous retinal detachment (without holes)** appears in severe systemic hypertension and retinopathy of toxæmia of pregnancy. Such retinal detachments resolve following therapy of the primary condition. **Secondary to choroidal tumours**, e.g. malignant melanomas. Transcleral illumination is of value in identifying solid retinal detachments (Fig. 129). Retinitis proliferans may give rise to **traction retinal detachments** in which no holes develop. **Treatment:** If retinal holes or tears can be identified before a retinal detachment occurs, photocoagulation or cryotherapy around the defect is all that is required to ensure bonding of the neural and pigment layers (Fig. 145b). After a retinal detachment has developed the coat of the eye must be indented to approximate the pigment epithelium to the detached neural layers of the retina at the site of any holes. Indentation is performed by pleating the sclera (Fig. 146a), positioning a superficial Silastic plomb on the sclera and oversewing this so that the sclera is pushed inwards (Fig. 146b), or by encirclement procedures, where the waist of the eye is constricted (Fig. 146c).

Detachment of the choroid: A condition usually seen after cataract or glaucoma operations in which a marked reduction of the intra-ocular pressure has occurred post-operatively. On ophthalmoscopy a raised tumour-like bulge is noted, which is very much darker than a retinal detachment. Choroidal detachments tend to resolve spontaneously without any permanent sequelae. Choroidal detachments also occasionally develop in association with collagen diseases.

Maculopathies

In the younger age groups pigmentary degenerative changes are sometimes seen to develop as an inherited condition (Fig. 144a). Central visual acuity may be moderately or severely impaired. **Treatment:** None available.

Central serous retinopathy: A focal disturbance of the retinal pigment epithelium develops, permitting fluid from the choroid to leak through a pigment epithelial defect and produce a serous detachment of the neural layers of the retina. On ophthalmoscopic examination this shows up as a circular area of retinal oedema at the posterior pole. The condition usually occurs in the 30-40 age group, and may be unilateral or, more rarely, bilateral, though it is extremely rare for both eyes to be involved at the same time. More males than females are affected. The patient complains of blurring of central vision, distortion of images, micropsia (objects appear small when viewed with the affected eye) and persistence of after-images, especially bright lights at night. Fluorescein angiographic studies reveal the presence of a leaking point (Fig. 142a). The serous detachment usually resolves spontaneously, leaving behind focal areas of retinal pigment disturbance. There is a tendency to recurrence, but not at the same point as was previously affected. **Aetiology:** Unknown. **Treatment:** Usually unnecessary, unless visual disturbances are prolonged or sight is severely impaired. Photocoagulation to the leaking point permits earlier resolution of the detachment.

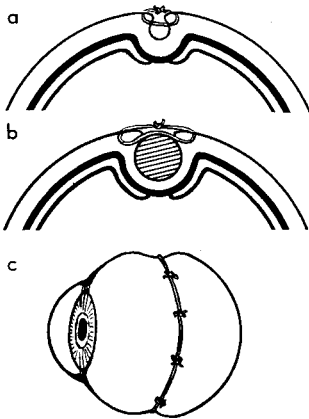


Fig. 146. a Pleating of the sclera; b plomb indenting the sclera; c encircling rod

Senile macular degeneration

Senile macular disorders are commonly responsible for severe central visual impairment in old age, and are classified according to whether exudative changes are present (exudative disciform) or absent (non-exudative, dry form).

Non-exudative form (Fig. 143c): Degenerative changes develop in the pigment epithelium adjacent to the macula. Central visual acuity is gradually, and eventually seriously, reduced, giving rise to dense central scotoma. The peripheral visual fields remain unimpaired, so that the patient can usually manage to get about. Fluorescein angiographic studies show no leakage of dye from the choroidal or retinal vessels, but merely a window effect due to atrophy of the pigment epithelium.

Exudative form (disciform maculopathy): Degenerative changes develop in Bruch's membrane. These are sometimes preceded by the development of pale excrescences in the membrane (drusen). Breaks occur in the membrane which permit fluid to pass from the choroid through into the retina, causing detachment of the pigment epithelium. Later, new vessels and fibrous tissue grow through these defects, producing a circular localized elevation of the retina at the posterior pole and oedema of the neural layers (Fig. 144d). Haemorrhages develop as the leash of new blood vessels spreads out underneath the pigment epithelium, and accompanying fibrous tissue later causes extensive scarring (Fig. 144b). Vision is lost early in this process and the prognosis is poor. If the defects in Bruch's membrane can be identified early by means of fluorescein angiography, laser coagulation may arrest the condition and preserve vision. **Aetiology:** Unknown. Similar changes may occur in younger age groups following traumatic choroidal ruptures and in association with angioid streaks.

Macular cysts ("holes") (Fig. 144c): Focal degeneration of the neural layers of the retina, with the exception of the inner limiting membrane, occur in old age, in retinal ischaemia and following severe concussive injuries (see Chapter 16). If located on the

fovea, vision is often severely impaired. **Treatment:** None effective. Retinal detachments are very rarely caused by the development of holes at the macula.

Tumours

Tumours occurring in childhood

Retinoblastoma (Fig. 147a): A malignant tumour derived from embryonic cells of the retina which usually appears before the age of 4 years, but can, rarely, appear later. The tumours are not infrequently multifocal and bilateral. Initially, a small yellowish-white tumour is seen on ophthalmoscopy which grows rapidly, developing a fungiform appearance as extension into the vitreous cavity takes place. With large tumours the pupil may appear white, and the description 'cat's eye amaurosis' is given to this condition (Fig. 148a). The tumour seeds into the vitreous, and has a

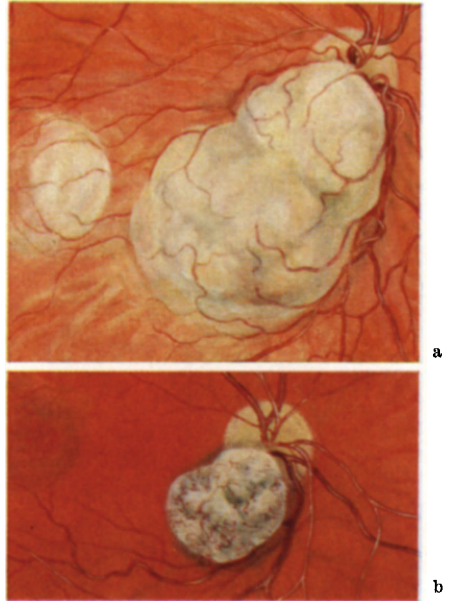


Fig. 147. a Retinoblastoma; b glioma at the optic disc in von Recklinghausen's disease

tendency to grow down the optic nerve to invade the cranial cavity. The principal pathological characteristic is the formation of rosettes (Fig. 148 b). The neoplasm is extremely radiosensitive and, providing treatment is instituted at an early stage, preservation of the sight is possible. If, however, the vitreous cavity is filled with the neoplasm, enucleation must be performed and care taken to remove as much of the optic nerve as possible. The prognosis is extremely poor if extension into the cranial cavity has occurred. **Differential diagnosis:** Retrolental fibroplasia in premature infants, vitreous abscesses and congenital retinal detachments. Following radiotherapy the patient must be seen regularly, as there is a tendency for new foci to appear. Retinoblastomas are transmitted to succeeding generations as a dominant gene, and siblings of known cases

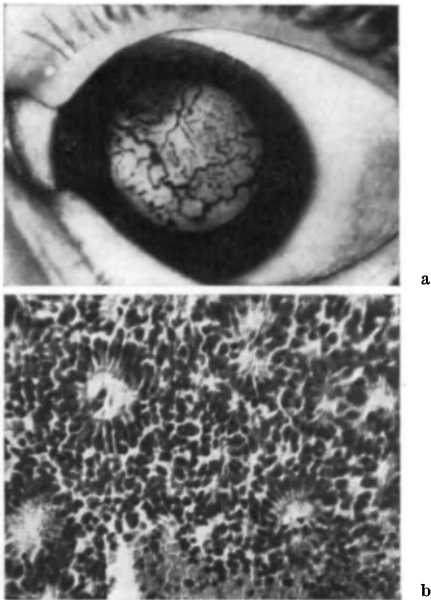


Fig. 148. a White pupil reflex caused by a neuroblastoma; b histological section showing neuroblastoma rosettes

must be examined from immediately after birth, as there is a 50 per cent risk of these children being affected.

Benign tumours: The most common of these are angiomas of the retina and choroid (Fig. 149f).

Tumours in adults

Malignant melanomas of the choroid: These pigmented tumours, which tend to occur in the older age group and may appear in the thirties and forties, but are extremely rare before puberty, cause elevation of the retina and serous retinal detachments. In the area of the tumour transcleral illumination shows a shadow in the pupil (Fig. 149e). Diagnosis is aided by confirming growth of a pigmented tumour, the uptake of radioactive phosphorus in the area of the tumour, by ultrasonography (Fig. 130c) and by means of fluorescein angiographic studies, which demonstrate the presence of a pathological circulation. Because vision may not be involved until a late stage and no other symptoms are noticed, the tumour can become relatively large before the patient is aware of any visual problems. At first the tumour, which is grey-brown in colour, either spreads within the choroid (Fig. 149b) or breaks through Bruch's membrane to become nodular or fungiform in shape, so that eventually it can be seen through the pupil (Fig. 149d). Metastases are blood-borne, giving rise to secondary growths in many organs, principally the liver, bones, lung and brain. Small tumours can be treated by radiation therapy, light coagulation, or cryotherapy. Eyes with larger tumours should be removed. Prognosis depends upon the degree of cellular differentiation in the tumour and its size. Small well-differentiated tumours have a good prognosis, and if the eye is removed quickly the long term prognosis is good. With tumours larger than 10 mm in diameter that are highly undifferentiated, or where there is evidence of extrascleral extension or metastases, the prognosis is poor. **Differential diagnosis:** Exudative degeneration of the macula, choroidal haemangioma, choroidal naevus

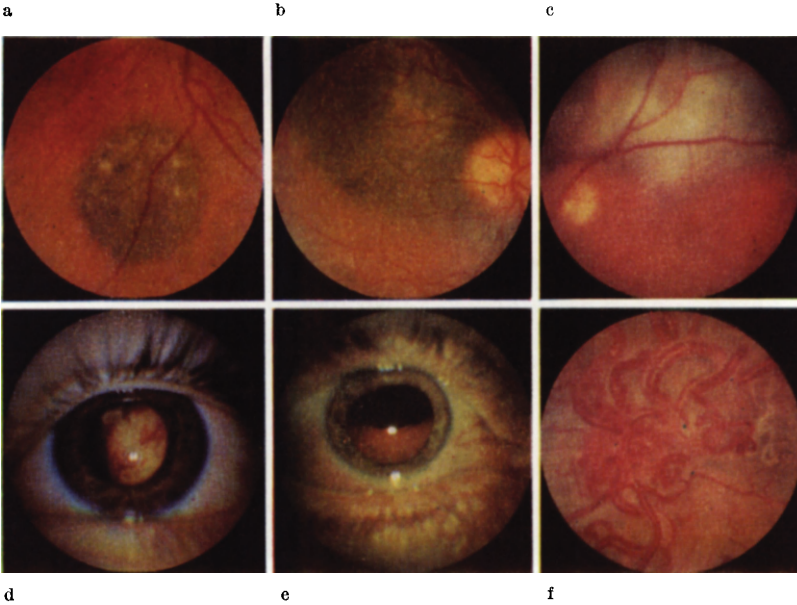


Fig. 149. **a** Choroidal naevus; **b** malignant melanoma of the choroid; **c** metastasis of a breast carcinoma in the choroid; **d** malignant melanoma of the choroid seen through the pupil; **e** malignant melanoma of the choroid seen by transmitted light using an ophthalmoscope; **f** angioma of the retina

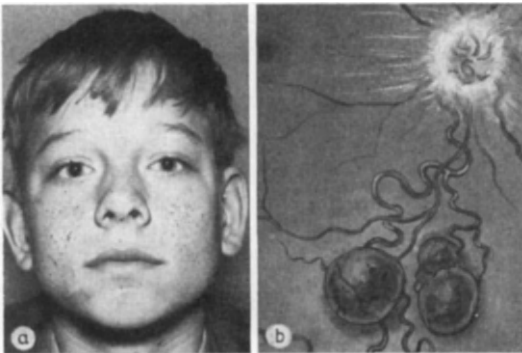


Fig. 150. **a** Sebaceous adenoma of the skin in Bourneville's disease; **b** retinovascular lesions in von Hippel-Lindau's disease

(Fig. 149 a). Secondary tumours of the choroid (Fig. 149 c).

Choroidal naevus: A benign pigmented tumour of the choroid which is rarely seen in childhood but develops early in adulthood. Drusen appear as white spots in the over-

lying Bruch's membrane (Fig. 149 a). Unlike malignant melanomas, there is rarely any overlying retinal degeneration, and visual field defects are infrequently produced. On fluorescein angiography, no pathological circulation is detected in the tumour. **Treat-**

ment: None required. Very occasionally these naevi become malignant, and the patient should be observed at intervals in case this should occur.

Benign retinal tumours are seen in the phakomatoses (conditions with birth spots). In neurofibromatosis (von Recklinghausen's disease) astrocytomas of the retina are occasionally seen. More rarely, swelling of the optic disc may be a feature, with gliomas affecting the optic nerve head (Fig. 147b). A characteristic of *tuberous sclerosis* (Bourneville's disease) is the presence of crystalline mulberry-like deposits at the optic nerve head. Other generalized features in-

clude epileptic seizures, mental deficiency and sebaceous adenomas of the skin (Fig. 150a). In *von Hippel-Lindau's disease* angiomas of the retina are constant features (Fig. 150b). These are associated with A-V malformations of the cerebral cortex and cerebellum, which may give rise to intracranial haemorrhages later in life. Peripheral angiomatous lesions, from which bleeding into the vitreous occasionally occurs, should be treated by light coagulation only if complications occur. *Sturge-Weber syndrome* (angiomatosis encephalofacialis): Large choroidal haemangiomas in these patients give rise to a tomato ketchup appearance when the fundus is viewed with an ophthalmoscope.

13. Optic Disc and Optic Nerve

General considerations

The axons of the ganglion cells converge on the optic disc, which is approximately 1.5 mm in diameter, pierce the sclera at the lamina cribrosa, a sieve-like structure, and combine as nerve fibre bundles separated by connective tissue septa to form the optic nerve (Fig. 151, above). The optic disc, which is devoid of photoreceptors, is a pale pink colour and is often slightly lighter temporally than nasally, as there are fewer blood vessels on the temporal side. The temporal margin is more sharply defined than the nasal, and in old age the rim often becomes pigmented. The central depression is the point from which the blood vessels supplying the retina radiate. Occasionally this central depression may be quite large (physiological excavation, see Fig. 111a). Spontaneous venous pulsation within the confines of the optic rim is detected in some 80 per cent of individuals. This is because the intra-ocular pressure is only just below the venous pressure, so when the systolic pulse enters the choroidal circulation the intra-ocular pressure is transiently raised above that in the veins, the walls of which collapse. Pulsation of the retinal arterioles occurs if firm pressure is applied to the coats of the globe

(ophthalmodynamometry), when the intra-ocular pressure is elevated above the mean perfusion pressure in the central retinal artery or in cases of aortic valve incompetence. The nerve fibres making up the optic nerve normally become myelinated immediately behind the lamina cribrosa. In the

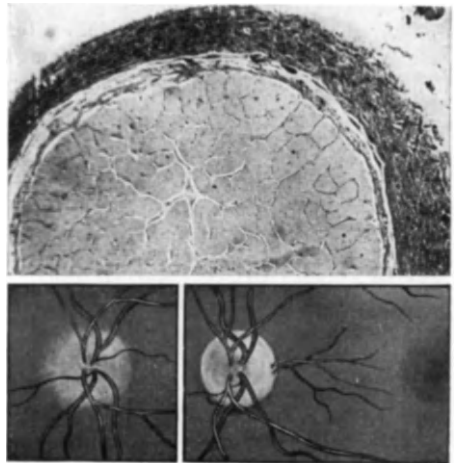


Fig. 151. Above: Histological cross-section of the optic nerve. Below left: Pseudo-papilloedema with blurred optic disc margins. Below right: Cilioretinal artery and vein

ment: None required. Very occasionally these naevi become malignant, and the patient should be observed at intervals in case this should occur.

Benign retinal tumours are seen in the phakomatoses (conditions with birth spots). In neurofibromatosis (von Recklinghausen's disease) astrocytomas of the retina are occasionally seen. More rarely, swelling of the optic disc may be a feature, with gliomas affecting the optic nerve head (Fig. 147b). A characteristic of *tuberous sclerosis* (Bourneville's disease) is the presence of crystalline mulberry-like deposits at the optic nerve head. Other generalized features in-

clude epileptic seizures, mental deficiency and sebaceous adenomas of the skin (Fig. 150a). In *von Hippel-Lindau's disease* angiomas of the retina are constant features (Fig. 150b). These are associated with A-V malformations of the cerebral cortex and cerebellum, which may give rise to intracranial haemorrhages later in life. Peripheral angiomatous lesions, from which bleeding into the vitreous occasionally occurs, should be treated by light coagulation only if complications occur. *Sturge-Weber syndrome* (angiomatosis encephalofacialis): Large choroidal haemangiomas in these patients give rise to a tomato ketchup appearance when the fundus is viewed with an ophthalmoscope.

13. Optic Disc and Optic Nerve

General considerations

The axons of the ganglion cells converge on the optic disc, which is approximately 1.5 mm in diameter, pierce the sclera at the lamina cribrosa, a sieve-like structure, and combine as nerve fibre bundles separated by connective tissue septa to form the optic nerve (Fig. 151, above). The optic disc, which is devoid of photoreceptors, is a pale pink colour and is often slightly lighter temporally than nasally, as there are fewer blood vessels on the temporal side. The temporal margin is more sharply defined than the nasal, and in old age the rim often becomes pigmented. The central depression is the point from which the blood vessels supplying the retina radiate. Occasionally this central depression may be quite large (physiological excavation, see Fig. 111a). Spontaneous venous pulsation within the confines of the optic rim is detected in some 80 per cent of individuals. This is because the intra-ocular pressure is only just below the venous pressure, so when the systolic pulse enters the choroidal circulation the intra-ocular pressure is transiently raised above that in the veins, the walls of which collapse. Pulsation of the retinal arterioles occurs if firm pressure is applied to the coats of the globe

(ophthalmodynamometry), when the intra-ocular pressure is elevated above the mean perfusion pressure in the central retinal artery or in cases of aortic valve incompetence. The nerve fibres making up the optic nerve normally become myelinated immediately behind the lamina cribrosa. In the

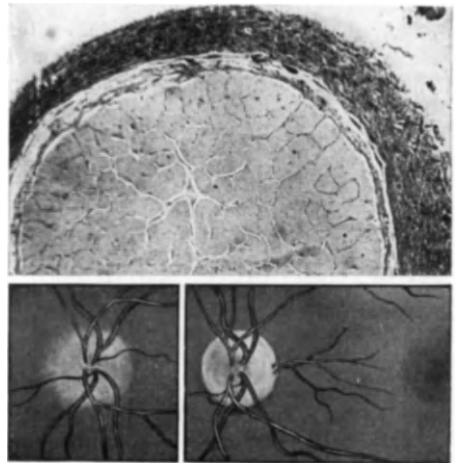


Fig. 151. Above: Histological cross-section of the optic nerve. Below left: Pseudo-papilloedema with blurred optic disc margins. Below right: Cilioretinal artery and vein

orbit the nerve is about 3 cm long and is S-shaped, so that the globe is able to move freely. Like the brain, of which the optic nerve is a part, it is surrounded by three sheaths, the pia mater, the arachnoid and the dura mater. On leaving the orbit the optic nerve enters the optic canal, which is some 7 mm long, and then passes into the cranial cavity, where it becomes the anterior part of the optic chiasm.

Blood supply: The arterial supply to the optic nerve head anterior to the lamina cribrosa is derived from the choroid via the short ciliary arteries. Immediately behind the lamina cribrosa vessels derived from the circle of Zinn, again supplied by the short ciliary arteries, enter the optic nerve. Within the orbit the blood supply is from the pial circulation, and vessels enter the depths of the nerve in the connective tissue septa; more posteriorly, contributions arise from the hypophyseal arteries. The central retinal artery does not normally give any significant contribution to the optic nerve.

Developmental abnormalities

Colobomas of the optic nerve head are often associated with choroidal or iris colobomas. Sometimes remnants of the posterior por-

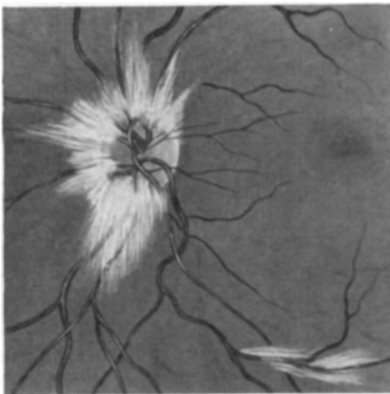


Fig. 152. Myelinated nerve fibres

tion of the hyaloid artery remain (Bergmeister's papilla), or glial sheets persist, and cover the optic nerve (epipapillary membrane). Occasionally, retinal nerve fibres become myelinated, appearing on ophthalmoscopy as bright white flame-shaped streaks, usually contiguous with the edge of the optic disc (Fig. 152), and give rise to corresponding field defects. Cilioretinal vessels (Fig. 151, below right) are a common finding (see Chapter 12).

Congenital swelling of the optic nerve is a physiological variation of the norm frequently seen in patients with axial hypermetropia. The margins are blurred and the disc tissue somewhat elevated. This disc appearance can give rise to confusion with pathological disc swelling resulting from raised intracranial pressure, but unlike the latter, no haemorrhages or exudates are noted on the disc and fluorescein angiographic studies show no abnormal features.

Diseases of the optic nerve

Optic neuritis: Features include fairly sudden visual deterioration due to the development of a central scotoma (Fig. 154a) or, more rarely, almost total visual loss (Fig. 154b). In cases where the anterior part of the optic nerve is involved, swelling of the disc (papillitis) is produced (Fig. 153e), with blurring of the disc margins, hyperaemia of the disc vessels and haemorrhages limited to the disc. When the inflammatory process settles, optic atrophy becomes apparent and the disc shows marked pallor with clearly defined edges (primary optic disc atrophy, Fig. 153d). The afferent pupillary light reflex is impaired in the acute phase.

Retrobulbar neuritis: Inflammation occurs some distance behind the optic nerve head and therefore no disc changes can be identified ophthalmoscopically. Even so, there are the same features as a papillitis, with sudden marked reduction of central visual acuity, and the disc eventually becomes pale, predominantly on the temporal side (Fig. 153f). Patients often complain of

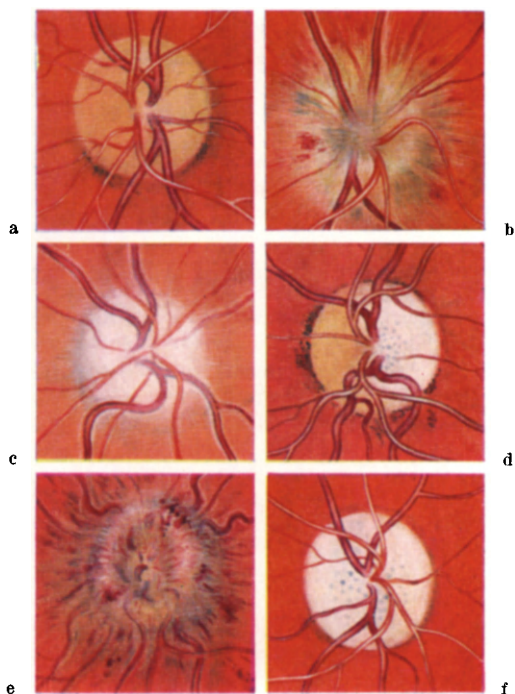


Fig. 153. a Normal optic disc; b papilloedema; c secondary optic atrophy; d primary optic atrophy; e papillitis; f primary optic atrophy (temporal pallor)

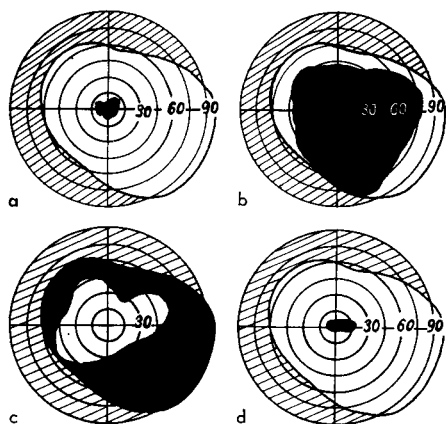


Fig. 154. a Central scotoma (optic neuritis); b extensive visual field loss (optic neuritis); c peripheral limitation of visual field in late papilloedema; d scotoma due to tobacco alcohol poisoning

pain on moving the eye in the active stage of the disease process.

Aetiology: Demyelinating disease (disseminated sclerosis), infections (encephalitis, meningitis), ischaemia (giant cell arteritis, syphilitic papillitis, severe anaemia), toxic (methyl alcohol, lead, etc.), vitamin deficiency (i.e. pernicious anaemia). **Differential diagnosis:** Papilloedema due to raised intracranial pressure, pseudopapilloedema and disc elevation due to drusen (presence of hyaline material within the optic nerve head). In all these conditions the visual acuity is usually not impaired. **Treatment:** The underlying cause should be determined and treated. Systemic corticosteroid therapy is sometimes effective in reducing the time needed to recover in cases of demyelinating disease.

Giant cell arteritis affects patients over the age of 55 years. Initial symptoms include

lassitude, anorexia, muscle pain and weight loss. Later, paresthesia of the scalp develops, with pain on chewing in the temporomandibular joints, and often tenderness and swelling of the temporal arteries occur (Fig. 155a). The disease process frequently involves arterial systems other than the temporal vessels, leading to coronary vascular and ischaemic brain disease. Characteristic pathological changes occur in moderate sized arteries, including fragmentation of the elastic lamina and inflammatory changes in the muscular coats with infiltration by chronic inflammatory cells, including giant cells. Arterial occlusions occur because of swelling of the muscular and intimal layers of the vascular walls. Some 20–40 per cent of patients with the above features develop ischaemic changes in the optic nerve which, once established, result in permanent and complete loss of vision. The plasma viscosity in affected patients is usually grossly elevated and biopsy of a temporal artery is often diagnostic of the changes. **Treatment:** Patients diagnosed as having giant cell arteritis require urgent treatment with doses of prednisolone 60 to 80 mg daily until the plasma viscosity falls to normal limits. The level of steroid dosage is then reduced to one which just keeps the plasma viscosity within the normal limits for the person's age. The disease is self-limiting and does not usually last for longer than 3 years, but steroids may be required for the whole of this period.

Giant cell arteritis is a major cause of ischaemic optic neuritis in the older age group and should always be suspected in any patient over 55 years presenting with sudden painless loss of vision. An emergency plasma viscosity estimation must be performed as part of the initial investigations of such cases.

Papilloedema

Disc oedema due to raised intracranial pressure. There is progressive elevation of the optic nerve head, the disc margins become blurred and the retinal veins con-

gested. The disc vessels are dilated and there are frequently ischaemic pale patches and haemorrhages on the elevated disc (Fig. 153 b). The surrounding retina may show evidence of corrugation, but is free of haemorrhages and exudates. Except in the late stages, papilloedema does not give rise to visual symptoms, apart from transient obscurations of vision lasting for 15 seconds or so. Except for some enlargement of the blind spot, the visual fields are full, unless the afferent visual pathways are involved in the disease process (in significant contrast to optic neuritis). Fluorescein angiographic studies show dilatation of the fine vessels overlying the disc head and leakage of dye from these vessels in the residual phases of the fluorescein transit. If the intracranial pressure remains elevated for some time the optic discs become pale, but unlike optic atrophy due to most other disease processes, the disc margins remain blurred (Fig. 153 c). Concentric irregular contraction of the visual field then occurs (Fig. 154 c), and central vision is eventually lost. In optic atrophy developing **secondary** to papilloedema, relief of raised intracranial pressure may not prevent progressive visual changes. **Differential diagnosis:** Pseudopapilloedema and drusen of the optic nerve head. Disc oedema is seen in malignant hypertension and in central retinal vein thrombosis, but in these widespread retinal changes are present. Swelling of the disc also occurs in severe anaemia, hypoparathyroidism and emphysematous pulmonary disease.

Papilloedema is an extremely important early sign of raised intracranial pressure. Space-occupying lesions within the cranial cavity may give rise to no specific localizing signs, but patients who give a history of headaches on waking in the morning, accompanied by nausea and occasional vomiting, where the headache is made worse by straining or bending down and relieved by analgesics require careful ophthalmoscopic examination of their optic disc.

Aetiology (apart from intracranial tumours): Cerebral abscesses, meningitis, en-

cephalitis and subarachnoid haemorrhages produce this change. Disc swelling is due to intracellular oedema of the nerve fibres. Studies on experimental animals suggest that there must be a continuity between the subarachnoid space within the cranial cavity and that surrounding the optic nerve for papilloedema to occur. It is probable that the raised hydrostatic pressure around the optic nerve causes embarrassment to the choroidal blood supply of the optic nerve head. In addition, flow in the central retinal vein is impaired as it crosses over the subarachnoid space, and blood may be diverted into the ophthalmic artery circulation from the cranial vessels, because of the increased hydrostatic pressure within the cranial cavity. **Treatment:** Reduction of intracranial pressure by radiotherapy or surgical removal of an intracranial neoplasm, draining of abscesses, etc., or, if necessary, a shunting procedure. Opening of the optic nerve sheath within the orbit, permitting subarachnoid fluid to drain out, will also cause resolution of papilloedema.

Optic nerve atrophy

Primary optic nerve atrophy: The optic disc margins become clearly defined and the disc takes on a porcelain-white appearance. The perforations in the lamina cribrosa become visible (Fig. 153 d), and the number of small vessels on the disc is significantly reduced. Disturbances of the visual fields are present, and the afferent pupillary light reflex is impaired. **Aetiology:** **Traumatic**, e.g. following section of the optic nerve within the orbit from knife wounds, and as a complication of fractures involving the optic foramen; **ischaemic**, e.g. in giant cell arteritis, endarteritis in syphilitic optic nerve disease, sarcoidosis, herpes zoster, high voltage radiation and secondary to massive gastro-intestinal bleeds; **compressive:** neoplastic lesions, aneurysms, chronic inflammations, sarcoid, tuberculosis, syphi-

lis; **toxic:** methyl alcohol, lead, nitrobenzine and chronic tobacco/alcohol intoxication. In tobacco/alcohol amblyopia central field defects occur (Fig. 154 d); **demyelinating disease, inflammatory diseases,** sphenoidal sinusitis, encephalitis, meningitis.

Treatment: Should be directed towards the underlying cause.

Consecutive optic atrophy: Secondary to retinal disease in which the ganglion cells have been destroyed, i.e. embolization of the retinal arterial circulation.

Tumours of the optic nerve

In children gliomas of the optic nerve are frequently associated with neurofibromatosis. These tumours are relatively slow growing and do not normally require removal. The most common secondary tumours of the optic nerve head in this age group are leukaemic infiltrations. In adults the most frequently occurring primary tumours are meningiomas (Fig. 155 b), which give rise to exophthalmos and reduction in mobility of the globe. **Treatment:** Surgical.

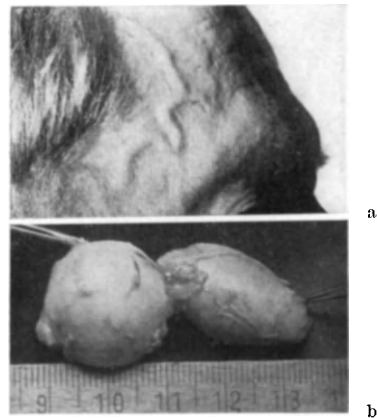


Fig. 155. **a** Prominent temporal arteries in giant cell arteritis; **b** optic nerve meningioma; the tumour and the eyeball have been removed

14. Optic Pathways

Anatomy

The afferent visual pathways (Fig. 156) are made up of the following components: optic nerve (I) → optic chiasm (II), in which the nerve fibres originating from the temporal

side of the retina do not cross, whereas the fibres coming from the nasal retina cross → optic tract (III) → lateral geniculate body (IV) → optic radiation (V) → primary visual centre in the occipital cortex (VI) which is located in the striate area around the calcarine fissure (Fig. 157, above). Subsequent neural pathways project to the association visual areas in the peri- and para-striate cortex, and to the contralateral visual areas via the corpus callosum (Fig. 157, above b-c).

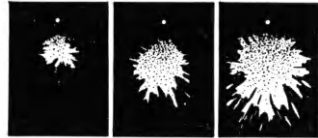
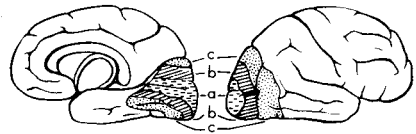
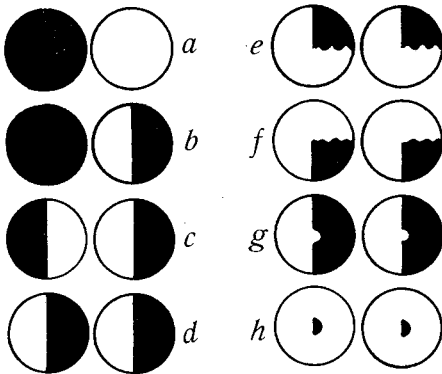
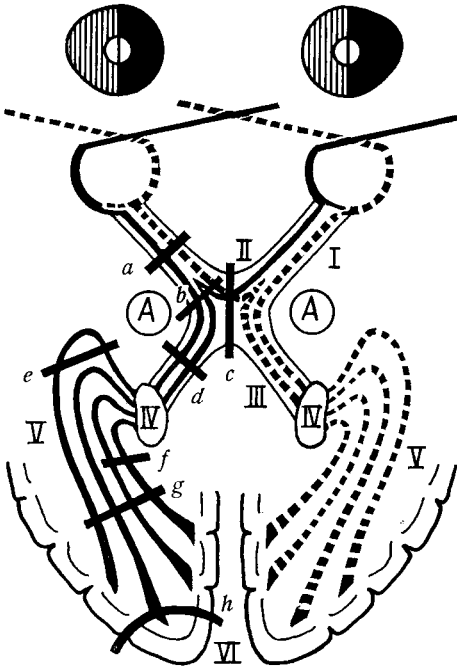


Fig. 157. Above: The cortical visual centres (occipital cortex). a Area striata; b area parastriata; c area peristriata. Below: Development of flickering scotoma in migraine

Disturbances of the optic pathways

Optic nerve (Fig. 156a): Lesions of one optic nerve cause a unilateral visual field defect and an impaired direct pupillary light reflex.

Optic chiasm: The topography of the optic chiasm area, is shown in Fig. 158. **Features of chiasmal lesions:** Disturbances of the afferent pathways in the chiasm give rise to bilateral field defects, typically a bitempo-

Fig. 156. Schematic diagram of the optic pathway, showing the most important sites of possible lesions together with the corresponding visual field losses (see text. A: internal carotid artery)

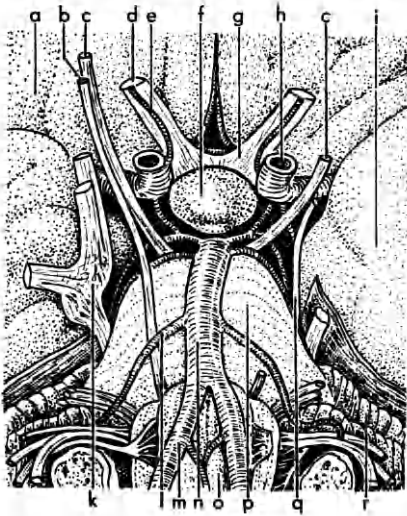


Fig. 158. Topography of the optic chiasm area: a frontal lobe; b abducens nerve; c oculomotor nerve; d optic nerve; e ophthalmic artery; f pituitary gland; g optic chiasm; h internal carotid artery; i temporal lobe; k Gasserian ganglion with the three branches of the trigeminal nerve; l inferior anterior cerebellar artery; m vertebral artery; n basilar artery; o pyramidal fibres; p pons; q trochlear nerve; r cerebellum

ral hemianopia. Pituitary tumours arising out of the pituitary fossa tend to compress the midline structures of the chiasm, causing congruous (symmetrical) visual field defects (Fig. 159a), which initially appear in the upper temporal quadrants. These tumours have to be quite large before compression occurs (some 2 cm in diameter). As the tumour grows, so the inferior temporal quadrants (Fig. 156c) and then the nasal quadrants become involved until, finally, the visual fields are extinguished. In patients where chiasmal compression is diagnosed early, removal of the tumour may restore the visual fields. Chiasmal compression is also caused by meningiomas and aneurysms pressing on the side of the chiasm; these produce very asymmetrical bitemporal field defects. Craniopharyngiomas, pressing down from above, give rise initially to inferior quadrantic defects. Compression of the anterior part of the chiasm may result in a severe unilateral field defect, and early involvement of the contralateral field (Fig. 156b) may sometimes only be detected by very careful perimetry. Very rarely, binasal visual field defects have been reported, and these may be due to thickening of the walls of both internal carotids, compressing the uncrossed chiasmal fibres, or, conversely, to dilatation of the third ventricle pushing the uncrossed fibres against the internal carotid arteries (Fig. 159b). Additional causes of bitemporal field defects include multiple sclerosis and trauma. In the latter, following sudden deceleration the chiasm is possibly thrown forwards against the anterior clinoid processes and split down the midline. Tumours of the olfactory groove occasionally lead to the Foster-Kennedy syndrome, a condition in which a tumour compresses one optic nerve, giving rise to optic atrophy, and as a result of raised intracranial pressure, produces papilloedema of the opposite disc. Once optic atrophy has developed, papilloedema cannot occur since there are no axons left to swell.

Chiasmal arachnoiditis is caused by chronic inflammation involving the chiasmal area following meningitis or trauma, including

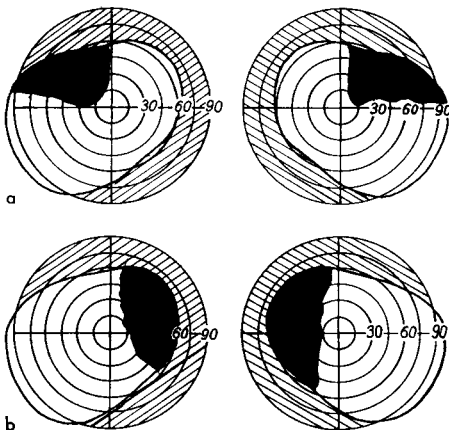


Fig. 159. a Bitemporal quadrantic visual field loss; b incomplete binasal hemianopia

surgical operations. Visual field loss is gradual, progressive and irregular, and optic atrophy becomes apparent. A similar condition may be seen after hypophysectomy, when scar tissue pulls the chiasm down into the pituitary fossa (empty-sella syndrome). **Treatment:** None effective.

Optic tract: Lesions of the optic tract produce grossly incongruous (asymmetrical) hemianopic visual field defects. Pathology of the right optic tract gives rise to left-sided visual field defects. As a rule, the greater the incongruity of a homonymous visual field defect, the nearer the lesion is to the chiasm; the greater the congruity, the nearer to the occipital cortex (Fig. 156h); macula sparing usually indicates that the lesion is suprageniculate (Fig. 156g). If a complete hemianopic visual field defect is detected, however, little localizing information can be derived from visual field examination in isolation (Fig. 156d). With lesions solely involving the optic tract or radiation, central visual acuity is not impaired, though reading may be disturbed because the beginning of a page cannot be found, or letters are lost on scanning from left to right. **Aetiology and treatment:** See below.

Optic radiation and striata area of the occipital cortex: Lesions of these areas result in more congruous homonymous defects than optic tract lesions. Pathological changes in the temporal lobe may involve the fibres looping over the inferior ventricle, and give rise to upper visual field defects (Fig. 156e), whereas disturbances of the parietal lobe produce inferior homonymous defects (Fig. 156f). **Aetiology:** Tumours, arteriovenous malformations, cerebral vas-

cular occlusions, hypoxia, etc. **Treatment:** Should be directed towards the underlying cause.

Visual agnosia: Disturbances of the association visual areas may result in the patient being unable to interpret what he sees, i.e. to read, to name objects in everyday use or to recognize colours.

Patients with bilateral occipital lesions involving the macular projection areas are blind, and confusion may arise because the pupillary light reflexes are present. A common cause of occipital blindness is transient cardiac or respiratory arrest. Although the occipital cortex appears to be well supplied by blood vessels from the middle and posterior cerebral arteries, this part of the brain is at the extremity of both systems (watershed area). Hypoxia of the occipital cortex may therefore produce infarctions of the striate areas. Some degree of recovery usually occurs if the patient regains full consciousness; initially, differentiation between light and dark is appreciated, and later movement sense recognized. Fine acuity and colour appreciation may take longer to improve.

Ophthalmic migraine: Classic attacks are heralded by the presence of flickering scotomas (Fig. 157, below) due to disturbances of the occipital cortex, possibly as a result of vascular spasm. Unformed visual hallucinations last for no more than 20 minutes and are frequently followed by a severe incapacitating headache, which is relieved by the patient lying down or going to sleep. Rarely, patients suffering from migraine develop extra-ocular muscle palsies (ophthalmoplegic migraine) and permanent visual field defects.

15. Orbit

Anatomy

The walls of the orbital cavity are composed of seven bones (Fig. 160); inferiorly and medially the bones lining the orbit are only 0.3 mm thick in

places. Fig. 161 shows the important structures adjacent to the orbit seen on X-ray examination, i.e. frontal, maxillary and sphenoidal sinuses, anterior and middle cranial fossae, cavernous sinus and the sella turcica containing the pituitary gland.

surgical operations. Visual field loss is gradual, progressive and irregular, and optic atrophy becomes apparent. A similar condition may be seen after hypophysectomy, when scar tissue pulls the chiasm down into the pituitary fossa (empty-sella syndrome). **Treatment:** None effective.

Optic tract: Lesions of the optic tract produce grossly incongruous (asymmetrical) hemianopic visual field defects. Pathology of the right optic tract gives rise to left-sided visual field defects. As a rule, the greater the incongruity of a homonymous visual field defect, the nearer the lesion is to the chiasm; the greater the congruity, the nearer to the occipital cortex (Fig. 156h); macula sparing usually indicates that the lesion is suprageniculate (Fig. 156g). If a complete hemianopic visual field defect is detected, however, little localizing information can be derived from visual field examination in isolation (Fig. 156d). With lesions solely involving the optic tract or radiation, central visual acuity is not impaired, though reading may be disturbed because the beginning of a page cannot be found, or letters are lost on scanning from left to right. **Aetiology and treatment:** See below.

Optic radiation and striata area of the occipital cortex: Lesions of these areas result in more congruous homonymous defects than optic tract lesions. Pathological changes in the temporal lobe may involve the fibres looping over the inferior ventricle, and give rise to upper visual field defects (Fig. 156e), whereas disturbances of the parietal lobe produce inferior homonymous defects (Fig. 156f). **Aetiology:** Tumours, arteriovenous malformations, cerebral vas-

cular occlusions, hypoxia, etc. **Treatment:** Should be directed towards the underlying cause.

Visual agnosia: Disturbances of the association visual areas may result in the patient being unable to interpret what he sees, i.e. to read, to name objects in everyday use or to recognize colours.

Patients with bilateral occipital lesions involving the macular projection areas are blind, and confusion may arise because the pupillary light reflexes are present. A common cause of occipital blindness is transient cardiac or respiratory arrest. Although the occipital cortex appears to be well supplied by blood vessels from the middle and posterior cerebral arteries, this part of the brain is at the extremity of both systems (watershed area). Hypoxia of the occipital cortex may therefore produce infarctions of the striate areas. Some degree of recovery usually occurs if the patient regains full consciousness; initially, differentiation between light and dark is appreciated, and later movement sense recognized. Fine acuity and colour appreciation may take longer to improve.

Ophthalmic migraine: Classic attacks are heralded by the presence of flickering scotomas (Fig. 157, below) due to disturbances of the occipital cortex, possibly as a result of vascular spasm. Unformed visual hallucinations last for no more than 20 minutes and are frequently followed by a severe incapacitating headache, which is relieved by the patient lying down or going to sleep. Rarely, patients suffering from migraine develop extra-ocular muscle palsies (ophthalmoplegic migraine) and permanent visual field defects.

15. Orbit

Anatomy

The walls of the orbital cavity are composed of seven bones (Fig. 160); inferiorly and medially the bones lining the orbit are only 0.3 mm thick in

places. Fig. 161 shows the important structures adjacent to the orbit seen on X-ray examination, i.e. frontal, maxillary and sphenoidal sinuses, anterior and middle cranial fossae, cavernous sinus and the sella turcica containing the pituitary gland.

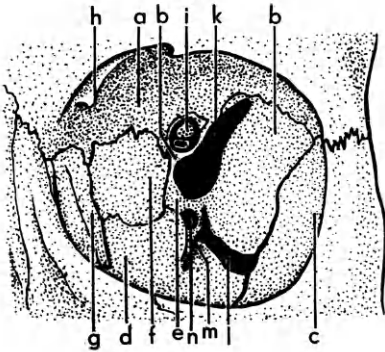


Fig. 160. Bones and openings of the left orbit. a Frontal bone; b sphenoid bone; c zygomatic bone; d maxilla; e palatine bone; f ethmoidal bone; g lacrimal bone; h trochlea; i optic canal with optic nerve and ophthalmic artery; k superior orbital fissure; l inferior orbital fissure; m infra-orbital groove; n foramen rotundum

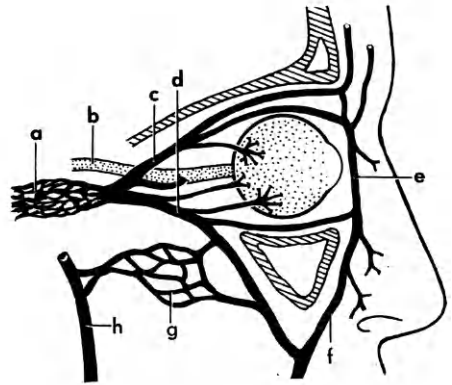


Fig. 162. Venous drainage from the orbit. a Cavernous sinus; b optic nerve; c superior ophthalmic vein; d inferior ophthalmic vein; e angular vein; f anterior facial vein; g pterygoid plexus; h retro-mandibular vein

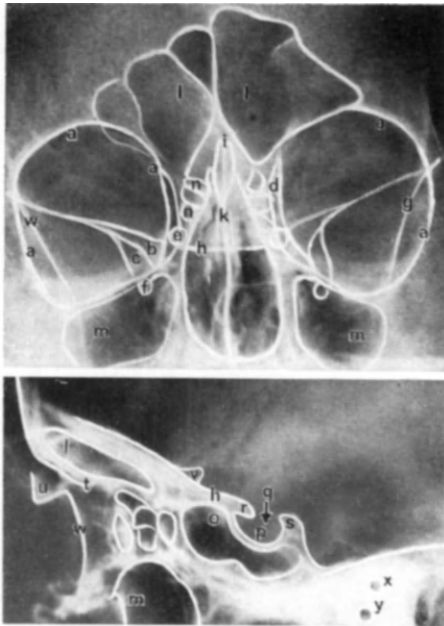


Fig. 161. X-rays of the orbit: above: anteroposterior view; below: lateral view. a Orbital margin; b lesser wing of sphenoid; c superior orbital fissure; d an-

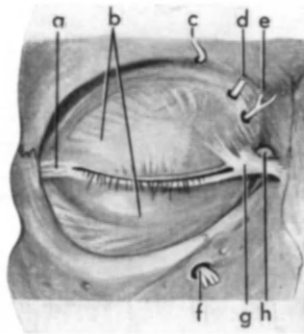


Fig. 163. Anterior aspect of orbit. a Lateral palpebral ligament; b orbital septum; c supra-orbital nerve; d supratrochlear nerve; e infratrochlear nerve; f infra-orbital nerve; g medial palpebral ligament; h top of lacrimal sac

terior lacrimal crest; e optic canal; f foramen rotundum; g linea innominata; h planum sphenoidum; i crista Galli; k nasal septum; l frontal sinus; m maxillary sinus; n ethmoid sinus; o sphenoid sinus; p floor of sella turcica; q entrance to sella turcica; r anterior clinoid process; s dorsum sellae with posterior clinoid process; t roof of orbit; u nasal bone; v great wing of sphenoid; w zygomatic bone; x internal opening of auditory canal; y external opening of auditory canal

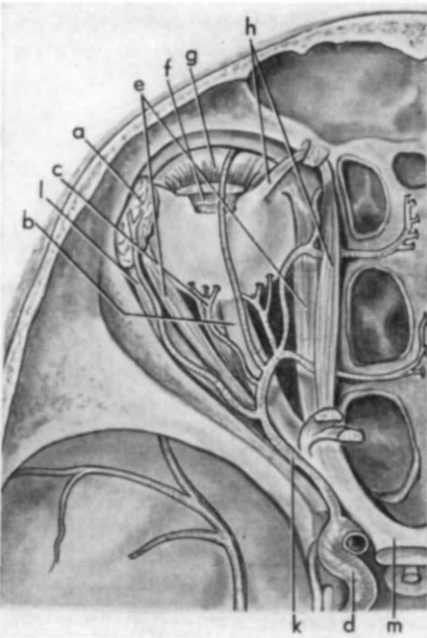
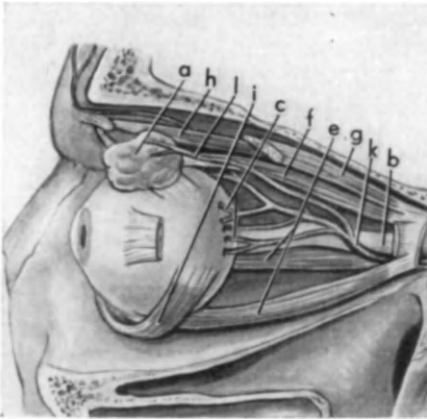


Fig. 164. Lateral and superior views of orbital contents. **a** Lacrimal gland; **b** optic nerve; **c** short ciliary arteries; **d** internal carotid artery; **e** lateral, medial and inferior rectus muscles; **f** superior rectus muscle; **g** levator palpebrae muscle (resected); **h** superior oblique muscle; **i** inferior oblique muscle; **k** ophthalmic artery; **l** lacrimal artery; **m** optic chiasm

Openings into the orbit: The optic foramen provides a passage for the optic nerve and the ophthalmic artery, and the superior orbital fissure for the 3rd (oculomotor), 4th (trochlear) and 6th (abducens) nerves. The ophthalmic division of the 5th (trigeminal) nerve divides within the fissure into its orbital branches (frontal, lacrimal and nasociliary nerves). The maxillary nerve (2nd branch of the trigeminal nerve) passes into the orbit through the inferior orbital fissure and becomes the inferior or-

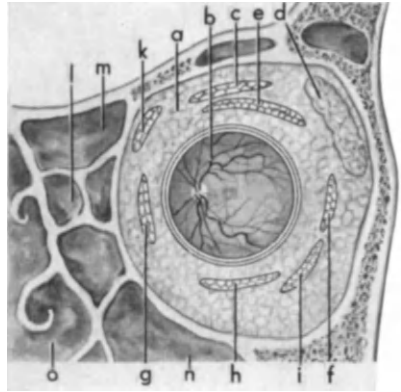


Fig. 165. Frontal section through the orbit approx. 2 cm posterior to the cornea. **a** Orbital fatty tissue; **b** eyeball with optic disc and macula; **c** levator palpebrae muscle; **d** lacrimal gland; **e-h** superior, lateral, medial and inferior rectus muscles; **i-k** inferior and superior oblique muscles; **l** ethmoidal sinus; **m** frontal sinus; **n** maxillary sinus; **o** nasal cavity

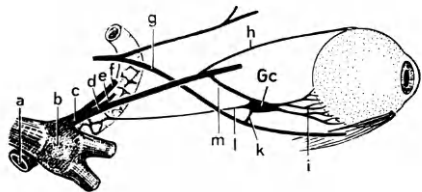


Fig. 166. Ciliary ganglion: **a** internal carotid artery; **b** Gasserian ganglion; **c** ophthalmic nerve; **d** nasociliary nerve; **e** frontal nerve; **f** lacrimal nerve; **g** oculomotor nerve; **h** long ciliary nerves; **i** short ciliary nerves; **k** oculomotor branch to ciliary ganglion; **l** sympathetic branch to ciliary ganglion; **m** sensory branch to ciliary ganglion

bital nerve, which runs along the floor of the orbit in the infra-orbital groove. The superior ophthalmic vein passes through the superior orbital fissure to drain into the cavernous sinus; the inferior ophthalmic vein, however, leaves the orbit via the inferior orbital fissure (Fig. 162).

These orbital veins have no valves but communicate with the facial veins. Following infections of the upper lip, nose or orbit, infection may easily spread, if phlebitis occurs, into the cavernous sinus, causing a cavernous sinus thrombosis. The orbital contents are shown in Figs. 164 and 165. Orbital fat acts as a cushion which protects the eyeball from blunt frontal injuries. The orbital contents are also protected in front by the orbital septa and the lids. (Fig. 163 shows the vessels and nerves that perforate the orbital septum to reach the lid tissues.)

The nerve supply of the orbit, eyeball, conjunctiva and skin of the upper lid is by branches from the ophthalmic division of the trigeminal nerve. The sensory supply to the skin of the lower lids and cheeks is from the infra-orbital division of the maxillary nerve. For the autonomic nerve supply, see Chapter 9. The ciliary ganglion is located approximately 15 mm posterior to the eyeball and receives parasympathetic fibres from the oculomotor nerve, sensory branches from the trigeminal nerve and contributions from the sympathetic nervous system (Fig. 166). The ciliary nerves, with contributions from all three nerve supplies, pass through the sclera close to the entry of the optic nerve.

Disturbances in the position of the globe in relation to the orbit

Exophthalmos (bulbar protrusion or proptosis): Produced by any space-occupying lesion within the orbit. Because of forward protrusion of the globe the palpebral aperture is widened and bulbar mobility may be reduced. The degree of protrusion of the eyeball is measured by means of an exophthalmometer (Fig. 167 a). The footpieces of this instrument are placed on the firm lateral orbital margins. The instrument contains a system of mirrors and a scale, so that the distance between the lateral orbital margin and the apex of the cornea can be measured. **Causes of unilateral exophthalmos** include dysthyroidism, orbital inflammation, e.g. orbital cellulitis, mucoceles arising from the surrounding sinuses, orbital tumours, granulomas and parasitic

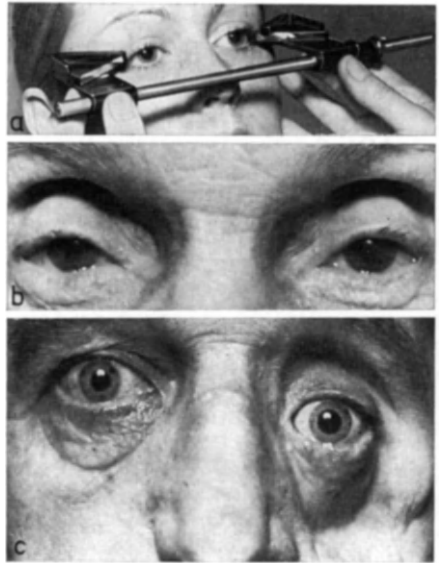

Fig. 167. a Hertel's exophthalmometer; b exophthalmos in elderly woman; c position of the left eye following fracture of the maxilla

cysts. **Pulsating exophthalmos**: Commonest cause in adults is a carotico-cavernous sinus fistula. Blood under high pressure escapes from a defect in the wall of the internal carotid artery within the cavernous sinus. The grossly dilated ophthalmic veins therefore carry arterial blood under high pressure, and the pulsation in these vessels is transmitted to the globe, which becomes proptosed. Pulsating exophthalmos is sometimes a feature of neurofibromatosis, as the superior orbital fissure is often extremely wide in this condition so that spontaneous pulsation from the brain is transmitted to the globe. **Bilateral exophthalmos** is usually a feature of thyroid disease, but can, more rarely, occur in diseases of the haemopoietic system and as a result of developmental abnormalities.

Axial proptosis is produced by space-occupying lesions arising within the muscle cone. Space-occupying lesions external to the muscle cone cause the eyeball to be

deviated out of the axial plane (Fig. 170a-c). All patients with axial proptosis should be carefully investigated for thyroid disease. Plain X-ray studies may reveal the presence of calcification in vascular tumours and meningiomas. Carotid angiographic studies will also show the presence of vascular tumours within the orbit, especially if subtraction techniques are employed. Ultrasonic and EMI scan investigations can be extremely helpful, and careful examination of the surrounding sinuses may show primary disease located at these sites. Pseudoproptosis occurs when the eye is bigger than normal, i.e. in myopia and buphthalmos.

Enophthalmos: The eye is recessed within the orbit and this occurs with excessive dehydration or weight loss, in old age due to atrophy of the orbital fat (Fig. 167b) and as a consequence of fractures of the orbital floor, see Chapter 16. Pseudo-enophthalmos occurs when the eye is smaller than normal (in microphthalmos and phthisis bulbi).

Inflammatory disorders

Orbital cellulitis: Clinical features are exophthalmos, chemosis (oedema of the bulbar conjunctiva), swelling of the lids and, not infrequently, a fixed and immobile pupil. The patient complains of malaise, with ocular pain radiating to the head. Haematological investigations show a leucocytosis and an increased plasma viscosity.

Complications: Cavernous sinus thrombosis and meningitis. If cavernous sinus thrombosis occurs, the patient becomes very ill, develops a severe headache and lapses into a coma. The prognosis is poor and some 50 per cent of patients die, in spite of intensive medical therapy, because the focus of infection is isolated by the blood-brain barrier and is inaccessible to surgical drainage procedures.

Aetiology: Following the spread of frontal and ethmoidal sinus infection, infections of the upper lids, nose or eyelids, infected injuries and secondary to panophthalmitis.

The most common cause in children is ethmoidal sinusitis. **Treatment**: Patients must be admitted to hospital immediately and receive suitable broad spectrum systemic antibiotic therapy. Investigations are carried out to ascertain the primary cause of infection.

Orbital apex syndrome: Inflammatory or neoplastic lesions of the orbital apex result in paralysis of all the extra-ocular muscles. With inflammatory lesions there is often severe ocular pain. Proptosis is present, and if the optic nerve becomes involved visual field defects develop. **Treatment**: To ascertain the nature of the lesions and treat as necessary.

Endocrine exophthalmos

Although it is commonly stated that exophthalmos is associated with a thyrotoxic state, in fact forward protrusion of the globe also occurs in euthyroid and hypothyroid

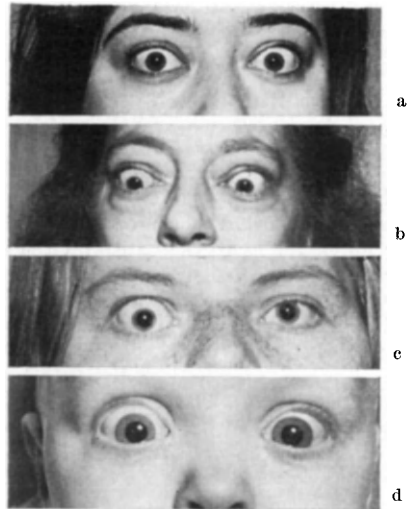


Fig. 168. a Dysthyroid exophthalmos; b Graefe's sign when the eyes are rotated downwards; c unilateral exophthalmos in hyperthyroidism in a young girl; d lid retraction in a child

states. Ocular signs related specifically to the hyperthyroid state include Graefe's sign (lid lag when the eye is rotated downwards, Fig. 168b), Stellwag's sign (infrequent blinking) and Dalrymple's sign (sclera is visible above the cornea on looking straight ahead because there is retraction of the upper lid, Fig. 168a). The latter sign should not be confused with widening of the palpebral aperture due to exophthalmos. Thyrotoxicosis can occur at any age, but is only rarely seen in children (Fig. 168d).

Dysthyroid exophthalmos: The condition is unilateral in approximately 10 per cent of patients (Fig. 168c). The axial protrusion of the globe is caused by accumulation of water, fat, chronic inflammatory cells and mucopolysaccharides in the retrobulbar space.

Malignant exophthalmos (Fig. 169, above): The rate of forward protrusion of the globe is rapid. There is chemosis of the conjunctiva, and the vessels over the medial and lateral recti are engorged. The cornea becomes exposed as the lids are unable to provide protection, giving rise to desiccation of the cornea, infection and corneal ulceration (Fig. 169, below). **Treatment**: This

is an emergency. With moderate degrees of exophthalmos sewing together of the lids (tarsorrhaphy) may be sufficient to provide corneal protection. However, in severe cases it is necessary to decompress the orbit by removing the lateral bony wall so as to allow the orbital contents to expand. In some patients the rise in pressure in the orbit is sufficiently great to interfere with the blood supply of the retina and optic nerve head, resulting in rapid visual deterioration. The extra-ocular muscles also become thickened in malignant exophthalmos due to an uptake of water, deposition of mucopolysaccharides and invasion by chronic inflammatory cells. Fibrous changes subsequently develop, particularly in the inferior and medial recti, resulting in a limitation of globe motility, especially upwards and on abduction. Surgery is then necessary if binocular vision is to be regained, but should only be carried out when the active phase of the disease has subsided. Malignant exophthalmos is a self-limiting disease, and the active stage rarely lasts for more than 3 years. Providing treatment is carried out quickly, corneal scarring with ulceration or, more seriously, corneal perforation need never occur.

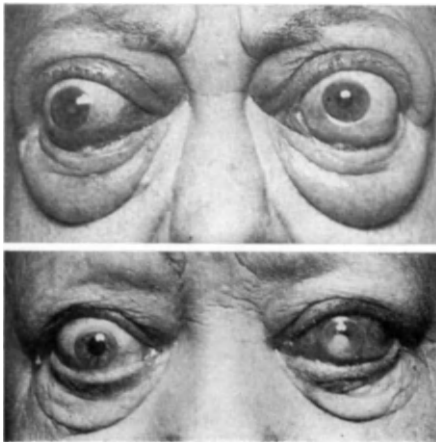

Fig. 169. Above: Malignant exophthalmos; below: malignant exophthalmos with corneal ulcer

Tumours

The main feature is usually a slowly progressive exophthalmos accompanied by a gradual reduction of ocular mobility. Refractive changes occur if a tumour presses on the posterior pole of the globe, reducing the axial length of the eye, or if the tumour indents the globe laterally, causing corneal astigmatism. The globe is pushed backwards into the orbit with difficulty in the case of solid tumours, but with vascular tumours the globe can easily be repulsed. Optic atrophy develops when a tumour presses on the optic nerve. **Aetiology**: **Primary orbital tumours** include angiomas, mixed cell tumours of the lacrimal gland, neurofibromas and, more rarely, gliomas. Occasionally, sarcomatous tumours arise

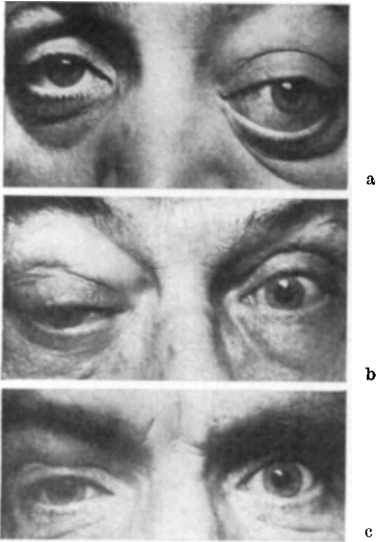


Fig. 170. a Exophthalmos of the left eye with displacement of the eyeball due to a tumour arising from the left frontal sinus; b exophthalmos of the right eye due to an orbital tumour arising outside the muscle cone; c mucocele in right frontal sinus

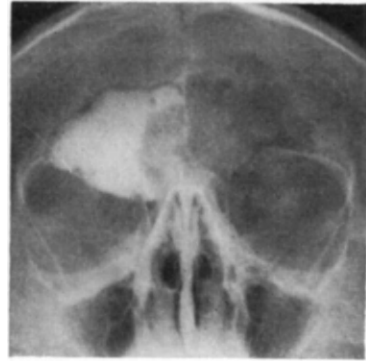


Fig. 171. X-ray of an osteoma in the region of the right frontal sinus

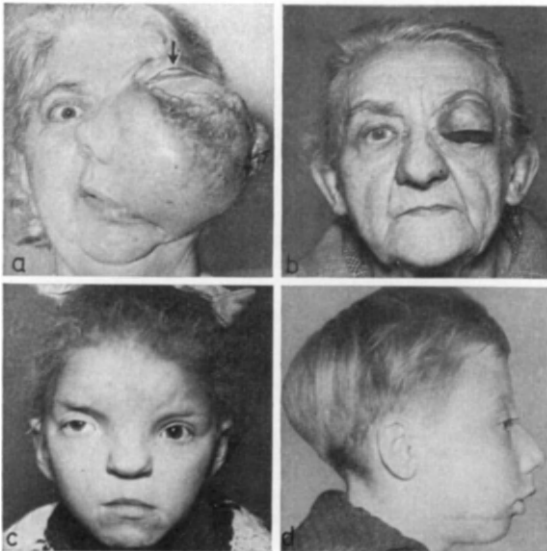

Fig. 172. a Tumour of the left maxillary sinus with upwards displacement of the eye (arrow); b orbital sarcoma; c hypertelorism; d acrocephaly

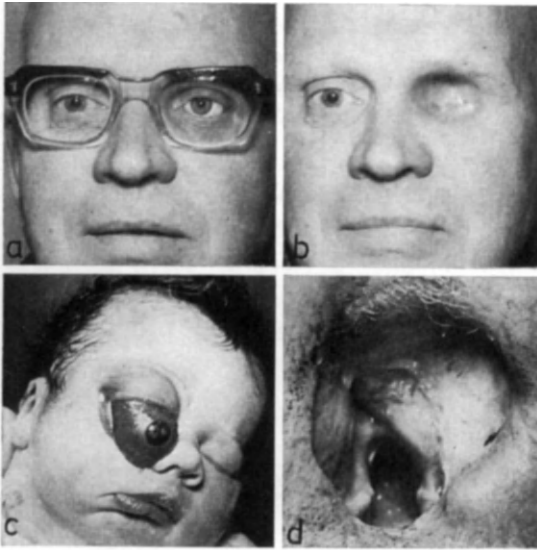


Fig. 173. a-b Appearance following orbital exenteration of the left eye, with and without a prosthesis; c teratoma of the orbit; d orbital cavity following exenteration with tumour invasion of the nasal sinuses

from the surrounding bones, connective tissues or muscles (Fig. 172b). **Metastatic deposits** not infrequently occur secondary to breast and bronchial carcinomas. Tumours of the cranial cavity may also spread through to the orbit, as can neoplastic lesions from the nasopharynx and surrounding sinuses (Figs. 170a, 171, 172b). Leukaemic deposits, lymphogranulomas, frequently develop within the orbit. **Differential diagnosis:** Mucocoeles of the surrounding sinuses (Fig. 170c), granulomatous lesions, i.e. sarcoid and non-specific chronic inflammatory disturbances within the orbit (pseudo-tumours), and parasitic cysts. **Treatment:** Should be directed towards the cause. Surgical exploration of the orbit should be performed for any neoplastic tumour which is potentially removable and orbital exenteration reserved for cases with extremely malignant tumours, where removal of the globe and orbital contents could be a life-

-saving procedure (Fig. 173b). The cosmetic appearance can be improved after this mutilating operation by fitting a prosthesis attached to spectacles (Fig. 173a). Irradiation is often effective in reducing the proptosis in secondary metastatic deposits and leukaemic infiltrates, etc.

Intermittent exophthalmos: Forward protrusion of the globe which becomes obvious on bending down or straining. **Aetiology:** Varices of the orbit.

Developmental abnormalities

In some cranial malformations the orbits are set very widely apart (hypertelorism, Fig. 172c). Associated defects include optic atrophy and strabismus. In acrocephaly (Fig. 172d) the orbits are shallow and the globes protrude forwards.

16. Trauma

All accidents involving the eyes should be regarded as emergencies until proved otherwise. Records of patients seen with ocular injuries must be carefully documented with special reference to the nature of the injury, the occupation of the individual at the time of the accident and whether any precautions were being taken to try to prevent ocular damage. The extent of the ocular injury must be noted in detail when a complete examination is carried out (see below) and treatment prescribed clearly indicated.

Injuries to the orbit

Large retrobulbar haematomas are produced as a result of stab injuries or missiles burying themselves deeply in the orbit. The position of any radio-opaque foreign body

requires localization by means of X-ray examination (Fig. 174). Rarely, the globe may be levered forwards in the orbit following, for example, penetration of the orbit with an umbrella ferrule or a cow's horn (Fig. 175a), causing a rupture of the optic nerve, usually at the optic nerve head. It

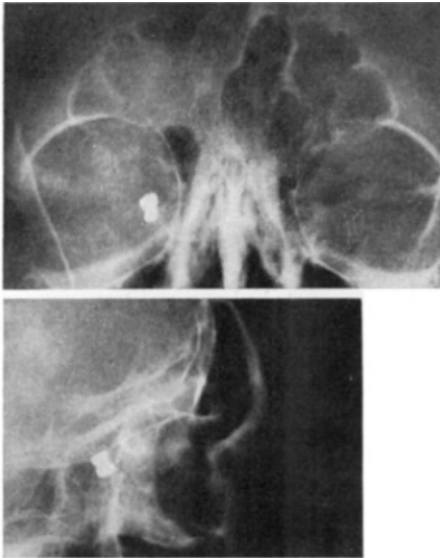

Fig. 174. Foreign body (algun pellet) in the orbit (frontal and temporal X-ray)

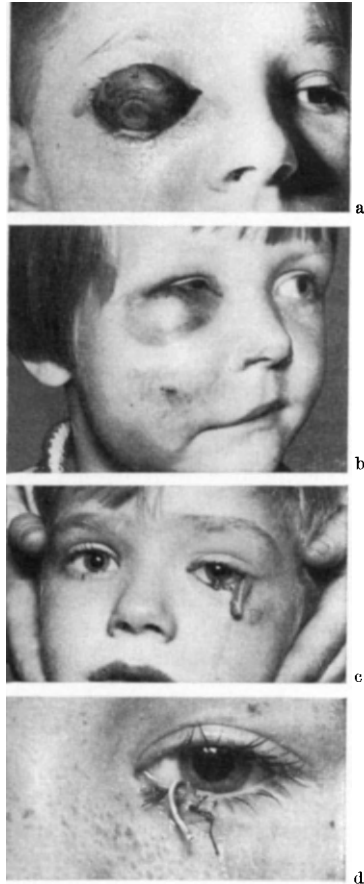

Fig. 175. a Luxation of the eyeball anterior to the orbit; b lid haematoma; c severe laceration of the lower lid; d laceration of the lid (sutured) with canaliculus repair

should always be borne in mind that foreign bodies entering the orbit can penetrate into the cranial cavity. Surgical exploration in cases where this has occurred should be undertaken by individuals with neurosurgical and ophthalmic expertise.

Fractures

Blow-out fractures develop following a heavy blow to the globe and the infra-orbital margin from the front. The thin roof of the maxillary sinus fractures, allowing orbital fat and the inferior rectus muscle to prolapse into the maxillary sinus (Fig. 176, above). Features of a blow-out fracture include an intact infra-orbital rim and enophthalmos due to loss of orbital fat, an-

aesthesia of the cheek due to trauma to the infra-orbital nerve and defective elevation of the eye because of entrapment of the inferior rectus muscle or adjacent connective tissue. **Treatment:** Surgical repair of the orbital floor and replacement of orbital tissues in their correct positions should be performed within 10 days when diplopia is present in the primary position and no recovery is detected. If the condition is not diagnosed and surgery is delayed, fibrotic changes develop and the patient may suffer from permanent vertical diplopia. Fractures of the maxilla, including the orbital rim, can result in an eye being displaced downwards. Major maxillofacial surgery is necessary to repair the bony and soft tissue injuries (Fig. 167c).

Fractures of the medial wall of the orbit: **Emphysema of the orbital tissues** occurs following fractures of the ethmoidal bones. Crepitation is noted in the lids and surrounding skin; the globe is proptosed. X-rays of the orbit reveal the presence of air in the retrobulbar space. **Treatment:** As purulent material from the sinuses can produce orbital cellulitis, a course of systemic antibiotics is indicated.

Fractures of the roof of the orbit: Small children playing with scissors or knitting needles, etc., and falling on to these instruments may sustain a perforating wound of the upper lid; the sharp point can proceed to penetrate the thin orbital roof and enter the anterior cranial fossa. After such accidents, X-ray studies must be performed, since a complication of these injuries is the development of frontal lobe abscesses. Fracture of the trochlea may occur in injuries involving the upper part of the orbit, leading to underaction of the superior oblique muscle.

Injuries to the eyelids

Haematomas of the lids readily develop after facial injuries owing to the laxity of the subcutaneous tissue at this site (Fig. 175b). Severe lid lacerations are common features

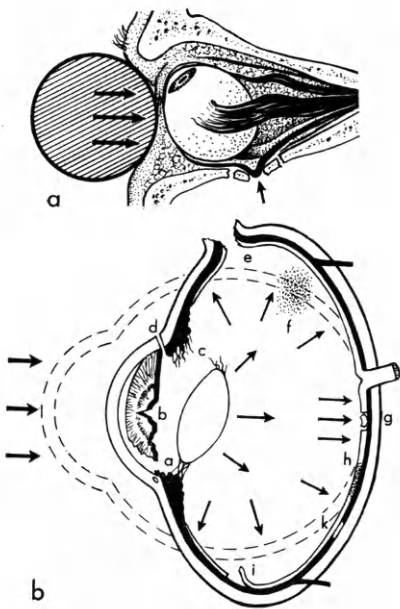


Fig. 176. Above: Blow-out fracture caused by frontal impact of a tennisball. Below: Possible consequences of contusion of the eye: a iridodialysis; b tear in sphincter pupillae muscle; c rupture of the zonule; d rupture of the eyeball at corneal limbus; e rupture of the sclera; f vitreous haemorrhage; g macular hole; h retinal haemorrhage; i retinal tear; k rupture of choroid

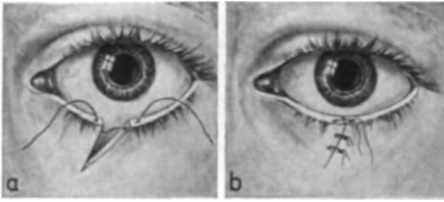


Fig. 177. Surgical repair of lid laceration

of road traffic accidents in which the individual has been ejected through the windscreen and the face forced down on to retained fragments of glass in the window rim. Full thickness lacerations of the lids are not infrequently caused in children by dog bites (Fig. 175c), and the lower canaliculus is often torn in such cases.

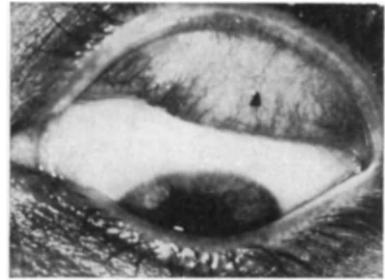
Treatment: Careful approximation of the wound edges, layer by layer, to ensure accurate apposition of the lid margins and restoration of muscle function (Fig. 177). Complications include ptosis, epiphora, cicatricial contraction of the scars → corneal exposure. If a canaliculus has been severed, a fine filament of silicone or nylon should be threaded through the exposed ends and retained in position until the tissues are fully healed (Fig. 175d).

Foreign bodies: Subtarsal foreign bodies produce a foreign body sensation, causing blepharospasm and tearing (Fig. 178a).

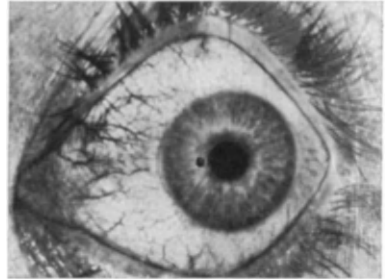
Treatment: Eversion of the upper lid and removal of the foreign body.

Mechanical injuries to the globe

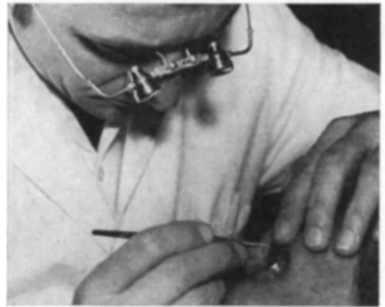Corneal foreign bodies are particularly liable to occur in occupations involving grinding and turning metal, sandblasting, etc. **Treatment:** Superficial conjunctival or corneal foreign bodies are removed with a cotton wool bud after instillation of local anaesthetic. If embedded in the cornea (Fig. 178b), foreign bodies are removed using a fine needle point to lift the fragment (Fig. 178c). Any surrounding rust ring associated with ferrous foreign bodies should be re-



a



b



c

Fig. 178. a Subtarsal foreign body, visible when upper lid is everted; b corneal foreign body; c removal of foreign body from cornea with sharp needle under magnification

moved at the same time. Antibiotic eye drops are prescribed and the eye padded for a few hours. Mydriatics are unnecessary unless corneal infection has occurred, or a cellular infiltration of the anterior chamber is present.

Corneal abrasions develop as a result of subtarsal foreign bodies rubbing on the cornea, or from scratches by twigs, plants,

stones, etc. The patient immediately complains of severe pain, photophobia, lacrimation and foreign body sensation. After instillation of 2 per cent sodium fluorescein, the corneal epithelial defects show up stained green. Topical antibiotic eye drops are prescribed and the eye padded. The defect heals rapidly (within 24 hours or so) unless infection is present.

Contusions of the eyeball

Conjunctival haemorrhages (Fig. 179a) are frequently a result of the conjunctiva being struck by missiles, etc., but may also occur after acute rises of venous pressure in the head and neck, e.g. following crush injuries to the chest, attempted strangulation and strong positive gravitational forces.

Anterior chamber: Following tears of the ciliary body or iris root, bleeding occurs into

the anterior chamber (hyphaema, Figs. 179b, 180b). Patients seen with an hyphaema should always be admitted to hospital, as there is a possibility of a further severe haemorrhage occurring later. The anterior chamber may then become completely filled with blood and the apertures in the trabecular meshwork occluded. Glaucoma develops, which necessitates urgent removal of the clot. Other anterior chamber injuries include iris sphincter rupture (Figs. 176, below b, 180a), resulting in traumatic mydriasis, backward displacement of the ciliary body with rupture of the trabecular meshwork (angle recession), producing defective drainage of aqueous and raised intra-ocular pressure, and rupture of the root of the iris (iridodialysis), causing a full thickness defect in the iris diaphragm (Figs. 176, below a, 180b). A most serious consequence of blows to the eye is rupture of the eyeball at the limbus (Fig. 176, below d) or

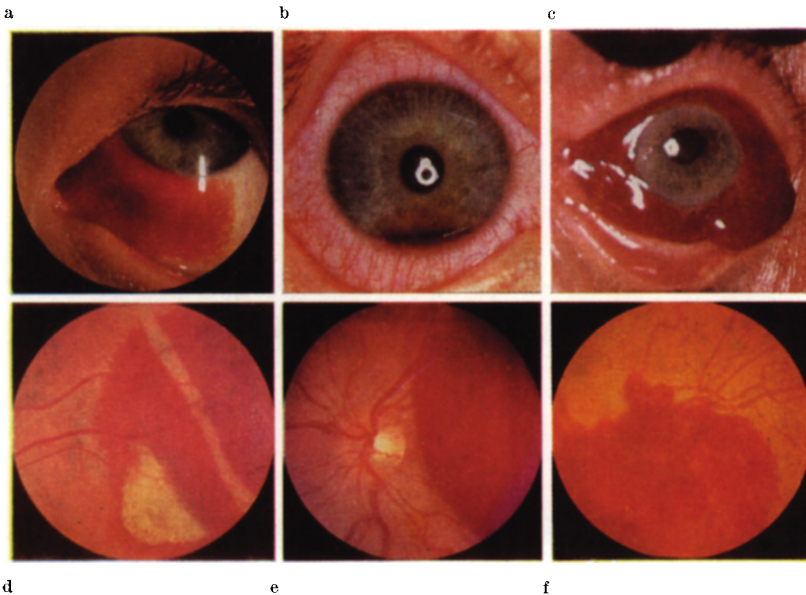


Fig. 179. Possible consequences of contusion of the eye: a subconjunctival haemorrhage following contusion injuries; b hyphaema (haemorrhage into anterior chamber); c concealed rupture of the sclera; d rupture of the choroid with choroidal haemorrhage; e deep retinal haemorrhage; f vitreous haemorrhage

of the sclera (Figs. 176, below e, 179c). In the latter case, tears may be difficult to identify as they are often hidden beneath the conjunctiva, but should be suspected when marked ocular hypotension is present. The area of scleral laceration must be identified and carefully sutured at operation.

Lens: Blunt mechanical trauma can cause a rupture of the suspensory ligament of the lens, allowing the lens to fall backwards into the vitreous (Fig. 176, below c) or, more occasionally, to prolapse forwards into the anterior chamber (Fig. 181a). After concussive injuries which have produced damage to the lens capsule, rosette-shaped lens opacities develop in the anterior cortex (Fig. 181b). A lens opacity has a tendency

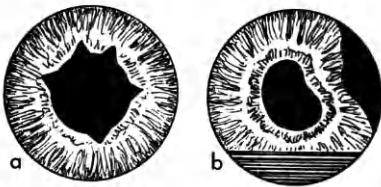


Fig. 180. a Tears in pupillary sphincter muscle; b iridodialysis and hyphaema

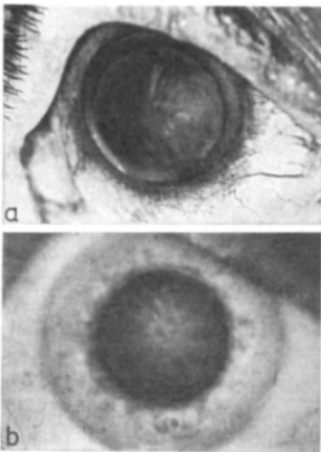


Fig. 181. a Luxation of lens into the anterior chamber; b contusion cataract

to develop into a total cataract, sometimes within a few weeks of injury, but occasionally only after a number of years.

Ocular fundus: Blunt mechanical non-perforating injuries to the globe often result in the development of retinal oedema (commotio retinae, Fig. 182a). The retina appears milky-white within a few hours of injury as a result of the development of intracellular oedema, but subsequently clears in 2–4 days. In severe contusion injuries, after the commotio retinae has cleared, pigmentary changes may develop at the retinal periphery and also at the macula. Visual acuity can be permanently impaired in patients developing a pigmentary maculopathy. More rarely, retinal tears follow such injuries (Fig. 176, below i). Indirect choroidal tears (Figs. 176, below k, 179d) are a complication of severe concussive injuries to the globe (the tears are usually crescent-shaped and concentric with the optic nerve head), and are the

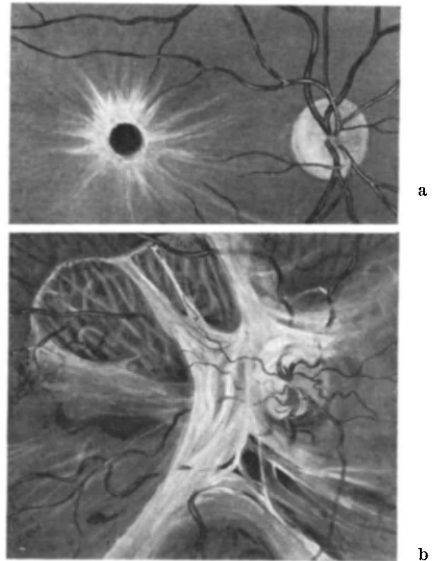


Fig. 182. a Commotio retinae (traumatic retinal oedema); b retinitis sclopetaria following severe contusion of the eyeball

result of breaks in the choroidal blood vessels. If the macula is involved, serious loss of central vision occurs. The overlying retina is not normally implicated in the tear, but haemorrhages into the choroid and beneath the retinal pigment epithelium are common (Fig. 179e). Severe contusions of the eyeball, e.g. following orbital gunshot wounds, without bulbar perforation lead to a condition known as retinitis sclopetaria (Fig. 182b), which is characterized by the development of considerable retinal pigmentary disturbance and exuberant localized scarring. The retina may be so severely damaged that visual function is permanently impaired.

Retinal haemorrhages are frequently noted 1 or 2 days after birth, as a result of compression of the cranium and globe in the infant's passage down the birth canal. Reabsorption occurs within a few days, leaving no traces.

Vitreous: Following dislocation of the lens, vitreous gel is sometimes seen in the anterior chamber. Severe contusion injuries resulting in deformation of the globe may lead to traction of the vitreous base on the retina, giving rise to vitreous haemorrhages (Fig. 179f), retinal dialysis and a subsequent retinal detachment.

Perforating injuries

Individuals at risk include those who work with tools such as hammers and chisels on metal, stone, etc. Similar injuries can occur following explosions. Foreign bodies may penetrate to any point within the eye (Figs. 183c, 184). Large perforating wounds of the cornea are characterized by the presence of a collapsed anterior chamber and often a gaping corneal wound (e.g. following windscreen injuries in road traffic accidents). Prolapse of the iris (Fig. 183a) and, more rarely, of lens material and vitreous, also occurs. The ocular tension is low, and vision is often severely impaired. Initial inspection of such injuries should be limited to making a diagnosis; excessive manipula-

tion will only cause further extrusion of intra-ocular contents. Small perforations of the cornea or sclera, however, are sometimes difficult to detect, as they close spontaneously after the passage of a small, high velocity missile and may, indeed, cause no initial visual disturbance.

Retained foreign bodies: All cases with a history suggestive of perforating ocular

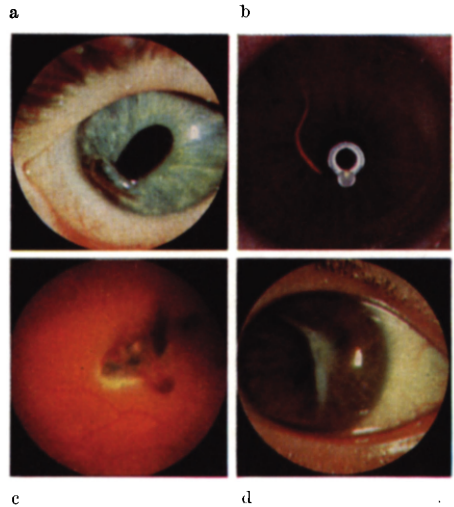


Fig. 183. a Iris prolapse following a perforating corneal injury; b copper wire in the anterior chamber; c foreign body lodged in the fundus; d corneal scar following a perforating injury

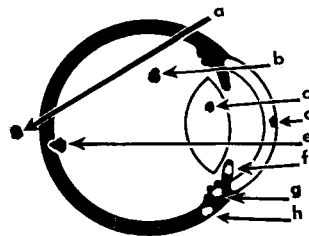


Fig. 184. Position of ocular foreign bodies: a double perforation, foreign body just behind the eyeball; b in vitreous; c lodged in lens; d in the cornea; e lodged in retina; f in iris; g in ciliary body; h in anterior sclera

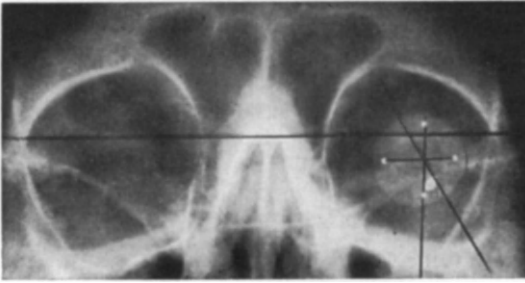
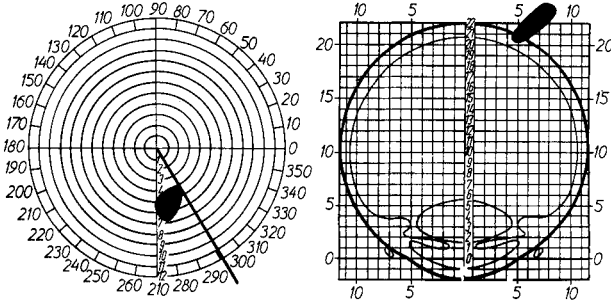


Fig. 185. Above: Anteroposterior X-ray of a perforating injury using a contact lens with 4 lead markers (Comberg's method). Below: Subsequent plotting. Left frontal, right meridional. The foreign body has penetrated the posterior wall of the eyeball



trauma must have X-ray investigations performed to eliminate the possibility of a radio-opaque intra-ocular foreign body. Localization of a foreign body within the globe is carried out by a contact lens with four lead markers. The relative distances of the markers from the foreign body are then plotted to give a fix of the foreign body within the globe (Fig. 185, above). **Treatment:** Intra-ocular foreign bodies such as glass, certain plastics and aluminium are well tolerated, as a rule, within the eye and may be left **in situ** if not causing any problems. Fragments containing iron, however, must be removed as soon as possible, since iron salts are toxic to the ocular tissues, causing degeneration of the retina with pigmentary changes leading to loss of vision, damage to the trabecular tissue resulting in glaucoma and disturbances of the iris producing a fixed dilated pupil and a heavily pigmented iris (siderosis bulbi, Fig. 188). Where a radio-opaque foreign body has been identified within the globe extraction can be achieved using an ophthalmic magnetic probe (Fig.

186), provided that the material is magnetic. If the foreign body lies posteriorly in the globe and the lens capsule is ruptured, the fragment may be drawn into the anterior chamber and removed through an incision in the cornea (anterior approach, Fig. 187). However, when the crystalline lens is clear (Fig. 183c), the foreign body should be removed through the sclera at or posterior to the pars plana (posterior extraction). Retained copper fragments (Fig. 183b) also require urgent removal, as this metal may produce a severe intra-ocular inflammatory change (chalcosis), as do retained fragments of fresh vegetable matter. It is necessary to extract such foreign bodies from inside the eye with forceps, a difficult and sometimes hazardous procedure if the material has come to rest in the vitreous.

All patients in whom a perforating injury of the eye is suspected must be referred to an ophthalmic unit for immediate further assessment, and if the diagnosis is verified, admitted to hospital, however small the



Fig. 186. Giant magnet (now largely superseded by hand-held instrument)

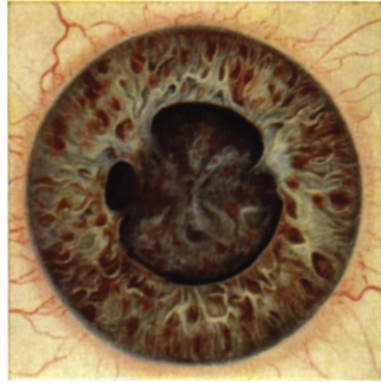

Fig. 188. Siderosis of the eye

antibiotics and mydriatics, as intra-ocular infection is a real danger.

All open perforating injuries must be repaired as quickly as possible by a surgeon experienced in dealing with such injuries, using general anaesthesia and an operating microscope. Exact apposition of corneal and scleral wound edges is essential to reduce scarring to a minimum (Fig. 183d). An iris prolapse should be replaced if the accident has not occurred too long previously, otherwise it should be abscised and a severely damaged lens removed if there is any chance of lens-induced uveitis or glaucoma developing. Vitreous gel must be removed from contact with any wounds of the ocular coats and retinal tears sealed by the application of cryoprobe to the adjacent sclera. Postoperatively, topical mydriatics and both topical and systemic antibiotics should be given.

Complications of perforating injuries

Include infection, secondary glaucoma, formation of cataracts, retinal detachments, phthisis bulbi (shrinking of the eyeball) and sympathetic ophthalmitis.

Sympathetic ophthalmitis: A serious, but now rare, consequence of perforating eye injury which is characterized by the development of uveitis in the non-injured eye, leading to unremitting and progressive ocular

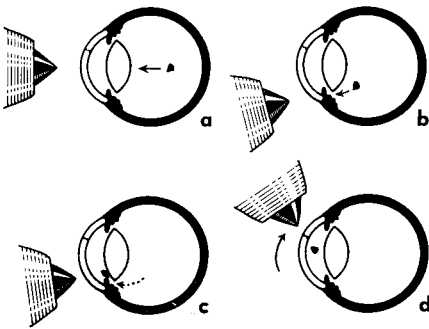


Fig. 187. Anterior extraction of an iron fragment from the vitreous, moving it around the lens and out through its entry wound

penetrating wound may be. Patients with small corneal wounds, caused by sharp instruments or foreign bodies not retained within the globe, that have subsequently sealed, should be treated with systemic

damage. It is rare for the inflammation in the untraumatized eye to commence less than 2 weeks after injury, but it has been reported to occur as long as 15 years later. Initial features include photophobia, reduced accommodation, ocular pain and mild reduction of vision. On examination, flare and cells are noted in the anterior chamber and cellular opacities in the vitreous. **Aetiology:** Unknown; possibly due to some infective agent, the nature of which has not been identified, or an autoimmune response to choroidal pigment. **Treatment:** Prophylaxis. Accurate repair of perforating ocular injuries should be performed as soon as possible after the accident, and if the traumatized eye remains painful and has become sightless 2 weeks after injury, enucleation should be considered. In cases of established sympathetic ophthalmitis, topical and subconjunctival steroids may be required in large doses to keep the inflammatory responses under control. NB, sympathetic ophthalmitis may not only follow accidental ocular injuries, but is a recognized but rare complication of intra-ocular surgery.

Cataract: Ruptures of the lens capsule frequently occur following perforating ocular injuries, leading to cataract formation and swelling of the lens, which may cause the anterior chamber to become shallow and iridocorneal contact to develop, resulting in secondary closed angle glaucoma. Following capsule rupture macrophages enter from the blood-stream and engorge the flocculent matter. The macrophages subsequently obstruct the trabecular meshwork, leading to lens-induced glaucoma (secondary open angle glaucoma). If neither of these complications occurs, lens material is usually slowly absorbed, so that eventually only the capsule remains.

Retinal detachments: Missiles piercing the sclera and retina can produce retinal tears and scar formation in the vitreous. Concussion injuries may cause traction on the retinal periphery via the vitreous base → retinal dialysis. Areas of retina likely to be the site of any subsequent retinal detach-

ments should be treated by cryotherapy as a prophylactic measure at the time of surgical repair and vitreous surgery performed within 2 weeks of injury if vitreous traction bands develop.

Chemical burns

Colliquative necrosis: Alkalis, by virtue of their fat solubility, readily penetrate body tissues and thus pass through the full thickness of the cornea to involve the internal structures of the eye. Alkaline burns, however trivial they may appear on initial examination, should be treated as an emergency. **Complications** include dense corneal scarring, vascularization, anterior uveitis, secondary glaucoma, adhesions between the tarsal and bulbar conjunctivae → symblepharon formation (Fig. 189c) and ankyloblepharon (Fig. 189d), subconjunctival scarring and a dry eye. Raised intra-ocular pressure, absence of tears and a vascularized cornea are all factors which reduce the chances of success of corneal grafting.

Coagulative necrosis: Acids produce coagulation of tissue protein which prevents deeper penetration, so the ocular complications are likely to be somewhat less serious than with alkali burns.

Prognosis for burns: An indication of the eventual prognosis can be obtained by the appearance of the eye on initial examination. Three degrees of severity are described:

1. A red eye, sometimes with corneal staining (Fig. 189a). Acid burns: a reasonably good prognosis; alkali burns: prognosis uncertain.
2. The cornea has a lack-lustre appearance, the conjunctiva is chemosed and the limbal vessels obliterated. Acid burns: prognosis uncertain; alkali burns: prognosis poor.
3. A white eye with coagulation necrosis of the conjunctiva and cornea (Fig. 189b). Prognosis invariably poor.

Treatment: Immediate, copious and prolonged irrigation of the chemically burned

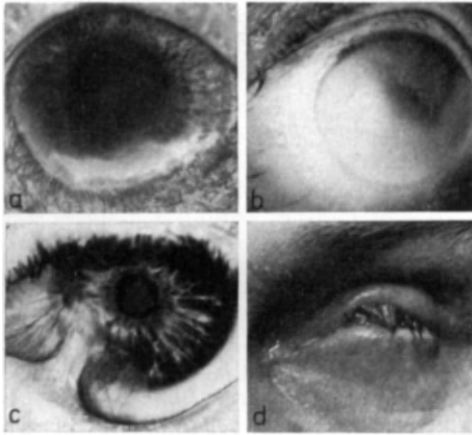


Fig. 189. a Moderate degree chemical burn; b severe chemical burn by lime; c symblepharon following chemical burn of the cornea; d ankyloblepharon following chemical burn by lime

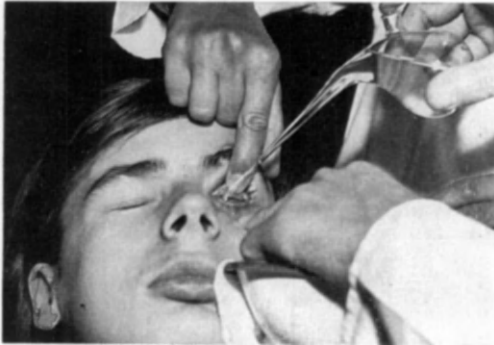

Fig. 190. Irrigation following chemical burn using an undine after upper lid eversion

areas with tap water (Fig. 190). Attempts to find a suitable antidote merely waste time. Any solid material, e.g. lime, particles of indelible pencil, etc. should be removed from the conjunctiva or cornea immediately. Eye pads must not be applied, so that tears can continue to wash away any residual chemical. The pupil is dilated to combat chemical iridocyclitis, and topical antibiotics instilled to prevent secondary infection. Steroid preparations may be used in an attempt to reduce the damage caused by the inflammatory response. If a symblepharon occurs (Fig. 189c), the adhering strands should be separated and the raw edges kept apart by means of a haptic contact lens. More severe adhesions reducing

the mobility of the lids to a minimum (ankyloblepharon, Fig. 189d) may require treatment at a later stage with mucous membrane grafts.

Radiation injuries

Ultraviolet keratitis following over-exposure to ultraviolet radiation (e.g. flash burns in arc welders, injudicious exposure to sun lamps or light reflected off snow at high altitudes, snow blindness). The patient complains of severe ocular pain and is unable to keep the eyes open. The symptoms develop 4-6 hours after exposure. Pain is relieved by the topical administra-

tion of local anaesthetics and examination of the cornea shows a marked superficial punctate keratitis. The symptoms clear within 24 hours. **Treatment:** The patient should be reassured that the condition will soon resolve spontaneously. Topical vasoconstrictors and anaesthetic agents may be used to tide the patient over the worst of the symptoms.

Solar radiation: The skin of the lids, as elsewhere on the body, may be burned following prolonged exposure to the sun.

Solar burns of the fundus occur particularly in individuals observing a solar eclipse without protective filters, but may occur in anti-aircraft gunlayers, astronomers, etc. The macular area is preferentially involved, and visual acuity may be severely and permanently impaired. **Treatment:** None effective.

Ionizing radiation: Beta or gamma radiation to the lids results in atrophy of the skin, depigmentation, telangiectasia, loss of hair including lashes and poor wound healing. The puncta become occluded, the lacrimal glands undergo involution, leading to dry eye, and keratinization of the conjunctiva occurs. Gamma rays cause radiation cataracts and endarteritis of the small retinal vessels, including those supplying the optic nerve head, leading to ischaemic optic atrophy. Such changes are only produced by radiation therapy to combat tumours or following atomic explosions. Heavy radiation of the orbit for therapeutic purposes can cause neoplasia to develop many years later.

Infrared radiation: The lens is vulnerable to infrared radiation, and individuals subjected to prolonged exposure, e.g. glass-blowers, chain-makers and blast furnace men, develop splits of the anterior lens capsule and posterior polar axial opacities (*see* page 56).

Cranial injuries

Fractures of the base of the skull not infrequently involve the optic canal, causing compression and laceration of the optic

nerve. Surgical decompression is rarely successful in restoring sight and the optic nerve head becomes pale within a few weeks. Fracture to the base of the middle cranial fossa is a major cause of carotico-cavernous sinus fistula (*see* Chapter 15). Brain stem lesions following open or closed cranial injuries give rise to gaze palsies, nystagmus, extra-ocular motor palsies, pupillary anomalies and accommodation paralysis. Supra-tentorial lesions may produce visual field defects and disturbances of eye movements. Raised intracranial pressure following closed cranial injuries can give rise to secondary brain stem lesions due to uncus herniation through the tentorial opening (tentorial coning). In cranial injuries caused by bullets and shell fragments, the findings depend on the direction of the trajectory and the damage caused by bone splinters and haemorrhage.

Aggravation and simulation

Patients sometimes exaggerate their physical injuries (aggravation) or even invent them (simulation) in connection with insurance claims following accidents, or as a manifestation of psychiatric illness. A patient complaining of complete loss of vision should be checked against an optokinetic drum. If sight is present, eye movements will be elicited when the drum is rotated. Individuals with constricted visual fields can be tested on a Bjerrum screen; where functional illness is present the visual fields when the patient is placed 1, 2 and 3 metres from the screen are frequently of the same size.

Self-inflicted damage to the eye by the insertion of objects or noxious substances is a manifestation of serious psychiatric disease. Patients suspected of introducing foreign material into the conjunctival sac should be admitted to hospital, the eye padded and the progress of the ocular condition carefully monitored. Occasionally mydriatics are intentionally or accidentally administered, giving rise to fixed dilated pupils. Pupil dilatation following neurological lesions of the parasympathetic pathways is always reversed by the instillation of pilocarpine drops.

17. Examination Procedures and Tests of Visual Function

Visual acuity

The ability of the eye to discriminate on a spatial basis is studied clinically by measuring the resolving power, the smallest angle subtended at the nodal point of the eye by two points or lines such that they are appreciated as separate, i.e. the so-called 'minimum separable'. In normal individuals with no refractive error this amounts to 1 minute of an arc, corresponding to the distance between two activated cones (Fig. 191a). There must be at least one unstimulated element between two stimulated cones for the points to be appreciated separately. The resolving power of the retina diminishes rapidly away from the fovea (Fig. 193).

Visual acuity is tested clinically by using visual symbols (optotypes) on the assumption that the average individual can resolve the details of letters if they subtend 1 minute of an arc at the eye, and the test letters are constructed so that the gaps, for example in the letter E, subtend this angle, while the whole letter subtends 5 minutes

of an arc (Fig. 191b). For routine testing purposes the patient is placed 6 metres from the test chart, in order to minimize the effect of accommodation.

A letter placed at 60 metres so that the bar width subtends 1 minute of an arc at the nodal point will be clearly recognized by a person with normal vision. However, a




Fig. 192. Visual testing charts with figures and pictorial symbols

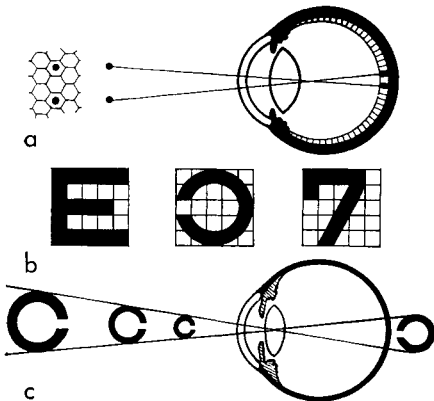


Fig. 191. a Resolving power of the eye (see text); b optotypes (Snellen E, Landolt's ring, figure); c relation between optotype size and distance

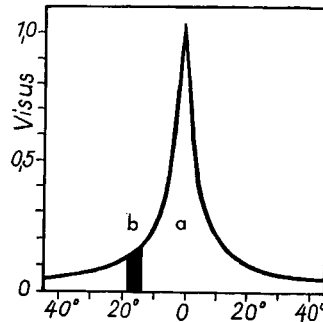


Fig. 193. Decrease of visual acuity away from fixation. a Fovea; b blind spot due to absence of receptor elements on the optic disc

patient with impaired vision may only be able to recognize the same optotype when it is placed 6 metres from him. Accordingly this patient is described as having 6/60 vision (Fig. 191c). The denominators, therefore, indicate the nominal distance at which the bar width of a particular letter subtends one degree of an arc at the nodal point. Patients' visual acuity is thus normally graded as follows: 6/60, 6/36, 6/24, 6/18, 6/12, 6/9, 6/6 and, if the visual acuity is better than normal, 6/5 or 6/4. Most Continental workers express the acuity using the decimal system. American ophthalmologists express test distances in terms of feet, thus 6/6 = 1, 0 = 20/20, and 6/60 = 0,1 = 20/200. If the visual acuity is less than 6/60 the viewing distance is reduced, i.e. the top letter of the chart may only be recognized at 3 metres or 1 metre (3/60, 1/60 respectively). Patients with more severely impaired visual function may only be able to count fingers at 2 metres or 1 metre, appreciate hand movements or distinguish between light and dark.

Near visual acuity, which is perhaps more important to most individuals than distance vision, is normally tested by means of reading texts, but can be assessed more accurately by the use of small optotypes. It is important to distinguish between poor vision due to refractive errors and those due to pathological processes. In recording the visual acuities a note must be made as to whether the test was performed with or without optical correction. Special charts are available for illiterates (Fig. 192).

Dark adaptation

Dark adaptation refers to the process whereby the retina adapts to decreasing levels of illumination, which entails a transition from a cone to a rod activity, and thus a change in light sensitivity. On starlit nights without a moon no colours are appreciable and small stars cannot be seen by looking directly at them. This is because the cones are inactive, leading to a reduction of dis-

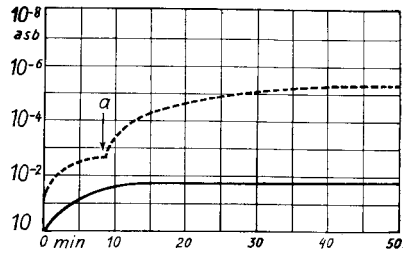


Fig. 194. Adaptation curve. Abscissa represents time from start of adaptation, ordinate represents illuminance of test spots in apostilbs. **a** Breakpoint (transition from cone to rod vision). ----- Normal; ——— defective adaptation in retinitis pigmentosa

crimination. **Adaptation testing:** The patient is first required to look at a diffusely lit screen (light adaptation) for 10 minutes, and is then placed in the dark on an instrument (adaptometer) where the minimum light perception thresholds are tested at regular intervals. See Fig. 194: Dark adaptation increases rapidly at first (immediate adaptation) and then more slowly for 30 to 60 minutes (longterm adaptation). Between the third and eighth minute of normal dark adaptation a kink occurs in the adaptation curve, and this point indicates the transition from cone to rod vision. Disturbances of the dark adaptation curve are present in tapetoretinal degenerations, i.e. retinitis pigmentosa, and in vitamin A deficiency syndromes.

Visual fields

The limits extend to about 60° nasally and above, 70° below and 90° temporally.

Visual field measurement

Topographic kinetic perimetry: An examination technique whereby points of equal retinal sensitivity are determined using test objects of varying sizes, brightness and colours. Lines connecting points of equal sensitivity in the visual field are known as isoptres (in the same way as points of equal altitude are linked on contour maps) (Fig. 196, above). Retinal sensitivity is greatest at the macula (the centre

of the visual field). Small, dimly illuminated objects give a small visual field; large, brightly illuminated objects give a large visual field. Because there are no cones in the periphery of the retina, coloured objects are only appreciated as being coloured in the more central portions of the retina, green giving the smallest field and blue the largest (Fig. 195).

Quantitative static perimetry: The measurement of brightness thresholds in one or more retinal meridians is plotted by presenting static test objects, the illumination of which is gradually increased until appreciated by the patient. This is repeated across the whole of one meridian and thus yields a sectional visual field profile (Fig. 196, below).

Perimeter: The simplest instrument is an arc perimeter, consisting of a semicircular frame and test objects of various colour which are moved along a track (Fig. 197a). Bowl perimeters are preferable, since the test object is projected on to the bowl and

the patient has no other clue as to its whereabouts. The size and illumination of the test object can be varied at will (Fig. 197b).

Confrontation test (Fig. 199b): This simple test is used to obtain a rapid assessment of the visual fields. The examiner and patient sit facing each other, each covering one

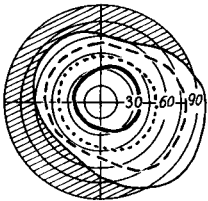


Fig. 195. Outer limits of colour perception (colour isoptres); from outside to centre ——— white; - - - - - blue; red; ——— green

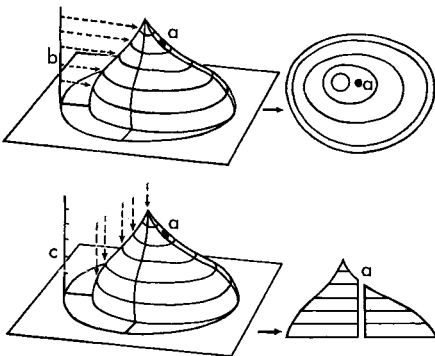
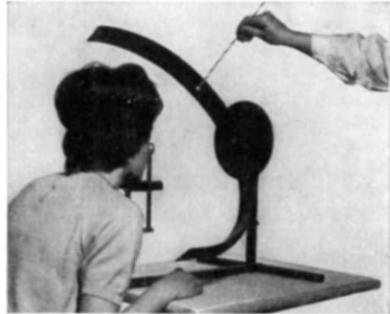
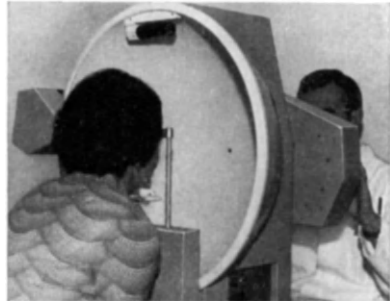


Fig. 196. Above: Topographic perimetry (see text). Below: Quantitative static perimetry



a



b



c

Fig. 197. a Visual field testing using an arc perimeter; b testing with a bowl perimeter (fixation point in centre); c Bjerrum target screen (chin and forehead rests immobilize the patient's head)

eye with a hand on the same side (i.e. doctor, left eye, patient, right eye). The examiner then moves a test object from the periphery towards the centre and the patient indicates when he first appreciates the object appearing in his field of vision. This test, if properly carried out, can be extremely

accurate, and is the best way of testing visual fields in a patient with a limited attention span, or one who has a central field defect that prevents accurate central fixation. In patients with dense opacities of the ocular media, some idea of the accuracy of light projection can be obtained using a point light source (Fig. 199 a).

Central visual field testing is normally performed on a Bjerrum target screen at a distance of 1 or 2 metres (Fig. 197c), and is valuable for assessing the central portions of the visual field and measuring changes in the size of the blind spot (Fig. 198a).

Amsler grid: Subjective test used to detect rapidly the presence of small central or paracentral scotoma, which may be complete or give rise to distortion in the shape of the grid. The test is extremely useful, since it enables the patient to plot his own field defects (Fig. 198b).

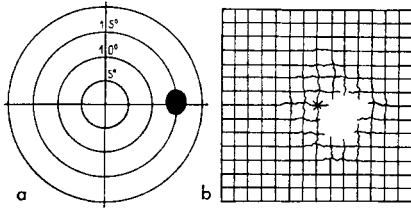


Fig. 198. a Blind spot of right eye recorded with Bjerrum screen; b field defect recorded on Amsler grid test in a case with macular degeneration

Visual field defects

Scotomas (island-shaped visual field defects) are subdivided as follows:

Objective (negative) scotomas are due to damage to the percipient elements or the afferent visual pathways and are therefore not consciously perceived by the patient. The blind spot belongs to this category.

Subjective (positive) scotomas are caused by vitreous opacities, blood on the surface of the retina, cataracts, etc., and these are seen by the patient as dark shadows or blobs.

Objective scotomas are subdivided into absolute scotomas (light perception in the area of the scotoma is absent) and relative scotomas (there is diminished perception in the area of the scotoma).

Retinal lesions involving the macula or its projection pathways which cause a reduction in visual acuity are always associated with scotomatous defects.

Colour vision

This is defined as the ability of an individual to perceive hue, colour brightness and color saturation corresponding to the visual wavelengths (800 to 400 nm). About 160 shades of colour can normally be appreciated.

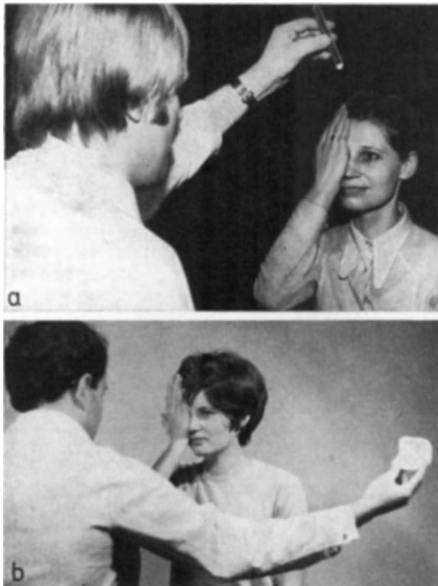


Fig. 199. a Light perception test using torch (in the dark); b assessment of visual field by confrontation test, with the patient fixing the doctor's uncovered eye

White is appreciated when all the spectrum colours are combined together, and grey when the brightness of this mixed spectrum is decreased. Black is in immediate contrast to brightest white. The appreciation of colour vision in man is dependent upon impulses being transmitted to the visual cortex from three groups of receptors in the retina, one group being stimulated by the red band of the visual spectrum, another by a green band and a third by the violet band. Depending on the mixture of light falling on the retina, so various hues or shades are appreciated.

Acquired disorders of colour vision

Acquired disorders of colour vision are often unilateral and linked with reduced visual acuity. Blue/yellow colour perception is often first impaired in diseases of the retina. Disorders of the optic nerve tend to produce disturbances of red/green vision. The cause of these findings is at present unknown. Bilateral acquired colour visual defects may occur in lesions involving the visual cortical association areas.

Congenital disorders of colour vision

Most congenital colour vision disorders are bilateral and non-progressive, and do not give rise to disturbances of visual acuity (except in cases of total colour blindness). Congenital colour defects are classified as follows:

Dichromatism indicates a colour perception which consists of only two components.

Protanopia denotes absence of red perception, **deutanopia** absence of green perception and **tritanopia** absence of blue/yellow perception. To protanopes and deuteranopes the spectrum appears to consist of shades of blue and yellow (Fig. 200, above).

Trichromatism is the term used for normal colour vision.

Anomalous trichromatism is a condition in which the sensitivity for a particular colour is reduced rather than completely lost. A distinction is made between protanomaly (reduced red sensitivity), deuteranomaly

(reduced green sensitivity) and tritanomaly (reduced blue sensitivity).

The inheritance of the above congenital disorders of colour vision is normally sex-linked in males but is recessive in females. Thus some 6 per cent of males are involved, but only about 0.6 per cent of females.

Achromatopsia or monochromatopsia (total colour blindness): A disorder which results from total lack of cones whereby central fixation is rendered impossible. Visual acuity is severely impaired and a dense central scotoma present. Daylight vision is extremely poor, but individuals with achromatopsia manage reasonably well in dim illumination.


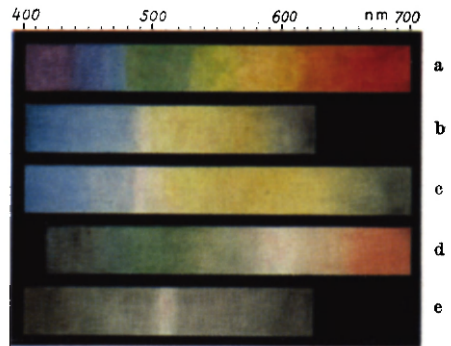


Fig. 200. Above: The colour spectrum as seen by: a trichromats (normal); b protanopes (red blindness); c deuteranopes (green blindness); d tritanopes (blue yellow blindness); e monochromats (total colour blindness). Below: Pseudo-isochromatic plate for colour vision testing

People with colour vision disorders should not be employed as train drivers, signalmen, deck officers on sea-going ships or electricians.

Methods of diagnosing disorders of colour vision

Pseudo-isochromatic plates (Fig. 200, below) are composed of coloured dots of equal brightness but of varying saturation in the colours which cause confusion to persons with colour vision defects. Tests are carried out in daylight illumination at the normal reading distance.

Farnsworth-Munsell test: Test blocks consist of a number of tones of various colours and the patient is asked to set them out in their correct gradation. Errors are entered on a special chart by the examiner.

Anomaloscope: The individual is required to mix a brilliant red (lithium red) and green (thallium green) together. A red-blind person will add too much red, and a green-blind person too much green.

Simple selection tests can also be conducted using different colours of wool, pencils, lights, discs, etc.

18. Refraction and Accommodation

General considerations

Refractive power of optical lenses is measured in dioptres (D) and is the reciprocal of the focal length (f) in metres of a lens:

$$D = \frac{1}{f}$$

A convex lens with a refractive

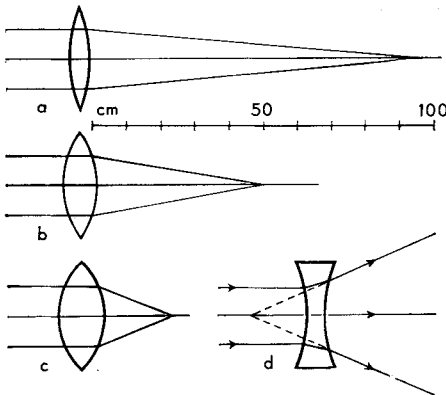


Fig. 201. Refracting power of converging (convex) lenses: a 1 dioptre → focal point is 1 metre behind lens; b 2 dioptres → focal point is 0.5 metre behind lens; c 5 dioptres → focal point is 20 cm behind lens; d refraction of a concave lens

power of +1 dioptre will cause parallel incident rays to come to a focus 1 metre behind the lens (= focal length). A lens with a refractive power of 2 dioptres has a focal length of $\frac{1}{2}$ metre. Convex lenses cause parallel incident light rays to converge to a single focal point beyond the lens (plus lenses) (Fig. 201a-c). Concave lenses cause incident rays to diverge; the focus is therefore in front of the lens (minus lenses) (Fig. 201d). Light consists of electromagnetic vibrations, and the visible spectrum is limited to a wavelength range of approximately 400 to 800 nm in man. White light is split into its constituent spectral colours by prisms.

The refractive power at the edge of both the crystalline lens and the cornea is not the same as at the centre (Fig. 202a-d), and therefore gives rise to spherical and chromatic aberrations. Blue light is refracted more than red, which has the longer wavelength. For this reason the resolving power of the eye can be some 5-20 per cent higher in monochromatic light (e.g. sodium or mercury vapour light). These aberrations are, however, mainly eliminated by the presence of the iris diaphragm, and only rays passing through the central part of the cornea and lens normally reach the retina.

People with colour vision disorders should not be employed as train drivers, signalmen, deck officers on sea-going ships or electricians.

Methods of diagnosing disorders of colour vision

Pseudo-isochromatic plates (Fig. 200, below) are composed of coloured dots of equal brightness but of varying saturation in the colours which cause confusion to persons with colour vision defects. Tests are carried out in daylight illumination at the normal reading distance.

Farnsworth-Munsell test: Test blocks consist of a number of tones of various colours and the patient is asked to set them out in their correct gradation. Errors are entered on a special chart by the examiner.

Anomaloscope: The individual is required to mix a brilliant red (lithium red) and green (thallium green) together. A red-blind person will add too much red, and a green-blind person too much green.

Simple selection tests can also be conducted using different colours of wool, pencils, lights, discs, etc.

18. Refraction and Accommodation

General considerations

Refractive power of optical lenses is measured in dioptres (D) and is the reciprocal of the focal length (f) in metres of a lens:

$$D = \frac{1}{f}$$

A convex lens with a refractive

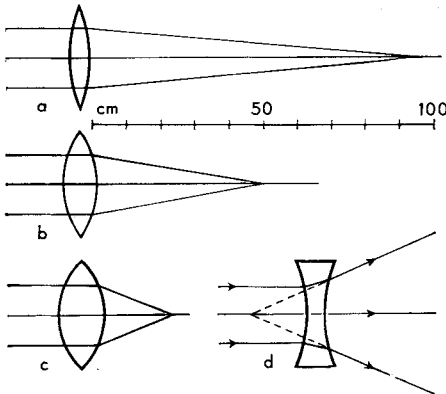


Fig. 201. Refracting power of converging (convex) lenses: a 1 dioptre → focal point is 1 metre behind lens; b 2 dioptres → focal point is 0.5 metre behind lens; c 5 dioptres → focal point is 20 cm behind lens; d refraction of a concave lens

power of +1 dioptre will cause parallel incident rays to come to a focus 1 metre behind the lens (= focal length). A lens with a refractive power of 2 dioptres has a focal length of $\frac{1}{2}$ metre. Convex lenses cause parallel incident light rays to converge to a single focal point beyond the lens (plus lenses) (Fig. 201a-c). Concave lenses cause incident rays to diverge; the focus is therefore in front of the lens (minus lenses) (Fig. 201d). Light consists of electromagnetic vibrations, and the visible spectrum is limited to a wavelength range of approximately 400 to 800 nm in man. White light is split into its constituent spectral colours by prisms.

The refractive power at the edge of both the crystalline lens and the cornea is not the same as at the centre (Fig. 202a-d), and therefore gives rise to spherical and chromatic aberrations. Blue light is refracted more than red, which has the longer wavelength. For this reason the resolving power of the eye can be some 5-20 per cent higher in monochromatic light (e.g. sodium or mercury vapour light). These aberrations are, however, mainly eliminated by the presence of the iris diaphragm, and only rays passing through the central part of the cornea and lens normally reach the retina.

As in a camera, the smaller the pupil, the greater the depth of focus (pin-hole effect). In an emmetropic eye parallel rays of incident light come to a focus on the retina and thereby form a clear image. Conversely, the far point of an emmetropic eye is situated at infinity (Fig. 203a). Rays of light from objects close to the eye will come to a focus behind the retina (Fig. 203b) unless the

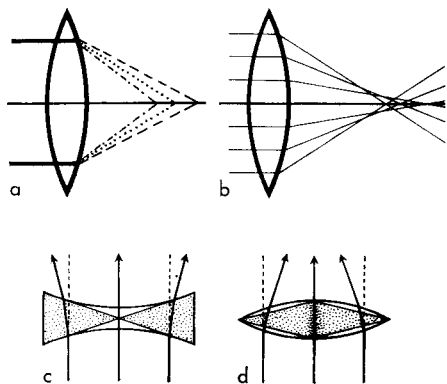


Fig. 202. a Chromatic aberration (----- red, yellow, - - - - - blue); b spherical aberration; c-d prismatic deflection when not looking centrally through concave (c) and convex (d) lenses. A prism bends the incident light rays towards its base

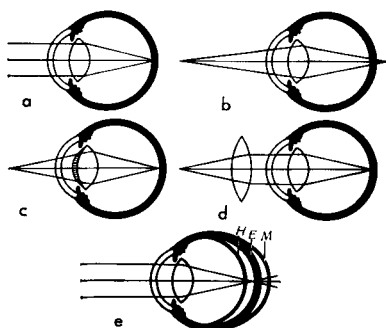


Fig. 203. Refraction in the emmetropic eye (a-d see text); e axial ametropia: H axial hypermetropia (eye too short); E axial emmetropia; M axial myopia (eye too long)

power of the crystalline lens is increased by accommodation, or a converging lens is placed between the object and the eye (Fig. 203c-d). The term emmetropia does not necessarily imply good vision in the patient, merely that the dioptric apparatus of the eye is such that, in the absence of ocular pathology, a clear image is formed on the retina.

Hypermetropia (long-sightedness)

In hypermetropia (hyperopia) parallel rays of incident light come to a focus behind the retina, producing a blurred retinal image (Fig. 204a). This may be because the eye is too short in proportion to its refractive power (Fig. 203e, axial hypermetropia), the extreme example being microphthalmos (Fig. 204i). A similar situation arises if the axial length of the eye is normal but the

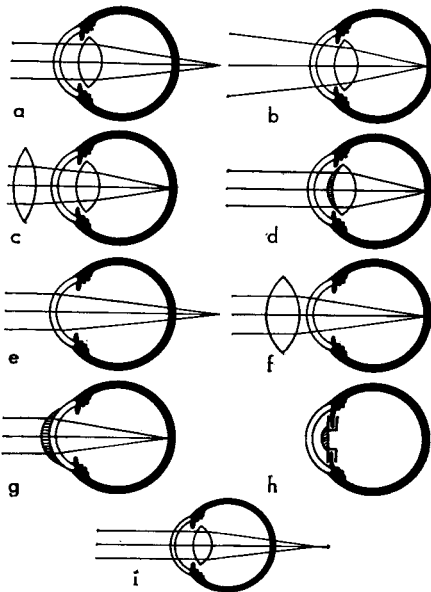


Fig. 204. Refraction in the hypermetropic eye (see text)

refractive power of the cornea or lens is too low (refractive hyperopia). Only in situations where converging incident rays strike the cornea will a clear image be formed on the retina of hyperopes (Fig. 204b). Thus, correction of the refractive error is achieved by using convex (plus) lenses (Fig. 204c). Slight degrees of hyperopia are corrected spontaneously by the individual using some of his accommodative power for distance (Fig. 204d).

In aphakia (after removal of the crystalline lens) the refractive power of the eye is markedly reduced and the patient needs to be prescribed cataract glasses of approximately 11 dioptres to see well for distance, a contact lens or an intra-ocular lens (Fig. 204f-h).

Patients with mild hyperopia require a continuous accommodative effort to see clearly, so that when spectacle correction is initially prescribed the ciliary muscle does not immediately relax completely and a portion of the hyperopia remains latent. Additional plus correction may therefore be required later to correct the error fully. The portion of the hyperopia that can be corrected immediately by a spectacle correction is known as the 'manifest hyperopia'. The total hyperopia is determined by refracting the patient after paralyzing accommodation with atropine: Total hyperopia minus manifest hyperopia = latent hyperopia.

The anterior chamber becomes shallower in old age, and therefore there is a tendency for hyperopic individuals to develop acute angle closure attacks in later life. On ophthalmoscopic examination the optic disc margins are often slightly blurred and the discs mildly elevated in these patients.

Myopia (short-sightedness)

In myopia parallel rays of incident light come to a focus in front of the retina (Fig. 205a). Only rays from near objects which diverge come to a focus on the retina. The far point of a myopic eye is situated not at

infinity, as in the case of emmetropia, but nearer the eye (Fig. 205b). Myopia occurs if the eye is too long axially in relationship to its refractive power (Fig. 203e) – a 1.0 mm increase in length of the eye's axis corresponds to approximately 3 dioptres of myopia – or if the refractive power of the cornea or crystalline lens is too great for the axial length of the eye (refractive myopia). Myopes can therefore see near objects well but poorly for distance. Myopia is corrected (Fig. 205c-d) by prescribing concave (minus) spectacle or contact lenses. Myopes should be prescribed the weakest minus lens which will give the optimum visual acuity, as over-correction results in unnecessary accommodative effort. Following cataract extraction a myope may require little or no plus correction to see clearly for distance (Fig. 205e). The refractive power of the lens nucleus often increases in patients developing nuclear cataracts, causing refractive myopia, and occasionally unioocular diplopia (double vision) because rays of light passing through the periphery of the lens come to a different focal point than those passing through the centre (Fig. 205f).

Types of myopia: In the majority of myopes the refractive error is not more than

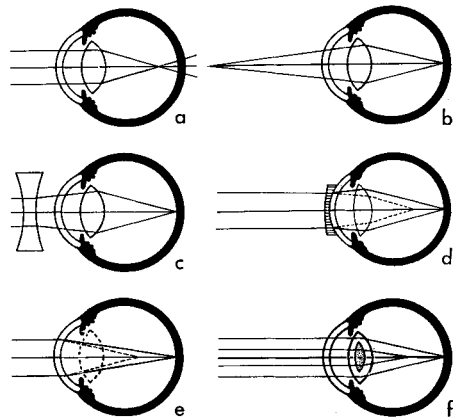


Fig. 205. Refraction in the myopic eye (see text)

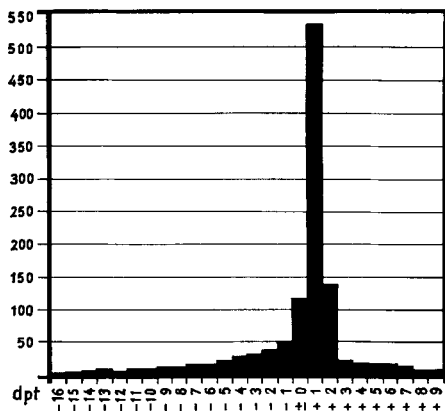


Fig. 206. Frequency of occurrence of hypermetropia and myopia. Ordinate: number of subjects examined

4 dioptres; it tends to increase slightly up to about the age of 18 years and then stabilize. In a small proportion of patients, myopia is progressive (malignant myopia) and continues to increase at a rate of up to 1 dioptre a year; refractive errors of in excess of 20 dioptres are not uncommon in this condition, and severe degenerative changes develop in the sclera, choroid and retina (see Chapter 12). A frequency distribution curve of refractive errors is not gaussian in shape because of the contribution made by persons with pathological myopia (Fig. 206).

Presbyopia

The plasticity of the lens gradually becomes reduced throughout life (Fig. 214c), so that changes of its shape in response to accommodation become reduced. Patients over the age of 40 with hypermetropia or emmetropia require plus lenses to enable them to see close objects and to read clearly. The power of the ciliary muscles to contract, however, remains unimpaired. Myopic individuals, on the other hand, find that they can dispense with glasses for reading.

Anisometropia

Anisometropia is a term used to describe the condition when the two eyes have unequal refractive powers. When the difference in refraction is in excess of 4 dioptres, only the better eye should be given full spectacle correction, since the difference in magnification of the two images formed on the retinae is such that the cerebral cortex is unable to fuse the two together as a unitarian whole (aniseikonia). Aniseikonia caused by anisometropia of up to 10 dioptres can, however, be corrected by means of contact lenses.

Astigmatism

The curvature of the cornea is unequal in different meridians, so incident rays of light cannot be brought to a point focus. Corneal

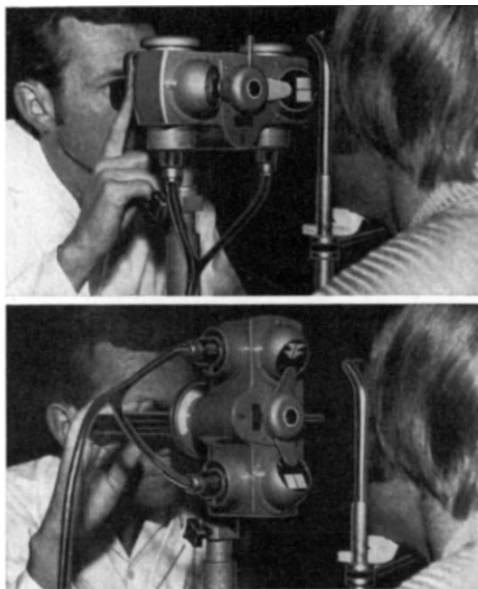


Fig. 207. Measuring corneal curvature using a Javal's keratometer; above along the horizontal meridian; below along the vertical meridian

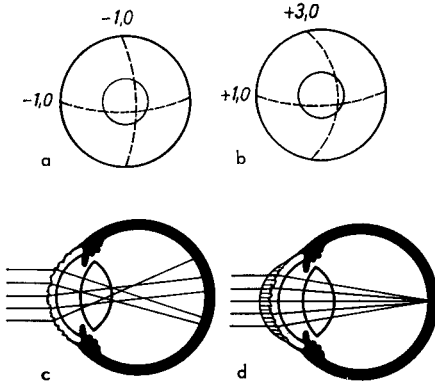


Fig. 208. Astigmatism: a curvature equal (refraction identical along all meridians = -1.0 dioptre), no astigmatism; b regular astigmatism (refraction along horizontal meridian = $+1.0$ dioptre is different from that along vertical meridian = $+3.0$ dioptres); c-d irregular astigmatism with and without correction by contact lens

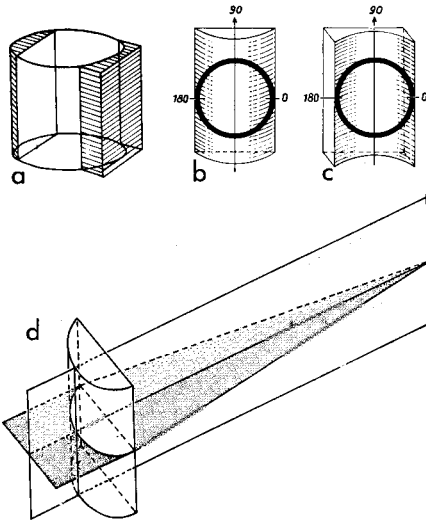


Fig. 209. Shape and action of cylindrical lenses. a Diagram of convex and concave cylindrical lenses in relation to cylinder; b-c convex and concave cylindrical lenses with their axes shown; d rays which are centrally incident on a vertical cylindrical lens are not refracted at all along the vertical meridian, while along the horizontal meridian they are refracted as by a convex lens

curvature along various meridians can be measured using a keratometer (Fig. 207).

Types of astigmatism: In most individuals the refractive power along the vertical corneal meridian is $\frac{1}{2}$ - $\frac{3}{4}$ dioptre greater than in the horizontal meridian; correction is unnecessary. **Regular astigmatism:** There is an unequal refraction in two meridians at right angles to each other (Fig. 208 b), usually in the vertical/horizontal axes. Correction is achieved by using spectacles containing cylindrical lenses which neutralize the ocular astigmatism (Fig. 209). **Irregular astigmatism:** The surface of the cornea becomes irregular due to corneal scarring, keratoconus, etc. (Fig. 208 c). Vision cannot be adequately improved by spectacle correction, but contact lenses, where the irregularities of the cornea are filled with tears, overcome this problem (Fig. 208 d).

Corrective lenses

Originally the only lenses available to correct refractive errors were biconvex/biconcave and planoconvex/planoconcave (Fig. 210 a-d). Such lenses produce marked chromatic and spherical aberrations. Modern lenses are curved (meniscus type) and their form is such that the lens aberrations are markedly reduced (Fig. 210 e-f).

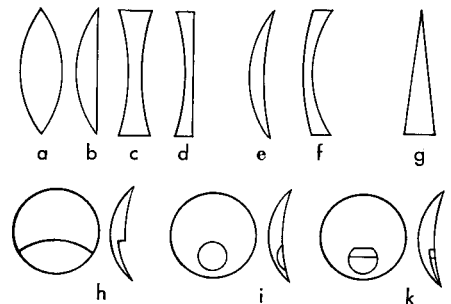


Fig. 210. Different types of spherical corrective lenses: a biconvex; b planoconvex; c biconcave; d planoconcave; e concave-convex meniscus; f convex-concave meniscus; g prismatic lens; h-i bifocal lenses; k trifocal lenses

In older patients requiring both distance and near corrections, bifocal lenses (Fig. 210h-i) may be ordered so that the necessary corrections are combined in one spectacle lens. More recent forms of lenses have built-in corrections for distance, intermediate and near vision combined (trifocals, Fig. 210k), or are designed to produce a gradual transition from far to near correction.

Prisms (Fig. 210g) are prescribed for individuals who have squints and in whom extra-ocular muscle surgery is contraindicated. A prism refracts the incident light rays towards the base, and its strength is measured in prism dioptres, or by the amount the incident light is deviated in degrees. A prism of strength 1 dioptre will cause a deflection of the light rays of 1 cm at a distance of 1 metre from the original light path (approximately 0.5°). If spectacle lenses are not correctly centred in relation to the visual axes, prismatic deflections occur. Fig. 202c-d shows deviations produced with convex and concave lenses.

Contact-lenses (Fig. 212b) fit directly on to the cornea. The advantages are:

1. They are the only means of optically correcting irregular corneal astigmatism.
2. They provide a wider field and lower magnification change than spectacle correction.
3. Spherical or chromatic aberrations are largely eliminated.

The disadvantages are:

1. Relative difficulty in handling and insertion.
2. Individual variance in tolerance.
3. Cost.
4. In rare cases they may cause damage to the cornea either as a result of their direct mechanical effect, or by preventing sufficient oxygen getting to the cornea for its metabolism.

Special types of glasses: Patients visually impaired with macular lesions or optic nerve pathology may be aided by using magni-

fying or telescopic spectacles. The increased magnification, however, results in a marked reduction in the visual fields (Fig. 243b).

Refraction

Objective refraction (retinoscopy) is performed by means of an instrument somewhat similar to an ophthalmoscope (retinoscope). The fundus is illuminated and the movement of fundus reflexes noted when the retinoscope is tilted. The examiner sits $\frac{3}{4}$ -1 metre away from the patient, with the sight hole of the instrument as close to his own pupil as possible. The patient is required to look at a distant object (Snellen test chart) to relax accommodation. Depending upon the refraction of the patient, the retinal reflex moves either in the same direction as the retinoscope, or in the opposite direction (**with** for hypermetropia, **against** for myopia). Lenses are placed in a trial frame worn by the patient until the point of reversal is reached. After subtracting plus 1 dioptre from the power of the lenses in the trial frame to compensate for the examiner's working distance (if seated at 1 metre), a fairly accurate assessment of the spectacle correction is obtained. Retinoscopy after paralysis of accommodation with atropine is the only method of obtaining a refraction in young children clinically.

Subjective refraction: To establish the type and strength of corrective lenses required, trial lenses are selected from a set and inserted into a trial frame (Fig. 211a-b). Plus, minus or cylindrical lenses are used until distance vision has achieved optimum levels. In the older person, additional plus lenses may be required to produce good near vision.

To establish whether a lens is of a plus or minus power, the lens is moved to and fro in front of a cross at a distance of a few centimetres. With a minus lens the cross appears to the examiner to move in the same direction as the lens, and with a plus lens, in the opposite direction. Cylindrical lenses

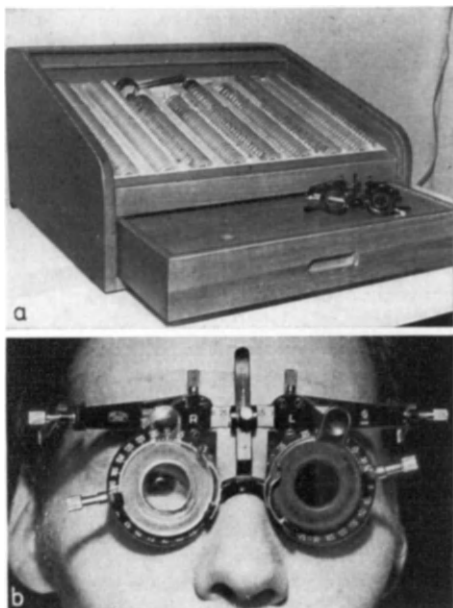

Fig. 211. a Set of trial lenses; b trial frame

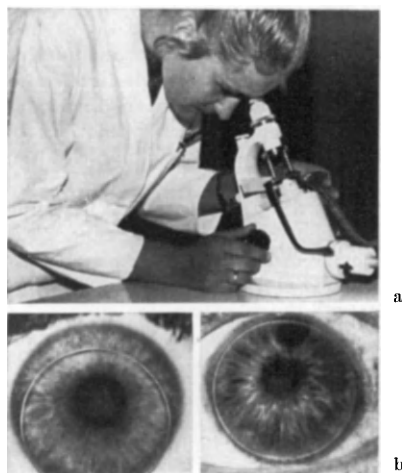


Fig. 212. a Measurement of the refractive power of spectacle lenses with a focimeter; b left: contact lens correction of a refractive anomaly; right: in an aphakic with a peripheral iridectomy at 12 o'clock

can be recognized by the apparent distortion of images when revolved around their axes. Precise measurements of the strength of spectacle lenses is made with an instrument known as a focimeter (Fig. 212a).

Accommodation

Accommodation is the ability of the eye to augment its refractive power by increasing the curvature, and hence the strength, of the crystalline lens. In this way a sharp image falls on the retina over a range of distances, i.e. between the far and near points of the eye (Fig. 213). The term 'accommodation range' denotes the amount by which the refractive power of the eye can be increased. Thus, if the near point of the eye is situated at a distance of 20 cm ($\frac{1}{5}$ metre) and the far point is infinity, the accommodation range is 5 diopters.

Mechanism of accommodation: Accommodation is brought about by contraction of the ring-shaped ciliary muscle, thereby causing a relaxation of the suspensory ligaments of the lens (Fig. 214a-b). A control loop, similar to that for the pupillary reflex, exists for accommodation (Fig. 215).

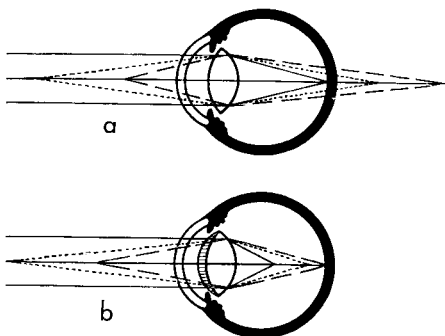


Fig. 213. Accommodation: a without accommodation the image of near objects is formed behind the retina; b with accommodation the image of distant objects is formed in front of the retina

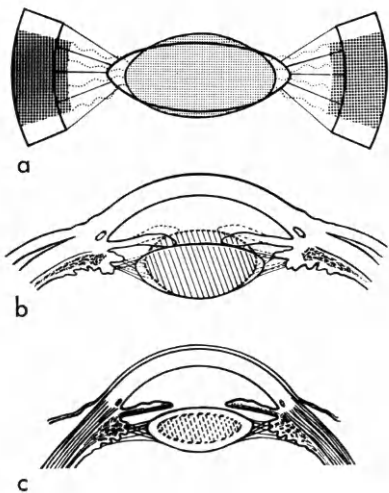


Fig. 214. **a** Schematic diagram of accommodation (dotted lines and/or dot-shaded areas represent the accommodated state); **b** changes during accommodation (dotted lines and shaded area represent the accommodated state); **c** accommodation impeded in old age by loss of lens plasticity (presbyopia)

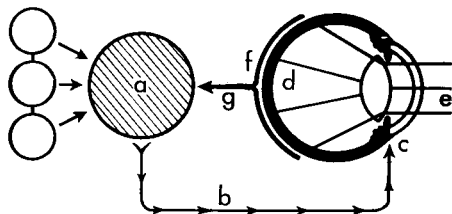


Fig. 215. Accommodation control loop: **a** control centre - accommodation centres and associated centres (pupillomotor and convergence centres); **b** command signal (transmitted by sympathetic and parasympathetic nerves); **c** controlled element (ciliary muscle); **d** control signal (sharpness of image on the retina depending on distance of object of regard); **e** error signal (distance of object of regard); **f** sensor (retinal receptors); **g** measured value (transmitted via the optic pathway)

Age and accommodation

With increasing age the near point of the eye moves further and further away (presbyopia), so that reading can only be per-

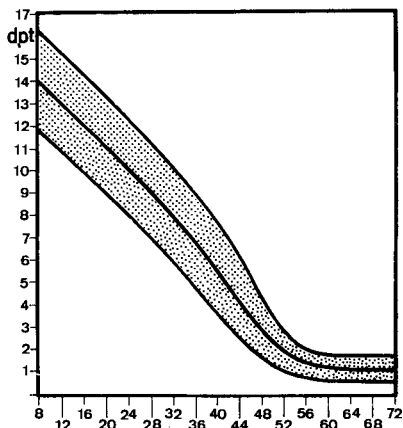


Fig. 216. Decrease in accommodation range. Ab-scissa: age in years; Ordinate: accommodation range in dioptres. Graph shows average values and normal range in a European group

formed with difficulty unless reading glasses are provided. The accommodation range at 45 years is about 3 dioptres (distance of near point 33 cm, Fig. 216) and reading glasses may then be needed (approximately 1 dioptre). At the age of 50 years 2 dioptre spectacle corrections are frequently required, and at the age of 60 some 3 dioptres. A mildly hyperopic person has to accommodate when looking into the distance in order to compensate for the basic refractive error, and will therefore need glasses earlier than an emmetropic individual. On the other hand, a myope of 3 dioptres does not need reading glasses since his far point is already situated at 33 cm. Accommodation is linked to the convergence reflex and miosis of the pupil so abnormalities of one system are frequently linked with disorders of the others.

Accommodation pareses

Paralysis of the ciliary muscle (supplied by the parasympathic nerves) may be bilateral or unilateral, with or without pupillary involvement. Functionally, its effect is similar to that of presbyopia. If the pupil is also

involved the resulting condition is known as an **ophthalmoplegia interna**.

Aetiology: Drugs; the effects of atropine last about 10 days, scopolamine 4–6 days and homotropine 1–2 days. Other causes include trauma, iridocyclitis, myotonic pupil, botulism. Centrally located disturbances of accommodation occur with meningitis, tumours involving the mid-brain, head trauma, syphilis and diphtheria. **Treatment:** Should be directed towards the underlying cause.

Asthenopia

A term used to describe symptoms caused by ocular fatigue or strain. These include

blurred vision, headache, pain in or around the eyes, photophobia and tearing. Symptoms tend to occur towards the end of a working day. **Aetiology:** The condition occurs following prolonged close work, the use of insufficiently strong reading glasses, inadequate accommodation or the performance of delicate tasks in poor levels of illumination. The same features also occur in patients with a reduced ability to turn the eyes inwards for close work (convergence insufficiency) and large latent squints which have a tendency to break down (see Chapter 19). Asthenopia occurs more often in patients suffering from mild exhaustion or recovering from serious systemic diseases. **Treatment:** Should be directed towards the underlying cause.

19. Binocular Vision and Strabismus

General considerations

Extra-ocular muscles

The globe is moved by six extra-ocular muscles, consisting of four recti muscles (superior, inferior, lateral and medial) and two oblique muscles (superior and inferior) (Fig. 217). In most people the movements of the eyes are co-ordinated so that the images of the object of regard fall on corresponding retinal points (foveae). The four recti muscles, together with the levator palpebrae superioris and the superior oblique, arise from a fibrous ring surrounding the optic foramen and insert into the globe anterior to the equator. The superior oblique muscle passes forwards between the roof and the medial wall of the orbit to the trochlea, which is situated on the nasal side of the orbital roof a few millimetres posterior to the orbital margin, loops round this structure and passes backwards to insert into the globe posterior to the equator and lateral to the axial plane. The inferior oblique muscle arises close to the orbital opening of the lacrimal canal and inserts into the globe behind the equator lateral to the axial plane. The oculomotor nerve supplies all the extra-ocular muscles, with the exception of the superior oblique (supplied by the trochlear nerve)

and the lateral rectus muscle (supplied by the abducens nerve).

Function of the extra-ocular muscles (Fig. 224, above): The horizontal rectus muscles (lateral and medial) rotate the eye laterally and medially (abduction and adduction respectively). The superior rectus runs slightly outwards from its origin to insert just lateral to the axial plane, so when this muscle contracts with the eye in the straight ahead position, the action can be subdivided into three components: elevation, adduction and intortion. If the eye is abducted by 23° from the straight ahead position, the rectus becomes an elevator alone. In adduction the pull of the muscle is at right angles to the anterior/posterior axis of the eye so that its adductive and intortive actions assume greater significance (Fig. 219a–c). The inferior rectus is an extorter, depressor and adductor, but when the eye is abducted 23° the muscle is a prime depressor. The superior oblique muscle is an intorter, depressor and abductor, but if the eye is adducted 51° the superior oblique acts as a pure depressor (Fig. 219d–e). The inferior oblique is an elevator, extorter and abductor, but when the eye is adducted 51° the superior oblique becomes a prime elevator.

A distinction is made between synergistic muscles, i.e. muscles that move both eyes in the same

involved the resulting condition is known as an **ophthalmoplegia interna**.

Aetiology: Drugs; the effects of atropine last about 10 days, scopolamine 4–6 days and homotropine 1–2 days. Other causes include trauma, iridocyclitis, myotonic pupil, botulism. Centrally located disturbances of accommodation occur with meningitis, tumours involving the mid-brain, head trauma, syphilis and diphtheria. **Treatment:** Should be directed towards the underlying cause.

Asthenopia

A term used to describe symptoms caused by ocular fatigue or strain. These include

blurred vision, headache, pain in or around the eyes, photophobia and tearing. Symptoms tend to occur towards the end of a working day. **Aetiology:** The condition occurs following prolonged close work, the use of insufficiently strong reading glasses, inadequate accommodation or the performance of delicate tasks in poor levels of illumination. The same features also occur in patients with a reduced ability to turn the eyes inwards for close work (convergence insufficiency) and large latent squints which have a tendency to break down (see Chapter 19). Asthenopia occurs more often in patients suffering from mild exhaustion or recovering from serious systemic diseases. **Treatment:** Should be directed towards the underlying cause.

19. Binocular Vision and Strabismus

General considerations

Extra-ocular muscles

The globe is moved by six extra-ocular muscles, consisting of four recti muscles (superior, inferior, lateral and medial) and two oblique muscles (superior and inferior) (Fig. 217). In most people the movements of the eyes are co-ordinated so that the images of the object of regard fall on corresponding retinal points (foveae). The four recti muscles, together with the levator palpebrae superioris and the superior oblique, arise from a fibrous ring surrounding the optic foramen and insert into the globe anterior to the equator. The superior oblique muscle passes forwards between the roof and the medial wall of the orbit to the trochlea, which is situated on the nasal side of the orbital roof a few millimetres posterior to the orbital margin, loops round this structure and passes backwards to insert into the globe posterior to the equator and lateral to the axial plane. The inferior oblique muscle arises close to the orbital opening of the lacrimal canal and inserts into the globe behind the equator lateral to the axial plane. The oculomotor nerve supplies all the extra-ocular muscles, with the exception of the superior oblique (supplied by the trochlear nerve)

and the lateral rectus muscle (supplied by the abducens nerve).

Function of the extra-ocular muscles (Fig. 224, above): The horizontal rectus muscles (lateral and medial) rotate the eye laterally and medially (abduction and adduction respectively). The superior rectus runs slightly outwards from its origin to insert just lateral to the axial plane, so when this muscle contracts with the eye in the straight ahead position, the action can be subdivided into three components: elevation, adduction and intortion. If the eye is abducted by 23° from the straight ahead position, the rectus becomes an elevator alone. In adduction the pull of the muscle is at right angles to the anterior/posterior axis of the eye so that its adductive and intortive actions assume greater significance (Fig. 219a–c). The inferior rectus is an extorter, depressor and adductor, but when the eye is abducted 23° the muscle is a prime depressor. The superior oblique muscle is an intorter, depressor and abductor, but if the eye is adducted 51° the superior oblique acts as a pure depressor (Fig. 219d–e). The inferior oblique is an elevator, extorter and abductor, but when the eye is adducted 51° the superior oblique becomes a prime elevator.

A distinction is made between synergistic muscles, i.e. muscles that move both eyes in the same

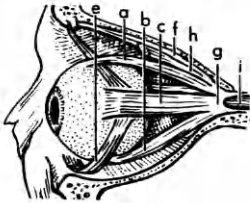
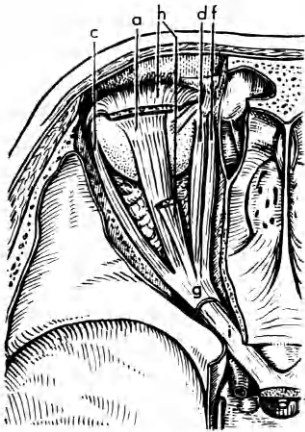


Fig. 217. Superior and lateral views of orbit: a superior rectus muscle; b inferior rectus muscle; c lateral rectus muscle; d medial rectus muscle; e inferior oblique muscle; f superior oblique muscle (with trochlea); g annular tendon (ring tendon); h levator palpebrae muscle (sectioned); i optic nerve

direction (e.g. the right lateral rectus and the left medial rectus on looking to the right, or the left superior rectus and right inferior oblique when looking up to the left) and antagonistic muscles which move the eyes in opposite directions (e.g. both medial rectus muscles). Exact coordination of the synergistic muscles is necessary to produce conjugate gaze movements (versions), i.e. looking to the left or right. Disjunctive ocular (vergence) movements are brought about by contraction of antagonistic muscles, i.e. convergence or divergence for looking at near or distant objects.

Ocular motor nuclei (Fig. 218)

Oculomotor (3rd nerve) nucleus: An elongated mass of cells lies in the periaqueductal grey matter of the mid-brain. Individual extra-ocular muscles are represented by clumps of cells within the oculomotor nucleus.

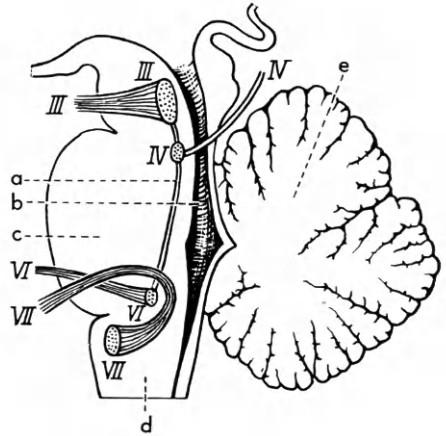


Fig. 218. Positions of ocular motor nuclei: a median longitudinal bundle which links the ocular motor nuclei; b Sylvian aqueduct; c pons; d medulla oblongata; e cerebellum

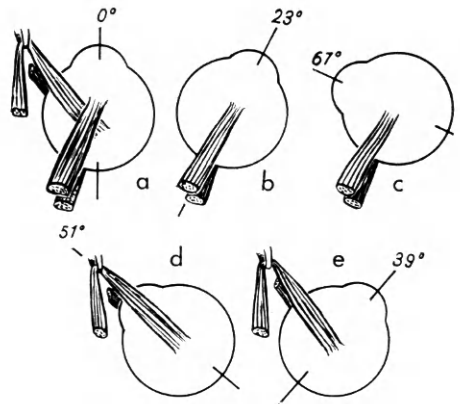


Fig. 219. Action of the vertical eye muscles (right eye, viewed from above): a gaze straight ahead; b position in which the superior rectus muscle is a pure elevator; c position in which torsional action of the superior rectus muscle is greatest; d position in which torsional oblique muscle is a pure depressor; e position in which torsional action of the superior oblique muscle is greatest

Trochlear (4th nerve) nucleus: The cells of origin of the trochlear nerve are located in the grey matter immediately behind the ocular motor nuclei of the upper part of the pons.

Abducens (6th nerve) nucleus: Lies immediately beneath the floor of the 4th ventricle in the dorsal part of the pons.

The **median longitudinal fasciculus** connects all the intra-ocular motor nuclei and is also a pathway by which impulses pass to these nuclei from the vestibular apparatus.

Gaze centres (Fig. 220, above): The ocular motor nuclei are controlled by gaze centres, which are responsible for the coordinated movements of the eyes. These are located in the pons (horizontal

movements) and mid brain (vertical movements). Centres in the frontal lobe control voluntary eye movements to command, whereas the centres in the occipital lobe control involuntary eye movements concerned with following and tracking. Pathways lead from these supranuclear centres to the ocular motor nuclei (see below). The vestibular nuclear complex acts in much the same way as the above centres, controlling the position of the eyes in space in relation to gravity and changes of acceleration (Fig. 220, below).

Binocular vision

Binocular single vision may be defined as the co-ordinated use of two eyes to produce a single mental impression. The law of projection of images establishes that an object which forms its image on any point in the retina is projected to a point in space directly opposite. When a distant object is viewed with both eyes normally the visual axes are parallel, so that each fovea receives an image of the object. Distant objects which are not directly in the line of the visual axes are also observed singly because, again, images fall on corresponding retinal areas which are situated to either side of, above or below the fovea. When images do not fall on corresponding

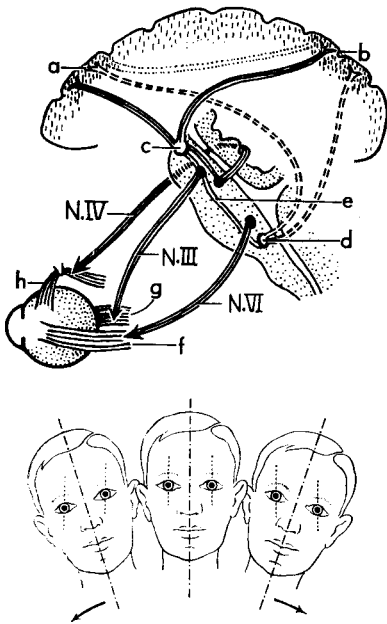


Fig. 220. Above: Gaze centres (schematic drawing): a frontal centre; b occipital centre; c 'centre' for vertical eye movements; d 'centre' for horizontal eye movements; e median longitudinal bundle; f lateral rectus muscle; g medial rectus muscle (6th nerve); h superior oblique muscle (4th nerve). The gaze centres are linked to the ocular motor nuclei by corticonuclear pathways. Below: Torsional movement to the eye when the head is tilted, activated by the vestibular apparatus




Fig. 221. Slides for determining grades of binocular vision. a Half-images for determination of simultaneous macular perception, which is present if both creatures are seen together; b half-images for identifying binocular fusion - the patient should see both images fused in the stereoscope; c stereo pair half-images - the small triangles are drawn so that one is seen in front of the slide and the other behind, if stereoscopic vision is present

retinal points, as for example when the image in one eye falls on the fovea and in the other eye is well to one side or the other, retinal correspondence is absent, the images are disparate and diplopia results. This can be demonstrated by a placing a powerful prism in front of one eye.

Grades of binocular vision (Fig. 221) are classified as follows:

Grade I. Simultaneous macular perception: Images of the objects fall on the fovea of both eyes and are appreciated at the same time.

Grade II. Binocular fusion: True fusion, with some amplitude, in which images are brought together and held so long as the images are centred on each fovea.

Grade III. Stereopsis: This the ability of individuals to perceive in depth (three-dimensional vision), and thus evaluate their position in relation to the environment.

Monocular clues to depth perception include perspective, parallax, shading, size and relation to other objects, colour (distant objects appear bluer than near objects) and definition (outlines of distant objects are less well defined due to atmospheric haze). **Squints** may be defined as a situation where the visual axes do not intersect at the point of regard, and are broadly divided into two groups: incomitant and concomitant.

Incomitant (paralytic) strabismus

The mobility of the globe or globes is impaired as a result of paresis of one or more extra-ocular muscles, or because their action is limited.

As an example of paralysis of a single extra-ocular muscle, if the right lateral rectus muscle is paralysed, the deviation of the visual axes is greatest when the eyes are rotated to the right, so that the visual axes intersect in front of the object of regard (convergent squint), and is least, or absent, when the eyes are rotated to the left, since the globe has moved out of the sphere of action of the defective right lateral rectus muscle.

Acquired incomitant squints give rise to diplopia because an image formed by the object of regard (the cross in Fig. 222) falls on the macula of one eye only. A dissimilar image falling on the macula of the squinting eye is normally suppressed to avoid seeing two different objects (confusion). Stimulation of non-corresponding retinal points in an individual who has previously acquired binocular vision gives rise to the impression that the object of regard is double, the non-fixing eye positioning the object in the temporal field of vision in a convergent squint. Conversely, images falling temporal to the macula in a divergent squint are projected to the nasal field (false projection). **The angle of strabismus** in a paralytic squint is smaller if the non-deviated eye is

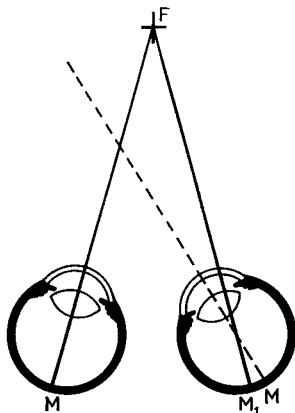


Fig. 222. Geometrical optics of diplopia; in the right eye the image of the fixation point (+) does not fall on the macula



Fig. 223. Paralysis of the right lateral rectus muscle: a primary angle of strabismus, left eye fixing; b secondary angle of strabismus, right eye fixing

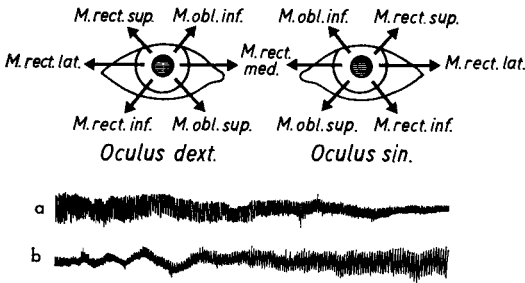


Fig. 224. Above: Directions of primary action of the six ocular muscles. Below: Electromyography showing potentials recorded as the left eye rotates from left to right. a Records from electrodes in lateral rectus muscle; b records from electrodes in medial rectus muscle demonstrating reciprocal innervation

used for fixation and greater if the deviated (squinting) eye is required to take up fixation. The primary angle of strabismus is therefore smaller than the secondary angle (Fig. 223) because when the paralytic eye is used for fixation, increased nerve impulses are transmitted to both the paralysed muscle and its synergist in an attempt to overcome the squint. To reduce the problems of diplopia, a patient may develop a **compensatory head posture**. In the case of a right lateral rectus palsy the head is turned to the right, so that single binocular vision can be maintained with all eye movements to the left including the straight ahead position.

Examination procedures

Testing of ocular motility: The patient is asked to move his eyes in the cardinal position of gaze, i.e. straight ahead, up, up to the left, left down to the left, down, down to the right, right, up to the right. Each extra-ocular muscle has a position in which its primary action is greatest into which the eye cannot move if this muscle is paralysed (Fig. 224, above).

Diplopia testing (only applicable in patients with acquired squints who previously had single binocular vision). To determine which extra-ocular muscle is underacting, the images falling on the two retinae can be identified by putting a coloured filter in front of one eye. Thus, using a point light source, a red image is formed on one retina and a white image on the other. When the

eyes are turned into the position where a paralysed intra-ocular muscle is normally active, the two images show maximum separation. However, if the two eyes are turned away from the sphere of action of the paralysed extra-ocular muscle, the two images become superimposed. For example, in a case with paralysis of the right lateral rectus horizontal separation of images is greatest on looking to the right and least on looking to the left (Fig. 225). The image perceived by the paralysed eye is always projected more to the periphery than that by the nonparalysed eye. Thus, with a red filter over the right eye, the red image is projected further peripherally on attempted gaze to the right. If the left medial rectus were the paralysed muscle, then the white light would be projected the furthest laterally. With a left inferior rectus palsy, verti-




Fig. 225. Result of diplopia test in a case of right lateral rectus paralysis (red filter in front of right eye); images are furthest apart with gaze to the right

cal separation of images is greatest on looking down to the left. With a red filter over the right eye the white image is inferior to the red. The reverse would be true in the case of a right superior oblique palsy. If the patient complains of vertical diplopia an elevator or depressor muscle is involved. If no vertical diplopia is present but a horizontal separation of images is reported, then a horizontally acting muscle is implicated. *Measurements of the angle of squint* can be made by use of a major amblyoscope (Fig. 235b). This instrument consists of two tubes equipped with mirrors so that images are presented separately to each eye. The angle of the tubes is adjusted so that the projected images fall on both maculae, and in this way the objective angle of the squint can be ascertained.

The Hess screen test requires that the patient indicates red marks on a screen with a green pointer while wearing red/green glasses. In this test there is binocular dissociation, so diplopia is not utilized to determine the defects of ocular motility but the disturbed projections of the maculae.

Electromyography: Muscle potentials can be recorded by inserting fine needle electrodes into the extra-ocular muscles. Fig. 224, below, shows normal electromyograms of the medial and lateral, rectus muscles when gaze is directed to the left and right, demonstrating reciprocal firing patterns. In an extra-ocular muscle paresis the electrical activity of the affected muscle is reduced. This test is somewhat painful, and has only a limited application in clinical practice.

Types of extra-ocular muscle paralysis

Abducens nerve paralysis is the most common extra-ocular muscle palsy encountered, because the long intracranial course of the abducens nerve permits a large variety of pathological processes to act upon it. With paresis of a lateral rectus muscle horizontal diplopia occurs, which is greater for distance than for close vision. **Aetiology**: Lesions which may involve the nuclei and nerves with the brain stem, cavernous sinus and orbit include vertebral insufficiency,

systemic hypertension, raised intracranial pressure, posterior fossa and cavernous sinus tumours, trauma, middle ear disease, meningitis and encephalitis.

Trochlear nerve paralysis: The superior oblique muscle is a depressor in adduction, so that the deviation of the visual axes and diplopia are greatest when the patient is required to look down in the direction away from the eye with the paralysed muscle, i.e. left superior oblique paresis produces maximum vertical diplopia looking down to the right. Because the vertical action of the superior oblique muscle is greatest in adduction, vertical diplopia is greater for near than for distance vision. The superior oblique has a marked torsional role, normally intorting the globe (rolling in of the eye), so the patient frequently develops a compensatory head posture in which the chin is depressed to overcome the depressing action of the muscle, and tilted away from the side of the paralysed muscle to reduce the effects of extorsion produced by this paralysis. The superior rectus and superior oblique muscles are both intorters of the globe, but act against each other to eliminate vertical movements when the head is tilted. Thus, if the head is inclined to the side of the globe with the paralysed superior oblique muscle, a marked upward deviation of this eye is noted. **Aetiology**: Lesions involving the nuclei, brain stem, cavernous sinus and orbit, as for the abducens, but trauma is the most common cause of underactivity of this muscle. Falls from a height where the head is rotated, e.g. falling off a horse, may cause rupture of the nerves as they decussate in the anterior medullary velum.

Oculomotor paralysis: Because of the unopposed action of the lateral rectus supplied by the abducens, the affected globe is rotated outwards (divergent squint). There is no depression of the eye, since it is rotated out of the position where the superior oblique muscle can act as a depressor. Diplopia may not be a problem, because paralysis of the levator palpebrae superioris produces ptosis. A distinction is made between

complete oculomotor paralysis, in which all the eye muscles supplied by the oculomotor nerve, including its parasympathetic component, are affected (total 3rd nerve palsy) and situations in which the parasympathetic element is preserved. **Aetiology:** Lesions involving the 3rd nerve nucleus alone are extremely rare, but involvement in the brain stem is by no means uncommon. Oculomotor paralysis associated with contralateral extrapyramidal signs indicates a lesion at the level of the red nucleus. Oculomotor palsy combined with crossed pyramidal signs locates a lesion to the level of the cerebral peduncles. Oculomotor palsy without any other neurological signs is suggestive of a disturbance to the nerve between the point where it leaves the brain stem and that at which it enters the posterior part of the cavernous sinus, i.e. tumours including aneurysms located close to the posterior part of the circle of Willis. Within the cavernous sinus, lesions are liable to cause combined cranial nerve palsies; the 3rd, 4th and 5th cranial nerves may all be involved with tumours at this site. Similar changes will occur with disturbances involving the orbital apex, but can in the case of space-occupying lesions be differentiated from cavernous sinus pathology by the presence of proptosis of the globe. Diseases causing oculomotor nerve palsies include encephalitis, meningitis, multiple sclerosis, systemic hypertension, diabetes, tumours, trauma and migraine. *Total ophthalmoplegia* is a condition in which paralysis of all the extra-ocular muscles occurs. This is usually due to pathological processes located within the cavernous sinus or in the orbit, more occasionally as a result of myopathies.

Limitations of ocular movements due to causes other than nerve palsies

Restriction of extra-ocular movements is not always due to disturbances of the extra-ocular motor nerves. Entrapment of the inferior rectus muscle following a blow-out fracture of the orbit, and fibrosis of the inferior rectus muscle in dysthyroidism may

mimic a superior rectus palsy. However, duction tests under local anaesthesia will determine that the mobility of the eye is restricted in such circumstances. Similarly, weakness of the extra-ocular muscles is often an early manifestation of myasthenia gravis (see below). **Treatment:** The nature of the lesion causing the extra-ocular muscle palsy should be ascertained and treated as necessary. In many cases the extra-ocular muscle palsies recover spontaneously. Extra-ocular muscle surgery should therefore not be performed until it has been established that no further recovery is going to take place, and not, in most cases, before 3 months after the onset of the ocular deviation. Strengthening of the paretic muscle is of little value, so surgical procedures are usually directed towards weakening the ipsilateral antagonist or the contralateral synergist, or to shortening the contralateral antagonist. The objective of surgery is to restore binocular single vision in the primary position of gaze and to gain as large a field of binocular vision as possible.

The diagnosis of **myasthenia gravis** (a disease characterized by a defect of neuromuscular transmission) must always be considered in patients presenting with a history of diplopia which is worse in the evening than in the morning, or in whom, on examination, a lesion attributable to paralysis of one cranial nerve cannot be established. Intravenous injections of Tensilon will frequently result in a dramatic, but transient, restoration of extra-ocular movements; a positive Tensilon test is diagnostic of this condition.

Other defects of extra-ocular motility

Gaze palsies are due to disturbances of pathways located in the brain stem or central to the extra-ocular motor nuclei which control muscle movements. Lesions of pathways connecting the frontal and occipital cortex to the extra-ocular motor

nuclei in the brain stem cause defective responses to command and pursuit movements respectively. Since the movements of the eyes are limited to the same extent and in the same direction, no diplopia occurs.

Vertical gaze palsies are often caused by lesions affecting the upper part of the brain stem. Dorsal lesions close to the pretectal nuclei produce disturbances of upward gaze, and more deeply located lesions in the region of the substantia nigra produce defects of downward gaze. **Aetiology:** Tumours, arteriovenous malformations, degenerations, trauma, encephalitis.

Disorders involving the pretectal region and the anterior part of the 3rd nerve complex may produce not only defects of upward gaze but also paralysis of accommodation and convergence (periaqueductal syndrome). Eye movements on tilting the head up or down are present if the vestibular oculomotor pathways remain intact (doll's head phenomenon).

Horizontal gaze palsies are frequently due to lesions adjacent to the lateral gaze centres in the pons. Supranuclear gaze palsies can be differentiated from lesions involving the extra-ocular motor nuclei or their nerves since, providing the vestibular nuclei and their connections with the extra-ocular motor nuclei are intact, the eyes can be moved in response to rotating the head (so-called doll's head responses). In unconscious patients caloric responses may be helpful in differentiating supranuclear from nuclear or infranuclear gaze palsies. If cold water is instilled into one ear, the eyes tend to deviate to the same side. Caloric tests using warm water have the reverse effect. NB, Irrigation of the ears with cold water induces nystagmus (fast phase) to the opposite side, warm water nystagmus to the same side.

Internuclear ophthalmoplegia occurs as a result of lesions involving the median longitudinal fasciculus and the adjacent pontine reticular formation, and is characterized by the following features: on horizontal gaze to the side opposite to that of the lesion the

contralateral abducting eye shows a jerky nystagmus, while the ipsilateral adducting eye fails to adduct fully, though convergence movements remain intact. In recovery from such lesions the movement of the ipsilateral adducting eye is slower than that of the contralateral abducting eye, but each eye reaches the fixation point at the same time, the abducting eye over-shooting and returning to its final position.

Nystagmus is a condition defined as involuntary to and fro oscillations of the eyes. It may be predominantly horizontal, vertical or rotatory, and combined forms often co-exist. In acquired, as opposed to congenital, nystagmus the patient may be aware of wobbling vision (oscillopsia). There are two main forms of acquired nystagmus.

Pendular nystagmus appears early in life as a result of opacities of the ocular media, damage to the retina or to the afferent visual pathways. Central fixation does not develop and the globes show a rapid to and fro oscillation, the rate of which is almost equal on both sides. In **jerky nystagmus** the rate of movement to each side is different. The direction of the fast component determines whether the nystagmus is said to be to the right or left, up or down. Nystagmus due to disturbances of the peripheral vestibular apparatus tends to be transient, but with destructive lesions of the central vestibular connections nystagmus is permanent. Damage to the peripheral vestibular apparatus on the right side will cause nystagmus to the left. Patients with gaze palsies also show a jerky nystagmus of a larger amplitude and slower frequency than those with vestibular nystagmus.

Physiological forms of nystagmus (which can be induced in a healthy individual) are end point nystagmus, which is seen at the extremity of lateral gaze, optokinetic nystagmus, noted in individuals observing moving objects (e.g. telegraph poles out of a moving train), and vestibular nystagmus (labyrinthine), when the body is rotated in a chair and also in response to caloric stimulation.

Concomitant strabismus

Concomitant strabismus is subdivided into convergent squints or esotropias, divergent squints or exotropias and vertical squints or hypertropias (Fig. 226).

Approximately 2 per cent of children born in the United Kingdom have, or will develop, a concomitant squint by the age of 3 years. In a proportion of these children the sight of the deviating eye will deteriorate (amblyopia) if treatment is not instituted. The majority of children who develop squints at or soon after birth do not acquire single binocular vision, and thus a number of occupations will be barred to them in adult life, including commercial and military flying, train driving, etc. With a concomitant squint the deviation of the visual axes is the same in all directions of gaze. There is no limitation of the movements of either globe when tested separately, and the primary and secondary deviations are equal in magnitude.

Monocular strabismus: Only one eye is used for fixation. Visual function in the deviated eye becomes progressively impaired, initially as a result of facultative suppression of the macula, and later, if the state is maintained, suppression becomes obligatory. Diplopia is not appreciated because the extramacular point in the squinting eye, to which the object of regard is projected, is also suppressed. In a child with a monocular squint the macula of the squinting eye fails to form the full range of central connections and, if treatment is not insti-

tuted early, vision in this eye will become permanently impaired, i.e. the eye will become amblyopic. Patients who develop amblyopia have grossly deficient discrimination sense in the affected eye (i.e. cannot read fine print, etc.) but movement appreciation, colour and night vision faculties remain intact. An amblyopic individual



Fig. 227. a Squint affecting identical twins; b alternating squint, showing fixation with right and left eyes

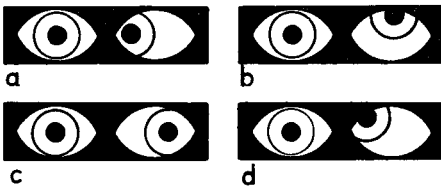


Fig. 226. Types of concomitant strabismus: a convergent strabismus; b vertical strabismus; c divergent strabismus; d combination of vertical and convergent strabismus

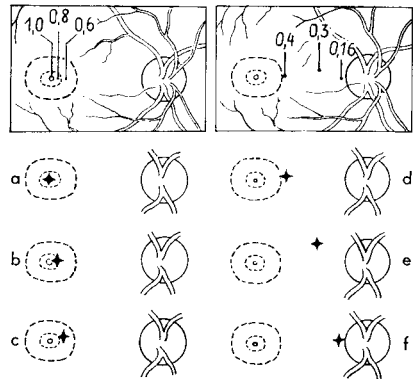


Fig. 228. Types of fixation in amblyopia, with corresponding visual acuity; a central; b macular; c paramacular; d-f eccentric. The attainable values of visual acuity are shown in the diagram above using the Continental convention




Fig. 229. Pseudo-strabismus (resulting from abnormal position of the eyeball in relation to the inner canthi, palbebral fissures, etc.): a normal eye position; b pseudo-exotropia; c pseudo-esotropia

does not fixate with the macula, so that fixation may be parafoveal, paramacular or even eccentric (Fig. 228), and the greater the distance of the fixation point from the fovea, the lower is the visual acuity. Amblyopia does not develop in squints acquired after the sixth year of life.

Other causes of amblyopia: Children of preschool age who have one eye occluded for long periods of time (e.g. by wearing a bandage following ocular surgery because of congenital ptosis, etc.) or who have marked anisometropia or severe astigmatism may also develop amblyopia. In amblyopic children no disturbances are visible on ophthalmoscopic examination, and the pupillary light reflexes are unimpaired.

Alternating strabismus: The child is able to fix with either eye in alternation. Suppression of the macula therefore remains facultative, and hence this type of squint cannot give rise to amblyopia (Fig. 227 b).

Differential diagnosis between concomitant and incomitant strabismus is shown in Table 3.

Pseudo-strabismus (apparent esotropia or exotropia) occurs if the interpupillary distance is abnormally large or small (Fig. 229 b-c). Abnormalities of the orbits may be present, or prominent epicanthic folds

Table 3. Differential diagnosis between incomitant and concomitant strabismus

	Incomitant strabismus	Concomitant strabismus
Aetiology	Disorders of ocular muscles, neuromuscular transmission, oculomotor nerves and nuclei	Often unknown. Inheritance; hypermetropia; brain damage at or before birth; prematurity, opacities of ocular media; retinal disturbances or optic nerve lesions in one or both eyes
Age: onset of disorder	May occur at any age; predominantly in adults; onset usually sudden	Mainly early childhood; onset usually gradual, or present at birth
Diplopia	Invariably present if patient has developed binocular vision	Not present due to suppression
Angle of strabismus	The largest deviation occurs when the globe is rotated into the direction of action of the paralysed muscle	Deviation is the same in all directions of gaze
Visual acuity	Unaffected	Often unilateral amblyopia if squint not treated
Stereoscopic vision	Intact, though disturbed functionally by diplopia	Absent

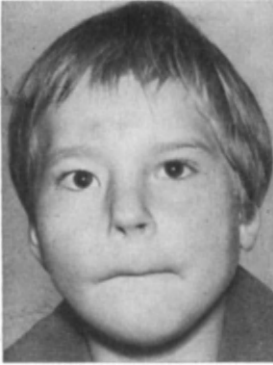

Fig. 230. Pseudo-esotropia caused by prominent epicanthal fold

evident (Fig. 230). Pseudo-squint can be differentiated from true squint by means of the cover test (see below).

Aetiology

Concomitant squints presenting in children at or immediately after birth are commonly found in association with severe brain damage, e.g. spastics and athetoids, mongols, etc. Children who were born prematurely or who suffered respiratory embarrassment in the early postnatal period are also liable to develop manifest deviations. There is often a family history of squint (Fig. 227a), and the mother should be questioned about this and also whether there is any history of meningitis or of cerebral trauma to the child. Concomitant squints are much more common in children who are hypermetropic.

Examination

First, it is necessary to identify whether a manifest squint is present by performing the cover test (Fig. 231a-b). The child is persuaded to regard objects directly in front of him (moving toys, flashing lights or the examiner's face may hold attention) and the fixing eye is then covered with the hand. This results in a movement of the

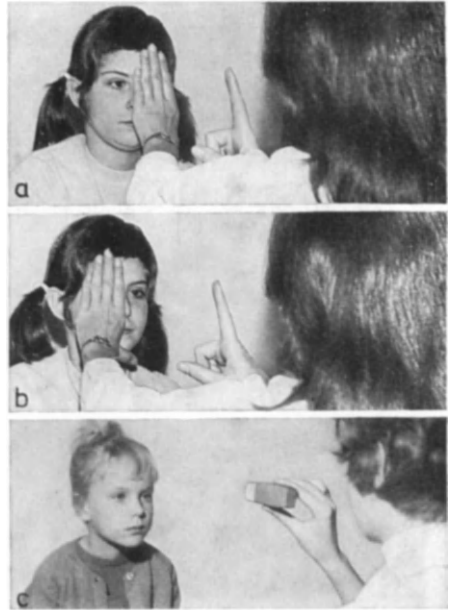


Fig. 231. a-b Cover test by alternately covering and uncovering each eye and observing the adjusting movements of the eyes; c target light test to diagnose strabismus by corneal reflections

deviating eye if a squint is present to take up fixation (providing eccentric fixation is not present). On removal of the occlusion, in a monocular squint the deviating eye returns to its original position and the previously covered eye, which has deviated under cover, again takes up fixation. In an alternating squint, the previously deviating eye continues to fixate and there is no movement of this eye when the opposite eye is uncovered (Fig. 232).

The angle of squint may be determined by testing the corneal reflections from a point light source (Fig. 231c). The light reflexes should normally be situated symmetrically on the cornea in children who have binocular fixation and in pseudo-strabismus, but asymmetrically in the presence of a squint (Fig. 233). If the corneal reflex in the deviating eye is located on the margin of the

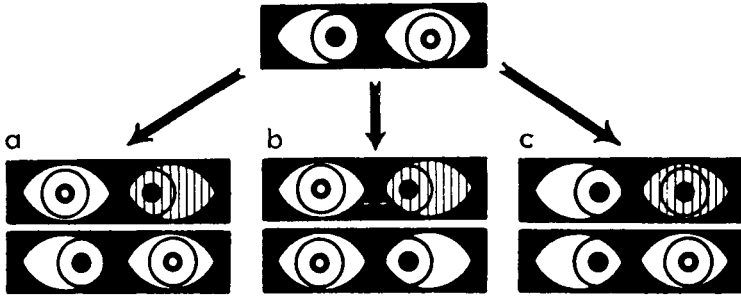


Fig. 232. Different results of the cover test (the right eye squints and the left eye is fixing). **a** Monocular strabismus: after the covering hand has been taken away, the child immediately squints again with the right eye. **b** Alternating strabismus: after the covering hand has been taken away, the previously squinting eye fixes. **c** Monocular strabismus with eccentric fixation and severe squint amblyopia: the squinting eye continues to deviate despite covering the fixing eye




Fig. 233. Position of corneal reflections in strabismus (see text): **a-c** symmetrical position of reflections in normal binocular fixation; **d-f** asymmetrical positions of reflections in strabismus (exotropia, esotropia and hyperopia)

pupil and the light reflex in the fixing eye is central, a squint of approximately 15° is present; if located at the corneoscleral junction, the deviation is approximately 45° . More accurate measurements of the angle of strabismus are obtained by using a tangent scale (Maddox cross). A reflection formed on the cornea by the central light of the scale is observed (Fig. 235a). Older children can be examined with the aid of a major amblyoscope (Fig. 235b) and stereoscope. The two images (Fig. 236b and c) are presented separately to each eye, fusing into a single image (d). The objective angle of strabismus and the range of fusion may be

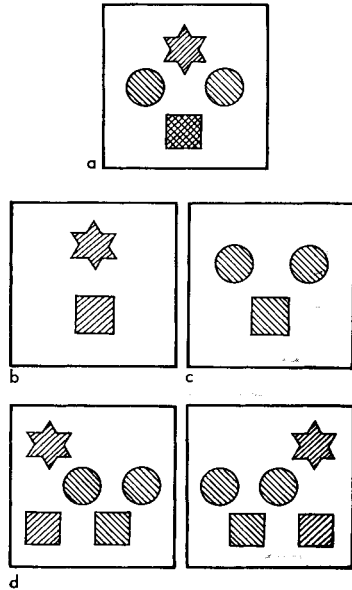


Fig. 234. Worth test: **a** test card (see text); **b-c** results in event of monocular suppression of (b) right and (c) left eye; **d** two possible results in paralytic squint

measured, as can the degree of stereoscopic vision, on this instrument. The angle of deviation may also be determined using prisms in conjunction with the cover test. Increasing strengths of prisms are put in front of the non-squinting eye until no deviation of the eyes is elicited (Fig. 239).

Testing for central fixation: The child looks at a small star projected by an ophthalmoscope and the ocular fundus is examined. If the image of the star falls on the fovea, central fixation exists. In cases in which fixation is not central, the position of the projected star as determined by the examiner will indicate whether fixation is not foveal, i.e. paramacular, or eccentric (Fig. 228).

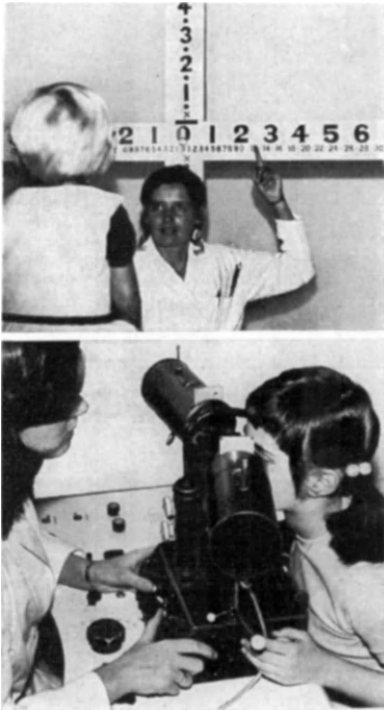

Fig. 235. a Measurement of the angle of strabismus using a tangent scale (Maddox cross); b examination of a squinting child with a major amblyoscope

Other methods of determining the presence of **simultaneous macular perception** in older children include the Worth four-dot test, using a pattern with one red star, two green circles and a white square (Fig. 234a). The child is provided with red/green spectacles, so that the right eye sees the star and the square, and the left eye the two circles and the square. In the presence of a concomitant squint only one eye is used for fixation, giving results as shown in Fig. 234b-c. If there is a paralytic element the positions shown in Fig. 234d are seen. Stereoscopic vision can be assessed in young children by means of a WIRT fly. The child is fitted with polaroid glasses and asked to look at a stereograph of a large house fly. Fear or an attempt to touch the fly indicates the presence of stereoscopic vision.

The **visual function** of the two eyes of the child must be assessed independently. Children who have developed amblyopia are quite happy when the squinting eye is covered, but turn the head if the fixing eye is covered. Some assessment of the degree of visual discrimination is possible using optokinetic drums with various sized objects, picture charts and the Sheridan-Gardner test. In this test the child is given a card with a few large letters printed upon

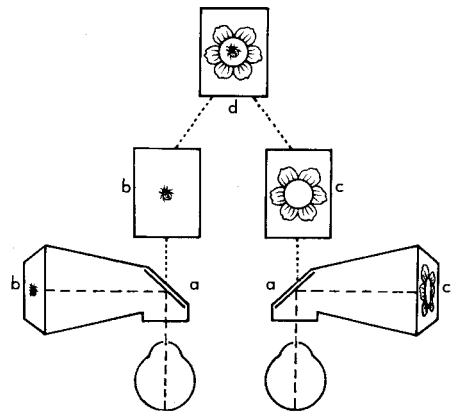


Fig. 236. Diagram of examination by means of a major amblyoscope; a mirror; b image for the left eye; c image for the right eye; d fused image

it; the examiner stands some 3 metres away with a series of cards on which are printed similar letters of graded sizes, so that the child is able to point to the letter on the card which corresponds to the optotype presented to him. This test is effective from the age of about $2\frac{1}{2}$ years. Visual function in younger children can be assessed by seeing if they can pick up small toys, scraps of paper, etc. Pupil responses to light must always be assessed, since defects of the pupillary reflexes will indicate pathology of the afferent visual system (local iris lesions excepted).

Treatment

Corrective lenses must be prescribed if there is any significant refractive error, so that a correctly focused image is projected on to the retina. In hyperopic children who need to accommodate for distance, the excessive accommodation required for near vision may cause a convergent strabismus when looking at close objects; prescription of suitable plus lenses in such cases eliminates the deviation (Fig. 237). Refraction is carried out after inducing paralysis of accommodation by administering atropine 1 per cent ointment three times a day for 3 days, and the refraction determined objectively by means of retinoscopy. Pupil dilation provides an opportunity to perform a full intra-ocular, including ophthalmoscopic, examination. Such an examination is mandatory in all infants presenting with a squint, as children with lesions of the macula or optic nerves often develop concomitant squints because there may be no stimulus to keep the visual axes aligned. *Occlusive therapy:* Children suffering from amblyopia under the age of 6 years are treated by occluding the fixing eye (Fig. 238), in order to promote macular fixation and decrease the level of suppression. Thus, the aim of occlusion is to change a monocular squint to an alternating one. If good vision can be achieved in both eyes and maintained up to the age of 7, amblyopia will never recur. In very young children vision is usually restored in the squinting

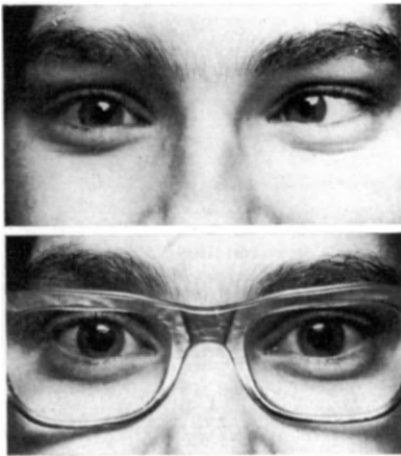


Fig. 237. Effects of hyperopic correction with plus lenses on the angle of convergent strabismus

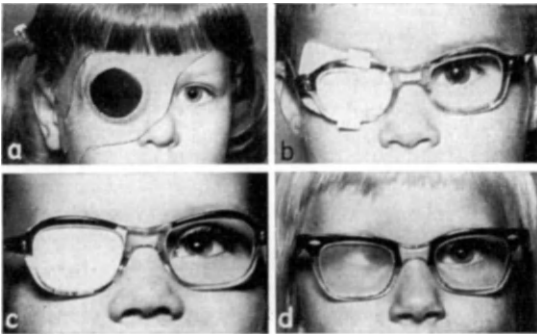


Fig. 238. Occlusive treatment in severe amblyopia: a by means of a bandage; b by means of a plastic occluder; c tape on a spectacle lens; d the use of a semi-transparent covering

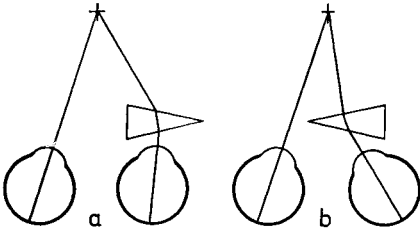


Fig. 239. Effect of prism correction in divergent (a) and convergent (b) strabismus

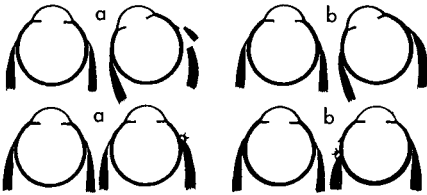


Fig. 240. Correction of convergent strabismus of the right eye: a resection of right lateral rectus muscle; b recession of medial rectus muscle

eye following occlusion within a few weeks, but recovery of vision becomes progressively more difficult in older children. By the age of 6 or 7 years, occlusive therapy tends to yield disappointing results, and amblyopia then becomes a permanent feature.

Surgery is principally performed to reduce the angle of deviation to cosmetically satisfactory levels, since squints are liable to cause comment when the child goes to school and may result in psychological trauma. Surgery performed, for example, for a manifest convergent squint requires a two-muscle operation, i.e. a recession of the medial rectus muscle and resection of the lateral rectus muscle (Figs. 240). In squints appearing at or soon after birth, binocular vision is not often achieved by surgery, even if carried out in the first few months of life, and it would appear that there may well be a primary defect of central organization in assimilating the images produced by the two eyes in such children.

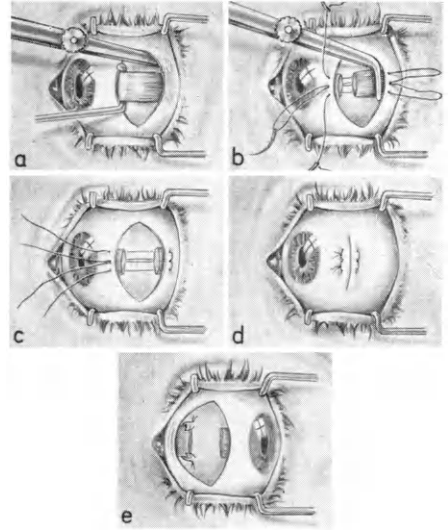


Fig. 241. Operative techniques. a-d Muscle resection: a exposure of the muscle with strabismus hook; b section of the muscle and placing of triple sutures through conjunctiva, muscle and muscle insertion; c dissection of a portion of the muscle; d pulling the sutures together; e recession of the medial rectus muscle

Prophylactic treatment

Screening: All children of pre school age should be screened as soon as possible after birth to ascertain whether a squint is present or not, so that those in danger of developing amblyopia can be treated at the earliest possible time.

Heterophoria

In very few individuals are the actions of the extra-ocular muscles so exquisitely adjusted that some deviation does not occur when the two eyes are dissociated, i.e. by occluding one eye. If there is no deviation under cover, the person is orthophoric. In cases where movements of the eyes occur in the dissociated situation, a latent squint is present, but fixation is taken up as soon as both eyes are used together to observe a

single object of regard in the interest of single binocular vision. A latent squint is detected by the **alternate cover test** in which each eye is covered rapidly in turn and the movement of the eye becoming uncovered assessed and recorded. With a latent convergent squint, the previously occluded eye will move quickly outwards to take up fixation when the occlusion is removed (Fig. 242). The reverse is true with a latent divergent squint, when the previously occluded eye moves inwards.




Fig. 242. Test for heterophoria by covering one eye (centre) in order to suppress the fusion reflex (see text)

20. Social Ophthalmology

Occupational requirements

Certain professions require an extremely high standard of ocular fitness. These include airline pilots, deck officers on board ships, train drivers, signalmen, etc., who have to undergo a careful ophthalmic examination before being accepted for employment. Apart from having no intra-ocular disease and a good visual acuity (without spectacle correction in the case of civil and military pilots), full visual fields, stereoscopic vision and good colour perception are necessary. Private drivers must, with suitable spectacle correction, be able to see a number plate at 25 yards, and commercial vehicle drivers are in addition required to have adequate visual fields. Patients with latent squints of sufficient magnitude to break down under fatigue situations should be discouraged from driving private vehicles, and this condition is an absolute bar to commercial flying. Individuals with defective colour vision should be dissuaded from entering occupations connected with decorating, colour mixing of any type, colour photography and electrical engineering.

Hazardous occupations

In some occupations there is a high risk of ocular injury. These include engineers working on cold metals, especially steel and iron dressers, turners, drillers, riveters, blacksmiths, hot metal workers (furnacemen, glassblowers, chain-makers, etc.). Ocular trauma frequently occurs in coalminers and quarrymen from metal or mineral fragments striking the eye, and the former are liable to receive trauma from hanging wires in tunnels, etc., because of poor illumination. Chemical workers may be exposed to noxious materials following splashes, explosions and escaping vapour. All factories employing more than a certain number of workers are subject to the Factories Acts, and precautions to protect workers are laid down by law. Failure on the part of the management to provide suitable protective clothing, goggles, etc., where necessary, or to screen machines adequately, renders them liable to prosecution under these acts. Factory inspectors are responsible for ensuring that adequate standards are maintained. Failure of an individual worker to make use of the protective devices

single object of regard in the interest of single binocular vision. A latent squint is detected by the **alternate cover test** in which each eye is covered rapidly in turn and the movement of the eye becoming uncovered assessed and recorded. With a latent convergent squint, the previously occluded eye will move quickly outwards to take up fixation when the occlusion is removed (Fig. 242). The reverse is true with a latent divergent squint, when the previously occluded eye moves inwards.




Fig. 242. Test for heterophoria by covering one eye (centre) in order to suppress the fusion reflex (see text)

20. Social Ophthalmology

Occupational requirements

Certain professions require an extremely high standard of ocular fitness. These include airline pilots, deck officers on board ships, train drivers, signalmen, etc., who have to undergo a careful ophthalmic examination before being accepted for employment. Apart from having no intra-ocular disease and a good visual acuity (without spectacle correction in the case of civil and military pilots), full visual fields, stereoscopic vision and good colour perception are necessary. Private drivers must, with suitable spectacle correction, be able to see a number plate at 25 yards, and commercial vehicle drivers are in addition required to have adequate visual fields. Patients with latent squints of sufficient magnitude to break down under fatigue situations should be discouraged from driving private vehicles, and this condition is an absolute bar to commercial flying. Individuals with defective colour vision should be dissuaded from entering occupations connected with decorating, colour mixing of any type, colour photography and electrical engineering.

Hazardous occupations

In some occupations there is a high risk of ocular injury. These include engineers working on cold metals, especially steel and iron dressers, turners, drillers, riveters, blacksmiths, hot metal workers (furnacemen, glassblowers, chain-makers, etc.). Ocular trauma frequently occurs in coalminers and quarrymen from metal or mineral fragments striking the eye, and the former are liable to receive trauma from hanging wires in tunnels, etc., because of poor illumination. Chemical workers may be exposed to noxious materials following splashes, explosions and escaping vapour. All factories employing more than a certain number of workers are subject to the Factories Acts, and precautions to protect workers are laid down by law. Failure on the part of the management to provide suitable protective clothing, goggles, etc., where necessary, or to screen machines adequately, renders them liable to prosecution under these acts. Factory inspectors are responsible for ensuring that adequate standards are maintained. Failure of an individual worker to make use of the protective devices

provided, as a deliberate act, renders him liable to lower levels of compensation in the event of an accident than might otherwise have been the case.

Agricultural workers are also prone to ocular injuries, especially when hedge cutting, and forestry workers may receive scratches to the eyes from tree branches. Exposure to agricultural pesticides may give rise to severe ocular problems.

The amount of compensation awarded following industrial injuries takes into account the degree of visual incapacity, the amount by which the earning power of the individual is reduced, whether the incapacity necessitates a change of occupation and possible retraining, the degree of negligence on the part of the worker and the employer, the amount of suffering, both physical and psychological, and the long term effects of such injuries. Victims of criminal assault, for which damages may not be recoverable from the perpetrators, can obtain awards by applying to the Criminal Injuries Board.

Blindness and visual impairment

Definition of blindness: This does not mean complete loss of sight, but is statutorily defined as follows: the person is so blind as to be unable to perform any work for which eyesight is essential. On this criterion a patient is eligible for blind registration, and thus for tax relief, retraining programmes, provision of a guide dog under certain circumstances, home help, rehousing, etc. For guidance in certification, patients with vision in the better eye of 3/60 or less, 6/60 or less where the visual fields are grossly impaired or better than 6/60 if the fields are constricted to less than 10° from fixation, may be considered blind.

Partial sight: There is no statutory definition of this state, but it applies to a person who is so substantially and permanently visually handicapped as to need aid from the welfare services, which local authorities

are required to provide. In the case of children where the distance vision in the better eye, with suitable spectacle correction, is 6/24 or less, special schooling may be necessary.

Rehabilitation

To provide occupations for blind and visually handicapped individuals there are a number of institutes, workshops and rehabilitation centres. In most areas of the country in order to help a blind person to adapt himself to society and environment local blind associations provide magazines in braille (Fig. 243a), large print books and talking books and newspaper services. Schools for the blind are intended for children with such a degree of visual handicap that they cannot benefit from a normal education.

Occupations suitable for visually handicapped individuals: Interpreters, personnel managers, basketweavers, audio-typists, computer programmers, telephone operators, piano-tuners, physiotherapists and capstan lathe operators in sheltered workshops, etc.

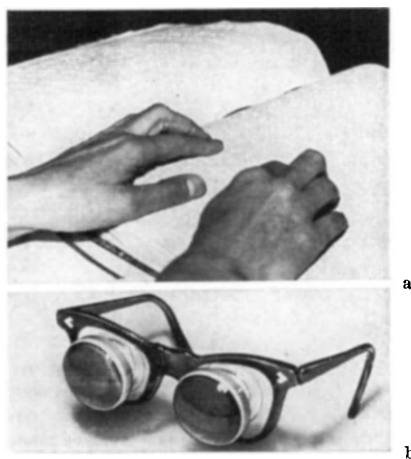

Fig. 243. a Reading with Braille; b low visual aid

21. Ophthalmological Examination Techniques

All clinicians should be able to perform the following elementary investigations.

1. Test the visual acuity for distance and near (p. 125).
2. Assess the visual fields by confrontation (p. 126).
3. Evaluate colour perception using pseudo-isochromatic plates (p. 128).
4. Evert both the lower and upper lids (p. 12).
5. Test the patency of the lacrimal drainage apparatus using fluorescein dye.
6. Examine the integrity of the corneal epithelium by means of instillation of fluorescein and test corneal sensitivity.
7. Examine the cornea, anterior chamber and lens using a loupe (p. 39).
8. Examine the refractive media with an ophthalmoscope (p. 135).
9. Investigate the presence of a squint by means of the corneal light reflexes and the cover/uncover test.
10. Thoroughly examine the retina with a direct ophthalmoscope.
11. Test and evaluate the pupillary responses.
12. Irrigate the conjunctival sac following chemical burns.

22. Ophthalmological Emergencies

Correct diagnosis and treatment of many ocular disorders during the initial stages may be of crucial importance in preserving an individual's sight or general health. The first doctor to see the patient is often a practitioner who has little first hand experience in dealing with an ocular emergency. Incorrect diagnosis may have severe implications as to the patient's sight and general health status.

The following disorders are some of the more serious ophthalmological emergencies, and patients suspected of having any of the conditions listed should receive an expert opinion as a matter of urgency:

Trauma: perforation injuries, severe contusions, chemical burns, orbital fractures, orbital cellulitis, lagophthalmos, malignant exophthalmos,

fundus changes indicating malignant hypertension, herpes simplex keratitis, bacterial ulceration of the cornea, neuroparalytic keratitis, endophthalmitis, acute glaucoma, threatened or manifest, infantile glaucoma, central or branch retinal artery embolic occlusion, threatened or manifest, retinal detachments, symptoms of or manifest, papilloedema, optic neuritis, toxic, metabolic and infective, retinal, choroidal or orbital tumours, ophthalmia neonatorum (gonococcal), sudden onset of paralytic squint, gaze palsy or nystagmus, especially in the younger age group, visual field defects suggesting extra-ocular lesions of the afferent visual pathways.

21. Ophthalmological Examination Techniques

All clinicians should be able to perform the following elementary investigations.

1. Test the visual acuity for distance and near (p. 125).
2. Assess the visual fields by confrontation (p. 126).
3. Evaluate colour perception using pseudo-isochromatic plates (p. 128).
4. Evert both the lower and upper lids (p. 12).
5. Test the patency of the lacrimal drainage apparatus using fluorescein dye.
6. Examine the integrity of the corneal epithelium by means of instillation of fluorescein and test corneal sensitivity.
7. Examine the cornea, anterior chamber and lens using a loupe (p. 39).
8. Examine the refractive media with an ophthalmoscope (p. 135).
9. Investigate the presence of a squint by means of the corneal light reflexes and the cover/uncover test.
10. Thoroughly examine the retina with a direct ophthalmoscope.
11. Test and evaluate the pupillary responses.
12. Irrigate the conjunctival sac following chemical burns.

22. Ophthalmological Emergencies

Correct diagnosis and treatment of many ocular disorders during the initial stages may be of crucial importance in preserving an individual's sight or general health. The first doctor to see the patient is often a practitioner who has little first hand experience in dealing with an ocular emergency. Incorrect diagnosis may have severe implications as to the patient's sight and general health status.

The following disorders are some of the more serious ophthalmological emergencies, and patients suspected of having any of the conditions listed should receive an expert opinion as a matter of urgency:

Trauma: perforation injuries, severe contusions, chemical burns, orbital fractures, orbital cellulitis, lagophthalmos, malignant exophthalmos,

fundus changes indicating malignant hypertension, herpes simplex keratitis, bacterial ulceration of the cornea, neuroparalytic keratitis, endophthalmitis, acute glaucoma, threatened or manifest, infantile glaucoma, central or branch retinal artery embolic occlusion, threatened or manifest, retinal detachments, symptoms of or manifest, papilloedema, optic neuritis, toxic, metabolic and infective, retinal, choroidal or orbital tumours, ophthalmia neonatorum (gonococcal), sudden onset of paralytic squint, gaze palsy or nystagmus, especially in the younger age group, visual field defects suggesting extra-ocular lesions of the afferent visual pathways.

Subject Index

- accommodation, (*Fig.* 213)
age and, (*Fig.* 216) 137
mechanism of, (*Figs.* 214, 215) 51, 136-7
pareses, 137-8
- Acetazolamide, in treatment of
acute angle closure glaucoma, 74
chronic open angle glaucoma, 72
- acute angle closure glaucoma, (*Fig.* 112a) 72-5
- Adie's syndrome, (*Fig.* 100) 66, 67
- ageing
and accommodation, (*Fig.* 216) 137
and acute angle closure glaucoma, (*Fig.* 112a) 72-5
and disease of the vitreous, (*Fig.* 120) 78
and pupil constriction, 66
and senile cataracts, 55
- allergic oedema of eyelid, (*Fig.* 2) 11-12
- amblyopia, (*Fig.* 228) 146-7
congenital ptosis and, 14
- amblyoscope, for measuring angle of strabismus,
(*Fig.* 235b) 149
- Amphotericin B, in treatment of keratomycosis, 44
- anaesthesia
of cornea, 41
for surgical removal of cataracts, (*Fig.* 85a) 57
- angioid streaks, (*Fig.* 136a) 93
in Paget's disease, 93
- angiomatosis encephalofacialis, *see* Sturge-Weber
syndrome
- anisometropia, 133
- anomalouscopy, for diagnosing colour blindness, 130
- anphthalmos, 29
- anterior chamber, 67
angle of, (*Fig.* 103) 68
- anterior uveal tract, *see* individual components
- antibiotics, in treatment of
acute dacryocystitis, 26
corneal bacterial infections, 43
gonococcal ophthalmia, 33
inclusion blepharorrhoea, 35
keratitis lagophthalmos, 47
marginal ulceration of the cornea, 46
panophthalmitis, 43
phlyctenular keratoconjunctivitis, 36
trachoma, 33
see also named drugs
- antihistamines, in treatment of oedema of eyelids, 19
- antimycotic agents, in treatment of keratomycosis
44
see also named drugs
- antiviral agents, in treatment of
herpes simplex keratitis, 44
herpes zoster ophthalmicus, 18
- aphakia, (*Fig.* 92f) 59, 132
- aqueous humor, (*Figs.* 101a, 102) 67
- arcus juvenilis, 47
- arcus senilis, (*Fig.* 67c) 47
- Argyll-Robertson pupil, 66
- argyrosis, of the conjunctiva, 37-8
- arteriovenous nicking, (*Fig.* 133) 86
- asthenopia, 138
- astigmatism, (*Fig.* 208) 133-4
irregular, bacterial infection causing, 18
caused by lacrimal gland malignancies, 26
- bacterial infections
of conjunctiva, (*Fig.* 14) 31-2;
gonococcal conjunctivitis, 33;
gonococcal ophthalmia of the newborn, 33;
treatment of, (*Fig.* 42) 32
of cornea
seriginous ulcer, (*Figs.* 58a, 59b, 60a b d, 62 b,
63 c, 91) 42-3
of eyelid, (*Figs.* 14, 17) 16-17, 18
panophthalmitis, 43
staphyloma of cornea, (*Figs.* 60f, 67a) 43
- bacterial toxins, causing marginal ulceration of cor-
nea, 46
- band-shaped keratopathy, (*Fig.* 66f) 47
- Bell's phenomenon, 12, 47
- beta-blocking agents, causing Stevens-Johnson syn-
drome, 36
- binocular vision, (*Fig.* 221) 140-1
- Bitot's spots, 37
- blepharitis
and chronic conjunctivitis, 35
squamous, 18; dandruff in, 18
ulcerative, (*Fig.* 19) 18; distichiasis and, (*Fig.* 13)
18
- blepharochalasis, causing narrowing of palpebral fis-
sure, (*Fig.* 2b) 12
- blepharospasm, 14
as a result of corneal disease, 41
- blepharostat, for eyelid examination, (*Fig.* 3) 12
- blindness
caused by; chlamydia, 33-4; gonococcal ophthal-
mia, 33; trachoma, 33-4; congenital glaucoma
in infants, 77
occupation following, 154
rehabilitation following, 154
statutory definition of, 154
- blue sclera syndrome, 50
- Bourneville's disease, (*Fig.* 150a) 99
- Bowman's membrane, 47
- Braille, (*Fig.* 243a) 154

- broad spectrum antibiotics, 43
 in treatment of conjunctivitis, 32
- Buller's shield, 31
 in prevention of corneal desiccation, (*Fig.* 43) 14
 use of in treatment of keratitis e lagophthalmos, 47
- buphthalmos, (*Figs.* 114, 115a) 77
- canal of Schlemm, 27, 49
- cataracts
 in animals, (*Fig.* 84) 59
 anterior polar, (*Fig.* 75g) 52
 associated with systemic disease, (*Fig.* 82);
 dermatogenic, 56; diabetic, (*Fig.* 82a) 55;
 myotonic, (*Fig.* 82c); tetanic, (*Fig.* 82b) 56
- blue dot, 52
- complicated, 56
- concussive, 56
- congenital, 51-2
- coronary, (*Fig.* 76b) 52
- couching of, 59
- in galactosemia, 51
- in Lowe's syndrome, 51
- membranous, (*Fig.* 75k) 52
- in mongolism, 51
- Morgagnian, (*Figs.* 78d, 81c) 54
- nuclear, 52
- opacification, degree of, and, (*Fig.* 78c) 54
- posterior polar, (*Fig.* 75e) 52
- post-polar, (*Fig.* 75g) 52
- pyramidal, (*Fig.* 75h) 52
- radiation, (*Figs.* 83a b) 56
- ring, (*Fig.* 75l) 57
- secondary, (*Figs.* 75kl, 83c) 57
- senile; nuclear, (*Fig.* 75b) 54; posterior cortical,
 (*Fig.* 81a) 54
- surgical removal of, (*Figs.* 85, 86, 87) 57
- toxic, 56
- traumatic, 56
- zonular, (*Figs.* 75c, 76a) 52
- cerebellopontine angle tumor, 14
- chalazion, inflammation of meibomian gland, 16
 treatment of, 18
- chelating agents, in treatment of band-shaped
 keratopathy, 47
- chemical burns
 of cornea, 47
 of eyes, (*Fig.* 189) 190
- chlamydial disease, 34
- choroid, (*Fig.* 88) 60
 congenital colobomas of, (*Fig.* 95) 63
 detachment of, 95
 layers of, 60
 malignant melanomas of, 97-8
 tumors cf, (*Figs.* 130c, 149a b de) 97-9
see also retina
- choroidoretinitis, 62
 disseminated, (*Fig.* 138abc) 89
 juxtapapillary, (*Figs.* 140b, 141a) 90
 purulent, (*Fig.* 139a) 90
- chronic (catarrhal) conjunctivitis, 35
 aetiology of, 35
 treatment of, 35
- chronic open angle glaucoma, (*Fig.* 109) 71-2
 treatment of, 72
- ciliary body, (*Fig.* 88) 59-60
 congenital colobomas of, 63
 malignant melanomas of, (*Figs.* 93c, 94, 97a)
- Cloquet's canal, 28
- colour blindness, (*Fig.* 200) 129-130
- colour vision
 acquired disorders of, 129
 congenital disorders of, (*Fig.* 120) 129
 diagnosis of disorders, (*Fig.* 200) 130
 spectrum of, 128-9
- cones, of retina, 79-80
- congenital abnormalities, of cornea, (*Fig.* 52) 39
- congenital glaucoma, causing widening of palpebral
 fissure, 12
- congenital syphilis, causing interstitial keratitis,
 (*Fig.* 65) 45-6
- conjunctiva
 anatomy of, (*Figs.* 41, 42) 30
 degenerative diseases of, 36-8; argyrosis, 37-8;
 pingueculae, (*Fig.* 49b) 36-7; pterygium, 37;
 xerosis, (*Fig.* 44h) 37
 inflammation of, 14
 irritation of, 14, 22
 melanosis of, (*Fig.* 49d) 38
 scarring of, 14
 tumors of, (*Fig.* 51) 38
- conjunctivitis
 acute; aetiology of, (*Fig.* 44) 31-2; differential
 diagnosis of, 32; features of, (*Figs.* 43a, 59b);
 31; forms of, (*Figs.* 45, 46) 33-5; treatment
 of, (*Fig.* 42) 32
 chronic, forms of, (*Figs.* 47, 48) 35-6
 diphtheritic, (*Fig.* 43b) 31
 ectropion causing, (*Fig.* 10) 15
- contact lenses, 135
 in correction of anisometropia, 133
 in correction of astigmatism, 134
 in correction of of bilateral dense congenital cata-
 racts, 54
 in treatment of filamentary keratitis, 47
 in correction of keratoconus, 48
- cornea
 abnormalities in size, (*Fig.* 52) 39
 bacterial diseases causing: scarring of, 43; serpi-
 ginous ulcer of, (*Figs.* 58a, 59b, 60a b, 61a b d,
 62c, 63c, 91) 42-3; stromal damage of, *Fig.*
 63a b) 43; thinning of, (*Figs.* 60f, 67a) 43

Cornea, continued

- degenerative conditions of, (*Figs.* 66f, 67c) 47
- description of (*Figs.* 1, 52) 39
- disciformis keratitis of, (*Fig.* 2) 11
- disease of, causing blepharospasm, 41
- dystrophies of, (*Figs.* 64c, 66e, 67d, 68, 70) 47-8
- endogenous diseases of (*Figs.* 58bf, 65, 66a, 67ab) 45-6
- examination of, (*Figs.* 54-6) 39-42; in small children, (*Fig.* 53a) 41
- fatty degeneration of, 47
- irritation of, 22
- keratitis sicca of, 36
- marginal ulceration of, (*Fig.* 58f) 46
- metabolic diseases of, (*Figs.* 64d, 69) 48
- mycosis of, 43
- neurotrophic diseases of, (*Figs.* 58de, 66bcd) 46-7
- perforating wounds of, 119
- ulcers of, causing pyramidal cataracts, (*Fig.* 75h) 52
- vascularization of, (*Figs.* 59efg) 41-2
- vital infections of (*Figs.* 58gh, 64ad) 44-5
- Credé's prophylaxis, 33
- cryoextraction, in cataract surgery, 58
- cyclitis, 62
- cyclodialysis, for glaucoma, (*Fig.* 117b) 76
- cycloplegics, in treatment of uveal tract inflammation, 62
- cytopia, 29
- cytostinosis, 48

- dacryo-adenitis
 - acute: diseases associated with, 25; treatment of, 25
 - chronic; aetiology of, 25; treatment of, 25
- dacryocystitis
 - acute, (*Figs.* 31d, 33) 26; treatment of, (*Fig.* 32) 26
 - chronic, (*Figs.* 28b) 23, 24, 26; complications of, 26; treatment of, (*Fig.* 32) 26
 - of the newborn, (*Figs.* 29a-d, 33) 26-7; treatment in, 27
- dacryocystorhinostomy, as treatment of acute dacryocystitis, (*Fig.* 32) 26
- dacryoliths, *see* dacryocystitis
- dacryops, 26
- Dalrymple's sign, 111
- dark adaption, of retina, (*Fig.* 194) 126
- daylight vision, 80
- dermoids
 - of conjunctiva, (*Fig.* 51c) 38
 - of eyelid, (*Fig.* 20e) 19
- dermolipomas, of conjunctiva, (*Fig.* 51b) 38
- Descemet's membrane, 43, 47
 - bacterial infection of, (*Figs.* 60c, 61c) 43

- Desmarre's blepharostat, (*Fig.* 53) 39
- developmental abnormalities, of eyelid, (*Fig.* 24) 20-1
- diabetic retinopathy, 78
- diabetics
 - development of senile cataracts in, (*Fig.* 82a) 55
 - extra-ocular muscle palsies in, 89
- diplopia test, (*Fig.* 225) 142-3
- Down's syndrome, 21
- dynametry, in retinal examination, (*Fig.* 128) 82
- dystrophia myotonica, myotonic cataracts in, (*Fig.* 82c) 56

- Eales's disease, *see* periphlebitis, retinal
- echography, in retinal examination, (*Fig.* 130) 83
- ectropion
 - cicatricial, (*Fig.* 10) 15
 - and epiphora, 25
 - paralytic, (*Fig.* 6) 15
 - senile atonic, (*Fig.* 10) 15
 - treatment of, (*Fig.* 16) 15
- Edinger-Westphal, pupilloconstrictor nucleus of, 65
- electromyography, for recording muscle potential, 143
- electroretinopathy, in retinal examination, (*Fig.* 129) 82
- Elliot's operation, for glaucoma, (*Figs.* 116, 117a) 75
- Elschnig's pearls, 57
- emergencies, ophthalmological, 155
- endophthalms, (*Fig.* 167b) 110
 - causing narrowing of palpebral fissure, 12
 - associated with ptosis, (*Fig.* 6) 13
- entropion, (*Figs.* 8, 9, 11, 12) 14-15
 - cicatricial, 14, 15
 - treatment of, (*Figs.* 11, 13) 14-15
- epicanthus, of eyelid, (*Fig.* 2) 21
- epidemic keratoconjunctivitis, (*Fig.* 63d) 33, 45
- epiphora, 24
 - and chronic dacryocystitis, 26
- epithelial cysts, of eyelid, 19
- examination
 - of cornea, (*Figs.* 54-6) 39-42
 - elementary, ability to perform, 155
 - of eyeball protrusions, (*Fig.* 167a) 109
 - of eyelid, (*Figs.* 3, 4) 12-13
 - of fundus, (*Fig.* 126) 81
 - of lacrimal apparatus, (*Figs.* 28, 29, 30) 23-5
 - of lens, (*Figs.* 74, 81b) 51, 54
 - of pupil for glaucoma, 67-78
 - of retina, 81-3
 - see also named procedures*
- exophthalmos, (*Fig.* 170) 109
- endocrine, (*Figs.* 168, 169)
 - causing widening of palpebral fissure, 12
- explosives, causing conjunctival pigmentation, 37-8

- extra-ocular motility, defects of, 144-5
see also strabismus
- extra-ocular muscles, (*Figs.* 217, 219) 138-9
 function of, (*Fig.* 224) 138
 paralysis of, *see* strabismus
- eyeball
 contusions of, (*Figs.* 176, 179 ab, 180 ab) 117-9
 developmental abnormalities of: anophthalmos, 29;
 cryptophthalmos, 29; cylopia, 29; macrophthalmos, (*Figs.* 37 de) 29; microphthalmos, (*Figs.* 37 a, 38 a) 29; orbital cysts, (*Fig.* 38 b) 29
 embryological development of (*Fig.* 36) 28-9
 enlargement of, in children, (*Figs.* 114, 115 a) 77
 layers composing, (*Figs.* 34, 35) 27-8
 surgical removal of, (*Fig.* 39) 29-30; enucleation, (*Fig.* 39) 30; evisceration, 30; extenteration, (*Fig.* 173) 30, 113
- eyedrops, causing conjunctival pigmentation, (*Fig.* 49 c) 37
- eyelashes
 causing epiphora, 24
 variations in position, (*Fig.* 13)
- eyelid
 allergic oedema of, (*Fig.* 2) 11-12
 anatomy of, (*Fig.* 1) 11
 blepharochalasis of, (*Fig.* 2)
 contraction following irritation or inflammation, 14
 developmental abnormalities of: ankyloblepharon, (*Figs.* 24 b) 20; blepharophimosis, (*Fig.* 24 c) 21; congenital coloboma, (*Fig.* 24 a) 20-1; congenital trichiasis, 21; epicanthus, 21
 disturbances of margin, (*Figs.* 8-13) 14, 15
 epicanthus of, (*Fig.* 2) 21
 erysipelas of, 18
 examination of, (*Fig.* 3) 12
 glands of, (*Fig.* 1) 11, 12
 inadequate closure of, (*Fig.* 6) 14
 inflammation of, caused by: bacteria, (*Figs.* 14, 17) 16, 18; viruses, (*Figs.* 18, 19, 21)
 injury to, (*Figs.* 175 bcd, 177, 178) 115-6
 layers of, (*Fig.* 1) 11
 palpebral fissure of, 12; and old age, 12
 protective function of, 12
 superior medial fatty herniation of, (*Fig.* 2) 11
 swelling of, caused by epidemic keratoconjunctivitis, 33
 tumors of: benign, (*Fig.* 20) 19; malignant, (*Figs.* 21 f, 22 a b c e f, 23) 19-20; neurofibromatosis, (*Figs.* 20 g h) 19
- eyelid cosmetics, causing conjunctival pigmentation, 37
- eye ointment, in treatment of,
 marginal ulceration of the cornea, 46
 neuroparalytic keratitis, 47
 recurrent corneal erosions, 46
- facial paresis, causing widening of palpebral fissure, 12
- Farnsworth-Munsell test, for diagnosing colour blindness, 130
- fibromas, of eyelid, (*Fig.* 20) 19
- filamentary keratitis, (*Fig.* 66 d) 47
- fluorescein angiography, in retinal examination, (*Figs.* 131, 138 c) 83, 90, 97
- foreign bodies
 causing perforating injuries, (*Figs.* 183 c, 184) 119-122
 removal of, (*Figs.* 178, 186, 187) 116, 120
- Foster-Kennedy syndrome, 105
- Fuch's endothelial dystrophy, (*Fig.* 66 e) 48
- fungal keratitis, *see* mycotic disease, of cornea
- fungi, in blockage of canaliculi, 24
- galactosemia, congenital cataracts in, 51
- gargoylism, 48
- gaze centres, (*Fig.* 220) 140
- glands of Moll, 11
- glands of Zeis, 11
- glaucoma, 67
 congenital, (*Figs.* 114, 115 a, 119) 77-8
 neovascular, 84
 primary; acute angle closure, (*Fig.* 112 a) 72-5; aphakic, 76; chronic closed angle, (*Fig.* 108 c) 75; chronic open angle, (*Fig.* 109) 71-2; surgical treatment of, 75-6; therapy of, 72, 74
 secondary; closed angle, 77; malignant, 77, open angle, 77
- globe
 mechanical injuries *tc.* (*Fig.* 178 bc) 116-7
 position of in relation to orbit, disturbances in, 109-110
- goniotomy, in treatment for congenital glaucoma, (*Fig.* 119) 77-8
- Graefe's sign, (*Fig.* 168 b) 111
- Groenblad-Stranberg syndrome, 93
- haemangiomas, of eyelid, (*Figs.* 20 c d) 19
- Halberstadt-Provazek inclusion bodies, 34
- hereditary corneal dystrophies, (*Fig.* 67 d) 48
- herpes simplex, of eyelid, (*Fig.* 18) 19
- herpes simplex keratitis, (*Figs.* 58 gh, 64 a) 44
- herpes zoster ophthalmicus, (*Fig.* 18) 18-19
 treatment of, 18-19
- herpes zoster ophthalmicus keratitis, 44-5
- heterophoria, (*Fig.* 242) 152-3
- homocystinuria, 52
- hordeolitis, 16
 and diabetes, 16

- hordeolum
 external, 16
 internal, (*Fig. 14*) 16
 treatment of, 16
 Horner's syndrome, (*Fig. 5b*) 13
 hyperlipoidema, 47
 hypermetropia, (*Figs. 203a, 204*) 131-2
 frequency of, (*Fig. 206*)
 hyperopia, *see* hypermetropia
 hypoglycaemics, and development of punctate cor-
 tical opacities in, (*Fig. 82a*) 55
 hypophysectomy, 89

 illumination, effect on pupil constriction, 66
 immune serum, in treatment of corneal lesions, 19
 inclusion blennorrhoea, 34-5
 inclusion conjunctivitis, *see* inclusion blennorrhoea
 influenza, causing acute dacryo-adenitis, 25
 injury, to eyes, 114-124
 aggravation of, 124
 chemical, 122-3
 complications of, 121-2
 perforating, 119-122
 radiation, 123-4
 self-inflicted, 124
 simulated, 124
 skull fractures causing, 124
 see also named components
 intra-ocular pressure
 measurement of, (*Figs. 106a,b*) 68-70
 raised, 67
 rise following glaucoma surgery, 77
 see also glaucoma
 5-iodo-2'-deoxyuridine, in treatment of herpes sim-
 plex keratitis, 44
 iridectomy
 broad, (*Figs. 96b, 116*) 74
 peripheral, (*Fig. 96c*) 74
 iridencleisis, for glaucoma, (*Figs. 118a,b*) 75
 iridocorneal angle, (*Fig. 103*) 68
 iris, (*Fig. 88*) 59
 absence of, 64
 atrophy of, 64
 congenital colobomas of, (*Figs. 93d, 96a*) 63
 cysts of, (*Figs. 97c,d*) 64
 iridodensitis of, 53
 iridoschisis, 64
 layers of, 79
 prolapse of, (*Fig. 183a*) 119
 iritis, (*Figs. 91-3*) 60-2

 Kayser-Fleischer ring, 48
 keratitis e lagophthalmos, (*Figs. 58d, 66c*) 47

 keratoconjunctivitis sicca, 25
 causing filamentary keratitis, 47
 treatment of, 25
 keratoconus, (*Fig. 68*) 47-8
 keratomycosis, *see* mycotic disease, of cornea
 keratoplasty
 procedure of, (*Figs. 64c, 70a-f*) 48-9
 prognosis of, 49
 in treatment of: corneal bacterial infection, (*Fig.*
 70) 43; Fuch's endothelial dystrophy, 48;
 hereditary corneal dystrophies, 48; herpes
 simplex keratitis, 44; interstitial keratitis
 caused by congenital syphilis, 46
 keratoscope, *see* Placido's disc
 Koch-Weeks bacillus, 31
 Krukenberg's spindle, 48

 lacrimal apparatus
 developmental abnormalities of, 22
 drainage system of, (*Fig. 27*) 22
 examination of, (*Figs. 28-30*) 23-4
 lacrimal gland, as part of, (*Figs. 25, 26*) 22; secre-
 tions of, 22, 24-5; tumors of, 26
 lacrimal sac, as part of, diseases of, (*Figs. 29a-d,*
 31d) 26-7
 lacrimal gland, (*Fig. 25*) 22
 diseases of secretions, (*Figs. 31a-c*) 25
 laceriation, 24
 treatment of, 24
 lagophthalmos, (*Fig. 6*) 14
 causes of, 14
 treatment of, 14
 Laurence-Moon-Biedl syndrome, 92
 lens
 and accommodation, 51
 anterior polar cataracts of, (*Figs. 75fg*) 52
 coloboma of, 52
 displacement of, (*Figs. 77, 78a,b, 79*) 53
 examination of, (*Fig. 74*) 51
 general features of, 50-1
 injury to, (*Figs. 176, 181a,b*) 118
 layers of, examined by slit lamp, (*Fig. 73*) 51
 leniconus of, (*Fig. 75i*) 52
 nutrition of, 50
 plasticity, reduction of, (*Fig. 214c*) 133
 posterior polar cataracts of, (*Fig. 75e*) 52
 pyramidal cataracts of, (*Fig. 75h*) 52
 refractive power of, (*Figs. 201-3*) 130-1
 senile cataracts of, (*Figs. 75b, 78c,d, 81a-c*) 54-5
 spherophakia of, 52, 53
 zonular cataracts of, (*Figs. 75a,d-g,k, 76b*) 51-2
 lenses, corrective, (*Fig. 210*) 134-5
 see also contact lenses
 lenticonus, (*Fig. 75i*) 52

- leukemia, causing Mikulicz's syndrome, 24
- long-sightedness, *see* hypermetropia
- Lowe's syndrome, congenital cataracts in, 51
- lysozyme, bactericidal action of, 22

- macrophthalmos, (*Figs.* 37e d) 29
- maculopathies, (*Figs.* 142a, 143c, 144a c d) 95-6
- Maddox cross, (*Fig.* 235a) 149
- Marfan's syndrome, (*Figs.* 78a, 80) 52, 53
- maternal rubella, causing congenital cataract of lens, 51
- measles, causing acute dacryo-adenitis, 25
- megalocornea, (*Fig.* 52) 39
 - associated with megalophthalmos, 39
- meibomian glands of eyelid, 12
 - infection of, (*Fig.* 14) 16, 18
 - malignant tumors of, 18
- meiosis, of pupil, 67
- melanosis, of conjunctiva, (*Fig.* 49d) 38
- microcornea, 39
 - associated with microphthalmos, 39
- microphthalmos, (*Figs.* 37a, 38a) 29
 - of fetal lens, 51
 - causing narrowing of palpebral fissure, 12
- Mikulicz's syndrome, 24
- factors causing, 24-5
- miosis, of pupil, 66
- miotic drops, in treatment of open angle glaucoma, 72
- molluscum contagiosum, of eyelid, (*Fig.* 21) 19
- mongolism, congenital cataracts in, 51
- monocular diplopia, 53
- mumps, causing acute dacryo-adenitis, 25
- mustard gas keratitis, 47
- mycotic disease, of cornea, (*Fig.* 63e) 43-4
- mydriasis, of pupil, 66, 67
- mydriatics, in treatment of
 - congenital cataracts, 54, 58
 - uveal tract inflammation, 62
- myopia, 132-3
 - axial, progressive, (*Fig.* 143b) 92-3
 - and disease of the vitreous, (*Fig.* 120) 78
 - frequency of, (*Fig.* 206) 133
 - caused by keratoconus, 47
 - refraction in, (*Fig.* 205) 132
 - types of, 132-3

- naevi
 - of conjunctiva, (*Fig.* 51a) 38
 - of eyelid, (*Fig.* 20b) 19
- neurofibromatosis, *see* von Recklinghausen's disease
- neuroparalytic keratitis, (*Figs.* 58e, 66b) 46-7
- night vision, 80

- occupation, and ocular fitness, 153
- ocular fatigue, *see* asthopia
- ocular fitness, high standard of, 153
- ocular fundus, injury to, (*Figs.* 176, 179, 182a) 118-9
- ocular injury, high risk of, 153
- ocular motor nuclei, (*Figs.* 218, 220) 139-140
- ocular pemphigoid, *see* Stevens-Johnson syndrome
- oedema, of eyelid, (*Figs.* 17c d) 19
 - treatment of, 19
- opacification
 - in distinguishing between cataracts, 54
 - progression of, 54-5
- ophthalmia, gonococcal, of the newborn, 33
 - treatment of, 33
- ophthalmia neonatorum, 52
- ophthalmoscopy, in retinal examination, 81
- optic disc, 99
 - see also* optic nerve
- optic nerve, (*Fig.* 151) 99
 - atrophy of, (*Figs.* 153 d, 154 d) 103
 - developmental abnormalities of, (*Fig.* 151, 152) 100
 - diseases of, (*Figs.* 153, 154, 155a) 100-2
 - tumors of, (*Fig.* 155b) 103
- optic pathways
 - anatomy of, (*Figs.* 156, 157) 104
 - disturbances of, (*Fig.* 156, 158, 159) 104-6
- orbicularis oculi muscle, 11
- orbit
 - anatomy of, (*Figs.* 160-6) 106-9
 - developmental abnormalities of, (*Figs.* 172c d) 113
 - disturbances in globe position in relation to, (*Figs.* 167b, 170) 109-110
 - inflammatory disorders of, 110
 - injuries to, (*Figs.* 174, 175) 114-5
 - fractures causing, (*Fig.* 176) 115
 - tumors of, (*Figs.* 170-3) 111-3
 - orbital cysts, (*Fig.* 38b) 29
- palpebral fissure
 - narrowing of, 12
 - widening of, 12
- panophthalmitis, 43
- papilloedema, (*Figs.* 153bc, 154c) 102-3
- parasympatholytics, action on pupil, 67
- partial sight, 154
- pendular nystagmus, caused by dense lens opacities, (*Fig.* 75a) 51
- penicillin, in treatment of gonococcal ophthalmia, 33
- periphlebitis, retinal, (*Figs.* 139bc, 142b) 90-1
- phenol, solution of, in treatment of herpes simplex keratitis, 44
- phlyctenular keratoconjunctivitis, (*Figs.* 47b, 67a) 35-6, 46

- phlyctenular keratoconjunctivitis, continued
 scrofulous facial eczema, as a feature of, (*Fig.* 48)
 35-6
 treatment of, 36
 phthisis bulbi, 62
 pigmentation
 in choroidoretinitis, 89
 of conjunctiva, 37-8; in Addison's disease, 37;
 caused by eyedrops, (*Fig.* 49c) 37; caused by
 naevi tumours, (*Fig.* 49d) 38
 of cornea, 47
 degeneration of in retina, 92
 of fundus, (*Fig.* 126) 81
 of retina, (*Fig.* 121) 79; caused by congenital ca-
 taracts, 51
 in retinitis, 89
 in sclera, 50
 Pilocarpine, in treatment of acute angle closure glau-
 coma, 74
 pingueculae, (*Fig.* 49b) 36-7
 Placido's disc, for determining corneal curvature, 39
 plastic surgery, in treatment of
 cicatricial entropion, 15
 lagophthalmos, 14
 malignant melanomas, 20
 posterior uveal tract, *see* individual components
 presbyopia, (*Fig.* 214c) 133
 provocative tests, for acute angle closure glaucoma,
 73
 pseudo-isochromatic plates, for diagnosing colour
 blindness, (*Fig.* 200) 130
 pseudoxanthoma elasticum, 93
 pterygium, 37
 ptosis, 12
 causes of, 13
 congenital, (*Fig.* 6, 7) 13; treatment of, (*Fig.* 7) 14
 as a feature of 3rd nerve disfunction, (*Fig.* 5) 13
 pseudo-, 14
 pupil
 disorders of, 66
 drug action on, 67
 muscles controlling, (*Fig.* 98) 65
 nerve supply to, (*Fig.* 99) 65
 reflex pathways of, (*Fig.* 99) 65
 quadratic visual field effect, (*Fig.* 141b) 84
 radiation, infrared, causing cataracts, (*Fig.* 83a) 56
 radiotherapy
 causing radiation cataracts, (*Fig.* 83b) 56
 in treatment of malignant tumors of conjunctiva,
 38
 radium, causing radiation cataracts, 56
 recurrent corneal erosions, 46
 refraction, 135-6
 refractive power, of lens, (*Figs.* 201, 202, 203) 130-1
 measurement of, (*Fig.* 212) 135-6
 retention cysts, *see* dacryops
 reticulosis, causing Mikulicz's syndrome, 24
 retina
 adaptation to darkness, (*Fig.* 194) 126
 blood diseases involving, (*Figs.* 134c, 137a) 89
 blood supply to, (*Figs.* 124-5) 80-1
 circulatory disturbances of: benign hypertensive
 retinopathy, (*Figs.* 132d, 133, 134b) 86; dia-
 betic angiopathy, (*Figs.* 135bc, 136b, 137b)
 88-9; occlusion of central retinal artery, (*Fig.*
 132a) 84; retrolental fibroplasia, (*Fig.* 135a)
 88; thrombosis of central retinal vein, (*Fig.*
 132b) 84
 damage to, (*Figs.* 129, 141, 145, 146, 176, 182)
 93-5, 118-9
 degenerative disorders of, 91-3; *see also* maculo-
 pathies
 detachment of due to scleritis, 50
 embryological development of, 81
 examination of, 81
 inflammatory disorders of: retinitis, 89-91; *see*
 also named disorders
 layers of, (*Fig.* 121) 79-80
 neural connections to, (*Figs.* 121-3) 79-80
 tumors of, (*Figs.* 147-9, 150) 96-9
 retinal vein thrombosis, and vitreous haemorrhages,
 78
 retinitis, (*Figs.* 138-140) 89-91
 retinitis pigmentosa, (*Figs.* 141c d, 143a) 91-2
 retinoblastoma, (*Figs.* 147a, 148a b) 96-7
 retinopathies
 benign hypertensive, (*Figs.* 132d, 133, 134b) 86
 diabetic, in association with vitreous haemorrh-
 ages, 78
 malignant hypertensive, (*Fig.* 132ef) 86
 in pregnancy toxæmia, (*Fig.* 134a) 86
 retrolental fibroplasia, 88
 and vitreous haemorrhages, 78
 rods, of retina, 79-80
 Rose Bengal
 in diagnosing filamentary keratitis, 47
 in identifying areas of punctate erosion, 16
 rheumatoid arthritis, and scleritis, 49
 rosacea keratitis, (*Figs.* 58b, 67b) 41, 46
 Rubella syndrome, feature of congenital glaucoma,
 77
 sarcoidosis, causing Mikulicz's syndrome, 25
 Schirmer test, for measuring tear secretion, 23

- sclera
- changes in old age of, 49
 - episcleritis of, (*Fig.* 71a) 49
 - intra-ocular tumors and, (*Fig.* 72) 56
 - melanosis of, (*Fig.* 71c) 50
 - scleritis of, (*Figs.* 58i, 64b, 71b) 49
 - van der Hoeve's syndrome of, 50
 - scleral patch grafts, in treatment of scleromalacia perforans, 50
 - scleromalacia perforans, 50
 - sclerosing keratitis, and scleritis, (*Figs.* 58i, 64b) 49-50
 - scrofulous facial eczema, as a feature of phlyctenular conjunctivitis, (*Fig.* 48) 35-6
 - shingles, *see* herpes zoster ophthalmicus
 - Schiötz tonometer, (*Fig.* 106a) 69
 - sensory epithelial cells, of retina, 79-80
 - short-sightedness, *see* myopia
 - sickle cell trait, and vitreous haemorrhages, 78
 - siderosis, of iris, (*Fig.* 188) 120
 - Sjögren's syndrome, 24
 - factors causing, 24
 - and filamentary keratitis, 47
 - skin grafting, in treatment of ectropion, 15
 - spring catarrh, *see* vernal conjunctivitis, 35
 - squint, *see* strabismus
 - Stähli's line, 47
 - Stellwag's sign, 111
 - steroids, in treatment of
 - herpes simplex keratitis, 44
 - herpes zoster ophthalmicus keratitis, 45
 - interstitial keratitis due to congenital syphilis, 46
 - rosacea keratitis, 46
 - scleromalacia perforans, 50
 - vernal conjunctivitis, 35
 - Stevens-Johnson syndrome, (*Fig.* 49a) 36
 - strabismus
 - concomitant, (*Figs.* 226-9) 146-152; aetiology of, (*Fig.* 227a) 148; examination of, (*Figs.* 231-5) 148-151; treatment of, (*Figs.* 237-9, 240, 241) 151-2
 - incomitant (paralytic), (*Figs.* 222, 223) 141-5
 - Sturge-Weber syndrome, feature of congenital glaucoma, (*Fig.* 115b) 77, 99
 - stye, *see* hordeolum
 - superior medial fatty herniation of eyelid, (*Fig.* 2) 11
 - surgery
 - causing rise in intra-ocular pressure, 77
 - dacryocystorhinostomy, of lacrimal sac, (*Fig.* 32) 26
 - of diseased cornea, *see* keratoplasty
 - of nasolacrimal drainage apparatus, 24
 - for removal of: conjunctival pterygium, (*Fig.* 50ef) 37; dermolipomas, 38
 - in treatment of: cataracts in adults, (*Figs.* 85-7) 57-9; congenital cataracts, (*Fig.* 85c) 52; eyelid injury, (*Figs.* 175d, 177) 116; glaucoma not responding to therapy, 75-6; trachoma, 34
 - vitreous, 89
 - swimming pool conjunctivitis, (*Fig.* 45d) 35
 - sympatholytics, action on pupil, 67
 - sympathomimetics, action on pupil, 67
 - synchysis scintillans, 78
 - systemic antibiotics, in treatment of
 - acute dacryocystitis, 26
 - hordeolum, 16
 - tapetoretinal degeneration, *see* retinitis pigmentosa
 - tarsal muscle of Müller, 13
 - tarsorrhaphy, in treatment of
 - exophthalmos, 111
 - lagophthalmos, 14, 47
 - neuroparalytic keratitis, 47
 - tears
 - artificial, to prevent corneal drying, 25, 47
 - bactericidal action of, 22
 - bloody, 27
 - control of secretion, 22, 23, 25
 - deficiency of formation, 25
 - drainage of, (*Fig.* 27) 22
 - factors influencing production of, 24
 - infection of pools, 26
 - Schirmer test for measuring secretion, 23
 - stasis of, 27
 - Tenon's capsule, 27
 - Tetracycline, in treatment of
 - rosacea keratitis, 46
 - trachoma, 34
 - thyrotoxicosis, causing widening of palpebral fissure, 12
 - see also* exophthalmos
 - tonic pupil, (*Fig.* 100) 66
 - tonography, for measuring aqueous outflow dynamics, (*Figs.* 107, 108) 70
 - tonometry, for measuring intra-ocular pressure, 68-70
 - topical antibiotics, in treatment of
 - corneal bacterial ulcers, 43
 - xerosis of conjunctiva, 37
 - topical mydriatics, in treatment of herpes zoster ophthalmicus keratitis, 45
 - toxoplasmosis, ocular, congenital, (*Fig.* 142c) 90
 - trabeculotomy, for glaucoma, (*Fig.* 118c) 76
 - trabeculectomy, for glaucoma, (*Fig.* 118de) 75-6
 - trachoma
 - aetiology of, (*Fig.* 46) 34
 - stages of, (*Figs.* 45a,b, 58c) 33
 - treatment of, 34
 - trans-scleral illumination, in retinal examination, (*Fig.* 129) 83

- trauma
 lens displacement following, 53
 zonular cataracts following, (*Figs.* 75 c, 76 a) 52
see also injuries to named ocular components
- trichiasis, 14
- TRIC organism, causing inclusion blennorrhoea, 34-5
- tuberous sclerosis, *see* Bourneville's disease
- tumors
 of eyeball, 29-30
 of eyelid: benign, (*Fig.* 20) 19; malignant, (*Fig.* 21 f) 19-20; neurofibromatosis, (*Fig.* 20 g h) 19
 of lacrimal gland: benign, 26; malignant, 25-6
 of orbit, (*Figs.* 170-3) 111-3
 of retina, (*Figs.* 147-9, 150) 96-9
- tunica fibrosa, 27
- tunica nervosa, 28
- tunica vasculosa, 27
- ultrasonics, in cataract surgery, 58
- Usher's syndrome, 92
- uveal tract
 circulatory system of, (*Fig.* 89) 60
 developmental abnormalities of: albinism, 63;
 congenital colobomas of iris, (*Figs.* 93 d, 96 a) 63
 inflammation of, (*Figs.* 91-3) 60-3
 tumors of: benign naevi, (*Fig.* 93 b, 97 b) 63; malignant melanomas, (*Figs.* 93 c, 94, 97 a) 63; secondary, 63
see also named individual components
- vaccinal blepharitis, (*Fig.* 19) 19
 treatment of, 19
- van der Hoeve's syndrome, 50
- varices, of eyelid, 19
- vernal conjunctivitis, 35
- viral infections
 of conjunctiva, 31
 of cornea, 44-5; epidemic keratoconjunctivitis, (*Fig.* 63 d) 45; herpes simplex keratitis, (*Figs.* 58 g h, 64 a) 44; herpes zoster ophthalmicus keratitis, 44-5
 epidemic keratoconjunctivitis, 33
 of eyelid: herpes simplex, (*Fig.* 18) 19; herpes zoster ophthalmicus, (*Fig.* 18) 18-19; molluscum contagiosum, (*Fig.* 21) 19; oedema, 19; vaccinal blepharitis, (*Fig.* 19) 19
 inclusion blennorrhoea, 34-5
 of lens: congenital cataracts, 51
 trachoma, 33-4
 visual acuity, examination of, (*Figs.* 191-3) 125-130
 visual discrimination, 80
 visual fields
 defects of, 128
 measurement of, (*Figs.* 195-9) 126-7
 visual impairment, 154
 vitamin A, deficiency of, causing xerosis of the conjunctiva, 37
 vitreous, 78-9
 abscesses of, 78
 diseases of, 78-9
 haemorrhages of, (*Fig.* 179 f) 78, 119
 injury to, (*Fig.* 179 f) 119
 vitreous floaters, 78
 von Hippel-Lindau's disease, (*Fig.* 150 b) 99
 von Recklinghausen's disease, (*Fig.* 147 b)
see also eyelid. tumors of, neurofibromatosis
- warts, tumor of eyelid, (*Fig.* 20 a) 19
- Wilson's disease, 48
- Worth test, (*Fig.* 234) 150
- xanthelasmas, of eyelid, (*Fig.* 20 f) 19-20
- xerosis, of the conjunctiva, 37
- X-rays
 causing radiation cataracts, (*Fig.* 83 b) 56
 in examination of: injury to orbit, 114; perforating injury, (*Fig.* 185) 120