

# Skeletal anomalies in reared European fish larvae and juveniles. Part 2: main typologies, occurrences and causative factors

Clara Boglione<sup>1</sup>, Enric Gisbert<sup>2</sup>, Paulo Gavaia<sup>3</sup>, Paul E. Witten<sup>4</sup>, Mori Moren<sup>5</sup>, Stéphanie Fontagné<sup>6</sup> and Giorgos Koumoundouros<sup>7</sup>

1 Biology Department, Laboratory of Experimental Ecology and Aquaculture, University of Rome Tor Vergata, Rome, Italy

2 IRTA-SCR, Sant Carles de la Rapita, Spain

3 CCMAR, University of Algarve, Faro, Portugal

4 Department of Biology, Ghent University, Ghent, Belgium

5 NIFES, Bergen, Norway

6 INRA, Saint Pée-sur-Nivelle, France

7 Biology Department, University of Crete, Heraklio, Crete, Greece

## Correspondence

Clara Boglione, Biology Department, Laboratory of Experimental Ecology and Aquaculture, University of Rome Tor Vergata, Via della Ricerca Scientifica s.n.c., 00133 Rome, Italy. Email: [boglione@uniroma2.it](mailto:boglione@uniroma2.it)

Received 1 June 2012; accepted 7 October 2012.

Re-use of this article is permitted in accordance with the Terms and Conditions set out at [http://wileyonlinelibrary.com/onlineopen#OnlineOpen\\_Terms](http://wileyonlinelibrary.com/onlineopen#OnlineOpen_Terms)

## Abstract

The presence of skeletal anomalies in farmed teleost fish is currently a major problem in aquaculture, entailing economical, biological and ethical issues. The common occurrence of skeletal abnormalities in farmed fish and the absence of effective solutions for avoiding their onset or definitely culling out the affected individuals as early as possible from the productive cycle, highlight the need to improve our knowledge on the basic processes regulating fish skeletogenesis and skeletal tissues differentiation, modelling and remodelling. Severe skeletal anomalies may actually occur throughout the entire life cycle of fish, but their development often begins with slight aberrations of the internal elements. Comprehensive investigation efforts conducted on reared larvae and juveniles could provide a great contribution in filling the gap in knowledge, as skeletogenesis and skeletal tissue differentiation occur during these early life stages. The aim of this review is to provide a synthetic but comprehensive picture of the actual knowledge on the ontogeny, typologies and occurrence of skeletal anomalies, and on the proposed causative factors for their onset in larvae and juveniles of European farmed fish. The state-of-art of knowledge of these issues is analysed critically intending to individualize the main gaps of knowledge that require to be filled, in order to optimize the morphological quality of farmed juveniles.

**Key words:** causative factor, environmental condition, genetics, juveniles, nutrition, rearing methodology, skeletal anomalies.

## Introduction

In aquaculture, the incidence of skeletal anomalies is highly variable, in different species and under different rearing conditions. The percentage of fish with medium to severe anomalies varies greatly, not only among the different farms, but also among different lots within the same hatchery or even within the same batch of eggs. Existing data about the incidence of anomalies are collected using different diagnostic tools (Fig. 1; external observations, X-rays, palpation, whole mount staining, synchrotron microcomputer tomography, computer

tomography, histology, histopathology, histochemistry, immunohistochemistry) that provide different levels of accuracy (varying according to the life stage considered). For example, palpation of different groups of Atlantic salmon underyearling smolts evidenced 2–27% of smolts with vertebral anomalies, against the 27–94% identified by radiology (Grini *et al.* 2011). Presently very few farms and/or only a fraction of the reared lots can claim routinely to produce 100% of non-deformed fish. The real economic losses are difficult to estimate, due to the reluctance of farmers to provide data that could compromise the farm's reputation: the minimum annual loss

estimated for European aquaculture is more than € 50 000 000 per year and it is supposed that a 50% reduction of skeletal anomalies could save € 25 000 000 per year, would increase production and profitability, and could improve the image of aquaculture (Hough 2009). The systematic monitoring of skeletal anomalies is missing for many reared species and for many farms.

There is a lack of standardized classification in the literature for the different skeletal anomalies in reared fish, and many typologies are still identified on subjective and not objective criteria. Furthermore, different terminologies are used without a detailed description of the bones affected, different terms refer to similar anomalies, and similar terms are used to describe unrelated anomalies. The reason for these discrepancies could be identified in the many gaps of knowledge regarding the aetiology and developmental relationship of different anomaly types (Witten *et al.* 2009). However, some effort in this direction has been made recently: an ordering system of vertebrae anomalies in farmed subadult and adult salmon has been proposed by Witten *et al.* (2009) and a more general listing (and description) of anomalies in some European reared fish was attempted by the FineFish EU Project (available at: <http://www.finefish.info/default.asp?CAT2=0&CAT1=0&CAT0=0&SHORTCUT=633>).

In the literature, anomalies in the shape of skeletal elements are often defined by different terms, e.g. deformation, malformation, anomaly. Based on the terminology for human pathology, all these and other terms clearly address peculiar developmental disorders: i.e. abnormality and anomaly could be considered as synonyms, indicating a difference or deviation from the average or norm (The

American Heritage<sup>®</sup> Medical Dictionary Copyright © 2007); deformation is an alteration in shape and/or in structure of previously normally formed part (The American Heritage<sup>®</sup> Medical Dictionary Copyright © 2007); disruption is a morphological defect resulting from the extrinsic breakdown of, or interference with, a developmental process: it depends on time not on agent (Dorland's Medical Dictionary for Health Consumers © 2007); dysplasia is an abnormality of development; in pathology, it is used to indicate an alteration in size, shape and organization of adult cells (Dorland's Medical Dictionary for Health Consumers © 2007); malformation is a morphological defect of an organ or larger region of the body, resulting from an intrinsically abnormal developmental process (Dorland's Medical Dictionary for Health Consumers © 2007); basically, it is a primary structural defect resulting from a localized error of morphogenesis; congenital malformation is a structural defect present at birth; syndrome is a set of symptoms occurring together in a recognized pattern of malformations with a given aetiology; teratology is a congenital malformation and developmental abnormality (Mosby's Medical Dictionary, 8th edition © 2009, Elsevier) and it is connected to the toxic effects of teratogens in the environment inducing or increasing the frequency of structural disorders in the progeny (Wilson 1959). It would clearly be better to use each of these terms according to their own meaning but the actual knowledge on the development or aetiology of the different skeletal disorders observed in fish, still makes it difficult. However, in this review, an effort to use this terminology was attempted, when practicable. Otherwise, the more generic terms 'anomaly' or 'abnormality' were used preferably.



**Figure 1** Some of the whole mounting methodologies more commonly used to check for skeletal anomalies in fish larvae and juveniles. (a) *In vivo* fluorescent calcium-binding dye (calcein): fluorescence analysis of calcein bound to calcium phosphate (hydroxyapatite) allows direct quantification of extracellular matrix mineral content. Strength: yellow-green fluorescence upon binding to calcium; live staining; highly sensitive; stained live larvae can be followed for several days, until squamation occurs; <2 h for observation; total bound calcein could be quantified by direct fluorescence analysis. Weakness: it only permits the identification of calcified structures; larger fish or those with scales do not allow clear visualization of internal structures (Photo by P. Gavaia). (b) Whole-mount specific staining for bone (Alizarin red) and cartilage (Alcian blue). Strength: it dyes both bone and cartilage; it allows easy observation of each skeletal element since hatching (higher resolution than X-rays). Weakness: no information is achievable on the different bone types and it is not entirely specific: Alizarin red is not a specific dye for hydroxyapatite, the main mineral phase of bone (Zerekh 1993) and its staining of areas of calcium salt deposition (Humason 1962; Pearse 1985) may indicate the deposition of calcium salts in non-ossifying embryonic connective tissue (Faustino & Power 1998). Alcian blue dye is more aspecific: it stains acid mucopolysaccharides and glycosaminoglycans, which are present also in tissues other than cartilage. Furthermore, its use entails the use of acetic acid, which can demineralize lightly ossified elements that lose Alizarin red affinity (Photo by S. Fontagné). (c) Radiographic analysis. Strength: it can be used also in live fish. Weakness: low resolution for larval stages as it can only be performed at stages when enough calcified tissue is present; it permits observation only on one side of the body (no evaluation of asymmetry); low resolution of pectoral and pelvic fins and of rays. (Photo Boglione/University TV).

## Early developmental anomalies

This section considers the anomalies of 'skeleton' detectable at the very early ontogenetic stages (newly hatched larva or stages in which skeletal tissues are still poorly or not yet differentiated), which can develop into sub-lethal skeletal anomalies in the subsequent life stages. The aim is to identify and describe what precocious signals of anomalous skeletal development are available in the literature for the early evaluation of larvae quality. It should be considered that a high larval growth rate, in itself, is not always considered to be a good indicator of the final quality of young fish: lots of red porgy (*Pagrus pagrus*) juveniles, from the same egg batch and with similar larval growth rates, showed significant differences in the number of deformed fish (e.g. 46.5% vs. 16.3%) (Roo *et al.* 2009). In addition, even if some vertebrae fusion and related anomalies can also develop late in life (i.e. after smoltification in salmon; Witten *et al.* 2005), many skeletal anomalies have their onset during chondrogenic and osteogenic differentiation at early larval stages.

The most early developmental defects include anomalies of the blastomeres (Avery *et al.* 2009; Hansen & Puvanendran 2010), yolk-sac (Divanach 1985; Kentouri 1985), swim bladder (Kitajima *et al.* 1981; Johnson & Katavic 1984; Battaglene *et al.* 1994; Trotter *et al.* 2004), notochord and primordial finfold (Barahona-Fernandes 1982; Divanach 1985; Kentouri 1985; Andrades *et al.* 1996; Koumoundouros *et al.* 1997a, 2001; Fitzsimmons & Perutz 2006), as well as hydropsy (Koumoundouros *et al.* 2004) and yolk-sac or pericardial oedema (Carls *et al.* 1999).

As far as *embryo anomalies* are concerned, most available information deals with pollution effects on natural populations. The most commonly observed anomalies were those affecting cranial structures and/or yolk sac ones, notochordal shortening and curvatures (lordosis, scoliosis C-shaped body) and cardiac anomalies. For detailed reviews on the effects of heavy metals, organophosphorus pesticide, dithiocarbamates (DCs, pesticides), fipronil (a phenylpyrazole insecticide used in or near aquatic environments, i.e. rice fields), disulfiram and radiation on fish embryonic development see Van Leeuwen *et al.* (1986), Middaugh *et al.* (1990), Stehr *et al.* (2006), Jezierska *et al.* (2009).

To our knowledge, the presence of urinary calculi is probably the only non-skeletal defect in reared larvae and juveniles that has been considered as potentially lethal and not related to the development of other skeletal anomalies.


Most of the marine reared fish are physoclistous as adults but physostomous at larval stages (i.e. gilthead seabream *Sparus aurata*, European seabass *Dicentrarchus labrax*, sharpsnout seabream *Diplodus puntazzo*), and the non-inflation of the swim bladder (Fig. 2o) was the most common early developmental failure observed at the beginning of European aquaculture. At present, losses as a result of

swim bladder anomalies are typically in the order of 5–10% of all fingerlings produced, but can reach as much as 50% in some cases (Woolley & Qin 2010). In species where rearing technologies are poorly developed, the incidence of swim bladder non-inflation is as high as 70–100% (Trotter *et al.* 2004). It is mainly induced by the inability of the larvae to access the air–water interfaces in order to activate swim bladder by gulping air (Kitajima *et al.* 1981; Chatain 1986; Battaglene *et al.* 1994; Trotter *et al.* 2004). Larvae and juveniles without a correctly inflated swim bladder have to actively swim with larval pectoral fins to maintain the required level in the water column; the derived overuse of pectoral fins flapping increases the activity of pre-haemal muscles, in the first stage. This hyper activity of pre-haemal muscles could cause a mechanical overload exerted on differentiating pectoral elements, with consequent anomalies occurring in this fin, as observed in reared gilthead seabream lacking a normally inflated swim bladder but not in siblings with swim bladder. This release of a more intense mechanical load on ossifying pre-haemal vertebrae may cause gradual bending of the notochord/vertebral axis (Kranenbarg *et al.* 2006), with consequent deformation and fusion of involved pre-haemal vertebrae (Kitajima 1978; Chatain 1994; Bogliione *et al.* 1995) at first, then extending to the haemal vertebrae (Clara Bogliione, unpubl. data, 2012). Also the loss of the mechanical support furnished by a normally inflated swim bladder to the developing vertebral axis, in combination with the overuse of pectoral larval fins, could induce axis anomalies.

The swim bladder can also abnormally over-inflate (Johnson & Katavic 1984; Katavic 1986). Larvae with over-inflated swim bladder remain trapped in the superficial layers, often against the tank wall, and die of starvation. In Atlantic cod (*Gadus morhua*) larvae, swim bladder over-inflation was shown to induce notochord abnormalities, which later evolved into anterior vertebrae anomalies (Grotmol *et al.* 2005), described below.

Interaction between the notochord and spinal cord influences vertebral differentiation: excision of the spinal ganglia induces the presence of an uninterrupted unique neural arch on normally shaped vertebral centra, the opposite occurs when the notochord is excised (Hall 2005). Vertebral fusions and changes in the number of vertebrae were attributed to defects of notochord segmentation and disruption of vertebral centrum differentiation (Haga *et al.* 2009), a condition that can be promoted by vitamin A-induced accelerated skeletogenesis (Mazurais *et al.* 2008).

Notochord anomalies are quite frequently observed in newly hatched larvae, but the most severe are commonly lethal: Koumoundouros *et al.* (2001) reported a low rate of notochord deviations (<1%) in newly hatched common dentex (*Dentex dentex*), but none in embryos and in first feeding larvae.

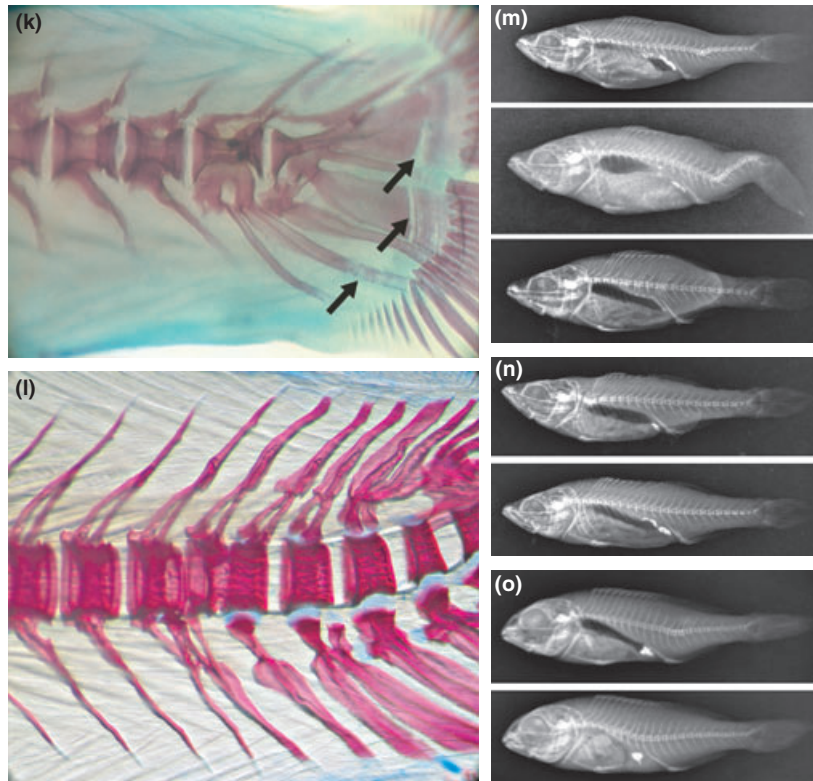


**Figure 2** Examples of some skeletal anomalies detected in reared European larvae and juveniles. (a) Atlantic bluefin tuna (*Thunnus thynnus*) juvenile (SL: 27 mm) showing a severe pre-haemal kyphosis (arrow) (Photo by Marroncini/University TV). (b) White seabream (*Diplodus sargus*) juveniles (SL: 77 and 82 mm). The fish at the top has a normal skeleton, the other shows a severe lordosis spanning on posterior pre-haemal and anterior haemal vertebrae (arrow) (Photo by P. Gavaia). (c) White seabream (*Diplodus sargus*) juvenile (SL: 73 mm) showing a saddle-back located between the anterior and posterior portions of the dorsal fin (Photo by P. Gavaia). (d) Senegalese sole (*Solea senegalensis*) juveniles (90 dph) with ectopic formation of a fin connecting anal and dorsal fins (arrowhead), and neural and haemal arches anomalies (arrows; Photo by P. Gavaia). (e) Senegalese sole (*Solea senegalensis*) juveniles (90 dph) with severe kypho-lordo-kyphosis in haemal and caudal vertebrae. Note rays and neural and haemal arches anomalies (Photo by P. Gavaia). (f) Meagre (*Argyrosomus regius*) larva (35 dph) with partly fused and deformed vertebral bodies and arches (arrow; Photo by P. Gavaia). (g) European seabass (*Dicentrarchus labrax*) postlarva (50 dph) with a supernumerary ectopic pelvic fin (Photo Boglione/University TV). (h) European seabass (*Dicentrarchus labrax*) juveniles showing different cephalic, caudal fin and axis anomalies. The fish on the bottom is normal (Photo by E. Gisbert). (i) Thicklip grey mullet (*Chelon labrosus*) early juvenile (SL 8.4 mm) showing different vertebral and axis anomalies (Photo Boglione/University TV). (j) Gilthead seabream (*Sparus aurata*) with anomalous opercular plates, at market (Photo by Boglione/University TV). (k) Dusky grouper (*Epinephelus marginatus*) larva (50 dph) with deformed body, neural and haemal arches of caudal vertebra. Note the ossification defects in the hypuralia and last haemal spine (arrows; Photo Boglione/University TV). (l) Rainbow trout (*Oncorhynchus mykiss*) fry (20 days after first-feeding) with fused and deformed haemal vertebral bodies and fused spines of caudal vertebra (Photo by S. Fontagné). (m) European sea bass (*Dicentrarchus labrax*) juveniles (85 dph) with haemal lordosis (top); with haemal lordosis and caudal kyphosis (central); with fused pre-haemal and haemal vertebrae (bottom; Photo by G. Koumoundouros). (n) European sea bass (*Dicentrarchus labrax*) juvenile (80 dph) with fusions and lordosis of anteriormost pre-haemal vertebrae (top); without spines of the dorsal fin (bottom; Photo by G. Koumoundouros). (o) Gilthead seabream (*Sparus aurata*) juvenile (75 dph) with haemal lordosis (top) and with pre-haemal lordosis and non-inflated swim bladder (Photo by G. Koumoundouros).

Koumoundouros *et al.* (1997a) found that about 65% of gilthead seabream larvae (total length (TL) 3.4–3.9 mm) were affected by slight upward distortion of the posterior tip of the notochord (not affecting larval swimming behaviour), which persisted also after the flexion stage. The postflexion larvae (TL > 9.5 mm) exhibited two different caudal anomalies: laterally twisted tail (concurrent with Z-like body shape when swimming) or additional hypoplastic caudal fin. In a further study, no association among notochordal deviations in larvae and kyphosis in postlarvae was found in European seabass (Koumoundouros *et al.* 2002).

Santamaria *et al.* (1994) observed the presence of lordotic gilthead seabream larvae at 18 days post hatching (hereafter named dph) that is before the vertebrae differentiate. Their notochord presented a variable diameter, disorganized muscle bundles that appeared arranged in different planes, and an irregular perinotochordal sheet with much infolding. Further, lower collagen–proteoglycan interactions were found to occur in lordotic larvae, probably due to an impaired proteoglycan formation.

Andrades *et al.* (1996) reported that although 27% of newly hatched gilthead seabream larvae displayed more or



**Figure 2** (Continued)

less severe notochord deviations, only very few of them were lordosis. The deviated notochord showed connective tissue penetrating the notochord to form septa and surrounding the notochordal sheet. In 60 dph gilthead seabream, axis deviations (mainly lordosis) affected the 5% of surviving fish, thus evidencing that survival of lordotic larvae was higher than that of other deformed larvae.

Wargelius *et al.* (2005) subjected Atlantic salmon (*Salmo salar*) embryos (at gastrulation, at 1–6 somites and at 15–20 somites) to an abrupt increase of temperature (from 6 to 12°C in 24 h). The temperature shock induced malformed embryos (27–34%) with severe trunk defects: the 80% of the anomalous embryos displayed a bilateral trunk phenotype (curled tail, in which the trunk appeared curved on itself) and the 20% a short tail (where the trunk caudad to the dorsal fin was bent, very different from the ‘shorttail’ salmon anomaly, described below, where the entire body appears compressed and not bent, due to the presence of compressed and fused vertebrae).

In red porgy *Pagrus pagrus*, vertebral fusions can be early detected at the onset of vertebral ossification, which occurs at 20 dph (TL around 6.3 mm; Roo *et al.* 2009).

In general, anomalies of the primordial finfold are not considered to influence the formation of adult fin structures: zebrafish mutants lacking the embryonic finfold can develop regular fins (Van Eeden *et al.* 1996). Nonetheless,

notochord, primordial marginal finfold and caudal fin anomalies have been correlated in some species: in common dentex, Koumoundouros *et al.* (2001) described that saddleback and severe caudal fin anomalies were anatomically and ontogenetically related to each other, and originated at early larval stages as a result of abnormalities of the primordial marginal finfold and of the posterior tip of the notochord.

The dorsal and ventral portions of the embryonic finfold are respiratory surfaces in pelagic fish larvae and it has been ascertained that physical and physiological changes accompanying oedema (decreased blood flow to tissues, interference with nervous system function and increased energy expenditures), reduced the finfold surface area and retarded pectoral fin development (Von Westernhagen 1988).

Regarding the early detection of fin anomalies, Marino *et al.* (1993) described anomalies in the second dorsal, first dorsal and anal fins initially appearing in 10.7, 12.6 and 13.5 mm standard length (SL) European seabass larvae, respectively. Caudal fin anomalies were detected earlier, in 9.4 mm SL larvae.

In 24 dph Senegal sole (*Solea senegalensis*) larvae, Gavaia *et al.* (2002) observed fusions occurring between cartilaginous parhypural and hypural plates 1–2, and the cartilaginous extra hypural plate near the tip of urostyle, not yet ossified.

## Vertebral column anomalies

Vertebral anomalies have been documented in all the reared fish species, in the form of curvature, dislocation, shortening and twisting. In severe cases, anomalies of vertebrae centra and/or arches are associated with macroscopic deviations of the vertebral axis. These latter involve lordosis (V-shaped dorsal–ventral curvature), kyphosis (Λ-shaped dorsal–ventral curvature), scoliosis (lateral curvature). The angle formed by axis bending must be of a certain magnitude in order to identify the anomaly under gross external examination, but it has to be considered that many fish may present this problem to a lesser severe degree. Different authors use diverse modalities to assess the severity of axis deviations: e.g. some are used to measure the angle between the most involved vertebrae in the deviation, centred in the intervertebral space at the most curved point, while others consider axis anomalies only as the column deviations where the involved vertebrae present deformed or fused bodies, and other deviations as vertebrae displacement or misalignment. In this way, a common methodology for univocal and objective identification should be established, particularly for larval stages where *in toto* staining is necessary for observing skeletal elements: the diaphanization process by glycerol or excess of trypsin treatment (as suggested, i.e. by the Park & Kim 1984 protocol) may provoke some swelling that, if exacerbated, can disarticulate some differentiating vertebrae or can deviate the notochord, resulting in confusing artefacts.

However, any severe axis deviation should include fusion and deformation of the involved vertebrae.

Existing literature indicates that finfish species of European aquaculture could be divided into two different groups according to the type, severity and frequency of some vertebral anomalies. The first group includes gilthead seabream, European seabass, flatfish and most of the candidate new species, whereas the second group includes the reared salmonids. In the non-salmonid group, vertebral axis anomalies are quite frequent in the same lot or species, and concern almost all the recorded types to date. In salmonid species, vertebral axis deviations appear dramatically only after smoltification, being rarely observed in early juveniles, and they mainly concern the compression of the vertebral axis due to fused and compressed vertebral bodies. Furthermore, it must be considered that belonging to the same Family should not justify the transfer of knowledge from one species to the other, considering that the farming environment for one species to another can be very diverse.

### Non-salmonid group

Lordosis is the most well studied axis anomaly in Mediterranean marine species (Fig. 2b,e,m,o). It can affect every

region of the vertebral axis, but it is most commonly observed in either the pre-haemal or haemal part.

Pre-haemal lordosis has been correlated significantly to the non-inflation of the swim bladder in European seabass and gilthead seabream by Chatain (1994), but Boglione *et al.* (1995, 2009) and Andrades *et al.* (1996) did not confirm a similar correlation for European seabass and dusky grouper *Epinephelus marginatus*, and gilthead seabream, respectively. In fact, even if some juvenile lordotic gilthead seabream display an uninflated swim bladder, most of the lordotic adults possess an inflated swim bladder; additionally, larvae with a lordotic curvature of the notochord in the pre-haemal region are detectable before the period in which the swim bladder inflates in gilthead seabream (Andrades *et al.* 1996) or in grouper larvae with a normally inflated swim bladder (Boglione *et al.* 2009). Further, it should be considered that larvae with notochord lordosis may well have an impaired ability to reach the air–water interface to gulp the air bubble necessary for the swim bladder inflation at the appropriate time; if so, the non-inflation of the swim bladder would be a consequence rather than a cause of lordosis.

Haemal lordosis was first differentiated from pre-haemal lordosis by Boglione *et al.* (1995) and by Divanach *et al.* (1997), both reporting that European seabass juveniles with a normally inflated swim bladder can develop lordosis, but in the haemal vertebrae. At present, causes other than an uninflated swim bladder are considered to be involved in the onset of lordosis during development (Andrades *et al.* 1996; Kihara *et al.* 2002; Koumoundouros 2010), as discussed below.

Haemal lordosis is a quite frequent anomaly in European seabass (reaching up to 70% of reared juveniles) and in Atlantic cod (Baeverfjord *et al.* 2009; Fjellidal *et al.* 2009; Koumoundouros 2010), less frequent in fish with a less elongated body shape (e.g. 1–13% in gilthead seabream, Georgakopoulou *et al.* 2010).

Cranial (i.e. involving the anteriormost vertebrae) and caudal lordosis (involving the centra of the caudal peduncle) are quite rare anomalies in European seabass and gilthead seabream: in a recent study carried out on 874 gilthead seabream and 638 European seabass reared juveniles, subadults and commercial size fish from different intensive farms, Cataudella *et al.* (2011b) found no individuals with cranial lordosis, no gilthead seabream with haemal lordosis and no European seabass with caudal lordosis. In gilthead seabream, the highest occurrences (5.3%) of haemal lordosis were found in samples from the ongrowing phase and very few in the juveniles (1.2%) or in commercial size fish (0.4%). Caudal lordosis was observed only in 1 (0.1%) gilthead seabream juvenile. In European seabass, only one individual was observed with pre-haemal and haemal lordosis, respectively.

Haemal lordosis has been proposed also to be linked with inappropriate tank hydrodynamism and forced swimming (Chatain 1994; Andrades *et al.* 1996; Divanach *et al.* 1997) but lordotic fish have been found also in gentle water flow tanks, leaving open the door to a different hypothesis formulation. Izquierdo *et al.* (2010) related the development of axis anomalies to the typical feeding behaviour of red porgy: juveniles of this species are very voracious and haemal lordosis has been considered the consequence of coupling insufficient feeding (causing skeleton weakness) and excessive swimming activity for feeding.

Lordosis and other spinal anomalies are the most genetically analysed anomalies (as described below): genetic causes were also shown to be involved in their onset.

Lordosis in red porgy juveniles spans the pre-haemal (about 20% of all lordosis) and, mostly, the haemal region (about 80%; Izquierdo *et al.* 2010). In this species, an association with fused vertebrae and a reduced or excessive number of vertebrae was found in most of the lordotic specimens, as described also in red seabream (*Pagrus major*; Hattori *et al.* 2003; Matsuoka 2003). The most common skeletal anomalies observed in reared red porgy were lordosis (13%) and fused vertebrae (14%), and their localization along the column, but not the occurrence, a result affected by culture intensity: in intensively reared red porgy, a significantly higher incidence of kyphosis between the cephalic and pre-haemal region (semi-intensive: 3.9%; intensive: 8.8%) was detected, not in association with an over-inflated swim bladder. In addition, most of the lordotic specimens showed the presence of a reduced or an excessive number of vertebrae (Izquierdo *et al.* 2010).

In reared Atlantic cod, lordosis is the most commonly reported anomaly of the vertebral axis. Again, in this species it has been observed also in individuals with a normally inflated swim bladder. The identification of this anomaly is based on the measurement of the angle between the eight most involved vertebrae in the lordosis, centred in the intervertebral space at the point of maximum flexion (Baeverfjord *et al.* 2009). In Atlantic cod, lordosis can affect the entire spine, but mostly the cranial vertebrae ('stargazer' anomaly), as a consequence of a persistent increase in pressure exerted early on the notochord by an over-inflated swim bladder (Grotmol *et al.* 2005). 'Stargazer' has been a particular and frequently occurring vertebral anomaly in intensively reared cod (Grotmol *et al.* 2005; Hamre 2006), so named for the particular upward bending of the head: an increased angle between the palatine bone and the anteriormost vertebrae leads to a slight upward tilt of the head (so the fish seems to gaze at the stars), so creating an indented dorsal body contour at the transition between the head and the trunk. It is detectable early (7 dph) by microscope observation of the larvae as an increased dorsal curvature of the notochord above the

swim bladder, but the fish farmer can detect it externally only at the juvenile stage. In the least severe cases, the external diagnosis may be uncertain. Grotmol *et al.* (2005) described a critical time window for the appearance of this anomaly (18–36 dph), characterized early by a ventral groove-shaped longitudinal impression of the notochord sheath, occupied by the swim bladder in severely affected larvae, to form a hernia-like lesion in the notochord. During vertebrae differentiation, the centra adopt an abnormal wedge shape, ventrally concave, and neural arches are frequently S-shaped. This condition can be associated with severe vertebral anomalies in the cranialmost vertebrae, as well as with other axial deviations such as lordosis, kyphosis and scoliosis in the cranial part of the spine. However, this anomaly is more easily detectable in larger fish (50 g) than in yearling, in which shrinking artefacts due to the fixative solution can result in a similar picture; it is considered to worsen with growth.

Pre-haemal kyphosis (Fig. 2a,b,e) was first reported by Boglione *et al.* (1995) to co-occur with haemal lordosis in European seabass juveniles without a normally inflated swim bladder. As was shown later by Koumoundouros *et al.* (2002), pre-haemal kyphosis can also develop in European seabass larvae with an inflated swim bladder, and kyphosis can be combined significantly with abnormalities of the branchiostegal rays, in the examined European seabass lots. Kyphosis is, however, rarely observed in European seabass and gilthead seabream (Boglione, unpubl. data) and is considered less common than lordosis in Atlantic cod.

Scoliosis, the lateral bending of the vertebral axis, is the axis anomaly most easily identifiable in live fish, with the best detection being from the dorsal or ventral side of the whole fish: for this reason can be culled out easily during manual selection. The reported incidences are very low in gilthead seabream, European seabass and Atlantic cod. As radiographs are taken routinely in a lateral view, less severe scolioses can be misjudged because of the poor preservation of the specimen or because of *rigor mortis* in a non-flat position (consult Witten *et al.* 2009 for a critical review on the possibility of artefacts in X-rays).

Sometimes, in the most severe cases, various combinations of these three anomalies occur, as in the LSK syndrome (a consecutive repetition of lordosis–scoliosis–kyphosis, from the head to the caudal fin) described in gilthead seabream by Afonso *et al.* (2000, 2009).

Izquierdo *et al.* (2010) recently found that in red porgy juveniles fused vertebrae affected only RPP-rotifer (Red Pepper Paste<sup>®</sup>, RPP-Rot) fed larvae, whereas in DPS-rotifers (DHA Protein Selco<sup>®</sup>, DPS-Rot) principally lordosis and kyphosis, together with scoliosis, compressed vertebrae (and asymmetric fins, deformed rays) were found. It is concluded that in this species, the nutritional quality of live

prey during very early feeding is a determining factor in the appearance of scoliosis and compressed vertebrae.

Flatfish are regularly affected by two main types of abnormalities of the external phenotype: pigmentation disorders and osteological anomalies. The abnormalities in pigmentation comprise albinism and ambicoloration and can affect up to 61% of the reared fish (Estévez & Kanazawa 1995; Estévez *et al.* 1999; Villalta *et al.* 2005). It was observed that in the post-larval and juvenile stages of Senegalese sole, produced under intensive rearing conditions, the incidence of individuals affected by vertebral anomalies can reach levels ranging from 44% to 80% of the reared lots (Gavaia *et al.* 2002, 2009; Engrola *et al.* 2009; Fernández *et al.* 2011) while wild captured larvae display a low incidence of deformed fish.

In Atlantic halibut (*Hippoglossus hippoglossus*) juveniles, Lewis-McCrea and Lall (2010) found that the most commonly observed anomalies changed in fish fed different diets: regarding axis deviation, low phosphorus diets enhanced scoliosis in the cephalic and haemal regions of the vertebral column; in the group fed no ascorbic acid supplement, the most frequent anomalies were scoliosis and lordosis, primarily affecting the haemal vertebrae; high levels of vitamin A in the diet caused scoliosis, spanning the cephalic/pre-haemal and anterior haemal vertebrae; fish fed the oxidized oil diet mainly showed scoliosis, spanning the cephalic/pre-haemal/anterior haemal regions. The authors underlined that the pattern and type of abnormalities observed in fish fed these experimental diets were similar to those observed in a commercial halibut hatchery. At the beginning of the experimental alimentation ( $4.61 \pm 0.09$  g), no serious types of abnormalities, such as scoliosis and lordosis, were detected. However, the same authors described lordosis as commonly observed in the anterior haemal region in juveniles of Atlantic halibut. The occurrence of pre-haemal lordosis and scoliosis in Atlantic halibut were reported by Lewis *et al.* (2004) to be related to the presence of hypertrophic vertebrae.

### Salmonid group

Fjelldal *et al.* (2007) reported compression, fusion and dislocation as the most frequent types of spinal anomalies in Atlantic salmon, but we consider that these anomalies affect single vertebrae and not the axis conformation and for this reason they will be described in the vertebrae anomalies section below. Recently, Witten *et al.* (2009) proposed an ordering system of anomalies affecting the vertebral axis in Atlantic salmon divided into seven categories: spinal curvatures (three types: lordosis, kyphosis and scoliosis), symmetry deviations and displacement of vertebral bodies (three types: vertically shifted vertebrae, vertebral bodies with uneven internal structures and vertebrae centra shifted

dorsally or ventrally), and severe multiple anomalies (all associated in one typology: a series of various co-occurring anomalies that may be associated in some cases with bone fractures). The description of the different anomalies is based on X-rays, thus excluding very early juveniles, resulting in very rare spinal curvatures. It is evident that, at least in salmon, there is the tendency to consider both vertebral body and vertebral axis anomalies together, probably as a consequence of the gap in knowledge existing on what is the primary anomaly. In this review, a separation between axis and vertebrae anomalies is maintained, taking into consideration that not all compressed and/or fused vertebrae bodies evolve into spine curvatures, even in salmonid fish.

The 'curled tailed' and 'short tail' axis anomalies, observed in the embryo salmon by Wargelius *et al.* (2005) (see section on early anomalies) were never observed in the more than 5000 X-rays from 5 g to 14 kg salmon analysed by Witten *et al.* (2009), so making these anomalies special cases.

*Vertebrae misalignment* is not a 'curved' axis but a discrete displacement of a limited number of vertebrae that appears shifted dorsad or ventrad to the rest of the vertebral column. This type of anomaly has been only recently described and monitored in salmonid fish (anomaly 17 in Witten *et al.* 2009) and only sporadically and recently in European seabass and gilthead seabream: the main reason is that the level of vertebrae misalignment shows a continuum between imperceptible and gross shifts, and many least severe cases are not considered and thus monitored. Displacement of vertebral bodies has been mainly detected in underyearling smolts, fast growing and intensively reared salmon (Gil Martens 2012).

Among the main risk factors invoked for the onset of spinal anomalies, in contrast to those reported in non-salmonid species, temperature seems to be the most potent (Wargelius *et al.* 2010), together with smoltification timing (underyearlings instead of yearlings), vaccination and dietary phosphorus deficiency, even if the reproducibility of induction of these anomalies by these factors has not always succeeded in laboratory conditions (Gil Martens 2012).

Scoliosis in Atlantic salmon has been reported to be the result of alterations in the central nervous system, neuromuscular junctions or/and ionic metabolism induced by a number of different causes by Silverstone and Hamell (2002) or vitamin C deficiency by Gil Martens (2012).

### Vertebrae anomalies

In this section, actual knowledge on the different types of anomalies affecting vertebrae (centrum, neural and haemal arches) and other skeletal elements that articulate (e.g. ribs)



on vertebrae is presented (Fig. 2f,i,l,m,n). Vertebrae anomalies co-occurring in deviated vertebral axis are excluded here, being considered as a secondary anomaly or because they are discussed in the former section. Vertebrae anomalies, in fact, may be present regardless of the presence of axis deviation, and the onset of vertebrae fusion/deformation does not always lead to fish with a deformed vertebral column.

They include: (i) dislocation, fusion, shortening, deformation or lack of the centra (Hattori *et al.* 2004; Sawada *et al.* 2006); (ii) dislocation, compression, deformation, lack or extra formation of the haemal and neural arches and apophysis (Nguyen *et al.* 2008), and (iii) dislocation, shortening, deformation, lack or separation of the ribs (Komada 1980; Matsuoka 1987; Boglione *et al.* 1993, 1995). Compressed vertebrae with intervertebral spaces are classified as platyspondyly, and compressed vertebrae without intervertebral spaces are classified as vertebral ankylosis and platyspondyly (Fjellidal *et al.* 2007).

The most severe vertebrae anomalies are those affecting the vertebral body such as fusion, compression and modified shape because, if including many vertebrae, the fish length could be reduced, as in stunt-body or short-tail salmon. Conversely, anomalies altering vertebral arches and ribs are considered slight, as they do not affect the external shape of the fish. In point of fact, from a physiological view their presence is, however, a sign of altered osteogenic processes and, if a functional context is concerned, it should be considered that neural arches protect the spinal cord and furnish the insertion for dorsal musculature: thus, severe anomalies affecting many neural arches and spines could lower fish performance. Haemal arches, in turn, protect the *arteria* and *venae caudalis*, and severe and extended arch anomalies could interfere with blood flow in the organism: oxygen levels influence chondrogenesis (Hall 2005). Also ventral compression of the renal ducts was found to be induced by anomalous vertebrae development (Couch *et al.* 1979).

In all reared fish, incomplete and complete fusion of vertebral bodies are considered not necessarily as developmental stages of the same anomaly, as not always incomplete fusions aggregate in older fish (Deschamps *et al.* 2009). Fused vertebrae have been described as the result of transdifferentiation of notochordal (at the intervertebral spaces) and periosteal (at the growth zone) cells into chondroblastic cells, in compressed and fused vertebrae of Atlantic salmon, European seabass, Senegalese sole and gilt-head seabream, as a pathological response to a compressive mechanical environment (Beresford 1981; Hall 2005; Kraneberg *et al.* 2005; Witten *et al.* 2005, 2009; Roberto 2006; Fiaz *et al.* 2010; Cardeira *et al.* 2012).

According to Witten *et al.* (2009), fusions of vertebral bodies to the occipital region of the skull and to the

urostyle should not be considered as anomalies as they are common non-pathological phenomena in Osteichthyans.

Compressed and fused vertebrae are considered as true deformations, as it has been reported that vertebral bodies often develop normally up to a certain point (Nordvik *et al.* 2005; Fjellidal *et al.* 2007; Witten *et al.* 2009), then the tissue of the intervertebral space (notochord tissue) is replaced by cartilage and fibrocartilage and, concurrently, cells of the vertebral growth zone change their character from osteoblastic to chondroblastic (Gil Martens *et al.* 2005; Witten *et al.* 2005, 2006, 2009).

It has been shown that two ankylosed and compressed vertebrae can reshape into one single regularly structured and joint vertebra in salmon (Witten *et al.* 2006). Sufficient dietary mineral content for promoting proper mineralization may be a factor that favours containment and prevents aggravation of a vertebral anomaly, as well as the possibility that normal hyperostotic processes (age-dependent) can repair or mask these anomalies in older fish, under favourable environmental rearing conditions.

Recently, under- (or radio-translucent) and over-mineralized (or radio-opaque) vertebrae have also been considered to be anomalies, as they can evolve into anomalous vertebral bodies. Identification is carried out by X-ray, so their early detection in early juveniles or in larvae is not possible and for that reason is not treated in this review: undermineralization (osteopenia) of vertebrae is detectable through X-rays starting from 100 g salmon. Hyper dense vertebrae are observed early as axial deviations caused by one small vertebra, that later develops into a hyper dense vertebra. This condition can exacerbate (fusion) or normalize (normal vertebra) (Baevefjord *et al.* 2009).

### Non-salmonid group

Vertebral body fusion, compression, deformation and reduction in the absence of vertebral axis deviations are quite common in reared European seabass and gilt-head seabream juveniles. The main affected regions in these species are the haemal and caudal vertebrae, even if they have been observed all along the column. Vertebrae anomalies are quite rarely the object of investigations themselves, as their presence does not necessarily affect the external shape of the fish, and have been described rarely in detail in marine reared juveniles.

Fused vertebrae are the most frequent anomaly observed in reared red porgy, together with vertebrae shortening and lack of neural and haemal spines (Izquierdo *et al.* 2010). Porgies reared under different methodologies exhibit different localization of fusions but similar incidence: in intensive conditions fused vertebrae particularly affect the caudal peduncle, whereas in the semi-intensive system they are located mainly in the pre-haemal region. Fish fed a low

phosphorus diet showed twisted neural and haemal spines in the pre-haemal and haemal vertebrae (43.7% and 41.2%, respectively).

Anomalous neural and haemal arches have been observed in all vertebral regions and in all the species, even in early larvae. They affect a consistent number of European seabass and gilthead seabream larvae, juveniles, subadults and adults. They are more frequent in intensively, rather than in semi-intensively, reared gilthead seabream juveniles, mainly concentrated in the haemal vertebrae (Prestinicola 2012). All arches and rib anomalies tend to be augmented with size of fish both in European seabass and gilthead seabream (Cataudella *et al.* 2011b).

In Atlantic cod, a general state of irregular morphology affecting several successive vertebrae (a condition difficult to classify) are generically grouped under the term 'asymmetries'. The final evolution of these anomalous vertebrae may be fusion or platyspondyly, or they might normalize (Baeverfjord *et al.* 2009).

Lewis-McCrea and Lall (2010) described neural spines anomalies (e.g. bifurcated and supernumerary spines) in the cephalic and haemal vertebrae of juvenile Atlantic halibut ( $4.61 \pm 0.09$  g), whilst fused and compressed vertebrae were prominently localized in the cephalic/pre-haemal and anterior haemal region.

The Senegalese sole vertebral column is mostly affected by vertebrae fusion and anomalies, and abnormalities of the vertebral arches (Engrola *et al.* 2009; Fernández *et al.* 2009; Cardeira *et al.* 2012), with a special incidence on the preural vertebrae and caudal fin regions, in both reared and wild specimens (Gavaia *et al.* 2002, 2009; Engrola *et al.* 2009; Fernández *et al.* 2009; Fernández & Gisbert 2010). In Senegalese sole, vertebrae are commonly found malformed or fused, with the fusion of preural vertebral elements as one of the main anomalies found in the early stages of this species. Recently, Cardeira *et al.* (2012) described the microanatomical changes that occur at tissue and cellular levels in lordo-kyphotic Senegalese sole. In affected individuals, ectopic cartilage-like tissue within bone matrix was found at the growth regions (contact area between two vertebrae) of affected vertebrae. The authors hypothesized that the increase in strain supported by deformed vertebrae may trigger the onset of metaplastic tissue formation through an osteochondroprogenitor precursor from the condensation of mesenchymal cells or by trans-differentiation of (pre-)osteoblastic cells to a chondrocytic lineage. In addition, a change in the phenotypes observed from juveniles to adults suggests that the response to altered loads will vary according to fish size or to the mineralization state of the vertebrae.

In Atlantic halibut juveniles, Lewis-McCrea and Lall (2010) found that a low phosphorus diet enhanced anomalous

haemal and neural spines in the haemal region. Pre-haemal lordosis and scoliosis were reported in Atlantic halibut by Lewis-McCrea and Lall (2004) as a secondary anomaly, a consequence of hypertrophic vertebrae. According to these authors, hypertrophic vertebrae are the result of an accelerated organogenesis while the body size maintains a normal size, contributing to vertebral column bending.

### Salmonid group

Discreet vertebrae anomalies are one of the main problems in salmonid culture: Deschamps *et al.* (2008) found that up to 55% of normally shaped rainbow trout *Oncorhynchus mykiss* (i.e. showing no external anomalies) at market size were found to be affected by vertebral anomalies in French farms. Gil Martens (2012) reported that a certain number of Atlantic salmon were affected to a different degree by a variable number of compressed vertebrae, not externally visible.

Platyspondyly is the main vertebrae anomaly observed in salmon reared in Norway (Gil Martens 2012), characterized by a compressed vertebral body that may or may not be fused. If the number of compressed vertebrae is large, then the reduction in the fork length characterizes the 'short-tail' phenotype. A compressed vertebra has a normal central portion of the body but deformational changes in the anterior and posterior rims of the compact bone (Witten *et al.* 2006). They mainly occur in the vertebrae caudad to the dorsal fin; however, the entire axis can be involved. Vertebrae compression was observed in salmon after a period of mechanical strength, in association with a low vertebral mineral content. The destiny of compressed vertebrae may follow two directions: (i) damage the notochordal tissue in the intervertebral regions, which initiates transdifferentiation of the notochordal cells into chondroblasts; or (ii) initiate cartilage deposition directly through differentiation of some bone cells into chondroblasts (Fjellidal *et al.* 2009). In salmon, the calcification of the heterotopic intervertebral cartilage and its subsequent remodelling into bone apparently facilitates the factual fusion of vertebral bodies (Witten *et al.* 2006).

The ordering system of vertebral body anomalies commonly observed in Atlantic salmon commercial farms proposed by Witten *et al.* (2009) provided a standard that could improve diagnosis, help link peculiar anomalies to particular extrinsic or intrinsic causal factors and better identify developmental patterns. Decreased intervertebral space without vertebral fusion (commonly related to platyspondyly), homogeneous compression, compression and reduced intervertebral space, compression that alters the radiodense X-structure (that characterizes each vertebral body) and one-sided compression are all subtypes of compressed vertebrae; compression and fusion (ankylosis),

complete fusion and centre fusion are subcategories of fused vertebrae. All these related anomalies were found to emerge both independently from each other and share common characters: platyspondyly can result in vertebral fusion but also occurs without vertebral fusion. This is because anomalies may regress, change their character or the same anomaly may represent a final stage, a developmental intermediate stage towards another type of anomaly or just a mild case that does not progress further.

As far as anomalies affecting the vertebral arches are concerned, they have been considered and reported rarely in reared Salmonid fish.

### Anomalies of the fins

Fins anomalies are frequently observed in reared fish, but the frequency, the affected fin and the severity of anomaly largely vary according to the species, the rearing methodology and the tank features (Fig. 2d,e,g,h,n). In intensive conditions, fin erosions or bitten caudal fins are quite frequent due to crowding effects: these are not to be considered as skeletal anomalies (and so are not considered in this review). However, the poor state of bitten or eroded fins prevents the monitoring of true fin anomalies.

In general, the most severe observed fin anomalies are the complete lack of a fin, the presence of a supernumerary fin or fin dislocation, but they are very rare or limited to some peculiar lot/farm or observed in the experimental rearing of a new candidate species.

The lateral bending and the duplication of caudal fin is the first severe fin anomaly recorded in European reared species (gilthead seabream, Koumoundouros *et al.* 1997a). Since then, caudal fin anomalies have been recorded as developing with an incidence of 60–100% in at least four commercial hatcheries, in a variety of species (e.g. gilthead seabream, sharpnose seabream, white seabream *Diplodus sargus*, red porgy and bogue *Boops boops*) and in the form of lateral bending, duplication, partial lack or stricture of the fin rays (Koumoundouros 2010). Koumoundouros *et al.* (1997a) demonstrated that caudal fin anomalies may originate during early ontogenetic stages (e.g. yolk-sac larval stage), well before the development of the caudal fin skeleton, as a result of anomalous bending of the posterior tip of notochord.

The partial or complete underdevelopment of the dorsal or anal fin has been documented as developing in the species of Mediterranean aquaculture. This anomaly is named 'saddleback syndrome' (Fig. 2c), but different anomalous patterns are included under this anomaly, by different studies, in different species. The common trait is a characteristic depression in the anterior dorsal profile, easily detectable at gross examination. According to Koumoundouros *et al.* (2001) and Koumoundouros (2010), this type of anomaly

in reared common dentex (affecting 4–4.4% of observed samples) originates from early abnormalities of the dorsal part of primordial marginal finfold. In this species, it was expressed as a lack of one to all the dorsal spines and relative pterygiophores, anatomically and ontogenetically associated with severe caudal fin anomalies. In white seabream, Sfakianakis *et al.* (2003) recorded a variant of saddleback syndrome, which was described as a V-shaped deformation of the complete dorsal fin, accompanied with a simultaneous development of pre-haemal kyphosis and haemal lordosis and caudal fin anomalies. In common pandora (*Pagellus erythrinus*), Boglione *et al.* (2003) described the saddleback occurring in the transitional area between the spinous and soft regions of the dorsal fin, also affecting relative pterygiophores. In this species, saddleback was found to be associated with caudal fin anomalies only in one juvenile (3.2% of saddleback deformed specimens) and never with anomalous underlying vertebrae. Up to now, no data are available to understand if all these deformation patterns can be attributed to a different severity of the same anomaly or to different anomalies with different aetiology: its presence has been reported in many fish species, under rearing and natural environmental conditions (Boglione & Costa 2011).

The formation of additional or duplicated dorsal fin is another severe, but rare, anomaly of fins (Komada 1980; Matsusato 1986).

Fusion, lack, extra formation, displacement of the fin supporting elements (Marino *et al.* 1993; Koumoundouros *et al.* 2001) and curvature of the rays and spines (Paperna 1978; Daoulas *et al.* 1991) are relatively frequent fin anomalies in Mediterranean aquaculture, with negligible importance in respect of their effect on the external morphology of the final product. In addition, Georga *et al.* (2011) reported for the first time a bilateral or unilateral (left side) lack of pelvic fins (at frequencies of 44% and 22%, respectively), in European seabass under experimental conditions (low dietary levels of vitamin A). To date, such anomalies are extremely rare in juveniles from commercial farming.

The flatfish possess large dorsal and anal fins, supported by a large number of soft rays. Typically, there is an extension of the dorsal fin from the head to the base of the caudal fin that, in some species like those of the families *Soleidae* and *Cynoglossidae* can form a continuous or semi-continuous structure together with the caudal and anal fins, both in adult and larval fish (Carpenter 2002). A significant number of anomalies affecting the fins of Senegalese sole have been observed, mainly appearing as fusions or anomalies of hypurals in the caudal fin and as anomalous pterygiophores in the dorsal and anal fins (Gavaia *et al.* 2002; Engrola *et al.* 2009; Fernández *et al.* 2009; Fernández & Gisbert 2010). It has been reported that the cartilaginous

elements, like those composing the internal skeleton of the dorsal, anal and caudal fins, are more sensitive to high levels of vitamin A than dermal bones, with higher incidences of anomalies in hypuralia in fish receiving high dietary vitamin A doses (Fernández & Gisbert 2010).

Anomalies of the fins are quite rarely reported in Salmonids, with exclusion of fin erosions.

### Skull anomalies

Anomalies affecting the skull, mainly splanchnocranium, are evident at gross examination and mainly affect dentary, pre- and maxillary, glossohyal and opercular plate. They are mainly sublethal anomalies and affected fish show difficulty in efficiently nourishing, so growing slower and weaker than unaffected fish.

Opercular plate reduction or folding (Fig. 2h,j) leaves the branchial arches more exposed to injuries or parasites, so affecting the health status of affected fish.

Terminology on cranium anomalies is even more confusing than for vertebral anomalies, for the presence of more complex syndromes, in which more than one skeletal element may be affected. In species of Mediterranean aquaculture, skull anomalies have been recorded to affect the gill cover, jaws and hyoid arch.

Among them, anomalies of the gill cover have been recorded to affect mainly gilthead seabream (up to 80%: Koumoundouros 2010; a maximum of 9%: Cataudella *et al.* 2011b; 5–20%: Beraldo & Canavese 2011), but also European seabass and a variety of candidate species, in some lots (Paperna 1978; Barahona-Fernandes 1982; Francescon *et al.* 1988; Verhaegen *et al.* 2007; Koumoundouros 2010). Opercular plate (or gill cover) anomalies are anatomically attributed to inside or outside folding, shortening or abnormal positioning of the opercular and subopercular bones, both bilaterally or monolaterally (directional: Verhaegen *et al.* 2007; Fernández *et al.* 2008; or fluctuating: Barahona-Fernandes 1982; Koumoundouros *et al.* 1997b; Galeotti *et al.* 2000). Gill cover anomalies develop during the pre-flexion and flexion stage (Koumoundouros 2010). In gilthead seabream, the opercular folding into the gill chamber is detectable starting from 25 dph larvae (Beraldo *et al.* 2003). Beraldo and Canavese (2011) recently showed that the monolateral inside folding of the gill-cover presents a partial recovery during the on-growing of fish in sea cages, but only when the degree of anomaly is low. Further, in gilthead seabream juveniles, opercular plate anomaly has been found to develop mostly in intensive conditions: siblings reared in semi-intensive conditions showed no deformed opercular plates compared with intensively reared fish (Prestinicola 2012).

Pugheadness, cross-bite and lower jaw reduction or elongation are the main types of jaw anomalies that can affect

the finfish reared in Mediterranean aquaculture (Barahona-Fernandes 1982; Koumoundouros *et al.* 2004; Abdel *et al.* 2005).

In pugheadness, the ethmoid region and upper jaws are antero-posterior compressed. Data from both experimental and reared fish demonstrate that pugheadness is more frequent in gilthead seabream, whereas in European seabass and common dentex all kinds of jaw anomalies are observed.

In cross-bite, the dentary appear affected by asymmetric growth: the result is that the dentary tip appears skewed off-centre so it is not oriented parallel to the upper jaw.

Finally, the reduction of the lower jaw is almost identical to the intense cross-bite and attributed to the ventro-lateral distortion of the jaw elements (Hickey *et al.* 1977; Cobcroft *et al.* 2001).

In Atlantic cod, curved palatine bone, pughead and deformed dentary have been described.

The prognathism (prolongation) of the dentary is quite frequently observed only in intensively reared European seabass or gilthead seabream (Clara Boglione, pers. comm., 2012) and in young stages in cod (Baeverfjord *et al.* 2009). It was found to be associated sometimes with premaxillary anomalies. In this way, both prognathism of the dentary, mainly observed in European seabass, and a reduction of premaxillary (and maxillary), more frequent in gilthead seabream, give a longer lower jaw to the fish.

It has been suggested that jaw anomalies develop mainly during the early larval stages (Koumoundouros 2010).

An anomalous hyobranchial skeleton is frequently observed in reared gilthead seabream juveniles (rarer in European seabass), reaching frequencies of even 40–80%, in some lots. The anomaly is related to the ventral projection of glossohyal, or basihyal or hypohyal elements, often associated with bending and/or dislocations of ceratohyals. This anomaly has been detected as developing during the early larval stages (Koumoundouros 2010).

Izquierdo *et al.* (2010), while studying the cranial anomalies in red porgy, found that the intensiveness of the rearing conditions, particularly increased upper-jaw reduction and cross bite jaw and observed a very low incidence of opercular plate anomalies. According to the authors, the low incidence of opercular anomalies in red porgy could be explained by the early presence of long larval pre-opercula and opercula spines that could reinforce the forming operculum, preventing its folding into the gill chamber. However, the presence of more or less extended larval opercular spines in all the Sparids, gilthead seabream included, does not support this hypothesis.

In flatfish, it is relatively common to find specimens with anomalies in the skull due to abnormal ocular migration and incorrect migration of the cranial structures during

metamorphosis. It has been found that post metamorphic Senegalese sole can display up to 5% of specimens with ocular migration related abnormalities (Gavaia *et al.* 2009). This type of abnormality has been associated with the presence of a deformed pseudomesial bar, in other flatfish species (Okada *et al.* 2003; Schreiber 2006).

Only one report on jaw anomaly in larval Senegalese sole is present in the literature: recently, Blanco-Vives *et al.* (2010) described a relationship between jaw anomalies and the daily variations of temperature and light cycles during the early development of Senegalese sole larvae. Lower incidences of jaw anomalies were observed when fish were reared at a thermal cycle of 22.1°C day/19.0°C night, instead of 19.2°C day/22.0°C night.

There are also some references inherent to jaw anomalies (named 'gapers') affecting the larvae of Atlantic halibut, at levels ranging from 1% (Saele *et al.* 2003, 2004) to 11% (Solbakken & Pittman 2004). Pittman *et al.* (1998) and Saele *et al.* (2004) described some of the main types of developmental problems affecting Atlantic halibut larvae and detectable during metamorphosis, in the form of malpigmentation, incomplete eye migration, unattached anterior dorsal fin, cranial anomaly and jaw anomalies.

Estévez and Kanazawa (1995) found that turbot larvae fed high levels of vitamin A resulted in a higher number of fish with abnormal eye migration.

In Salmonids, cephalic anomalies are less frequent than vertebral, but maintain a certain relevance. Particularly in salmonids, the terminology used often refers to a general anomalous picture, involving more than one bone, instead of indicating a single anomalous bone, so making difficult any comparison with skull anomalies found in other reared teleosts. Further, some description of severe skull anomalies, involving both splanchno- and neurocranium, is limited only to some and not all involved bones. Pugnose relates to consistent anomalies on pre-maxillary, palatine and mesethmoid that give the head a characteristic profile. In advanced juveniles, an abnormal dentary can be found in association. This anomaly develops during embryonic development and is already externally detectable in just-hatched fry. In rainbow trout, many juveniles exhibit anomalies of premaxillary and maxillary, associated with severe reduction and maldevelopment of the upper rostral bones of neurocranium. The upper jaw may be deformed and protruding or only deformed or severely deformed and reduced. The so-called 'screamer disease' is used to indicate a typical anomaly co-affecting both dentary and maxillary, that both curve ventrad. This anomaly has been detected only after smoltification.

In early salmon juveniles, a ventral projection of the glossohyal is observed, and in the most severe cases, the bone projection perforates the skin ventrad to the mouth,

so forming a 'double mouth'. This condition is easily detectable during manual sorting and, however, is considered lethal.

The dentary shortening or dislocation is identifiable in first feeding rainbow trout, rarely at later stages. Other anomalies have been described in trout lower jaw, such as dentary blockage in a gaping position (the mouth cannot be closed). In rainbow trout, a series of peculiar anomalous conditions are described (e.g. missing body parts, twin anomalies, some head anomalies, strictures) only in some groups and in high temperature rearing conditions (Baevefjord *et al.* 2009).

### Effects of skeletal anomalies on fish biological performance

The literature on the effects of skeletal anomalies on the biological performance of the reared fish is scarce and existing published information consists of secondary data collected indirectly during studies on the ontogeny and anatomy of different types of skeletal anomalies. In general, skeletal anomalies are considered to exert significant negative effects on animal welfare, the biological performances of the reared fish, the quality of the product and the production cost. Moreover, in species that are mainly marketed as whole-fish (e.g. gilthead seabream and European seabass), an anomalous external morphology (even of a few fish) could substantially decrease the consumers' overall perception of aquaculture products.

Since external morphology is a major quality criterion for consumers, body shape is probably the most important character that is affected by skeletal anomalies. The alterations of body shape by the presence of skeletal anomalies usually have a continuous range, depending on the severity of the anomalies. For example, the effects of haemal lordosis on the body shape of European seabass were shown to be well correlated with the lordosis angle and to have a continuous expression between a low significance of the effect to severe shape alterations (Sfakianakis *et al.* 2006b). On the other hand, gill-cover anomalies or the saddleback syndrome could be considered anomalies with discontinuous effects on the external morphology, since their presence is associated in some reared lots with other severe morphological alterations (i.e. gill exposure or depression of the dorsal profile, respectively; Koumoundouros *et al.* 1997b; Setiadi *et al.* 2006; Verhaegen *et al.* 2007).

Except for their negative effects on fish morphology, some skeletal anomalies have been shown to or are expected to downgrade the biological performance of the reared fish. Gill cover anomalies have been shown to increase the sensitivity to oxygen stress and a predisposition to myxobacterial infections (Paperna *et al.* 1980), whereas during the larval stage their incidence has been shown to

correlate negatively with the growth rate of the fish (Koumoundouros *et al.* 1997b). In gilthead seabream, Verhaegen *et al.* (2007) and Georgakopoulou *et al.* (2010) showed a 2.5–4.0-fold decrease in the incidence of gill cover anomalies during the metamorphosis phase, possibly resulting from a selective mortality of the deformed fish.

In European seabass, pre-haemal kyphosis was shown to induce lethargic behaviour and a subsequent heavy mortality during vertebral axis osteogenesis, as a result of the compression of the neural tube by the deformed vertebrae (Koumoundouros *et al.* 2002). Finally, Basaran *et al.* (2007) showed that lordosis significantly decreases the endurance and critical swimming speed of European seabass juveniles.

Carls *et al.* (1999) exposed herring eggs to 0.7 ppb polynuclear aromatic hydrocarbons (PAHs) and then, by observing the effects on hatched larvae, they found that the spinal condition was the most important predictor of swimming ability, the lower jaw size was the second predictor and yolk sac oedema was the third; correlation with pericardial oedema was not significant.

Seriously deformed neural and haemal arches, as above reported, can affect blood flows and spinal cord functions.

Anomalies affecting the fins can exercise negative effects on fish locomotion with effects varying according to the involved fin, the seriousness of the anomalies and species-specific swimming and feeding behaviour.

Serious jaw anomalies impair efficiency in feeding with consequences on the growth rate.

### **Causative factors of skeletal anomalies in reared fish**

Many skeletal anomalies are the result of genetic factors and/or the incapacity of homeorhetic mechanisms to compensate for stressful environmental conditions.

Up to now, a great variety of factors have been shown to be involved in the development of skeletal anomalies in a variety of finfish species under rearing conditions (reviewed by Divanach *et al.* 1996; Cahu *et al.* 2003a,b, 2009; Koumoundouros 2010; Zambonino-Infante & Cahu 2010; Boglione & Costa 2011). With the exclusion of pollutants and pathogens, which are well controlled under rearing conditions, existing literature clearly suggests that unfavourable abiotic conditions, inappropriate nutrition and genetic factors are the most possible causative factors of skeletal anomalies in reared fish. This great variability of causative factors, of their results on the skeleton, and of the species under concern is furthermore expanded by changes in the environmental and nutritional preferences of a given species during the process of ontogeny, as well as by the development of the different skeletal elements (and thus of the related anomalies) at different ontogenetic stages (reviewed

by Koumoundouros (2010) for the species of Mediterranean aquaculture and by Boglione & Costa (2011) for reared Sparidae). As an example of this ontogenesis-related requirement, Mazurais *et al.* (2009) showed that the optimal level of dietary retinol for harmonious skeletal development fluctuates significantly along the ontogeny of European seabass. Similarly, Georgakopoulou *et al.* (2010) showed that the optimal temperature for normal skeletal development fluctuates significantly along the ontogeny of gilthead seabream.

### **Genetic factors**

Genetic factors underlying skeletal anomalies in reared fish have been very recently the subject of investigations, most of them arise secondarily during genetic selection programmes aimed at enhancing a fast growth rate. A series of studies have been conducted to ascertain the heritability of some skeletal anomalies, the existence of genetic drift or gene mutations in deformed fish, the effects on the phenotype of genetic modifications, inbreeding, selective breeding, polyploidy. The availability of highly polymorphic genetic markers, such as microsatellites, has opened new scenarios in estimates of the genetic basis of body anomalies (O'Reilly & Wright 1995; Ferguson & Danzmann 1998; Castro *et al.* 2004, 2006, 2007).

Genetic screening for mutants in zebrafish regulating skeletogenesis represent the bulk of the studies on genetic factors influencing fish skeletal anomalies and has been used extensively to enlarge the knowledge on genetic factors and regulatory mechanisms.

The first indication of the possibility that high inbreeding levels in rainbow trout may produce skeletal anomalies was described by Aulstad and Kittelsen (1971). It has also been reported that some anomalies may be inherited as single gene effects (Rosenthal & Rosenthal 1950; Gordon 1954; Takeuchi 1966).

Several reports have suggested that both simple Mendelian genes and polygenic determinants could explain the incidence of skeleton anomalies, and some recent papers report on the heritability of some skeletal anomalies in gilthead seabream: Thorland *et al.* (2007) found moderate–low heritability for external colour and vertebral axis anomalies; Castro *et al.* (2008) reported in gilthead seabream a slight familiar association ( $P < 0.05$ ) when comparing individuals lacking an operculum, but not between lordotics or between normal ones, and concluded that most of the phenotypic variation observed for lordosis and lack of an operculum in gilthead seabream is due to environmental factors; Afonso *et al.* (2000) found that the LSK syndrome was statistically associated with the family structure, suggesting a possible genetic origin. In a later study, Afonso *et al.* (2009) described lordosis and consan-

guinity levels in gilthead seabream breeders increase the incidence of deformed larvae and that the susceptibility for the presence/absence of vertebral column anomalies has a high additive genetic component. Navarro *et al.* (2009) reported estimates of heritability for lordosis and lack of an operculum in gilthead seabream fingerlings, whilst a weak association among skeleton anomalies and inbreeding was reported in gilthead seabream by Astorga *et al.* (2003). Izquierdo *et al.* (2010) reported that lordosis has been found to be correlated to consanguinity, being a character with a high heritability (85%).

Kolstad *et al.* (2006) found in Atlantic cod some specific spinal anomalies showing a high degree of environmental sensitivity, and that the G\*E (Genotype vs. Environment) interaction was of some significance owing to the occurrence of these anomalies: their conclusion was that the inclusion of spinal anomalies character in a breeding program demands a controlled environment, as performance in one environment may not reflect performance in another.

The contrary was found in Atlantic salmon by Gjerde *et al.* (2005), where inbreeding is excluded from the causes of the anomalies.

Researchers seem to agree that if a genetic basis for skeletal anomalies is observed, this predisposition is expressed only when exceptional environmental conditions occur (energy failure, temperature rising, ...): Kause *et al.* (2007), when analysing skeletal deformations in farmed salmon, discovered that heritability was close to zero in cohorts in which management practices routinely run. When there was a management failure, the incidence of skeletal anomalies unusually rise with elevated heritability. These authors also found that both positive and negative correlations between generations were present, showing that high liability at any time can be genetically connected to low liability at another time, and that genetic correlations between anomalies recorded in different environments were significantly or near to significantly positive, in farmed salmon. The authors hypothesize that a trait recorded as a skeletal anomaly is not a single trait, and its genetic determination varies from place to place and from generation to generation (Kause *et al.* 2007).

Interaction G\*E is the main body of recent genetic investigation in reared fish: Wargelius *et al.* (2005) found that when Atlantic salmon eggs were incubated at elevated temperature, the expression of *shh* and *twist* transcriptional factors decreased (major details are available below). In the same species, Grini *et al.* (2011) found that a temperature higher than the species-specific one induced an up-regulation of MMP13 (increasing the degradation process of extracellular bone matrix) while Ytteborg *et al.* (2010) found a down-regulation of extracellular matrix components, as further reported.

The possibility that a genetic drift effect could be envisaged in reared fish is based on the observation of uneven contribution given by different breeders to each reproduction event in farming conditions. Up to now and to the best of our knowledge, the presence of genetic drift has been ascertained in red seabream, cutthroat trout (*Oncorhynchus clarkii*), brown trout (*Salmo trutta fario*), Atlantic salmon and black seabream (*Spondyliosoma cantharus*). Several genetic studies have been carried out on farmed Atlantic salmon, demonstrating reduced allelic variation compared with wild salmon populations, and Skaala *et al.* (2004) observed significant genetic differentiation among five major strains of farmed Atlantic salmon.

Regarding swim bladder anomalies, Peruzzi *et al.* (2007) hypothesized that paternally and maternally inherited factors may contribute to the expression of swim bladder anomalies in European seabass.

Recently, the use of polyploid salmon (for a review on current issues related to the application of induced polyploidy in aquaculture see Piferrer *et al.* 2009), for improving body growth rates and reducing male aggressiveness during the reproductive period, evidenced a higher incidence of skeletal anomalies. Triploid European seabass larvae showed a high incidence of anomalies and died just after hatching (Zanuy *et al.* 1994), and Sugama *et al.* (1992) attributed the low survival rates observed in triploid red seabream to the high levels of anomalies. Since the beginning of the 1990s triploid salmon have been more satisfactorily produced, but the high frequencies of deformed fish opened the scenario to investigations aiming to distinguish which between the triploidy condition in itself and the induction shock applied to eggs the causative factor was. In rainbow trout, temperature shocks for triploidization of eggs resulted in a higher deformation rate at hatching than pressure shocks. The lower jaw anomalies augmentation in triploid salmon has been imputed to the triploidy condition (Piferrer *et al.* 2009), whilst more complex anomalies, such as the co-occurrence of opercular and gill filament anomalies, and reduced gill surface area, can be imputed to only one of these two factors.

Externally detectable anomalies that were higher in triploid than in diploid salmon, only in first feeding juveniles, are macrocephalia, lordosis and twisted body (spiral tail; Piferrer *et al.* 2009). In triploid Atlantic salmon at first feeding, opercular shortening was the main anomaly observed in one lot, but in the period from post hatch to smolt unit transfer, spiral tail (a variant of twisted body) was mainly observed in all the triploid lots (Taylor *et al.* 2011, 2012). However, anomalies in many triploid studies are only rarely reported in the early stages, in contrast to older stages where the prevalence of deformed individuals can be very high, at least in Atlantic salmon (Lijalad & Powell 2009). According to some authors, the most com-

mon anomalies reported in triploid salmon are those affecting the lower jaw, gill filament, spinal axis as well as cataract and reduced gill surface area (Sadler *et al.* 2001; Oppedal *et al.* 2003).

As far as spinal anomalies in triploid fish are concerned, Johnston *et al.* (1999) hypothesized that ploidy induces muscle fibre recruitment and hypertrophy, with a consequent alteration of vertebral axis. Supernumerary normal vertebra was found in triploid rainbow trout (Kacem *et al.* 2003), whilst triploid European seabass showed no alteration in the frequency but in the severity of skeletal anomalies with respect to diploids (Piferrer *et al.* 2009).

The presence of a high prevalence of deformation rate in triploid fish has been ascribed to maternal effects (egg quality).

### Non-genetic factors: nutrition

Larval nutrition has been recognized by many studies as one of the key parameters that affect skeletogenesis during early fish development (for a comprehensive review on different nutritional requirements in reared finfish larvae see Hamre *et al.* 2013 and Rønnestad *et al.* 2013). Several studies have demonstrated that different nutrients (e.g. lipids, amino acids, vitamins and minerals) are responsible for the appearance of skeletal anomalies when their level and/or form of supply in the diet are inappropriate or unbalanced (Cahu *et al.* 2003b; Lall & Lewis-McCrea 2007). The very early observations reporting on the impact of larval nutrition on skeletal anomalies were recorded mainly in freshwater fish species such as salmonids that can be fed easily from first-feeding with compound diets (Halver 1957; Kitamura *et al.* 1965). Then studies were extended to marine fish species, in relation to the development of freshwater and marine aquaculture. Considering that marine fish larvae hatch much earlier in their development than most freshwater fish and higher vertebrates (Haga *et al.* 2002), they provide an exceptional tool for studying the molecular processes influenced by nutrition that are involved in the appearance of skeletal anomalies during the early stages of teleost development. In this sense, the development of a reliable and balanced microdiet for European seabass larvae, which can totally and efficiently replace live prey, has allowed several studies on the optimization of different essential nutrients in feeds for marine fish larvae (Villeneuve *et al.* 2005a,b, 2006; Mazurais *et al.* 2008; Kvåle *et al.* 2009; Darias *et al.* 2010, 2011a,b; Georga *et al.* 2011; among others). However, the nutritional requirements for the larvae of many other marine species, and the impact of nutrients that are essential for normal larval development and skeletogenesis, are still being researched using enriched live prey, in those species that cannot accept microdiets at early stages of development. In this sense, the rotifer

*Brachionus plicatilis* and the nauplii and metanauplii of the branchiopod *Artemia* sp. have been used extensively as live prey in rearing marine fish larvae protocols due to their appropriate size, easy and rapid culture/production, and suitability for mass production under controlled conditions. However, their use requires the improvement of their nutritional value to fit the nutritional requirement of fish larvae by means of enrichment procedures. Although the nutritional quality of rotifers and *Artemia* can be easily manipulated by means of commercial or tailor-made enrichments and emulsions, these live organisms have the ability to metabolize nutrients, changing their nutritional content (Navarro *et al.* 1999; Giménez *et al.* 2007). This increases the difficulty of conducting nutritional studies in this group of fish larvae that need to be fed with enriched live prey, although there exist very comprehensive and interesting studies in the literature assessing the impact of different nutrients in fish larval morphogenesis and the genetic regulation of this developmental process (Dedi *et al.* 1995; Takeuchi *et al.* 1995; Haga *et al.* 2002; Tarui *et al.* 2006; Fernández *et al.* 2011, among others). In this section, the effect of different nutrients on fish larval skeletogenesis and their impact on the development of skeletal anomalies are presented, considering the available literature on this topic obtained from cold and temperate, marine and freshwater reared fish species, fed with compound microdiets and/or live feeds.

It is possible to find more detailed information on the different larval nutrient requirement and general method of action in the review on larval nutrition by Hamre *et al.* 2013.

### Proteins and amino acids

It is generally recommended that artificial diets for fish larvae should have a nitrogen solubility and molecular weight profile similar to that found in wild live food (Carvalho *et al.* 2003). In addition, the low capacity to digest proteins, and the amino acid (hereafter indicated as AA) requirements for energy production and growth of marine fish larvae, means that amino acid requirements are likely to be very high and that dietary imbalances will have a burden in terms of nitrogen utilization (Aragão *et al.* 2004) and, eventually growth and development (Conceição *et al.* 2003). In this sense, several authors have recommended the inclusion of protein hydrolysates in compound diets for fish larvae, since they enhance the digestibility and nutritional value of the feed (Kolkovski 2008). Protein hydrolysates typically consist of low molecular-weight peptides (200 < MW < 500 Da) resulting from protein pre-digestion (Önal & Langdon 2009). These compounds are more efficiently absorbed and digested by enterocytes compared with high-molecular-weight macromolecules, which is due to the specific digestive features of fish larvae in compari-



son with juveniles or adults (see review in Zambonino-Infante & Cahu 2010).

Different types of experimental and commercial protein hydrolysates differing in their original raw material (i.e. casein, krill, squid, shrimp, mussel, fish meal), their production system (i.e. silage, enzymatic digestion, fermentation, among others) and their biochemical characteristics (i.e. amino acid profile, molecular weight of peptides) have shown that protein hydrolysates enhanced larval and fry growth and/or survival performance in several freshwater and marine species, such as common carp *Cyprinus carpio* (Carvalho *et al.* 1997), rainbow trout (Dabrowski *et al.* 2003), Atlantic salmon (Berge & Storebakken 1996), European seabass (Zambonino-Infante *et al.* 1997; Cahu *et al.* 1999), gilthead seabream (Gisbert *et al.* 2012), Atlantic cod and Atlantic halibut (Kvåle *et al.* 2009). In terms of fish larval quality and the development of skeletal anomalies, the dietary incorporation of short peptides is considered as beneficial for fish larval development, as they promote the harmonious development of the skeleton (see review in Cahu *et al.* 2003b). The rationale of this improvement of the skeletogenesis in fish larvae fed microdiets incorporating protein hydrolysates is not clear. Enhanced larval performance and quality of larvae fed these types of feeds might be attributed to the enhanced proteolytic capacity of the pancreas and the earlier development of the intestinal digestion in those fish microdiets containing protein hydrolysates (Rønnestad *et al.* 2003; Kvåle *et al.* 2009; Zambonino-Infante & Cahu 2010). The capacity of the larval digestive tract to process dietary protein is limited by its proteolytic rather than by absorptive capacity (Conceição *et al.* 2011). Thus, the advanced intestinal digestion may have resulted in a better use of those nutrients contained in the diet, which might have contributed to a better development of the skeleton (Cahu *et al.* 2003b; Lall & Lewis-McCrea 2007; Zambonino-Infante & Cahu 2010).

In addition to the molecular size of the protein compounds included in the diet, the amino acid profile of the feed has also been described as having an effect on the quality of fish larvae, since dietary imbalances in amino acids have been reported to have major implications for larval development, other than effects on growth (for major details on amino acid requirements and effects on larvae see Rønnestad *et al.* 2013 and Hamre *et al.* 2013). First studies on specific amino acid deficiency conditions reported that dietary tryptophan deficiency induced scoliosis in several salmonid species, such as the sockeye salmon *Oncorhynchus nerka*, the rainbow trout, the coho salmon *O. kisutch* and the chum salmon *O. keta* (Tacon 1992), whereas scale anomalies and vertebral abnormalities were found in rainbow trout fed with a diet containing high levels of leucine (Choo *et al.* 1991). Recently, Saavedra *et al.* (2009) reported that a balanced dietary amino acid profile

improved larval quality by reducing the incidence of skeletal anomalies (lower incidence of vertebral fusions and no cases of lordosis) in the white seabream, whereas a diet supplemented with tyrosine and phenylalanine also improved the larval quality of this sparid (Saavedra *et al.* 2010). In a recent study in gilthead seabream larvae co-fed live prey and microdiets containing different levels and types of protein hydrolysates, Gisbert *et al.* (2012) suggested that leucine, phenylalanine and valine had an important role in the skeletogenesis process. Although the exact role of these amino acids has not been studied in fish with regard to skeletogenesis and bone health status, studies from higher vertebrates indicated that leucine, phenylalanine and valine were important for the proper development of the extracellular bone matrix. Thus, phenylalanine is necessary for maintaining the bone morphogenetic property of the bone matrix (Urist & Iwata 1973), whereas leucine is the one of the main components of some structural proteoglycans, which are the most abundant constituents of the non-collagenous proteins in the bone matrix (Robey 2002). In addition, nutritional studies have shown that valine-deficient diets reduced calcium levels in bones and induced skeletal anomalies in chicks (Farran & Thomas 1992).

#### *Lipids and fatty acids*

In fish larval nutrition, lipids and their constituent fatty acids are probably the most studied nutrients (see Hamre *et al.* 2013 and Rønnestad *et al.* 2013). However, they remain one of the least understood and enigmatic nutrients in aquaculture nutrition (Glencross 2009). This might be due in part to the relatively complex chemistry and the varied functional roles of lipids (for review see Sargent *et al.* 2002). Lipids can be divided into different classes: triacylglycerols, wax esters, phospholipids, sphingolipids and sterols that all contain fatty acids with the exception of cholesterol. All fatty acids can serve as an energy source, but some specific long-chain polyunsaturated fatty acids (PUFA) also have a number of essential roles in metabolism and especially in bone metabolism, as demonstrated in mammals (for review see Poulsen *et al.* 2007) and are highly vulnerable to lipid peroxidation. The lipid requirements of marine fish larvae have been extensively studied during the past two decades and particular attention has been paid to PUFA and phospholipids (Cahu *et al.* 2003a; Villeneuve *et al.* 2005b, 2006).

*Essential fatty acids.* Marine fish are considered to have an absolute requirement for PUFA, such as eicosapentaenoic acid (EPA, 20:5n-3), docosahexaenoic acid (DHA, 22:6n-3) and arachidonic acid (ARA, 20:4n-6), being unable to produce these fatty acids from their precursors alpha-linolenic acid (18:3n-3) and linoleic acid (18:2n-6). Thus, their deficiency delays fish growth, induces mortality,

reduces resistance to stress and results in anatomical alterations associated with nutritional disorders (see Hamre *et al.* 2013 on this journal). Although the quantitative requirements and deficiency signs of essential fatty acids (EFA) in several freshwater and marine fish have been documented, the functional role of n-3 and n-6 HUFA in bone lipid metabolism of fish remains to be investigated (Lall & Lewis-McCrea 2007). Essential fatty acid requirements vary qualitatively and quantitatively with both species and during ontogeny of fish, with early developmental stages and broodstock being critical periods (for review see Tocher 2010 and Rønnestad *et al.* 2013). Symptoms of EFA deficiency include reduced growth and increased mortality as well as myocarditis, pale/swollen (fatty) liver, intestinal steatosis, fin erosion, bleeding from gills, lordosis, reduced reproductive potential and shock syndrome (Tacon 1996; NRC 2011). However, data about the relationship between EFA deficiency and the development of skeletal anomalies are quite scarce. Takeuchi *et al.* (1991) reported that fingerlings of grass carp *Ctenopharyngodon idella* fed a diet without EFA showed a high incidence of specimens displaying an upward displacement of the column at the region of the 12–15th vertebrae, from the caudal end. However, the former authors were able to prevent lordosis by the addition of 1% linoleic acid to the diet. In milkfish *Chanos chanos* larvae, the enrichment of live food with DHA allowed a reduction in the incidence of opercular anomalies in juveniles (Gapasin & Duray 2001). Likewise, in red porgy larvae, a 50% reduction in the number of deformed fish (mainly vertebral fusion and cranial anomalies) was obtained when the larvae were fed higher DHA levels, denoting the important role of this fatty acid in bone development (Izquierdo *et al.* 2010). However, the exact role of dietary lipids in the development of skeletal anomalies remains to be investigated in fish (Lall & Lewis-McCrea 2007). Dietary lipids could influence the fatty acid composition of fish bones and thus the formation of highly biologically active compounds, the eicosanoids, which are 20-carbon derivatives of 20-carbon PUFA. These compounds include prostaglandins and leukotrienes, which have diverse pathophysiological actions, including bone cell metabolism. In Atlantic salmon juveniles, dietary vegetable oil as a replacement for fish oil has been shown to influence the ARA level in the phospholipids of vertebrae, slightly increase the production of prostaglandin E<sub>2</sub> (PGE<sub>2</sub>) in blood and reduce vertebral mineralization without leading to any detectable skeletal anomaly (Berge *et al.* 2009). Although ARA is present in fish tissues in lower amounts than DHA and EPA, absolute amounts of dietary ARA may not be neglected, as well as its content relative to EPA and DHA (Moren *et al.* 2011). Arachidonic acid is the major precursor for

eicosanoid synthesis, enhancing the immune system and resistance to stress (Bell *et al.* 2003) and alterations in the dietary ARA/EPA ratio can affect the production of PGE<sub>2</sub> known to regulate osteoblasts and bone metabolism (Berge *et al.* 2009). Although the action of ARA on bone turnover is well known in mammals (Watkins *et al.* 2001), little information on the effects of the dietary ARA content on bone development in fish is available. In a recent study, Boglino *et al.* (2012) fed Senegalese sole larvae with *Artemia* metanauplii enriched with graded levels of ARA (1.0%, 4.5% and 7.0% ARA of total fatty acids), and found that dietary ARA levels did not affect the incidence of total skeletal anomalies, although the skeleton of larvae fed 4.5% ARA tended to be more calcified at 15 dph than that of larvae fed the other diets. Dietary PUFA and their metabolites have also been demonstrated to affect gene expression through several mechanisms including the control of several transcription factors, leading to changes in metabolism, growth and cell differentiation in mammals (Jump 2004) and fish (Oku & Umino 2008; Ytteborg *et al.* 2010). In European seabass larvae, high dietary levels of n-3 long-chain PUFA with 4.8% of EPA and DHA have been shown to induce cephalic and vertebral column anomalies, adversely affecting fish growth and survival if compared with diets containing 1.1% to 2.3% EPA and DHA, which were associated with a down-regulation of some transcription factor genes (Villeneuve *et al.* 2005b). Likewise, these high dietary levels of n-3 long-chain PUFA only during the very early development (from 8 to 13 days post-hatching) have been shown to accelerate osteoblast differentiation process through the up-regulation of RXR $\alpha$  and BMP4, two genes involved in morphogenesis, causing a supernumerary vertebra and suggesting that the composition of diets devoted to early stages of marine fish larvae has a particularly determining effect on the subsequent development of larvae and juvenile fish (Villeneuve *et al.* 2006). In addition, deleterious effects of excessive DHA contents in microdiets for European seabass larvae have also been observed by Betancor *et al.* (2011) with an increased incidence of muscular lesions. A recent report by Viegas *et al.* (2012) showed that when gilthead seabream osteoblastic cells are exposed *in vitro* to different levels of arachidonic acid, EPA and DHA, the cells have alterations of phenotype, gene expression patterns and capacity to mineralize. Arachidonic acid and EPA inhibited extracellular matrix mineralization while DHA stimulated mineralization, possibly by modulating the expression of bmp2, osteopontin and alkaline phosphatase.

*Phospholipids.* A relationship between the incidence of skeletal anomalies and dietary lipid class has been highlighted in several studies with fish larvae and early juveniles. Indeed

a dietary requirement for intact phospholipids has been established for various freshwater and marine fish species (for review see Tocher *et al.* 2008). The primary beneficial effect was improved growth in both larvae and early juveniles, but also increased survival rates and decreased incidence of anomalies in larvae. The stimulating effects of phospholipids in larval fish development and growth have been suggested to be due to the fish larvae having a limited ability to biosynthesize phospholipids *de novo* (Coutteau *et al.* 1997). The influence of dietary phospholipids on the early ontogenesis of fish, and specifically on fish skeletal development, has been reviewed recently by Cahu *et al.* (2009). Since the first studies by Kanazawa *et al.* (1981) that reported a reduction of skeletal anomalies (mainly twisted jaw and scoliosis) in ayu (*Plecoglossus altivelis altivelis*) larvae with the addition of chicken egg lecithin to the diet, the importance of the phospholipid class for the prevention of skeletal anomalies, particularly phosphatidylinositol, has been highlighted in common carp larvae (Geurden *et al.* 1998). The improved performance in Atlantic cod (Finn *et al.* 2002) and Atlantic halibut (Næss *et al.* 1995; Hamre *et al.* 2002) larvae, both coldwater species, fed natural copepods compared with commercially enriched live prey has been known for a long time and the differences in nutrient composition (Van der Meeren *et al.* 2008) and the potential consequences in larval production have been reviewed in detail by Hamre *et al.* (2005) and Hamre (2006). The main skeletal anomalies in these species are jaw anomalies and 'stargazers' in cod, and lack of eye migration in Atlantic halibut. The development of these are under fairly good control in today's hatcheries, but producers say the quality may still vary from batch to batch and the 'robustness' is not as strong as when the larvae are fed natural copepods. A recent publication shows that an increase of phospholipids resulted in a lower incidence of vertebral anomalies and better growth (Hansen 2011). Natural copepods contain fewer lipids, but phospholipids constitute a higher portion of the total lipids, which can partly explain why natural diets are better than rotifers and *Artemia*. Lipid digestion in marine larvae is still not fully understood (see Rønnestad *et al.* 2013). The success of the use of pre-hydrolysed proteins in formulated feeds has triggered the idea that pre-hydrolysed neutral lipids would also improve the absorption of lipids. Mollan *et al.* (2008) found that the limited ability to digest neutral lipids hampered the uptake and processing of neutral lipids, while mono-acyl-glycerol and phospholipids were absorbed by the enterocytes in a linear manner in Atlantic halibut larvae. But this effect was almost lacking in cod juveniles (Hamre *et al.* 2011). Different age, species and experimental setup between these two studies could have affected the outcome. The role of phospholipids on the ossification process of the vertebral column has also been suggested in

Atlantic cod larvae (Kjørsvik *et al.* 2009) and rainbow trout fry (Daprà *et al.* 2011), but the mechanisms remain to be elucidated. The beneficial effects of phospholipid on fish larval skeletal development could be due partly to an enhancement in digestive functions and lipid absorption as reported by Fontagné *et al.* (1998) in common carp larvae and a more efficient provision of long-chain PUFA to target tissues and cells compared with triacylglycerols as suggested by the studies in European seabass larvae by Villeneuve *et al.* (2005b). Indeed, the former authors demonstrated the existence of a direct relationship between the amount of n-3 PUFA in phospholipids and the effect on the normal development of the skeleton during the larval stage. The former authors showed that European seabass larvae used EPA and DHA more efficiently when present in the phospholipid fraction: 1.1% EPA + DHA (corresponding to a total DHA: EPA ratio of 1.9:1) appeared optimal since it induced a low level of anomalies. Better growth and survival of larvae was obtained with higher EPA + DHA levels but to the detriment of morphogenesis. An excess of these fatty acids in the phospholipid fraction of the diet induced severe anomalies in the maxilla and vertebral column. High levels of skeletal anomalies and a reduction in the growth and survival were associated with a down-regulation of the expression of RXR $\alpha$ , RAR $\alpha$ , RAR $\gamma$  and BMP4 expression. These studies highlight the necessity for further research to clearly understand the relationship between dietary lipid classes and skeletal anomalies in fish larvae and early juveniles as well the type of bone ossification.

**Oxidized lipids.** Fish bones of some marine species contain as high as 24–90% w/w lipid (Lall & Lewis-McCrea 2007). Tissues containing such relatively high HUFA concentrations are highly vulnerable to lipid peroxidation. Lipid peroxidation is an autocatalytic process initiated by free radicals, which are produced in the body primarily as a result of aerobic metabolism. Lipid peroxidation occurs when lipids are damaged by free radicals. In this process, HUFAs in cell membranes undergo degradation via a chain reaction (Lall & Lewis-McCrea 2007). Thus, high levels of PUFA in the absence of suitable antioxidant protection are highly prone to auto-oxidation in feeds but also to *in vivo* lipid peroxidation within the fish tissues that is considered a major cause of diseases, including muscular dystrophy in several fish (Tacon 1996). Information on the role of oxidized lipids in the development of skeletal anomalies in fish is very limited (Lall & Lewis-McCrea 2007).

Oxidized lipids could inhibit osteoblast differentiation and induce osteoclast differentiation by increasing interleukin-6 expression, an osteoclast-promoting cytokine, as described for mammalian osteoblasts (Parhami *et al.* 1997; Tseng *et al.* 2010). This contributes to the impairment of the bone remodelling equilibrium that can result in an

inhibition of osteoblasts and stimulation of osteoclasts, causing bone loss (Watkins *et al.* 2001). In Siberian sturgeon (*Acipenser baerii*) larvae, a non-teleost species, dietary oxidized fish oil has been shown to induce morphological anomalies (curved larvae, Fontagné *et al.* 2006). Lewis-McCrea and Lall (2007, 2010) reported scoliosis, spanning the cephalic/pre-haemal regions as well as the anterior haemal region of the vertebral column, in juvenile Atlantic halibut fed oxidized fish oil. According to the latter authors, additional studies are needed to examine the molecular and biochemical basis of the pathogenesis of skeletal disorders caused by lipid peroxidation in larval and juvenile tissues as well as the efficacy of antioxidants in preventing these anomalies. On the other hand, synthetic antioxidants such as ethoxyquin have been shown to exert some toxic effects (Yamashita *et al.* 2009; Wang *et al.* 2010) that might affect skeletal development in fish larvae, although no specific assays have been conducted on this issue.

### Vitamins

**Water soluble vitamins.** The water-soluble vitamins include eight members of the vitamin B complex group, the water-soluble essential nutritional factors choline, inositol and ascorbic acid that play key roles in growth, physiology and metabolism, and several vitamins or dietary nutrients, depending on the author, with less-defined activities for fish, i.e. p-aminobenzoic acid, lipic acid, citrin, and undefined growth factors (Halver 2002). Deficiencies of an individual water-soluble vitamin (B-group or C) are quite uncommon in commercial feeds; however, the effects of the above-mentioned nutrients on fish growth and development have been described in specific experimental studies. In this section, the authors consider only the effects of vitamins B and C on the process of skeletogenesis in fish, since there is no available information about the effects of the other compounds on the skeleton of fish larvae.

B vitamins (thiamine, riboflavin, niacin, pantothenic acid, pyridoxine, biotin, folate and vitamin B<sub>12</sub>) generally function as coenzymes in the main energy-producing metabolic pathways, and in the degradation and synthesis of nucleic acids, protein, lipids and carbohydrates. Thus, deficiency stages of the individual B vitamins lead to severe metabolic functions and mortalities (Moren *et al.* 2011; Hamre *et al.* 2013). While dietary unbalanced levels of vitamin C cause drastic changes in different fish tissues, the lack or excess of B vitamins is less obvious to evaluate, especially in larvae and juveniles that normally experience high mortalities early in the larval production chain (Waagbø 2010). Most of the studies dealing with B vitamins in young fish are focused on establishing the nutritional requirements for a single B vitamin in juveniles (Halver 2002; Waagbø 2010), but no information is available about the effects of different B vitamins in fish larvae, although the

deficiency effects of this group of vitamins may be inferred from the existing knowledge in juveniles, and especially that from salmonid species.

In the case of thiamine (vitamin B<sub>1</sub>), most of the signs of dietary thiamine deficiency in salmonids, including rainbow trout, consisted of anorexia, poor growth and neurological disorders, while no effect on the skeletal tissue has been reported (Tacon 1995).

Fish fed diets deficient in riboflavin (vitamin B<sub>2</sub>) showed poor growth, anorexia, erosion of the snout and fins, corneal lesions, neurological disorders and spinal anomalies, among other deficiency signs (Tacon 1995). In this sense, the high levels of riboflavin recorded in the ovaries of several fish species seemed to highlight the importance of this vitamin in embryogenesis and for the proper development of larvae, although no specific assays have been conducted on this issue (Waagbø 2010).

Niacin (vitamin B<sub>3</sub>) functions as a coenzyme in many energy-related metabolic pathways and its deficiency normally results in anorexia, poor growth dermatoses and neurological disorders (erratic swimming; Halver 2002), and it has been also associated with jaw anomalies in catfish *Ictalurus punctatus* (Tacon 1995). In chickens and poultry, niacin deficient diets have also been associated with abnormal development of the cartilage or so-called chondrodystrophy (Combs 2008), which may be linked to an impairment of chondroitin sulphate synthesis through a reduction in the level of ATP in chondrocytes (Sheffield & Seegmiller 1980).

Biotin is a cofactor in carboxylation and decarboxylation reactions involving the fixation of carbon dioxide. These reactions have important roles in anabolic processes and in nitrogen metabolism. When biotin is deficient in experimental salmonid diets, it generally results in poor growth, anorexia, neurological disorders (spastic convulsions) and muscular atrophy (Tacon 1995). No data on the effects of biotin-deficient diets on fish skeleton are currently available, although data from poultry indicate that a deficiency in this vitamin results in chondrodystrophy and irregular bone development (shortened and twisted skeletal elements). The explanation for these findings are not completely established, but presumably, reduced biotin levels prevent prostaglandin synthesis from essential fatty acids, and bone growth fails to respond to stress during development (McDowell 2000).

Vitamin B<sub>5</sub> (pantothenic acid) has critical roles in metabolism, being an integral part of the acylation factors coenzyme-A and acyl-carrier protein; thus, vitamin B<sub>5</sub> is required for the normal metabolism of fatty acids, amino acids and carbohydrates, and has important roles in the acylation of proteins (Combs 2008). The dietary vitamin B<sub>5</sub> deficiency signs in salmonids are anorexia, reduced growth, gill necrosis and clubbing, skin ulceration and opercular

distension (Tacon 1995; Halver 2002). Considering that this vitamin has an important role in lipid metabolism (Combs 2008) and bones in fish species contain high lipid levels (Lall & Lewis-McCrea 2007), it seems plausible, although it has not been reported or experimentally demonstrated, that impaired dietary levels of vitamin B<sub>5</sub> may also affect bone development and health in fish.

Vitamin B<sub>6</sub> (pyridoxine) has a major role in amino acid and protein metabolism and its deficiency generally results in a fall in nitrogen retention, an excessive nitrogen excretion and impaired tryptophan metabolism, and a poor use of protein from feed. As this vitamin is involved in the utilization of dietary protein and synthesis of tissue protein, it is required in greater amounts during periods of rapid tissue growth such as in the larval period. Salmonids and gilt-head seabream fed pyridoxine-deficient diets showed poor growth performance, anorexia, neurological disorders (lack of coordination of muscle movements, hyperirritability, erratic and rapid swimming behaviour) and excessive flexing of the operculum (Tacon 1995; NRC 2011).

The most important tasks of vitamin B<sub>12</sub> or cyanocobalamin concern the metabolism of nucleic acids and proteins, but it also participates in the metabolism of lipids and carbohydrates. A brief summary of vitamin B<sub>12</sub> functions would include purine and pyrimidine synthesis, transfer of methyl groups and the formation of proteins from amino acids. Vitamin B<sub>12</sub> is metabolically related to other essential nutrients, such as choline, methionine and folate. In particular, dietary deficiency of this vitamin will induce folate deficiency by blocking the utilization of folate derivatives (McDowell 2000). Data on the effects of vitamin B<sub>12</sub> on fish species indicated that salmonid species fed diets lacking vitamin B<sub>12</sub> resulted in poor growth and severe anaemia (Halver 2002), whereas no signs of deficiency related to the skeletal tissue have been described in fish. However, data from humans indicated that a poor dietary intake and low blood concentrations of several B vitamins such as folate, vitamin B<sub>6</sub> and B<sub>12</sub> may affect the health of the skeletal tissue. In this sense, low dietary levels of folate, vitamin B<sub>6</sub> and B<sub>12</sub> were associated with decreased bone mineralization, whereas *in vitro* studies indicated that low B-vitamin concentrations promoted osteoclast activity, whereas elevated concentrations may stimulate bone formation. The effect of the above-mentioned vitamins on bone may be through an effect on plasma homocysteine levels, since these vitamins serve as cofactors or substrates for the enzymes involved in homocysteine metabolism (McLean *et al.* 2008).

Vitamin C or L-ascorbic acid (LAA) has many biological and physiological functions. It acts as a biological reducing agent for hydrogen transport, and it is involved in many enzyme systems for hydroxylation. This is especially relevant since L-ascorbic acid is necessary for the synthesis of

collagen in the formation of connective tissues and structural supporting organs, such as the skin, cartilage and bone in the developing fish larvae, as well as in bone formation and remodelling, contributing therefore to growth (Darias *et al.* 2011a; Moren *et al.* 2011). In addition, L-ascorbic acid is also involved in the formation of chondroitin sulphate fractions (Halver 2002), which is an important structural component of cartilage and provides much of its resistance to mechanical compression. L-ascorbic acid also plays a key role in other essential functions related to the role of this nutrient in the integrated antioxidant system in synergy with vitamin E, constituting an important part of the cellular water-soluble antioxidant capacity together with glutathione (Halver 2002; Waagbø 2010). Generally, several benefits have been attributed to LAA supplementation in fish diets such as enhanced growth, survival, reduction of skeletal anomalies, immunoactivity and stress response (Dabrowski 1992). For a deep insight into the dietary effects of LAA on the above-mentioned performance parameters in several fish species and stages of development, readers are encouraged to consult the review of Darias *et al.* (2011a), since the impact of LAA in skeletogenesis is the only issue covered by this section.

Most of the available information dealing with the effects of dietary LAA on bone health has been reported in fish juveniles from different species fed compound diets in which diets deficient in LAA were tested (Tacon 1995; Halver 2002). Thus, LAA deficiency signs in fish are generally related to impaired collagen synthesis, resulting in hyperplasia of the collagen and cartilage, and consequently, scoliosis, lordosis, opercular resorption, abnormal support cartilages in gills, spines, and fins, and hyperplasia of the jaw and snout (Halver 2002). In marine fish species that depend on live food at the onset of exogenous feeding, there exist no studies on the effects of LAA in early fish morphogenesis (Moren *et al.* 2011). Most of these studies in fish larvae were more focused on establishing the nutritional requirements of LAA in terms of growth, stress resistance, survival and/or LAA deposition in larval tissues (Merchie *et al.* 1995, 1996; Terova *et al.* 1998). However, there is a comprehensive study that evaluates the effects of dietary LAA on the skeletogenesis process and the development of skeletal disorders in fish larvae (Darias *et al.* 2011b). The former authors fed European seabass larvae with microdiets containing graded levels of LAA (5, 15, 30, 50 and 400 mg LAA kg<sup>-1</sup> microdiet) from first feeding to 45 days after hatching and evaluated the effects of dietary LAA levels on skeletogenesis, the development of skeletal disorders and the degree of ossification of the skeleton, among other parameters. In brief, Darias *et al.* (2011b) found that LAA especially affected skeletal elements that underwent chondral ossification (i.e. maxillary, caudal fin complex, proximal pterygiophores of dorsal and anal fins)

rather than those skeletal structures undergoing intramembranous ossification. Dietary levels of LAA lower than  $30 \text{ mg kg}^{-1}$  diet were not enough to match the larval needs for collagen biosynthesis and bone ossification; therefore, larvae were predisposed to develop skeletal anomalies. The incorrect development of some of these structures in their initial stages of development lead to the appearance of anomalies later on, such as the joint of the haemal processes to form the haemal arches or the formation of epurals and specialized neural arches. In contrast, skeletal elements that formed late in ontogeny and/or underwent intramembranous ossification, such as vertebral column, were less influenced by the extreme doses of LAA tested. Indeed, these authors were not able to find a correlation between the levels of dietary LAA and the development of lordosis, scoliosis and kyphosis. In addition to these results, the quantification of the ossification degree in conjunction with gene expression results suggested that both low ( $30 \text{ mg kg}^{-1}$ ) and high ( $400 \text{ mg kg}^{-1}$ ) dietary levels of LAA led to poor mineralization or delayed ossification in European seabass larvae. It was also noted that different LAA levels induced a different percentage and type of anomaly. There were anomalies specific for both low and high levels of LAA, such as anomalies of the proximal pterygiophores of dorsal and anal fins, and severe anomalies in the caudal fin complex, specially affecting the specialized neural arch and urostyle. However, low LAA levels specifically caused cartilage damage characterized by unformed haemal arches and 'cartilaginous vertebrae', among other skeletal abnormalities, such as jaw anomalies and the loss of one vertebra. In contrast, high LAA levels also caused pugheadness and the development of a supernumerary vertebra, although the overall degree of skeleton ossification was lower than in those fed  $50 \text{ mg LAA kg}^{-1}$  diet. Finally, Darias *et al.* (2011b) concluded that European seabass larvae required a minimum amount of  $15 \text{ mg LAA kg}^{-1}$  diet to survive,  $30 \text{ mg kg}^{-1}$  diet to attain maximal growth and  $50 \text{ mg kg}^{-1}$  diet for adequate morphogenesis of the skeletal tissue.

**Fat soluble vitamins.** The fat-soluble vitamins, A, D, E and K, are absorbed in the intestine along with dietary lipids; therefore conditions favourable for lipid absorption also enhance the absorption of fat-soluble vitamins. Fish store this group of vitamins, either actively in specific cell compartments or by simple accumulation in the lipid compartment, if dietary intake exceeds metabolic needs. This situation can result in an excessive accumulation of these vitamins in tissues to produce a toxic condition (hypervitaminosis). Although this has only been demonstrated in laboratory conditions with fish juveniles, it is unlikely to occur under practical conditions (NRC 2011), and is likely to occur in fish larvae. Considering the high growth and meta-

bolic rates during the larval period, it was assumed that vitamin requirements of fish larvae were higher than those of juveniles. Higher levels of vitamins are generally incorporated into larvae feeds, microdiets or live preys enriched with tailor-made or commercial enriching emulsions, the most common level used being eight times the requirement of juvenile fish (Mazurais *et al.* 2008); however, there are still important gaps of knowledge regarding the nutritional requirements for vitamins in fish larvae, and several studies seemed to indicate that the level of incorporation of vitamins in diets for fish larvae exceeds their nutritional needs, resulting in reduced growth, delayed maturation of the digestive system and a high incidence of skeletal anomalies (Haga *et al.* 2004a,b; Villeneuve *et al.* 2005a; Mazurais *et al.* 2009; Darias *et al.* 2010; Fernández & Gisbert 2011, among others).

Vitamin A is an essential nutrient during the complete lifecycle in all chordates. The term vitamin A is used to designate any compound possessing the biological activity of retinol (alcohol form), whereas the term retinoids applies to a group of morphogenetic nutrients that include all compounds that possess the same biological activity as retinol (Ross *et al.* 2000). Beta-carotene and other carotenoids that can be converted by the body into retinol are referred to as provitamin A carotenoids or just carotenoids. There are two primary active forms of retinoids: the retinal form (11-*cis*-retinal, aldehyde form) used as the chromophore of rhodopsin in the eye; and the retinoic acid (RA, acid form), the main active metabolite of vitamin A that plays the other non-visual functions of this vitamin (Ross *et al.* 2000). This fat-soluble vitamin has numerous important functions, including a role in vision, maintenance of epithelial surfaces, immune competence, reproduction, and embryonic growth and development (Ross *et al.* 2000). The basis of these functions appears to be gradients of RA created by specialized cells that degrade or produce RA from retinol. Then, the RA diffuses into the surrounding tissues and creates a gradient over the organ or embryo. The *in situ* RA concentration seems to be a signal to individual cells, modulating their pattern of gene expression, differentiation and proliferation through ligand-activated nuclear receptors (Germain *et al.* 2006a,b).

Considering that fish are not able to synthesize vitamin A, they have to obtain it from the diet at the optimum level, in the form of carotenoids from vegetal and/or as retinyl esters, such as retinyl palmitate or retinyl acetate (synthetic form), or as xanthines, from animal sources. In general, retinoids and their precursors (carotenoids) are absorbed from the diet by means of a complex metabolism, which includes a high number of transport proteins and enzymes, that tightly control retinoid absorption, transport, accumulation and conversion to their active forms (see a detailed and comprehensive review in Rodrigues *et al.* 2004). Most

of the numerous activities of this vitamin are due to the action of all-*trans* retinoic acid (atRA) and its 9-*cis* isomer (9-*cis* RA). Two classes of receptors convey the activity of RA. The retinoic acid receptors (RARs) bind atRA and 9-*cis* RA. This class is well-characterized for its predominant but not exclusive role in embryogenesis and organogenesis. The second class corresponds to the retinoid X receptors (RXRs) that bind 9-*cis* RA only. Both RARs and RXRs belong to the nuclear receptor superfamily, the largest class of transcription factors. By the specific binding of RA isomers to the RAR and RXR, they form homo- such as RXR/RXR or hetero-dimers (with other nuclear receptors such as THR, VDR and PPAR $\gamma$ ) that bind to specific nucleotide sequences (retinoic acid response elements, RAREs) in the promoter region of a large number of genes (Balmer & Blomhoff 2002). By direct gene expression regulation through the exhibition of a retinoic acid response element in the gene promoter or through downstream signalling cascade, retinoic acid could control directly or indirectly the transcription of more than 300 genes (Balmer & Blomhoff 2005). Through the stimulation and inhibition of transcription of specific genes, RA plays a major role in cellular differentiation (Fernández 2011). For a deeper revision of the molecular pathways involving vitamin A in the induction of skeletal anomalies in fish larvae, readers are encouraged to consult Haga *et al.* (2002, 2003); Villeneuve *et al.* (2005a, 2006), Laue *et al.* (2008), Fernández (2011), Fernández *et al.* (2011) and Haga *et al.* (2011).

A certain intake of vitamin A is essential for good health in fish, including that of the embryo and the larvae at early life stages of development, but both deficiency and excess can cause problems. Excessive intake of vitamin A, in the range 5–10 times the requirement, may disturb the same functions for which it is vital (NRC 2011). Hypovitaminosis A is characterized in fish by poor growth, anorexia, visual impairment (clouding and thickening of corneal epithelium, degeneration of the retina, xerophthalmia and eye haemorrhages), keratinization of the epithelial tissues, haemorrhages at the base of the fins, and abnormal bone formation (Halver 2002; NRC 2011). An excess of this fat-soluble vitamin has been associated with an enlargement of the liver and spleen, anaemia, abnormal growth, skin lesions, epithelial keratinization, hyperplasia of the head cartilage, and abnormal bone formation, resulting in ankylosis, fusion of vertebrae and severe lordosis and scoliosis (Halver 2002).

When considering fish larvae, most studies deal with the effects of hypervitaminosis A due to the inherent difficulties in working with live prey and the impossibility of reducing the content of this nutrient in live prey without affecting their lipid and fatty acid nutritional value (Giménez *et al.* 2007). There is scarce information on the effects of suboptimal levels of dietary vitamin A on fish skeletogenesis. In a

first study dealing with hypovitaminosis A in European seabass larvae, Villeneuve *et al.* (2005a) fed larvae with 0.011 mg all-*trans* retinol g<sup>-1</sup> diet and found a moderate incidence of skeletal anomalies, similar to that of the control group (0.031 mg all-*trans* retinol g<sup>-1</sup>), but worse growth and development of their digestive function. Anomalies affecting European seabass fed hypovitaminosis A were mainly concentrated in the maxillary and opercular bones, whereas in fish fed 0.031 mg all-*trans* retinol g<sup>-1</sup> showed a higher incidence of anomalies affecting the skeletal elements composing the neurocranium. In a recent study, Mazurais *et al.* (2009) showed that suboptimal dietary vitamin A content (0.001 mg all-*trans* retinol g<sup>-1</sup> diet) implied a lower Hoxd-9 gene expression that could explain why fish fed vitamin A deficient diet presented a partial or complete lack of the pelvic fin. The above-mentioned dietary regulation of Hox genes expression by vitamin A has also been reported previously in other marine fish species such as Japanese flounder *Paralichthys olivaceus* (Suzuki *et al.* 1999). In contrast, Villeneuve *et al.* (2005a) showed that an excess of dietary levels of vitamin A (0.196 mg all-*trans* retinol g<sup>-1</sup>) diet in European seabass resulted in a fourfold increase of the incidence of anomalies affecting the neurocranium and maxilla, whereas no significant increase was observed with regards the anomalies affecting the vertebral column in relation to those observed in the control group (0.031 mg all-*trans* retinol g<sup>-1</sup>). The former authors also observed a linear correlation between the dietary vitamin A level in larval tissues and the incidence of skeletal disorders that was linked to a modification of several nuclear receptors of the RA such as in RXR $\alpha$ , RAR $\alpha$  and RAR $\gamma$  expression patterns, and they concluded that the optimal dietary retinol level for the harmonious development of European seabass larvae was close to 0.031 mg g<sup>-1</sup> diet. The effect of dietary vitamin A on European seabass larval performance and skeletogenesis does not depend on the dietary level of this vitamin but also on the larval developmental stage at which the nutritional vitamin A imbalance is applied, as was demonstrated by Villeneuve *et al.* (2006). In this sense, larvae fed hypervitaminosis A (32 all-*trans* mg g<sup>-1</sup> diet) from 8 to 13 days after hatching exhibited a significant increase in skeletal anomalies localized to the cephalic region, as well as to the vertebral column (the loss of one vertebra) in contrast to those fish fed the control diet (0.08 all-*trans* mg g<sup>-1</sup> diet). These changes in the normal development of the skeleton in those larvae were correlated with a high expression of RAR $\gamma$ , RXR $\alpha$  and BMP-4, although the disruption of the expression in other genes, particularly other retinoid receptor isoforms not analysed in that study, could have taken place and affected the normal development of the skeleton in larvae. In addition, the results from the study of Mazurais *et al.* (2009) revealed that the retinol levels for the optimal

development of European seabass larvae depend to a great extent on the skeletal elements under consideration and their timing of differentiation/type of ossification. Thus, the frequency of jaw and hyoid anomalies was minimized for dietary retinol levels lower than  $0.003 \text{ mg g}^{-1}$ , whereas vertebral and fin elements developed better when retinol levels were equal to or higher than  $0.003 \text{ mg g}^{-1}$ . These levels of retinol were much lower than those reported by Villeneuve *et al.* (2005a), although Mazurais *et al.* (2009) concluded that it was not possible to compare data from both studies due to the elevated growth rates of larvae from the other study (three times higher to those usually observed), which could have induced a higher and unusual nutritional requirement of vitamin A in this species.

In gilthead seabream larvae fed enriched rotifers with increasing levels of vitamin A (75, 109, 188 and 723 ng total vitamin A  $\text{mg}^{-1}$  rotifer DW) from 2 to 18 dph, Fernández *et al.* (2008) found a significant and positive correlation between vitamin A levels and the incidence of skeletal anomalies in the premaxilla, maxilla, dentary and opercular bones of early juveniles (60 dph). Fish fed higher levels of vitamin A (109, 188 and 723 ng  $\text{mg}^{-1}$  rotifer DW) showed a supranumerary vertebra in the caudal region, between the urostyle and vertebra number 23. The incidence of lordotic, kyphotic and scoliotic specimens increased with increasing dietary levels of vitamin A, the compression of vertebral bodies being more frequent than fusions. Independent of the dietary level of vitamin, the caudal region was the area most affected by compression and fusion of the vertebral bodies. Vertebral fusions and changes in the number of vertebrae were attributed to a defect of notochord segmentation and disruption of vertebral centrum differentiation (Haga *et al.* 2009), potentially resulting from a vitamin A-induced accelerated skeletogenesis (Mazurais *et al.* 2008). Finally, the skeletal elements in the caudal fin complex most affected were the specialized neural arch, epurals, hypurals and parahypurals, and the uroneural. In most cases, anomalies consisted in twisted or undeveloped skeletal elements and their fusion with adjacent ones.

Regarding the specific effects of dietary vitamin A on Senegalese sole skeletogenesis, Fernández *et al.* (2009) found that feeding larvae with high vitamin A doses (24.8 and 60.9 ng total vitamin A  $\text{mg}^{-1}$  *Artemia* DW) from 6 to 37 dph (*Artemia* feeding phase) led to an increase of deformed fish and the percentage of fish showing more than one anomaly, which was correlated to an increase in the dietary body vitamin. However, in contrast to what was observed in gilthead seabream and other species (Haga *et al.* 2002; Fernández *et al.* 2008), no jaw anomalies were observed in any larval group, suggesting that the dietary vitamin A imbalance was applied at a non-critical developmental stage for jaw skeletogenesis (most skeletal elements

of the jaws were ossifying before feeding larvae with *Artemia*), and/or the tested vitamin A dietary contents in *Artemia* were not high enough to affect jaw development. In addition, Fernández and Gisbert (2010) showed that skeletal structures undergoing chondral ossification such as neural and haemal spines, epural, parahypural and hypurals were more sensitive to high dietary vitamin A levels than dermal bones (vertebral bodies).

Considering several nutritional studies dealing with vitamin A and enriched live prey, in gilthead seabream fed enriched rotifers from 2 to 18 dph, the safe dietary vitamin A content was reported as  $30 \text{ mg retinol g}^{-1}$  (Fernández *et al.* 2008), whereas in Senegalese sole fed enriched *Artemia metanauplii* from 6 to 37 dph, it was  $0.013 \text{ mg retinol g}^{-1}$  (Fernández *et al.* 2008, 2009). These results suggest a wide range of dietary vitamin A values depending on the species and developmental stage considered, although these studies are barely comparable due to the use of different experimental dietary levels and forms of vitamin A, feeding protocols and types of live prey (Fernández 2011). In addition, the effects of dietary vitamin A on skeletal development mainly depend on the levels of each vitamin A form included in the diet and not the total vitamin A content, as diets containing higher total vitamin A levels mainly in the form of retinyl acetate resulted in lower toxicity than those with lower total vitamin A content, where retinol, retinyl palmitate and retinoic acid were the vitamin A compounds primarily present in the diet (Takeuchi *et al.* 1998).

Although the teratogenic effect of vitamin A is well studied and characterized in temperate fish species and fish tend to develop skeletal anomalies in the presence of excess vitamin A, what seems to separate coldwater marine species from temperate ones is that they tolerate much lower levels of vitamin A in their diet before adverse effects are observed (Moren *et al.* 2004). While vitamin A in excess introduces anomalies, low levels do not seem to affect negatively cod or Atlantic halibut larvae as long as the diet contains carotenoids (Moren *et al.* 2004, 2011). *In vitro* studies, using cod lower jaw explants, have revealed that vitamin A (as retinoic acid) decreases the osteoblast activities and increases the osteoclast activity, probably through alteration of the OPG/RANKL system (Lie & Moren 2012). Clearly, vitamin A is essential in the regulation of skeletal growth, but these responses may be altered by other nutrients (Enric Gisbert, pers. comm.), as well as pollution: Olsvik *et al.* (2011) showed that cod larvae exposed to oil spill had severely reduced expression of genes involved in bone growth and an increased expression of genes important in bone degradation.

Summarizing, different studies dealing with microdiets and enriched live prey have shown that dietary vitamin A is responsible for the development of various types of skeletal anomalies, affecting the head, vertebral column and fins of



fish larvae in Japanese flounder (Dedi *et al.* 1995; Takeuchi *et al.* 1995; Haga *et al.* 2002), European seabass (Villeneuve *et al.* 2005a, 2006; Mazurais *et al.* 2009), Senegalese sole (Fernández *et al.* 2009; Fernández & Gisbert 2010) and gilt-head seabream (Fernández *et al.* 2008). Cranial anomalies affected the maxillary and premaxillary bones (pugheadness), dentary (shortening of the lower jaw), operculum (inside folding), branchiostegal rays (curvature) and glossohyal (lateral or ventral transposition). Vertebral anomalies consisted of compressed and fused vertebrae, over-mineralization of vertebral bodies, kyphosis and lordosis of the haemal vertebrae, as well as of the transformation of a prehaemal vertebra into haemal in European seabass. Loss of caudal fin and supranumerary caudal fin rays was observed in Japanese flounder, whereas fin anomalies concerned abnormalities of the dorsal and anal pterygiophores, associated or not with severe deviations of the related rays, slight (slight fusion between two elements) or severe (extensive fusions, dislocations, shape alterations) modifications of the anatomy of the caudal supporting elements (parahypural, epurals, hypurals, urostyle and pre-ural centra) in Senegalese sole, European seabass and gilt-head seabream, as well as partial to complete lack of the pelvic fins in European seabass. In addition to the above-mentioned skeletal disorders induced by dietary vitamin A, Georga *et al.* (2011) demonstrated that the levels of this vitamin during the larval stage have a significant effect on the skeleton shape of normal juveniles.

Vitamin D is essential for maintaining calcium and inorganic phosphate homeostasis and protecting bone integrity; it also stimulates the absorption of calcium from the intestinal mucosa, and influences the action of parathyroid hormone on skeletal tissues (Halver 2002). In contrast to mammals that are able to synthesize vitamin D from a cholesterol derivative through photosynthesis in the skin under ultraviolet B radiation exposure, fish cannot synthesize vitamin D from solar energy because all traces of irradiation are absorbed by sea water in the first few metres from the surface (Lock *et al.* 2010). Two main natural forms of vitamin D are vitamin D<sub>2</sub> or ergocalciferol that only occurs in plants, and vitamin D<sub>3</sub> or cholecalciferol that occurs in animals. Vitamin D<sub>3</sub> itself is not physiologically active; it has to undergo one or two hydroxylations to form the more polar metabolites 25-hydroxyvitamin D<sub>3</sub> (25(OH)D<sub>3</sub>) or 1 $\alpha$ ,25-dihydroxyvitamin D<sub>3</sub> (1,25(OH)<sub>2</sub>D<sub>3</sub>; calcitriol) and 24R,25-dihydroxyvitamin D<sub>3</sub> (24,25(OH)<sub>2</sub>D<sub>3</sub>), respectively (NRC 2011). Most, if not all, actions of this vitamin are mediated through a nuclear transcription factor known as the vitamin D receptor (VDR) (for further details, see Hamre *et al.* 2013 and Rønnestad *et al.* 2013).

In salmonid species, vitamin D deficient diets have been correlated with reduced growth and feed efficiency, anorexia, tetany, elevated liver/muscle lipid content and

impaired calcium homeostasis in juveniles (Tacon 1995; Halver 2002). Being a calcitropic hormone, the main task of vitamin D<sub>3</sub> is to regulate plasma calcium levels. Indeed, several genes involved in the control of calcium uptake are regulated by calcitriol, e.g. the epithelial calcium channel, found in both the intestine and the gills (Hamre *et al.* 2010). Regarding fish larvae and early juveniles, very few studies exist of the role of this vitamin on the development of skeletal anomalies. Haga *et al.* (2004b) reported that early juveniles of Japanese flounder fed a dietary excess of vitamin D<sub>3</sub> (21 vs. 1.8 IU g<sup>-1</sup> from the control diet) showed an increase in skeletal disorders mostly consisting in the winding of the vertebral bodies caused by abnormal calcification and impairment of their rigidity. In a recent study of European seabass fed microdiets containing graded levels of vitamin D<sub>3</sub> (11, 28, 42 and 140 IU g<sup>-1</sup> diet), Darias *et al.* (2010) found an impact of dietary vitamin D<sub>3</sub> on the European seabass digestive system ontogenesis that consequently conditioned the ossification process and skeletogenesis. In this sense, the former authors found a significant correlation between the levels of osteocalcin gene expression and those of TRPV6, a membrane calcium channel that is responsible for the first step in calcium absorption in the intestine. Thus, they hypothesized that impaired intestinal Ca<sup>2+</sup> absorption together with the low level of osteocalcin expression could induce poor bone mineralization and lead to skeletal anomalies. In that study, two distinct response patterns regarding skeletal anomalies were observed considering the level of dietary vitamin D<sub>3</sub>: vertebral and branchiostegal anomalies were maximized in those larvae fed both the extreme levels of vitamin D<sub>3</sub> (11 and 140 IU g<sup>-1</sup> diet), whereas, pugheadness (deformed maxillary and premaxillary elements) and caudal-fin anomalies were maximized in only fish fed 11 IU g<sup>-1</sup>. These results could suggest that skeletal elements developed at the early developmental stages (such as jaws and caudal fin elements) were less prone to the effect of high vitamin D<sub>3</sub> levels than those developing at later stages of development (vertebrae and branchiostegal rays). Summarizing, based on the changes of gene expression of bone morphogenetic protein 4 (BMP-4), osteocalcin, VDR and TRPV6, as well as growth performance and the incidence of skeletal anomalies, Darias *et al.* (2010) concluded that the level of dietary vitamin D<sub>3</sub> in European seabass larvae should be close to 28 IU g<sup>-1</sup> in order to obtain an harmonious larval growth and morphogenesis.

Finally, the interactions of vitamins A and D<sub>3</sub> and their metabolites have to be considered together in future studies, since both fat-soluble vitamins share several tissues, including bone, as common targets of their action. In this sense, in several mammalian species an antagonistic action has been observed between retinoic acid and 1 $\alpha$ ,25-dihydroxyvitamin D<sub>3</sub> (Lock *et al.* 2010).

Vitamin K (VK) belongs to the lipid soluble vitamins, and occurs naturally as phyloquinone (vitamin K<sub>1</sub>) that is synthesized by plants, and menaquinone (vitamin K<sub>2</sub>) synthesized by bacteria. In addition, there is a synthetic provitamin, menadione (vitamin K<sub>3</sub>), primarily used as a vitamin K source in animal feed. Vitamin K has been shown to be essential to bone metabolism through its role in the gamma-carboxylation of skeletal vitamin K-dependent proteins such as osteocalcin (Oc) and matrix Gla protein (Mgp) (Price 1988) and through its role in skeletal gene transcription via pregnane X receptor (PXR, the vitamin K receptor; Azuma *et al.* 2010). However, mechanisms associated with the osteogenic and skeletogenic activity of vitamin K in fish are still poorly understood and the nutritional requirement remains to be determined.

Vitamin K-dependent proteins (VKD) have been detected in many tissues and it has become clear that vitamin K plays an important role in many biological processes (see Hamre *et al.* 2013 and Rønnestad *et al.* 2013), such as bone metabolism and growth control (Krossøy *et al.* 2011). Several vitamin-K dependent proteins are present in bone and cartilage: osteocalcin (Oc or bone Gla protein; BGP), Gla rich protein (GRP), matrix Gla protein and protein S, being the important players in bone health, extracellular matrix mineralization and skeletogenesis.

The major clinical signs of vitamin K deficiency in all studied species are anaemia and impaired blood coagulation. In addition, in animals that are vitamin K deficient, the Gla proteins are incompletely formed or not formed at all, rendering the Gla proteins inactive. This results in under-carboxylated vitamin K-dependent proteins that can lead to uncontrolled, extensive bleeding and internal haemorrhaging, cartilage calcification, bone anomalies in developing bone, and the presence of insoluble calcium salts in arterial vessels (Lall & Lewis-McCrea 2007). Regarding the effects of dietary vitamin K on bone in fish larvae and juveniles, only a few studies have dealt with this topic (Graff *et al.* 2002; Udagawa 2006; Roy & Lall 2007; Krossøy *et al.* 2009). In haddock *Melanogrammus aeglefinus* juveniles, Roy and Lall (2007) showed that vitamin K deficiency decreased bone mineralization and increased the occurrence of bone anomalies, without affecting the number of osteoblasts (measured by histomorphometry) in the vertebrae. Diets without vitamin K supplementation caused a higher incidence of anomalies in the vertebral column and caudal skeleton in mummichog *Fundulus heteroclitus* larvae. More specifically, vitamin K deficiency caused the formation of thin and weak bone, and induced bone structure abnormalities, such as vertebral fusion and row irregularity, as well as anomalies in the neural and haemal arches, both in early development and during later growth (Udagawa 2006). In contrast, no signs of vertebral anomalies

were observed in first-feeding fry of Atlantic salmon (Krossøy *et al.* 2009) fed increasing levels of menadione sodium bisulphite salt (0–0.05 mg vitamin K<sub>3</sub> g<sup>-1</sup> diet). The former authors concluded that the minimum vitamin K requirement in Atlantic salmon fry for normal growth and bone development was 0.01 mg g<sup>-1</sup> diet. However, no data are available about the minimum and optimum levels of dietary vitamin K to support normal growth and development of the skeletal tissue in marine fish larvae. It was shown that a nutritional imbalance (deficiency or excess) affects bone mineralization, bone mass and increases vertebral anomalies (Udagawa 2001). In addition, the effects of vitamin K on the nutritional status of adults have been related recently to larval quality (Udagawa 2004). It was observed that in larvae from mummichog fed a vitamin K-deficient diet showed a higher incidence of vertebral abnormalities than larvae from fish fed a vitamin K-rich diet. Larvae that were reared on a vitamin K-deficient diet showed a thin and weak vertebral bone (Udagawa 2004). Moreover, the use of phyloquinone (VK1) as a vitamin K metabolite for diets was shown to be more appropriate than menadione (VK3) (Udagawa 2001). Surprisingly, there is no research aimed at understanding the effects of vitamin K imbalance during the early stages of development, and determining the underlying mechanisms of skeletal anomalies.

The term vitamin E is a generic descriptor for all molecules that possess the biological activity of  $\alpha$ -tocopherol. There is an extensive and recent review on the role and dietary requirements of vitamin E in fish (Hamre 2011). In brief, this vitamin functions as a chain breaking antioxidant, reacting with lipid peroxide radicals and preventing further reaction with a new HUFA. In addition, vitamin E plays an important role in the fish immune response, reproduction, stress resistance and larval growth. The main deficiency signs of vitamin E in several fish species are similar and include muscular dystrophy, oedema of heart, muscle and other tissues, anaemia, body depigmentation and ceroid pigment accumulation in the liver (NRC 2011). For fish larvae, the main results on the effects of dietary vitamin E were reported in gilthead seabream and European seabass by Atalah *et al.* (2012) and Betancor *et al.* (2011), respectively. Betancor *et al.* (2011) fed European seabass larvae with diets containing different ratios of DHA (22:6n-3) to vitamin E and found that increasing the level of DHA increased the incidence of muscular degeneration, while adding extra vitamin E at the high DHA levels reduced the incidence of muscular pathology. However, considering that fish larvae are very sensitive to oxidative imbalances due to their high oxidative metabolism, fast growth and/or high requirements for PUFA, the role of this fat-soluble vitamin in bone homeostasis and development might not be negligible, although no current

data are available on the effects of vitamin E in fish larval skeletogenesis. As Lall and Lewis-McCrea (2007) recently reviewed, vitamin E may be important for proper skeletal development, especially to combat endogenous and exogenous free radicals that can cause damage to osteoblasts and stimulate osteoclasts, as data from mammalian species seemed to indicate.

### Minerals

Information concerning mineral nutrition of fish is limited compared with most other nutrient groups (for review, see NRC 2011). Problems associated with the quantification of mineral requirements include the identification of the potential contribution of minerals from the water, leaching of minerals from the diet prior to consumption, availability of suitable test diets that have a low concentration of the targeted mineral and the limited data on mineral bioavailability. Moreover, the uptake of minerals from the diet or aquatic medium and excretion of minerals in the urine or faeces are influenced by osmoregulatory processes in response to salinity of the aquatic medium, which can lead to differences in the metabolism of certain minerals between freshwater and marine species. However, like terrestrial animals, fish have been shown to require minerals for their normal life processes such as the formation of skeletal structures, maintenance of colloidal systems, regulation of acid-base equilibrium and as important components of hormones, enzymes and co-activators of enzymes. Minerals can be divided into two groups: (i) macrominerals, found at high concentrations and required in gram amounts including calcium (Ca), chloride (Cl), magnesium (Mg), phosphorus (P), potassium (K) and sodium (Na), and (ii) trace elements, occurring in the body at much lower concentrations such as chromium (Cr), copper (Cu), iodine (I), iron (Fe), manganese (Mn), selenium (Se) and zinc (Zn) recognized to be essential in fish (for review, see Watanabe *et al.* 1997; Lall 2002). Other elements have also been claimed to be essential, but their essentiality remains to be confirmed in fish.

**Macrominerals.** Among the macrominerals, only phosphorus, calcium and magnesium have been shown to affect skeletogenesis process in fish (for review, see Lall 2002; Lall & Lewis-McCrea 2007; Lewis-McCrea & Lall 2010; NRC 2011). Indeed, phosphorus and calcium function primarily as structural components of hard tissues (e.g. bone, exoskeleton, scales and teeth) and are closely related to the development and maintenance of the skeletal system. Magnesium, that is mostly located in the bone, is also required in skeletal tissue metabolism.

**Phosphorus** is probably the most studied mineral in fish nutrition. In addition to its structural functions, phosphorus (P) is a component of a variety of organic phosphates,

such as nucleotides, phospholipids and coenzymes, playing a major role in many metabolic processes. Dietary phosphorus supplies most of the phosphate required for growth and metabolism, as the concentration of phosphorus is low in both seawater and freshwater (Lall 2002). The absorbed phosphorus accumulates in soft tissues and deposition in skeletal tissue is relatively low. Signs of dietary phosphorus deficiency include reduced growth, decreased feed efficiency, poor bone mineralization and skeletal abnormalities (for review, see Lall 2002; Sugiura *et al.* 2004; Lall & Lewis-McCrea 2007; NRC 2011). Common skeletal anomalies include curved spines, soft bones, twisted pleural ribs, compressed vertebral bodies that can result in scoliosis and cephalic anomalies. Poor growth, deformed operculum, decreased bone mineralization and increment in whole body lipid content were reported in juvenile Japanese flounder fed a fed P-deficient diet (Uyan *et al.* 2007). A deficiency of available dietary phosphorus in Atlantic salmon fry has been suggested to cause spinal anomaly (Sullivan *et al.* 2007). In rainbow trout fry, dietary phosphorus deficiency resulted in whole body phosphorus depletion and mineralization defects with a lowered calcification of both endochondral and dermal skeleton, resulting in irregular placement of vertebrae with twisted arches (Fontagné *et al.* 2009). The dietary phosphorus requirements of fish species have been reported to range from 0.3% to 1.5% of diet (Lall 2002). The dietary phosphorus concentration has been identified as a critical factor in the development of bone anomalies. In Atlantic salmon, Fjelldal *et al.* (2009) recommend extra mineral supplementation in the early sea water phase to reduce the prevalence of vertebral anomalies in fast-growing underyearling (0+) smolts and Bæverfjord *et al.* (1998) and Helland *et al.* (2005) showed that in Atlantic salmon juveniles fed insufficient dietary phosphorus, undermineralized but normally shaped vertebrae were found (as confirmed later by Gil Martens *et al.* 2011, on the same species) so enhancing that P supplementation may reduce the prevalence of anomalies, but its dietary deficiency is not necessarily a causal but a concausative factor. On the other hand, high concentrations of dietary P and Ca have been shown to interfere with the absorption and retention of Mg and certain trace elements and if a high dietary P level (2.2%) was associated with a reduced incidence of internal skeletal abnormalities in rainbow trout fry, it also induced an impairment of survival (Fontagné *et al.* 2009).

**Calcium**, in addition to its structural functions, is essential for blood clotting, muscle function, proper nerve impulse transmission, osmoregulation and as a cofactor for enzymatic processes (Lall 2002). Unlike terrestrial animals, the major site of calcium regulation in fish is not in the bone but in gills, fins and oral epithelia tissues. Dietary Ca deficiency, that is usually quite uncommon due to the pres-

ence of this ion in the water, resulted in reduced growth, poor feed conversion, anorexia and reduced bone mineralization (for review, see Lall 2002 and NRC 2011). The reduced bone mineralization has been reported only for blue tilapia *Tilapia aurea* (now *Oreochromis aureus*) fingerlings fed diet containing <0.65% Ca in Ca-free water (Robinson *et al.* 1984). On the other hand, dietary Ca deficiency has been reported to induce a delay in the ontogeny of skeletal development of rainbow trout fry without affecting final bone mineralization but leading to modifications in the shape and size of vertebrae (smaller vertebrae in the anterior and mid-region of the vertebral column and irregular placement of the vertebrae in the column) compared with rainbow trout fry fed a diet containing 0.8% Ca (Fontagné *et al.* 2009). The requirement for proper bone mineralization has been shown to range between 0.34% and 1.5% for different freshwater and marine fish species; however, no specific data concerning larval stages are available. Moreover, as mentioned above, different factors have been suggested to affect Ca metabolism such as valine, vitamin D but also fluoride (Camargo 2003) or heavy metals (Berntssen *et al.* 2003). For instance, cadmium has been shown to induce disturbance of Ca homeostasis in Atlantic salmon parr without leading to bone anomalies (Berntssen *et al.* 2003), whereas spinal anomalies or altered axial curvature and tail anomalies were noticed in the early life stages of zebrafish (*Danio rerio*) and Australian crimson spotted rainbow fish (*Melanotaenia fluviatilis*) by Cheng *et al.* (2000) and Williams and Holdway (2000).

*Magnesium*, besides its role in skeletal tissue metabolism, osmoregulation and neuromuscular transmission, is an essential cofactor in many enzymatic reactions in intermediary metabolism. Dietary magnesium deficiencies have been documented for a variety of freshwater fish and include poor growth, high mortality, anorexia, lethargy, muscle flaccidity, convulsions, vertebral curvature and depressed Mg levels in the whole-body, blood serum and bone (Lall 2002). As seawater contains high levels of Mg that can be uptaken by fish to meet their metabolic requirement, marine species may not require a dietary source of Mg. For instance, a dietary Mg level of 0.04% was required to prevent skeletal anomalies (deformed snout and vertebral curvature) in juvenile channel catfish (Lim & Klesius 2003). In contrast, only 0.01% Mg was needed for proper bone mineralization of Atlantic salmon reared in brackish water and no signs of deficiency were observed in red seabream reared in seawater (NRC 2011). However, in contrast to Mg concentration, the ash, Ca and P concentrations in the whole body, vertebrae and scales were inversely related to the dietary Mg level in grass carp juveniles as in rainbow trout, tilapia and channel catfish, suggesting that Mg could reduce Ca absorption (Liang *et al.* 2012). These authors also reported decreased Zn and Fe contents in whole body

and vertebrae of grass carp juveniles fed with high levels of Mg (0.09%).

*Trace elements.* The role of trace elements in biological systems has been described in several animals. However, the knowledge in fish is mainly limited to iron, copper, manganese, zinc and selenium (Watanabe *et al.* 1997). Among these trace elements, only manganese, zinc and selenium have been shown to affect skeletogenesis process in fish (Watanabe *et al.* 1997; NRC 2011). Due to the role of thyroid hormones in developmental processes, iodine deficiency has been suggested as one possible reason for skeletal anomalies (Hamre *et al.* 2005; Solbakken *et al.* 2002) but so far no studies have shown that an improved iodine status gave a reduced level of skeletal abnormalities (Moren *et al.* 2006; Hamre *et al.* 2008; Ribeiro *et al.* 2011, 2012).

*Manganese* functions as a cofactor in several enzyme systems including enzymes involved in lipid, protein and carbohydrate metabolism and the highest concentration of manganese is found in bone. In vertebrates, Mn is essential for development of the bone and cartilaginous matrix, which is largely composed of mucopolysaccharides. Dietary deficiencies in fish resulted in poor growth, skeletal abnormalities, high embryo mortalities and poor hatch rates (Lall 2002). In carp fingerlings, low dietary Mn levels (<10 mg kg<sup>-1</sup>) induced short body dwarfism associated with a reduction of ash, Mn, P, Ca, Mg and Zn contents in vertebrae (Satoh *et al.* 1987). In red seabream larvae, Mn supplementation to *Artemia* nauplii (from 12 to 43 mg kg<sup>-1</sup> dry weight) has been shown to enhance growth and to promote normal skeletal development with a reduction of anomalies in neural spines and arches (Nguyen *et al.* 2008). According to these authors, supplementation with Mn through *Artemia* to red seabream larvae during the bone ossifying stage (total length: 6–19 mm) was more effective in promoting normal skeletal development than in the rotifer feeding stage, when most bones are still in the cartilage form.

*Zinc* is an important trace element in fish nutrition as it is involved in various metabolic pathways. Zinc functions as a cofactor in several enzyme systems and is a component of a large number of metalloenzymes. Dietary Zn deficiency in fish resulted in reduced growth, decreased digestibility of protein and carbohydrate, reduced appetite, impaired immunological response, eye lens cataract and erosion of fins and skin as well as short body dwarfism (for review, see Watanabe *et al.* 1997 and Lall 2002). Satoh *et al.* (1983) reported depressed growth, cataracts (100%) together with short body dwarfism (80%) in rainbow trout fry fed a Zn-deficient diet compared with diets containing 80 mg Zn kg<sup>-1</sup>. Depressed growth and increased incidence of anomaly in dorsal fin rays were observed in red seabream

larvae fed *Artemia* containing 119 mg Zn kg<sup>-1</sup> compared with enriched *Artemia* containing 423 mg Zn kg<sup>-1</sup> (Nguyen *et al.* 2008). The latter authors suggested that the beneficial effects of Zn supplementation on skeletal development could be due to the stimulation of osteoblastic bone formation and inhibition of osteoclastic bone resorption by Zn, as demonstrated *in vitro* in mammalian cell cultures. The minimum Zn requirement for proper development has been shown to vary with age, sexual maturity, water temperature, water quality and composition of diet (Lall 2002). As already mentioned, some minerals such as P, Ca and Mg can interfere with absorption and retention of Zn. On the other hand, Zn supplementation has been shown to decrease whole body Fe content in red seabream (Nguyen *et al.* 2008).

Selenium is an essential trace element for animals, including fish, but also has the smallest window of any element between requirement and toxicity. Selenium plays a pivotal role against oxidative cellular injury as a component of the enzyme family termed glutathione peroxidase, which converts hydrogen peroxide and lipid hydroperoxides into water and lipid alcohols, respectively (Watanabe *et al.* 1997; NRC 2011). Moreover, Se is a vital constituent of many other protein molecules with diverse physiological functions including the control of thyroid hormone production (e.g. deiodinases), transport proteins (e.g. selenoprotein P) and muscle physiology (e.g. selenoprotein W). Fish have 32–34 selenoproteins relative to 23–25 in terrestrial vertebrates and the physiological functions of some of these selenoproteins are yet to be characterized (Lobanov *et al.* 2008). Prior to the discovery of the essential role of Se, its toxic properties were well recognized (Lall 2002). High levels of Se exert their toxic effects in animals probably through competition with sulphur compounds or production of reactive oxygen species from the reaction with glutathione leading to oxidative stress (Misra *et al.* 2010). Selenium toxicity has been demonstrated in several fish species at dietary levels of 10–20 mg Se kg<sup>-1</sup> from sodium selenite or selenomethionine, resulting in reduced growth and high mortalities as well as renal calcinosis (NRC 2011). On the other hand, dietary Se deficiency has also been shown to result in depressed growth and mortality as well as reduced glutathione peroxidase activity, lipid peroxidation, lethargy, loss of appetite and reduced muscle tone (for review, see Watanabe *et al.* 1997 and Lall 2002). However, a combined deficiency of Se and the lipid-soluble antioxidant vitamin E was required to produce more overt deficiency signs such as exudative diathesis and muscular dystrophy (NRC 2011). In Atlantic cod larvae, Se supplementation to rotifers (3 mg Se kg<sup>-1</sup> similar to the level found in copepods) did not improve growth and survival or reduce the rate of skeletal anomalies but increased whole body levels of Se, and expression and activity of Se-depend

ent glutathione peroxidases suggesting that normally enriched rotifers do not meet the Se requirements of cod larvae (Penglase *et al.* 2010). However, the support of an optimum antioxidant status during fish larval development may be important to prevent the pathogenesis of skeletal disorders caused by lipid peroxidation.

#### Non-genetic factors: miscellaneous

Despite the significance of skeletal anomalies for finfish aquaculture, existing studies specifically targeted on their causative factors are rather rare. Environmental factors mainly cited for possibly causing skeletal anomalies in reared fish are the broodstock condition, egg quality, stock density, fast growth conditions, handling stress, hydrodynamism/water turbulence/water supply rate, rearing methodologies, light regimes, mechanical factors, oil films on water surface, levels of O<sub>2</sub>/CO<sub>2</sub>, pH, physical trauma/mechanical stress, pathogens, parasites, toxins, radiation, salinity variation, typology of substratum (mainly for flatfish), tank characteristics (volume, shape, colour, material), variation of temperature, antibiotics and xenobiotics.

Environmental non-nutritional factors have been invoked to explain the failure of swim bladder activation (for the presence of an oily film at the air–water interface of the tank) and vertebral axis deviations (water temperature and water currents). The presence of an oily film on the water surface during the first feeding and the preflexion stage, before the re-absorption of the pneumatic duct, has been proven to be the most important factor preventing the non-inflation of the swim bladder (Chatain & Ounais-Guschemann 1990). Secondly, salinity (Battaglione & Talbot 1993; Tandler *et al.* 1995), light intensity and quality, photoperiod (Battaglione *et al.* 1994; Chatain 1997), water turbulence (Chatain & Ounais-Guschemann 1990; Battaglione & Talbot 1993) and larval vigour have been imputed to influence the initial swim bladder inflation.

Concerning swim bladder over-inflation, stress due to disturbances of abiotic factors (Johnson & Katavic 1984; Katavic 1986), handling and transportation (Carmichael & Tomasso 1984) have been placed among the most crucial factors.

Water temperature is a critical factor for the successful hatchery production of poikilotherm organisms such as fish and it has significant effects on growth, differentiation and survival rates. Concerning skeletal anomalies, existing studies demonstrate a significant effect of water temperature during the early ontogeny of all the species examined so far. In gilthead seabream, Polo *et al.* (1991) demonstrated that water temperature during the embryonic and yolk-sac larval stages affects the development of early defects such as abnormalities of the primordial marginal finfold, jaws, notochord and pericardial oedema. In the same species,

Georgakopoulou *et al.* (2010) showed that water temperature up to the metamorphosis and juvenile phase has a significant effect on the development of inside folded gill-cover, haemal lordosis, as well as of the slight anomalies of the caudal and dorsal fin. In Senegalese sole the effects of temperature during the egg incubation stage were recently evaluated by Dionísio *et al.* (2012) revealing that temperatures higher than 18°C cause an increased incidence of anomalies affecting the vertebral column.

In European seabass, relevant existing literature is limited to the direct effects of water temperature on the development of anomalies of the branchiostegal rays (Georgakopoulou *et al.* 2007), gill-cover (Abdel *et al.* 2005) as well as of haemal lordosis (Sfakianakis *et al.* 2006b). Although haemal lordosis was initially attributed to the high water-current velocity during the early juvenile stage of European seabass (via the rheotactism and the following intense swimming activity of the fish, Divanach *et al.* 1997), Sfakianakis *et al.* (2006b) showed that the effects of temperature prevail upon those of current velocity. The effects of temperature on the development of haemal lordosis could, at least partially, be explained by the temperature-driven phenotypic plasticity of European seabass in respect to body shape (Koumoundouros *et al.* 2001; Georgakopoulou *et al.* 2007), muscle anatomy and swimming performance (Koumoundouros *et al.* 2009).

The investigation on the deleterious effects on skeletogenesis of inappropriate rearing temperatures is actually enhanced due to the practice of using higher rearing temperatures for fast-growing salmon. High water temperatures seems to affect the normal development of bone in salmon, whatever the life cycle stage at which it is applied, even after egg incubation: caudal vertebrae anomalies were found in salmon 4 months after the eggs were heat shocked (6–12°C; Wargelius *et al.* 2005). In other similar cases, no spinal anomalies but warped opercula, fin and jaws anomalies were observed. Grini *et al.* (2011) described severe vertebral compressions and fusions in the tail region in salmon maintained for the first 6 weeks in seawater at 16°C. The process underlying temperature-induced anomalies in salmon is only hypothesized by Wargelius *et al.* (2010): in fish reared at higher temperature, in the compressed vertebrae, notochord, compact and trabecular bone, MMP13 was significantly upregulated, 44 weeks after seawater transfer. Ytteborg *et al.* (2010) reported in high temperature reared salmon the down-regulation of extracellular matrix genes (collagen  $\alpha$ 1, osteocalcin, osteonectin and decorin) and Wargelius *et al.* (2009) the diminution of *shh* and *twist* expression. Sonic hedgehog (*shh*) protein is expressed in the notochord in the early embryo, it is involved in axial skeleton patterning and it is used as a marker for osteoblast proliferation (Wargelius *et al.* 2009). *Twist* codes for a transcription factor expressed in precu-

rior skeleton cells and it is involved in the control of epithelial-to-mesenchymal transition.

In fast growing conditions, salmon show some high charge of compressed and fused vertebrae and decreased bone quality, either in reducing the vertebral mineral content, yield-load or stiffness. Another hypothesized risk factor is linked to the possibility that fast growth conditions determine a too great mechanical stress on differentiating vertebrae due to chronic and unbearable muscle pressures acting on the axial skeleton during intensive growth (Deschamps *et al.* 2009). Sustained swimming at moderate speeds was shown to induce many positive effects on growth and swimming performances in salmonids, but little is known about its effects on vertebral remodelling processes and related hormonal regulation. Deschamps *et al.* (2009) described that slow growth (e.g. at a constant temperature of 7°C) favoured vertebral bone mineralization in rainbow trout when compared with normal (e.g. seasonal variations of temperature) and fast growth (e.g. at a constant temperature of 17°C), because the low vertebral bone area resulting from periods of fast growth (i.e. summer and beginning of autumn) was not counterbalanced by a subsequent increase in bone deposition during slow-growing periods (e.g. winter and spring). This may cause the changes observed in vertebral features, interpreted as a compromise between the necessity to mobilize vertebral mineral ions in response to various physiological demands and to maintain vertebral strength against mechanical constraints. However, the authors were not able to identify whether this increase in bone area resulted from changes of bone specific growth rate and/or bone mineralization rate in larger specimens, neither they can exclude that other concurrent factors (nutritional state in relation to mineral balance or some genetic cause due to selection of the reared trout for high growth rate through many generations) had played a role in the strong demineralization of the middle vertebral region.

Another solution recently adopted in salmon culture for forcing growth, suppressing the nocturnal production of melatonin and flattening out the diurnal pattern in melatonin secretion (observed under natural light conditions) foresees the use of continuous light. Atlantic salmon after 6 months under continuous light revealed a lower mineral content and mechanical strength in the vertebrae bone than under natural light (Fjelldal *et al.* 2005). Wargelius *et al.* (2009) hypothesized a mediation action exerted directly by melatonin on bone by action on membrane-bound receptors on osteoblast cells or through the function of melatonin in setting the suprachiasmatic circadian rhythm in the brain, as observed in mammals. Studies in mammals have reported that light manipulation changes the pattern of osteoblast proliferation and bone mass in response to changes in circadian pattern.

Concerning the effects of current velocity on the development of haemal lordosis, these were also documented in species such as red seabream (Kihara *et al.* 2002) and Atlantic cod (Baeverfjord *et al.* 2009).

As already mentioned, Izquierdo *et al.* (2010) formulated the hypothesis that lordosis onset in red porgy could be linked to the typical voracious behaviour of larvae belonging to this species: the large occurrence of haemal lordosis could be related to an insufficient feeding (with consequent skeleton weakness resulting from malnutrition) coupled to an excessive swimming effort of the larvae looking for food.

As far as hyperdense vertebrae are concerned, concausative factors have been considered by Helland *et al.* (2006) and later by Witten and Huysseune (2009).

Spinal anomalies have been reported as side effects of vaccination over the years in Atlantic salmon and factors such as time and fish size at vaccination, water temperature after seawater transfer, vaccine type, antigen concentration and adjuvant type can influence the severity of side effects. The operation for vaccination entails heavy mechanical stress due to handling of fish during vaccination, grading, pumping and transport. Fast-growing under-yearling smolts (so-called 0+ smolts or autumn smolts) have a reduced bone mineral content and lower mechanical strength (Fjellidal *et al.* 2006, 2007). So the mechanical stress for vaccination and selection may affect the integrity of the spine, and/or may induce local inflammation or bone microfractures that heal forming hyperdense vertebrae. At present, some debate is running on what is the primary cause of platyspondylic and ankylotic vertebra observed in salmon after vaccination: the injection (mechanical injury) or inflammation in the vicinity of the injection point induced by oil-adjuvants in vaccine (like human rheumatoid arthritis and/or osteoarthritis). In this scenario, Gil Martens *et al.* (2010) effectuated in 46 dph salmon: (i) injection of bacterial lipopolysaccharides strain (BLS: *Escherichia coli* 0111:B4) inducing a pro-inflammation picture; (ii) injection of phosphate-buffered saline (PBS, placebo); (iii) commercial vaccination; and (iv) no treatment. After injection, analyses of all the fish were carried out to find the presence of markers of inflammation in plasma and bone near the injection point. The results obtained showed evidence of higher frequencies of vertebral anomalies in the PBS (38%) than in the LPS (21%) group, located in the vicinity of the injection point. Conversely, among all the tested human markers for bone inflammation, only high levels of plasma prostaglandin E<sub>2</sub> (PGE<sub>2</sub>) and upregulation of immunoglobulin M (IgM) were found in the LPS-injected groups. Furthermore, granulocytic leucocytes that surrounded the spinal cord and thus also appeared in the vicinity of the bone of the vertebral bodies were observed in bone sections from all experimental groups. The authors concluded that localized injection-

related processes could have triggered the development of vertebral body anomalies. A successive trial (Gil Martens *et al.* 2011) with a more potent local inflammation inducer (Freund's complete adjuvant) again failed to find unequivocal induced ankylosis and platyspondyly by inflammation factors: all injected fish (placebo included) had more compressions in the injection site than untreated fish, and only the 7% of FCA-injected individuals showed peculiar severe scoliosis associated with a mixture of bone anomalies in the tail region. In conclusion, mechanical trauma due to the injection seems more likely to be the causative factor of compressed and fused vertebrae observed in vaccinated salmon than inflammation. However, inflammation cannot be excluded from the risk factors for these anomalies in salmon: it is known from biomedical research that inflammation can alter the normal pattern of bone growth and that bone remodelling is regulated by the interaction of systemic hormones and local factors such as local cytokines, prostaglandins, growth factors and transcription factors (Gil Martens 2012).

The presence of some antibiotics, as enrofloxacin, oxytetracycline and flumequine (in Atlantic salmon and Arctic charr *Salvelinus alpinus*: Toften & Jobling 1996; rainbow trout: Madsen *et al.* 2001) in food was associated with vertebral column anomalies.

### Sorting methods

Selections for deformed fish are carried out regularly along the whole chain, as fish farmers generally discard malformed fish during growth to minimize feeding costs.

In Mediterranean aquaculture, deformed fish are removed from the reared stocks well before they reach the final consumer usually by a two-step process. In the first step, early juveniles (usually at the mean weight of 0.3–0.5 g) are subjected to salinity floating tests, during which anaesthetized fish without an inflated swim bladder should sink to the bottom of the test-container, whereas those with an inflated swim bladder float on the surface. The method was initially applied in anaesthetized larvae, in normal salinity conditions (e.g. Chatain & Corrao 1992), but in the next years the efficiency of the method was largely improved by increasing the salinity of the test medium to 52–62 ppt. Nowadays, in most of the Mediterranean hatcheries, during the salinity test, anaesthetized floating fish are also checked for the presence of severe skeletal anomalies (mainly gill-cover anomalies).

At the second step of the removal of deformed fish from the reared stocks, juveniles of 1–5 g mean weight (depending on the hatchery) are anaesthetized and one by one examined on a light table by specialized personnel for the presence of vertebral, gill-cover, fin and jaw anomalies. The second manual step of the process results in a significant

increase of the personnel cost and delays in the production cycle (Koumoundouros 2010).

Strictly based on anatomical criteria, the distinction of normal fish from those with an abnormal skeleton is just an issue of comparative examination. At the hatchery level, however, anomalies of interest are those with significant effects on the external morphology of fish and not any internal skeletal deformation. With the exception of gill-cover anomalies and the non-inflated swim bladder, the effects of a single type of skeletal anomaly on the external morphology of fish show a continuous range from slight internal aberrations, to severe anomalies with clear effects on the external body shape (Loy *et al.* 1999, 2000; Koumoundouros *et al.* 2001; Gjerde *et al.* 2005; Sfakianakis *et al.* 2006a,b). As a scale of quality with a precise correlation between the skeletal development and the external morphology of the fish at the end of the hatchery and on-growing phases is missing, nowadays the threshold between commercially severe and non-severe anomalies is empirically and subjectively defined by the hatcheries (Koumoundouros 2010).

### Elements of solutions

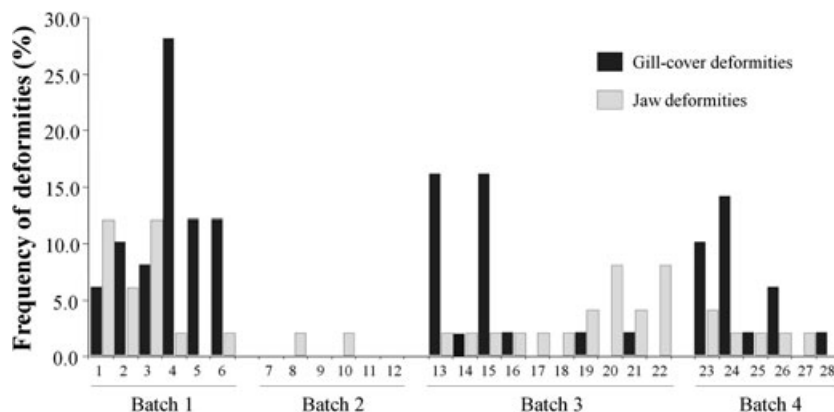
The only possible actual solution of the problem of skeletal anomalies basically relies on the determination of the causative factors and to the subsequent application of appropriate practices at the hatchery level. In parallel, it requires the development of processes for the mass removal of the deformed individuals from the cultured stocks, the establishment of procedures for the early assessment, verification and improvement of quality, as well as the development of a scale of quality for the precise distinction of commercially severe anomalies from those of scientific interest only.

At the applied level of the commercial hatcheries, the development of skeletal anomalies is a very complex problem, whose magnitude is determined not only by the average incidence of anomalous individuals, but also by the

large variability of incidence and anomalies typologies. Data from the routine quality controls in some commercial hatcheries demonstrate that the frequency of the various types of skeletal anomalies often vary among the different hatcheries, but also in the same hatchery at a seasonal or annual basis. Moreover, this intra-hatchery variability is evident among batches that are simultaneously reared, as well as among the different groups of the same batch (in hatcheries, the term batch describes the fish born from the same batch of eggs; Fig. 3).

The variable development of skeletal anomalies reflects the complexity of the ontogeny of the reared species, especially those with a small differentiation state at hatching and a relatively long following larval period (e.g. gilthead seabream, European seabass, common dentex, cod, Senegalese sole). From the existing literature, not all included here, much evidence highlights how intensive rearing conditions are by themselves causative factors for increased anomaly rates compared with semi-intensive conditions. However, space limitations due to coastal zone use conflicts prevent the adoption of semi-intensive rearing conditions in many farms for producing juveniles of a higher morphological quality.

One solution could be the theoretical adaptation of the complexity of the followed rearing methodology to the continuously changing requirements of the developing fish (Mazurais *et al.* 2009; Georgakopoulou *et al.* 2010), taking into consideration available (or improving) knowledge on ecological, physiological, nutritional and morphological features characterizing each species-specific life cycle (see the review by Rønnestad *et al.* 2013). This increased variability reflects the large number of potential causative factors, the lack of adequate knowledge on the species preferences for optimal development, the variability in raw materials used for the hatchery production, as well as the sensitivity of the rearing processes to human mistakes. Finally, the fact that selective breeding programmes rarely take into consideration the development of skeletal anomalies



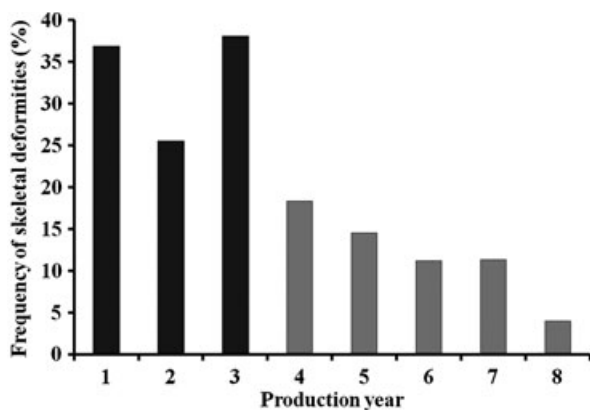
**Figure 3** Occurrences of skeletal anomalies in 28 gilthead seabream lots of juveniles reared in a commercial hatchery. All batches were reared under the same methodology and the same raw materials (G. Koumoundouros, unpubl. data).



lies, the involvement of the changing genetic background on the sensitivity of the fish to the action of causative factors cannot be excluded.

In order to connect the development of skeletal anomalies with their large variability at the hatchery level, a continuous awareness is required with respect to the whole rearing process and the quality of the fish produced. Even when optimal conditions for the normal development of fish species have been identified and incorporated into the applied protocols, fish quality has to be routinely monitored and continuously verified in order to guarantee the conformity of the applied methodology with the normal development of the fish, and to allow an early warning for fault/accidental deviations of the complex hatchery processes and their subsequent correction. The successful application of this procedure presupposes the precise monitoring of all stages of the rearing process on a regular basis, and that the control of fish quality is appropriate for early developmental stages, before hatchery practices (such as pooling of different lots, size grading etc.) mask the variability of anomalies. Existing results from commercial hatcheries demonstrate that the combination of such an approach (named 'Loop of Quality' by Koumoundouros 2010) with the identification of standard operating procedures and the implementation skills of the hatchery can result in significant improvements of fish quality (Fig. 4).

The swim bladder inflation in many marine finfish species occurs during a finite 'window' period of early larval development (Woolley & Qin 2010). Therefore, optimal rearing conditions are required for successful initial inflation, particularly the absence of an oil film at the air–water interface of the tank. The larvae at the time of



**Figure 4** Trend of frequencies of severe skeletal severe skeletal anomalies in a commercial hatchery, before (dark bars) and after (grey bars) the application of LoQ strategy. Data do not include the incidence of fish without an inflated swim bladder (the rate was improved from 12% on year 3 to 2–4% in the years 4–8) (Koumoundouros, unpubl. data).

inflating swim bladder (6–12 dph in European seabass and gilthead seabream) has not yet differentiated most of fins or axis skeletal elements, so they cannot develop enough force to break the oily film, preventing the larvae access to air for gulping. Some strategies have been set up for removing the superficial oily film, all conceived to disrupt the oily surface layer: particular superficial skimmers or four points of aeration at the surface area and an arm placed at the centre of the tank. All these devices concentrate the oil film on a small area of the tank, so enabling a manual removal. Despite using these devices, some individuals or lots fail to inflate the swim bladder, as recently demonstrated in gilthead seabream (Prestinicola 2012) and in Atlantic bluefin tuna larvae (Cataudella *et al.* 2011a). The high mortalities and the inferior quality of juveniles with a non-inflated swim bladder in the adult stage still remain a major problem in intensive farming, and the need to cull out the larvae without a functional swim bladder from the reared lots remains a crucial point in aquaculture management. As reported above, the sorting method commonly used by commercial hatcheries is based on the difference in buoyancy between larvae with and without functional swim bladders (Chapman *et al.* 1988; Chatain & Corrao 1992). When the resulting groups have been analysed in detail, however, the efficiency of this sorting method for swim bladder assessment was not demonstrated. In gilthead seabream, at least, the selection carried out using this methodology by the hatchery operators identified 45% of individuals with and 55% without a swim bladder, but the observations carried out on *in toto* stained juveniles (under stereomicroscope) did not confirm this ratio: 83% of analysed juveniles were without and only 50 (equal to the 17%) had a normally inflated swim bladder (Prestinicola 2012). This difference may be due to artefacts due to the diaphanization of swollen tissues in the whole mount staining protocol (that foresees the infiltration of glycerine in tissue) or to the use of anaesthetic. Previous studies have shown, in fact, that gases within the swim bladder tend to be released when the larvae are anaesthetized (Massee *et al.* 1995) and anaesthesia may cause a stress response (Small 2003). Therefore, other studies targeted to analyse each step of the methodology used to select individuals with a normal swim bladder seem still necessary.

### Main gaps in scientific knowledge and further research needs

In Part 1 of this review on skeletal anomalies, some (few) basic needs for scientific knowledge on skeletogenic processes in reared fish are detailed. The other main gaps of knowledge can be divided mainly into diagnostic and causative items. Among the diagnostic tools that are

presently needed in order to reduce the rate of deformed fish in cultured lots, standardization of the classification and definition of criteria to categorize uniformly the different typologies of skeletal anomalies in fish, mostly for larvae and juveniles, is of great importance. Many different terminologies are currently used to define some types of anomaly, often without providing a detailed description. In order to achieve this goal, a detailed description of the total ontogenesis of each skeletal anomaly, with the identification of timing windows, should be obtained, in order to distinguish between the different anomaly typologies and the ontogenetic steps of the same anomaly, as well as to comprehend the anomaly fate (recover, aggravation, sublethality, lethality). The ontogenetic pathway of many skeletal anomalies is rather unclear, as are the changes in the vertebral architecture during growth in the different reared species. Further, as some anomalies can develop directly during osteogenesis, whilst others develop on a pre-existing normal skeletal element, the capacity to discriminate between these two forms is crucial for a better understanding of the aetiology of skeletal anomalies. The possibility that a unique classification system can be developed for all the reared species and life stages should be definitely and soundly clarified.

Another aspect that demands a common shared approach is a method to assess the severity of axis deviations: some authors measure the angle between the most involved vertebrae in the deviation, centred in the intervertebral space at the most curved point; others consider as axis anomalies only column deviations in which the involved vertebrae present deformed or fused bodies, while considering as vertebrae displacement or misalignment the other deviations. Also, a common methodology for univocal and objective identification should be established, particularly for larval stages where *in toto* staining is necessary for observing skeletal elements.

Since systematic monitoring of skeletal anomalies in larval batches is already performed for some species only (European seabass, gilthead seabream), it should be extended on a regular basis to the other commonly reared species.

In order to study the relationships between rearing conditions, bone condition and vertebral abnormalities, terminology and observation methodologies should be delineated through well-defined experimental studies, as bone parameters appear to have a wide range of responses.

Further studies related to genetics, nutrition (including the trophic behaviour of larvae and juveniles), mineral balance, biomechanics and cellular features related to bone modelling and the hormonal regulation of bone metabolism should be performed, taking into account knowledge of human bone pathology, but also differences existing in bone tissues between tetrapods and fish, and between basal

and advanced teleosts (see Boglione *et al.* 2013). The applicability of existing knowledge on skeleton tissue differentiation, modelling and remodelling gathered in model fish species to reared fish should be verified extensively.

The main body of gaps resides basically in the knowledge necessary to identify the causative factors. All the available literature on this matter, to our knowledge, highlights how experimental design aimed at investigating the effect of one factor at a time on skeletal development mostly failed to produce the same anomaly found in rearing conditions, where multilevel factors interact on the developing organism in an unknown way, not reproducible in experimental conditions. Besides the many factors suspected to cause skeletal anomalies in reared European larvae and juveniles reviewed here, many others have been identified as influencing the skeletal anomaly pattern (frequency or typology; i.e. colour, shape and volume of tank; stocking density; oxygen level; water quality; light intensity and duration) in the different reared species and/or life stage, that could not have been treated in depth here.

So, greater interaction between researchers and producers should be established, in order to carry out multilevel investigations on the causative factors on a productive, not experimental, scale. The solution could be found possibly only by integrating the rearing conditions, molecular, genetic, physiological, anatomical and cellular data obtained for the same fish. The integrated nature of all (anomaly frequencies and typologies, environmental, genetic, physiological, biomolecular, histological) data should be considered in each study in order to address the multi-factorial nature of the cause of skeletal anomaly. The recent availability of new generation data analysis (e.g. unsupervised artificial neural networks; see Russo *et al.* 2010, 2011) may allow integration of multidisciplinary and multilevel data, even if it is characterized by non-linearity, internal redundancy and noise, and by obtaining classification, pattern recognition and empirical modelling. Such investigations should be aimed in particular to obtain deeper insights into the mechanics of bone anomalies, the anomalous mechanical load acting on developing skeletal elements being one of the most credited causative factors for many vertebrae anomalies, but the molecular pathways linking mechanics and bone development remain largely unknown. These integrative studies should be carried out on each reared species, including candidate species, directed towards a comprehensive method of manipulating biotic and abiotic factors to improve larval development and to promote a 'better' skeletal quality.

## Acknowledgements

This work benefits from participation in LARVANET COST action FA0801. Part of the data are the results of

research programmes funded by the Italian Ministry for Agriculture, Food and Forestry Policy (Law 41/82) (n. 5C49; 6C82; 6C100; 6C138; 6C144), and by the Commission of the European Communities (specific RTD programme 'Specific Support to Policies', SSP-2005-44483 'SEACASE – Sustainable extensive and semi-intensive coastal aquaculture in Southern Europe'). Also, this study was partially funded by the programme NSRF 2007-2013, 'Competitiveness and Entrepreneurship' (call Cooperation I, Project No 09SYN-24-619) of the Ministry of Education, Lifelong Learning and Religious Affairs, Greece; by the project PDTC-MAR-105152-2008 (SPECIAL-K) from the Portuguese Foundation for Science and Technology – FCT and integrated action CRUP-MICINN – AI-E-54; by the European Community's Seventh Framework Programme FP7/2007-2013 under Grant Agreement 222719-LIFECYCLE; by the Spanish Ministry of Science and Innovation (MICINN; projects AGL2008-03897-C04-01 and AIB2010-PT-00313).

## References

- Abdel I, Abellán E, López-Albors O, Valdés P, Nortes MJ, García-Alcázar A (2005) Abnormalities in the juvenile stage of sea bass (*Dicentrarchus labrax* L.) reared at different temperatures: types, prevalence and effect on growth. *Aquaculture International* **12**: 523–538.
- Afonso JM, Montero D, Robaina L, Astorga N, Izquierdo MS, Ginés R (2000) Association of a lordosis-scoliosis-kyphosis deformity in gilthead seabream (*Sparus aurata*) with family structure. *Fish Physiology and Biochemistry* **22**: 159–163.
- Afonso JM, Astorga N, Navarro A, Montero D, Zamorano MJ, Izquierdo M (2009) Genetic determination of skeletal deformities in gilthead seabream (*Sparus aurata* L.). In: IAFSB 2009 Book of abstracts, p. 90. Communication Interdisciplinary Approaches in Fish Skeletal Biology, 27–29 April 2009, Tavira, Algarve, Portugal.
- Andrades JA, Becerra J, Fernández-Llébreges P (1996) Skeletal deformities in larval, juvenile and adult stages of cultured gilthead sea bream (*Sparus aurata* L.). *Aquaculture* **141**: 1–11.
- Aragão C, Conceição LEC, Fyhn H-J, Dinis MT (2004) Estimated amino acid requirements during early ontogeny in fish with different life styles: gilthead seabream (*Sparus aurata*) and Senegalese sole (*Solea senegalensis*). *Aquaculture* **242**: 589–605.
- Astorga N, Valencia A, Fernández-Palacios H, Montero D, Zamorano MJ, Aguilera C *et al.* (2003) Genetic effect of the type of cross and consanguinity level in spawning quality of gilthead seabream (*Sparus aurata* L.). Eighth International Symposium on Genetics in Aquaculture. The Foundation for Agrarian Innovation (FIA) and The Institute of Fisheries Development (IFOP) Book of Abstracts, pp. 86; 9–15 Nov 2003, of Puerto Varas, Chile.
- Atalah E, Hernández-Cruz CM, Ganuza E, Benitez T, Roo J, Fernández-Palacios H *et al.* (2012) Enhancement of gilthead seabream (*Sparus aurata*) larval growth by dietary vitamin E in relation to two different levels of essential fatty acids. *Aquaculture Research* **43**: 1816–1827.
- Aulstad D, Kittelsen A (1971) Abnormal body curvatures of rainbow trout *Salmo gairdneri* inbred fry. *Journal of Fisheries Research Board of Canada* **28**: 1918–1920.
- Avery TS, Killen SS, Hollinger TR (2009) The relationship of embryonic development, mortality, hatching success, and larval quality to normal or abnormal early embryonic cleavage in Atlantic cod, *Gadus morhua*. *Aquaculture* **289**: 265–273.
- Azuma K, Casey SC, Ito M, Urano T, Horie K, Ouchi Y *et al.* (2010) Pregnane X receptor knockout mice display osteopenia with reduced bone formation and enhanced bone resorption. *Journal of Endocrinology* **207**: 257–263.
- Bæverfjord G, Asgard T, Shearer KD (1998) Development and detection of phosphorus deficiency in Atlantic salmon, *Salmo salar* L., parr and post smolts. *Aquaculture Nutrition* **4**: 1–11.
- Bæverfjord G, Helland S, Hough C (eds) (2009) *Control of Malformations in Fish Aquaculture: Science and Practice*. Federation of European Aquaculture Producers. RapidPress, Luxembourg.
- Balmer JE, Blomhoff R (2002) Gene expression regulation by retinoic acid. *Journal of Lipid Research* **43**: 1773–1808.
- Balmer JE, Blomhoff R (2005) A robust characterization of retinoic acid response elements based on a comparison of sites in three species. *Journal of Steroid Biochemistry and Molecular Biology* **96**: 347–354.
- Barahona-Fernandes MH (1982) Body deformation in hatchery reared European sea bass *Dicentrarchus labrax* (L.): types, prevalence and effect on fish survival. *Journal of Fish Biology* **21**: 239–249.
- Basaran F, Ozbilgin H, Ozbilgin YD (2007) Effect of lordosis on the swimming performance of juvenile sea bass (*Dicentrarchus labrax* L.). *Aquaculture Research* **38**: 870–876.
- Battaglione SC, Talbot RB (1993) Effects of salinity and aeration on survival and initial swimbladder inflation in larval Australian bass. *The Progressive Fish-Culturist* **55**: 35–39.
- Battaglione SC, McBride S, Talbot RB (1994) Swim bladder inflation in larvae of cultured sand whiting *Sillago ciliata* Cuvier (Sillaginidae). *Aquaculture* **128**: 177–192.
- Bell JG, Mc Evoy LA, Estévez A, Shields RJ, Sargent JR (2003) Optimising lipid nutrition in first-feeding flatfish larvae. *Aquaculture* **227**: 211–220.
- Beraldo P, Canavese B (2011) Recovery of opercular anomalies in gilthead sea bream, *Sparus aurata* L.: morphological and morphometric analysis. *Journal of Fish Diseases* **34**: 21–30.
- Beraldo P, Pinosa M, Tibaldi E, Canavese B (2003) Abnormalities of the operculum in gilthead seabream (*Sparus aurata*): morphological description. *Aquaculture* **220**: 89–99.
- Beresford WA (1981) *Chondroid Bone, Secondary Cartilage and Metaplasia*. Urban & Schwarzenberg, Baltimore-Munich.

- Berge GM, Storebakken T (1996) Fish protein hydrolysate in starter diets for Atlantic salmon (*Salmo salar*) fry. *Aquaculture* **145**: 205–212.
- Berge GM, Witten PE, Baeverfjord G, Vegusdal A, Wadsworth S, Ruyter B (2009) Diets with different n-6/n-3 fatty acid ratio in diets for juvenile Atlantic salmon, effects on growth, body composition, bone development and eicosanoid production. *Aquaculture* **296**: 299–308.
- Berntssen MHG, Waagbø R, Toften H, Lundebye AK (2003) Effects of dietary cadmium on calcium homeostasis, Ca mobilization and bone deformities in Atlantic salmon (*Salmo salar* L.) parr. *Aquaculture Nutrition* **9**: 175–183.
- Betancor MB, Atalah E, Caballero MJ, Benítez-Santana T, Roo J, Montero D *et al.* (2011)  $\alpha$ -Tocopherol in weaning diets for European sea bass (*Dicentrarchus labrax*) improves survival and reduces tissue damage caused by excess dietary DHA contents. *Aquaculture Nutrition* **17**: e112–e122.
- Blanco-Vives B, Villamizar N, Ramos J, Bayarri MJ, Chereguini O, Sánchez-Vázquez FJ (2010) Effect of daily thermo- and photo-cycles of different light spectrum on the development of Senegal sole (*Solea senegalensis*) larvae. *Aquaculture* **306**: 137–145.
- Boglino A, Darias MJ, Estévez A, Andree KB, Gisbert E (2012) The effect of dietary arachidonic acid during the *Artemia* feeding period on larval growth and skeletogenesis in Senegalese sole, *Solea senegalensis*. *Journal of Applied Ichthyology* **28**: 411–418.
- Boglione C, Costa C (2011) Skeletal deformities and juvenile quality. In: Pavlidis M, Mylonas C (eds) *Sparidae: Biology and Aquaculture of Gilthead Sea Bream and Other Species*, pp. 233–294. Wiley-Blackwell, Oxford.
- Boglione C, Marino G, Bertolini B, Rossi A, Ferreri F, Cataudella S (1993) Larval and postlarval monitoring in sea bass: morphological approach to evaluate finfish seed quality. In: Barnabé G, Kestemont P (eds) *Production, Environment and Quality. Special Publication No. 18*, pp. 189–204. European Aquaculture Society, Ghent, Belgium.
- Boglione C, Marino G, Fusari A, Ferreri F, Cataudella S (1995) Skeletal anomalies in *Dicentrarchus labrax* juveniles selected for functional swim bladder. *ICES Marine Science Symposium* **201**: 163–169.
- Boglione C, Costa C, Di Dato P, Ferzini G, Scardi M, Cataudella S (2003) Skeletal quality assessment of reared and wild sharp snout sea bream and pandora juveniles. *Aquaculture* **227**: 373–394.
- Boglione C, Marino G, Giganti M, Longobardi A, De Marzi P, Cataudella S (2009) Skeletal anomalies in dusky grouper *Epinephelus marginatus* (Lowe 1834) juveniles reared with different methodologies and larval densities. *Aquaculture* **291**: 48–60.
- Boglione C, Gavaia P, Koumoundouros G, Gisbert E, Moren M, Fontagné S *et al.* (2013) A review on skeletal anomalies in reared European fish larvae and juveniles. 1: normal and anomalous skeletogenic processes. *Reviews in Aquaculture* **5**: s99–s120.
- Cahu CL, Zambonino-Infante JL, Quazuguel P, Le Gall MM (1999) Protein hydrolysate vs fish meal in compound diets for 10-day old sea bass *Dicentrarchus labrax* larvae. *Aquaculture* **171**: 109–119.
- Cahu CL, Zambonino-Infante JL, Barbosa V (2003a) Phospholipid level in dietary lipid fraction is determining for sea bass (*Dicentrarchus labrax*) larval development. *British Journal of Nutrition* **90**: 21–28.
- Cahu C, Zambonino Infante JL, Takeuchi T (2003b) Nutritional components affecting skeletal development in fish larvae. *Aquaculture* **227**: 245–258.
- Cahu C, Gisbert E, Villeneuve LAN, Morais S, Hamza S, Wold P-A *et al.* (2009) Influence of dietary phospholipids on early ontogenesis of fish. *Aquaculture Research* **40**: 989–999.
- Camargo JA (2003) Fluoride toxicity to aquatic organisms: a review. *Chemosphere* **50**: 251–264.
- Cardeira J, Bensimon-Brito A, Pousão-Ferreira P, Cancela ML, Gavaia PJ (2012) Lordotic-kyphotic vertebrae develop ectopic cartilage-like tissue in Senegalese sole (*Solea senegalensis*). *Journal of Applied Ichthyology* **28**: 460–463.
- Carls MG, Rice SD, Hose JE (1999) Sensitivity of fish embryos to weathered crude oil. Part 1. Low level exposure during incubation causes malformations and genetic damage in larval Pacific herring (*Clupea pallasii*). *Environmental Toxicology and Chemistry* **18**: 481–493.
- Carmichael GJ, Tomasso JR (1984) Swim bladder stress syndrome in largemouth bass. *Texas Journal of Science* **35**: 315–321.
- Carpenter KE (ed.) (2002) *The Living Marine Resources of the Western Central Atlantic. Volume 3: Bony Fishes. Part 2 (Opistognathidae to Molidae), Sea Turtles and Marine Mammals*. FAO Species Identification Guide for Fishery Purposes and American Society of Ichthyologists and Herpetologists Special Publication No. 5. FAO, Rome.
- Carvalho AP, Escaffre A-M, Oliva-Teles A, Bergot P (1997) First feeding of common carp larvae on diets with high levels of protein hydrolysates. *Aquaculture International* **5**: 361–367.
- Carvalho AP, Oliva-Teles A, Bergot P (2003) A preliminary study on the molecular weight profile of soluble protein nitrogen in live food organisms for fish larvae. *Aquaculture* **225**: 445–449.
- Castro J, Bouza C, Presa P, Pino-Querido A, Riaza A, Ferreiro I *et al.* (2004) Potential sources of error in parentage assessment of turbot (*Scophthalmus maximus*) using microsatellite loci. *Aquaculture* **242**: 119–135.
- Castro J, Pino A, Hermida M, Bouza C, Riaza A, Ferreiro I *et al.* (2006) A microsatellite marker tool for parentage analysis in Senegal sole (*Solea senegalensis*): genotyping errors, null alleles and conformance to theoretical assumptions. *Aquaculture* **261**: 1194–1203.
- Castro J, Pino A, Hermida M, Bouza C, Chavarrías D, Merino P *et al.* (2007) A microsatellite marker tool for parentage assessment in gilthead sea bream (*Sparus aurata*). *Aquaculture* **272**: S210–S216.

- Castro J, Pino-Querido A, Hermida M (2008) Heritability of skeleton abnormalities (lordosis, lack of operculum) in gilt-head seabream (*Sparus aurata*) supported by microsatellite family data. *Aquaculture* **279**: 18–22.
- Cataudella S, Boglione C, Caprioli R, Vitalini V, Pulcini D, Cataldi E *et al.* (2011a) Aquaculture of Atlantic bluefin tuna (*Thunnus thynnus* L. 1758): increasing morphological knowledge on larvae and juveniles. Mediterranean Aquaculture Europe 2020. Rhodes, Greece 18–21 October 2011. Organized by the European Aquaculture Society (EAS). Book of Abstracts, pp. 171–172.
- Cataudella S, Palamara E, Ferrante I, Prestinicola L, Velluti F, Costa C *et al.* (2011b) Validation of morpho-physiological indicators of the productive chain of (*Dicentrarchus labrax*) and gilt-head seabream (*Sparus aurata*), and reference modeling for an expert system. Final report Research Project 7C144 Italian Ministry for Agricultural and Forestry Politics (in Italian with extended abstract in English).
- Chapman DC, Hubert WA, Jackson UT (1988) Influence of access to air and of salinity on gas bladder inflation in striped bass. *The Progressive Fish-Culturist* **50**: 23–27.
- Chatain B (1986) La vessie natatoire chez *Dicentrarchus labrax* et *Sparus auratus*: 1. Aspects morphologiques du développement. *Aquaculture* **53**: 303–311.
- Chatain B (1994) Abnormal swimbladder development and lordosis in sea bass (*Dicentrarchus labrax*) and sea bream (*Sparus aurata*). *Aquaculture* **97**: 169–180.
- Chatain B (1997) Development and achievements of marine fish-rearing technology in France over the last 15 years. *Hydrobiologia* **358**: 7–11.
- Chatain B, Corrao D (1992) A sorting method for eliminating fish larvae without functional swimbladders. *Aquaculture* **107**: 81–88.
- Chatain B, Ounais-Guschemann N (1990) Improved rate of initial swimbladder inflation in intensively reared *Sparus aurata*. *Aquaculture* **84**: 345–353.
- Cheng SH, Wai AWK, So CH, Wu RSS (2000) Cellular and molecular basis of cadmium-induced deformities in zebrafish embryos. *Environmental Toxicology and Chemistry* **19**: 3024–3031.
- Choo P-S, Smith TK, Cho CY, Ferguson HW (1991) Dietary excesses of leucine influence growth and body composition of rainbow trout. *Journal of Nutrition* **121**: 1932–1939.
- Cobcroft JM, Pankhurst PM, Sadler J, Hart PR (2001) Jaw development and malformation in cultured striped trumpeter *Lateolabrax lineatus*. *Aquaculture* **199**: 267–282.
- Combs GF (2008) *The Vitamins – Fundamental Aspects of Nutrition and Health*, 3rd edn. Elsevier, Amsterdam.
- Conceição LEC, Grasdalen H, Rønnestad I (2003) Amino acid requirements of fish larvae and post-larvae: new tools and recent findings. *Aquaculture* **227**: 221–232.
- Conceição L, Aragão C, Rønnestad I (2011) Proteins. In: Holt GJ (ed.) *Larval Fish Nutrition*, pp. 83–116. Wiley-Blackwell, Oxford, UK.
- Couch JA, Winstead JT, Hansen DJ, Goodman LR (1979) Vertebral dysplasia in young fish exposed to the herbicide trifluralin. *Journal of Fish Diseases* **2**: 35–42.
- Coutteau P, Geurden I, Camara MR, Bergot P, Sorgeloos P (1997) Review on the dietary effects of phospholipids in fish and crustacean larviculture. *Aquaculture* **155**: 149–164.
- Dabrowski K (1992) Ascorbate concentration in fish ontogeny. *Journal of Fish Biology* **40**: 273–279.
- Dabrowski K, Lee KJ, Rinchard J (2003) The smallest vertebrate, teleost fish, can utilize synthetic dipeptide-based diets. *Journal of Nutrition* **133**: 4225–4229.
- Daoulas C, Economou AN, Bantavas I (1991) Osteological abnormalities in laboratory reared sea bass (*Dicentrarchus labrax*) fingerlings. *Aquaculture* **97**: 169–180.
- Daprà F, Geurden I, Corraze G, Bazin D, Zambonino-Infante JL, Fontagné-Dicharry S (2011) Physiological and molecular responses to dietary phospholipids vary between fry and early juvenile stages of rainbow trout (*Oncorhynchus mykiss*). *Aquaculture* **319**: 377–384.
- Darias MJ, Mazurais D, Koumoundouros G, Glynatsi N, Christodouloupoulou S, Huelvan C *et al.* (2010) Dietary vitamin D3 affects digestive system ontogenesis and ossification in European sea bass (*Dicentrarchus labrax*, Linnaeus, 1758). *Aquaculture* **298**: 300–307.
- Darias MJ, Mazurais D, Koumoundouros G, Cahu CL, Zambonino-Infante JL (2011a) Overview of vitamin D and C requirements in fish and their influence on the skeletal system. *Aquaculture* **35**: 49–60.
- Darias MJ, Mazurais D, Koumoundouros G, Le Gall MM, Huelvan C, Desbruyeres E *et al.* (2011b) Imbalanced dietary ascorbic acid alters molecular pathways involved in skeletogenesis of developing European sea bass (*Dicentrarchus labrax*). *Comparative Biochemistry and Physiology. A, Comparative Physiology* **159**: 46–55.
- Dedi J, Takeuchi T, Seikai T, Watanabe T (1995) Hypervitaminosis and safe levels of vitamin A for larval Japanese flounder (*Paralichthys olivaceus*) fed *Artemia nauplii*. *Aquaculture* **133**: 135–146.
- Deschamps M-H, Kacem A, Ventura R, Gourty G, Haffray P, Meunier FJ *et al.* (2008) Assessment of ‘discreet’ vertebral abnormalities, bone mineralization and bone compactness in farmed rainbow trout. *Aquaculture* **279**: 11–17.
- Deschamps M-H, Labbé L, Baloche S, Fouchereau-Péron M, Dufour S, Sire J-J (2009) Sustained exercise improves vertebral histomorphometry and modulates hormonal levels in rainbow trout. *Aquaculture* **296**: 337–346.
- Dionísio G, Campos C, Valente LMP, Conceição LEC, Cancela ML, Gavaia PJ (2012) Effect of egg incubation temperature on the occurrence of skeletal deformities in *Solea senegalensis*. *Journal of Applied Ichthyology* **28**: 471–476.
- Divanach P (1985) *Contribution de la Biologie et de l'Élevage de 6 Sparidés Méditerranéens: Sparus aurata, Diplodus sargus, Diplodus vulgaris, Diplodus annularis, Lithognathus mormyrus, Puntazzo puntazzo (Poissons Téléostéens)*. Université des Sciences et Techniques de Languedoc, Montpellier, France.

- Divanach P, Boglione C, Menu B, Koumoundouros G, Kentouri M, Cataudella S (1996) Abnormalities in finfish mariculture: an overview of the problem, causes and solutions. In: Handbook of Contributions and Short Communications, International Workshop on Sea Bass and Sea Bream Culture: Problems and Prospects, organized by European Aquaculture Society (EAS) in Verona, Italy, 16–18 October, pp. 45–66.
- Divanach P, Papandroulakis N, Anastasiadis P, Koumoundouros G, Kentouri M (1997) Effect of water currents on the development of skeletal deformities in sea bass (*Dicentrarchus labrax* L.) with functional swimbladder during postlarval and nursery phase. *Aquaculture* **156**: 145–155.
- Engrola S, Figueira L, Conceição LEC, Gavaia P, Dinis MT (2009) Co-feeding in Senegalese sole larvae with inert diet from mouth opening promotes growth at weaning. *Aquaculture* **288**: 264–272.
- Estévez A, Kanazawa A (1995) Effect of (n-3) PUFA and vitamin A *Artemia* enrichment on pigmentation success of turbot *Scophthalmus maximus* (L.). *Aquaculture Nutrition* **1**: 159–168.
- Estévez A, McEvoy LA, Bell JG, Sargent JR (1999) Growth, survival, lipid composition and pigmentation of turbot (*Scophthalmus maximus*) larvae fed live-prey enriched in arachidonic and eicosapentaenoic acids. *Aquaculture* **180**: 321–343.
- Farran MT, Thomas OP (1992) Valine deficiency. 2. The effect of feeding a valine deficient diet during the starter period on performance and leg abnormality of male broiler chicks. *Poultry Science* **71**: 1885–1890.
- Faustino M, Power D (1998) Development of osteological structures in the sea bream: vertebral column and caudal fin complex. *Journal of Fish Biology* **52**: 11–22.
- Ferguson MM, Danzmann RG (1998) Role of genetic markers in fisheries and aquaculture: useful tools or stamp collecting? *Canadian Journal of Fisheries and Aquatic Sciences* **55**: 1553–1563.
- Fernández I (2011) Hypervitaminosis A effects on *Sparus aurata* and *Solea senegalensis*: characterization of larval performance and the underlying gene expression of abnormal skeletogenesis (Doctoral Thesis). University of Barcelona, Barcelona, Spain.
- Fernández I, Gisbert E (2010) Senegalese sole bone tissue originated from chondral ossification is more sensitive than dermal bone to high vitamin A content in enriched *Artemia*. *Journal of Applied Ichthyology* **26**: 344–349.
- Fernández I, Gisbert E (2011) The effect of vitamin A on flatfish development and skeletogenesis: a review. *Aquaculture* **315**: 34–48.
- Fernández I, Hontoria F, Ortiz-Delgado JB, Kotzamanis Y, Estévez A, Zambonino-Infante JL *et al.* (2008) Larval performance and skeletal deformities in farmed gilthead sea bream (*Sparus aurata*) fed with graded levels of Vitamin A enriched rotifers (*Brachionus plicatilis*). *Aquaculture* **283**: 102–115.
- Fernández I, Pimentel MS, Ortiz-Delgado JB, Hontoria F, Sarasquete C, Estévez A *et al.* (2009) Effect of dietary vitamin A on Senegalese sole (*Solea senegalensis*) skeletogenesis and larval quality. *Aquaculture* **295**: 250–265.
- Fernández I, Darias MJ, Andree KB, Mazurais D, Zambonino-Infante JL, Gisbert E (2011) Coordinated gene expression during gilthead sea bream skeletogenesis and its disruption by nutritional hypervitaminosis A. *BMC Developmental Biology* **11**: 7.
- Fiaz AW, van Leeuwen JL, Kranenbarg S (2010) Phenotypic plasticity and mechano-transduction in the teleost skeleton. *Journal of Applied Ichthyology* **26**: 289–293.
- Finn RN, Rønnestad I, van der Meer T, Fyhn JH (2002) Fuel and metabolic scaling during the early life stages of Atlantic cod *Gadus morhua*. *Marine Ecology-Progress Series* **243**: 217–234.
- Fitzsimmons SD, Perutz M (2006) Effects of egg incubation temperature on survival, prevalence and types of malformations in vertebral column of Atlantic Cod (*Gadus morhua*) larvae. *Bulletin of the European Association of Fish Pathologists* **26**: 80–86.
- Fjelldal PG, Nordgarden U, Berg A, Grotmol S, Totland G, Wargelius A *et al.* (2005) Vertebrae of the trunk and tail display different growth rates in response to photoperiod in Atlantic salmon, *Salmo salar* L., post-smolts. *Aquaculture* **250**: 516–524.
- Fjelldal PG, Lock EJ, Grotmol S, Totland GK, Nordgarden U, Flik G *et al.* (2006) Impact of smolt production strategy on vertebral growth and mineralisation during smoltification and the early seawater phase in Atlantic salmon (*Salmo salar* L.). *Aquaculture* **261**: 715–728.
- Fjelldal PG, Hansen TJ, Berg AE (2007) A radiological study on the development of vertebral deformities in cultured Atlantic salmon (*Salmo salar* L.). *Aquaculture* **273**: 721–728.
- Fjelldal PG, Hansen T, Breck O, Sandvik R, Waagbø R, Berg A *et al.* (2009) Supplementation of dietary minerals during the early seawater phase increase vertebral strength and reduce the prevalence of vertebral deformities in fast growing under-yearling Atlantic salmon (*Salmo salar* L.) smolt. *Aquaculture Nutrition* **15**: 366–378.
- Fontagné S, Geurden I, Escaffre AM, Bergot P (1998) Histological changes induced by dietary phospholipids in intestine and liver of common carp (*Cyprinus carpio* L.) larvae. *Aquaculture* **161**: 213–223.
- Fontagné S, Bazin D, Brèque J, Vachot C, Bernarde C, Rouault T *et al.* (2006) Effects of dietary oxidized lipid and vitamin A on the early development and antioxidant status of Siberian sturgeon (*Acipenser baeri*) larvae. *Aquaculture* **257**: 400–411.
- Fontagné S, Silva N, Bazin D, Ramos A, Aguirre P, Surget A *et al.* (2009) Effects of dietary phosphorus and calcium level on growth and skeletal development in rainbow trout (*Oncorhynchus mykiss*) fry. *Aquaculture* **297**: 141–150.
- Francescon A, Freddi A, Barbaro A, Giavenni R (1988) Daurade *S. aurata* L. reproduite artificiellement et daurade sauvage. Expériences paralleles en diverses conditions d'elevage. *Aquaculture* **72**: 273–285.
- Galeotti M, Beraldo P, de Dominis S, D'Angelo L, Ballestrazzi R, Musetti R *et al.* (2000) A preliminary histological and ultra-

- structural study of opercular anomalies in gilthead sea bream larvae (*Sparus aurata*). *Fish Physiology and Biochemistry* **22**: 151–157.
- Gapasin RSJ, Duray MN (2001) Effects of DHA-enriched live food on growth, survival and incidence of opercular deformities in milkfish (*Chanos chanos*). *Aquaculture* **193**: 49–63.
- Gavaia PJ, Dinis MT, Cancela ML (2002) Osteological development and abnormalities of the vertebral column and caudal skeleton in larval and juvenile stages of hatchery-reared Senegal sole (*Solea senegalensis*). *Aquaculture* **211**: 305–323.
- Gavaia PJ, Domingues S, Engrola S, Drake P, Sarasquete C, Dinis MT *et al.* (2009) Comparing skeletal development of wild and hatchery-reared Senegalese sole (*Solea senegalensis*, Kaup 1858): evaluation in larval and postlarval stages. *Aquaculture Research* **40**: 1585–1593.
- Georga I, Glynatsi N, Baltzios A, Karamanos D, Mazurais D, Darias MJ *et al.* (2011) Effect of vitamin A on the skeletal morphogenesis of European sea bass, *Dicentrarchus labrax* (Linnaeus, 1758). *Aquaculture Research* **42**: 684–692.
- Georgakopoulou E, Angelopoulou A, Kaspiris P, Divanach P, Koumoundouros G (2007) Temperature effects on cranial deformities in European sea bass, *Dicentrarchus labrax* (L.). *Journal of Applied Ichthyology* **23**: 99–103.
- Georgakopoulou E, Katharios P, Divanach P, Koumoundouros G (2010) Effect of temperature on the development of skeletal deformities in Gilthead seabream (*Sparus aurata* Linnaeus, 1758). *Aquaculture* **308**: 13–19.
- Germain P, Chambon P, Eichele G, Evans RM, Lazar MA, Leid M *et al.* (2006a) International Union of Pharmacology. LX. Retinoic acid receptors. *Pharmacological Reviews* **58**: 712–725.
- Germain P, Chambon P, Eichele G, Evans RM, Lazar MA, Leid M *et al.* (2006b) International Union of Pharmacology, LXIII. Retinoid X receptors. *Pharmacological Reviews* **58**: 760–772.
- Geurden I, Marion D, Charlon N, Coutteau P, Bergot P (1998) Comparison of different soybean phospholipidic fractions as dietary supplements for common carp, *Cyprinus carpio*, larvae. *Aquaculture* **161**: 225–235.
- Gil Martens L (2012) Is inflammation a risk factor for spinal deformities in farmed Atlantic salmon? (PhD Dissertation). University of Bergen, Norway.
- Gil Martens L, Obach A, Ritchie G, Witten PE (2005) Analysis of a short tail phenotype in farmed Atlantic salmon (*Salmo salar*). *Fish Veterinary Journal* **8**: 71–79.
- Gil Martens L, Lock EJ, Fjellidal PG, Wargelius A, Araujo P, Torsensen BE *et al.* (2010) Dietary fatty acids and inflammation in the vertebral column of Atlantic salmon (*Salmo salar*) smolts: a possible link to spinal deformities. *Journal of Fish Diseases* **33**: 957–972.
- Gil Martens L, Fjellidal PG, Lock EJ, Wargelius A, Wergeland H, Witten PE *et al.* (2011) Dietary phosphorus does not reduce the risk for spinal deformities in a model of adjuvant-induced inflammation in Atlantic salmon (*Salmo salar*) post-smolts. *Aquaculture Nutrition* **18**: 12–20.
- Giménez G, Kotzamanis Y, Hontoria F, Estévez A, Gisbert E (2007) Modelling retinoid content in live prey: a tool for evaluating the nutritional requirements and development studies in fish larvae. *Aquaculture* **267**: 76–82.
- Gisbert E, Skalli A, Fernández I, Kotzamanis Y, Zambonino-Infante JL, Fabregat R (2012) Protein hydrolysates from yeast and pig blood as alternative raw materials in microdiets for gilthead sea bream (*Sparus aurata*) larvae. *Aquaculture* **338**: 96–104.
- Gjerde B, Pante MJR, Baeverfjord G (2005) Genetic variation for a vertebral deformity in Atlantic salmon (*Salmo salar*). *Aquaculture* **244**: 77–87.
- Glencross BD (2009) Exploring the nutritional demand for essential fatty acids by aquaculture species. *Reviews in Aquaculture* **1**: 71–124.
- Gordon M (1954) The genetics of fish diseases. *Transactions of the American Fisheries Society* **83**: 229–240.
- Graff IE, Waagbø R, Fivelstad S, Vermeer C, Lie Ø, Lundebye AK (2002) A multivariate study on the effects of dietary vitamin K, vitamin D3 and calcium, and dissolved carbon dioxide on growth, bone minerals, vitamin status and health performance in smolting Atlantic salmon *Salmo salar* L. *Journal of Fish Diseases* **25**: 599–614.
- Grini A, Hansen T, Berg A, Wargelius A, Fjellidal PG (2011) The effect of water temperature on vertebral deformities and vaccine-induced abdominal lesions in Atlantic salmon, *Salmo salar* L. *Journal of Fish Diseases* **34**: 531–546.
- Grotmol S, Kryvi H, Totland GK (2005) Deformation of the notochord by pressure from the swim bladder may cause malformation of the vertebral column in cultured Atlantic cod *Gadus morhua* larvae: a case study. *Diseases of Aquatic Organisms* **65**: 121–128.
- Haga Y, Suzuki T, Takeuchi T (2002) Retinoic acid isomers produce malformations in postembryonic development of Japanese flounder *Paralichthys olivaceus*. *Zoological Science* **19**: 1105–1112.
- Haga Y, Suzuki T, Kagechika H, Takeuchi T (2003) A retinoic acid receptor-selective agonist causes jaw deformity in the Japanese flounder, *Paralichthys olivaceus*. *Aquaculture* **221**: 381–392.
- Haga Y, Takeuchi T, Murayama Y, Ohta K, Fukunaga T (2004a) Vitamin D3 compounds induce hypermelanosis on the blind side and vertebral deformity in juvenile Japanese flounder *Paralichthys olivaceus*. *Fisheries Science* **70**: 59–67.
- Haga Y, Takeuchi T, Seikai T (2004b) Changes of retinoid contents in larval Japanese flounder *Paralichthys olivaceus* and *Artemia* nauplii enriched with a large dose of all-trans retinoic acid. *Fisheries Science* **70**: 436–444.
- Haga Y, Dominique VJ, Du SJ (2009) Analyzing notochord segmentation and intervertebral disc formation using the twhh: gfp transgenic zebrafish model. *Transgenic Research* **18**: 669–683.
- Haga Y, Du S-J, Satoh S, Kotani T, Fushimi H, Takeuchi T (2011) Analysis of the mechanism of skeletal deformity in fish

- larvae using a vitamin A-induced bone deformity model. *Aquaculture* **315**: 26–33.
- Hall BK (2005) *Bones and Cartilage: Developmental Skeletal Biology*. Elsevier, London.
- Halver JE (1957) Nutrition of salmonoid fishes. 4. An amino acid test diet for chinook salmon. *Journal of Nutrition* **62**: 245–254.
- Halver JE, Hardy RW (eds) (2002) *Fish Nutrition*, 3rd edn, pp. 182–259. Academic Press Inc., San Diego, CA.
- Hamre K (2006) Nutrition in cod (*Gadus morhua*) larvae and juveniles. *ICES Journal of Marine Science* **63**: 267–274.
- Hamre K (2011) Metabolism, interactions, requirements and functions of vitamin E in fish. *Aquaculture Nutrition* **17**: 98–115.
- Hamre K, Opstad I, Espe J, Solbakken G-I, Hemre A, Pittman K (2002) Nutrient composition and metamorphosis success of Atlantic halibut (*Hippoglossus hippoglossus*, L.) larvae fed natural zooplankton or Artemia. *Aquaculture Nutrition* **8**: 139–148.
- Hamre K, Moren M, Solbakken J, Opstad I, Pittman K (2005) The impact of nutrition on metamorphosis in Atlantic halibut (*Hippoglossus hippoglossus* L.). *Aquaculture* **250**: 555–565.
- Hamre K, Mollan TA, Saele O, Erstad B (2008) Rotifers enriched with iodine and selenium increase survival in Atlantic cod (*Gadus morhua*) larvae. *Aquaculture* **284**: 190–195.
- Hamre K, Krossoy C, Lock E-J, Moren M (2010) Roles of lipid-soluble vitamins during ontogeny of marine fish larvae. *Aquaculture Research* **41**: 745–750.
- Hamre K, Lukram IM, Rønnestad I, Nordgreen A, Saele O (2011) Pre-digestion of dietary lipids has only minor effects on absorption, retention and metabolism in larval stages of Atlantic cod (*Gadus morhua*). *British Journal of Nutrition* **105**: 846–856.
- Hamre K, Yúfera M, Conceição LEC, Rønnestad I, Boglione C, Izquierdo M (2013) Fish larval nutrition and feed formulation – knowledge gaps and bottlenecks for advances in larval rearing (a larvanet review). *Reviews in Aquaculture* **5**: s26–s58.
- Hansen MH (2011) Effects of feeding with copepod nauplii (*Acartia tonsa*) compared to rotifers (*Brachionus ibericus*, Cayman) on quality parameters in Atlantic cod (*Gadus morhua*) larvae (Doctoral Thesis). Department of Biology, NTNU, Trondheim, Norway.
- Hansen OJ, Puvanendran V (2010) Fertilization success and blastomere morphology as predictors of egg and juvenile quality for domesticated Atlantic cod, *Gadus morhua*, broodstock. *Aquaculture Research* **41**: 1791–1798.
- Hattori M, Sawada Y, Takagi Y, Suzuki R, Okada T, Kumai H (2003) Vertebral deformity in cultured red sea bream, *Pagrus major*, Temminck and Schlegel. *Aquaculture Research* **23**: 1129–1137.
- Hattori M, Sawada Y, Kurata M, Yamamoto S, Kato K, Kumai H (2004) Oxygen deficiency during somitogenesis causes centrum defects in red sea bream, *Pagrus major* (Temminck et Schlegel). *Aquaculture Research* **35**: 850–858.
- Helland S, Refstie S, Espmark A, Hjelde K, Baeverfjord G (2005) Mineral balance and bone formation in fast-growing Atlantic salmon parr (*Salmo salar*) in response to dissolved metabolic carbon dioxide and restricted dietary phosphorus supply. *Aquaculture* **250**: 364–376.
- Helland S, Denstadli V, Witten PE, Hjelde K, Storebakken T, Baeverfjord G (2006) Occurrence of hyper-dense vertebrae in Atlantic salmon (*Salmo salar* L.) fed diets with graded levels of phytic acid. *Aquaculture* **261**: 603–614.
- Hickey CR, Young BH, Bishop RD (1977) Skeletal abnormalities in striped bass. *New York Fish and Game Journal* **24**: 69–85.
- Hough C (2009) Improving the sustainability of European fish aquaculture by the control of malformations. Oral communication at the FINEFISH Final Workshop, 7 Sep 2009, held during Larvi 2009 - 5th Fish & Shellfish Larviculture Symposium; 7–10 Sep 2009, Ghent University, Belgium.
- Humason GL (1962) *Animal Tissue Techniques*, pp. 214–215. WH Freeman and Co, San Francisco, CA.
- Izquierdo MS, Socorro J, Roo J (2010) Studies on the appearance of skeletal anomalies in red porgy: effect of culture intensiveness, feeding habits and nutritional quality of live preys. *Journal of Applied Ichthyology* **26**: 320–326.
- Jeziarska B, Lugowska K, Witeska M (2009) The effects of heavy metals on embryonic development of fish (a review). *Fish Physiology and Biochemistry* **35**: 625–640.
- Johnson DW, Katavic I (1984) Mortality, growth and swim bladder stress syndrome of sea bass (*Dicentrarchus labrax*) larvae under varied environmental conditions. *Aquaculture* **38**: 67–78.
- Johnson IA, Strugnell G, McCracken ML, Johnstone R (1999) Muscle growth and development in normal-sex-ratio and all-female diploid and triploid Atlantic salmon. *Journal of Experimental Biology* **202**: 1991–2016.
- Jump DB (2004) Fatty acid regulation of gene transcription. *Critical Reviews in Clinical Laboratory Sciences* **41**: 41–78.
- Kacem A, Meunier JF, Aubin J, Haffray P (2003) Caractérisation histo-morphologique des malformations du squelette vertébral chez la truite arc-en-ciel (*Oncorhynchus mykiss*) après différents traitements de triploïdisation. *Cybio* **28**: 15–23.
- Kanazawa A, Teshima S, Inamori S, Iwashita T, Nagao A (1981) Effects of phospholipids on growth, survival rate and incidence of malformation in the larval ayu. *Memoirs of the Faculty of Fisheries, Kagoshima University* **30**: 301–309.
- Katavic I (1986) Diet involvement in mass mortality of sea bass (*Dicentrarchus labrax*) larvae. *Aquaculture* **58**: 45–54.
- Kause A, Ritola O, Paananen T (2007) Changes in the expression of genetic characteristics across cohorts in skeletal deformations of farmed salmonids. *Genetics Selection Evolution* **39**: 529–543.
- Kentouri M (1985) *Comportement larvaire de 4 sparidés méditerranéens en élevage Sparus aurata, Diplodus sargus, Lithognathus mormyrus, Puntazzo puntazzo (Poissons Téléostéens)*. Université des Sciences et Techniques de Languedoc, Montpellier, France.



- Kihara M, Ogata S, Kawano N, Kubota I, Yamaguchi R (2002) Lordosis induction in juvenile red sea bream, *Pagrus major*, by high swimming activity. *Aquaculture* **212**: 149–158.
- Kitajima C (1978) Acquisition of fertilized eggs and mass culture of juveniles of red sea bream, *Pagrus major*. Special Report 5, Nagasaki, Prefecture Institute of Fisheries.
- Kitajima C, Tsukashima Y, Fujita S, Watanabe T, Yone Y (1981) Relationship between uninflated swim bladders and lordotic deformity in hatchery-reared red sea bream *Pagrus major*. *Bulletin of the Japanese Society of Scientific Fisheries* **7**: 1289–1294.
- Kitamura S, Ohara S, Suwa T, Nakagawa K (1965) Studies on vitamin requirements of rainbow trout (*Salmo gairdneri*). *Bulletin of the Japanese Society for the Science of Fish* **31**: 818–826.
- Kjørsvik E, Olsen C, Wold P-A, Hoehne-Reitan K, Cahu CL, Rainuzzo J *et al.* (2009) Comparison of dietary phospholipids and neutral lipids on skeletal development and fatty acid composition in Atlantic cod (*Gadus morhua*). *Aquaculture* **294**: 246–255.
- Kolkovski S (2008) Advances in marine fish larvae diets. In: Cruz-Suárez E, Ricque D, Tapia M, Nieto MG, Villarreal LDA, Lazo JP *et al.* (eds) *Avances en Nutrición Acuicola IX*, pp. 20–45. Universidad Autónoma de Nuevo León, Nuevo León, Mexico.
- Kolstad K, Thorland I, Refstie T, Gjerde B (2006) Body weight, sexual maturity and spinal deformity in strains and families of Atlantic cod (*Gadus morhua*) at two years of age at different locations along the Norwegian coast. *ICES Journal of Marine Science* **63**: 246–252.
- Komada N (1980) Incidence of gross malformations and vertebral anomalies of natural and hatchery *Plecoglossus altivelis*. *Copeia* **1**: 29–35.
- Koumoundouros G (2010) Morpho-anatomical abnormalities in Mediterranean marine aquaculture. In: Koumoundouros G (ed.) *Recent Advances in Aquaculture Research*, pp. 125–148. Transworld Research Network, Kerala, India.
- Koumoundouros G, Gagliardi F, Divanach P, Boglione C, Cataudella S, Kentouri M (1997a) Normal and abnormal osteological development of caudal fin in *Sparus aurata* L. fry. *Aquaculture* **149**: 215–226.
- Koumoundouros G, Oran G, Divanach P, Stefanakis S, Kentouri M (1997b) The opercular complex deformity in intensive gilt-head sea bream (*Sparus aurata* L.) larviculture. Moment of apparition and description. *Aquaculture* **156**: 165–177.
- Koumoundouros G, Divanach P, Kentouri M (2001) The effect of rearing conditions on development of saddleback syndrome and caudal fin deformities in *Dentex dentex* (L.). *Aquaculture* **200**: 285–304.
- Koumoundouros G, Maingot E, Divanach P, Kentouri M (2002) Kyphosis in reared sea bass (*Dicentrarchus labrax* L.): ontogeny and effects on mortality. *Aquaculture* **209**: 49–58.
- Koumoundouros G, Carrillo J, Divanach P, Kentouri M (2004) The rearing of common dentex *Dentex dentex* (L.) during the hatchery and on-growing phases. *Aquaculture* **240**: 165–173.
- Koumoundouros G, Ashton C, Sfakianakis DG, Divanach P, Kentouri M, Anthwal N *et al.* (2009) Thermally induced phenotypic plasticity of swimming performance in European sea bass *Dicentrarchus labrax* juveniles. *Journal of Fish Biology* **74**: 1309–1322.
- Kranenborg S, Waarsing JH, Muller M, Weinans H, van Leeuwen JL (2005) Adaptive bone formation in acellular vertebrae of sea bass (*Dicentrarchus labrax* L.). *Journal of Biomechanics* **38**: 1239–1246.
- Kranenborg S, Schipper H, van Leeuwen JL (2006) Local biophysical stimuli and chondroid bone in lordotic vertebrae of the sea bass. *Comparative Biochemistry and Physiology. A, Comparative Physiology* **143A**: 95.
- Krossøy C, Waagbø R, Fjellidal PG, Krossøy C, Waagbø R, Fjellidal P-G *et al.* (2009) Dietary menadione nicotinamide bisulphite (vitamin K3) does not affect growth or bone health in first feeding fry of Atlantic salmon (*Salmo salar* L.). *Aquaculture Nutrition* **15**: 638–649.
- Krossøy C, Waagbø R, Ørnsrud R (2011) Vitamin K in fish nutrition. *Aquaculture Nutrition* **17**: 585–594.
- Kvåle A, Mangor-Jensen A, Harboe T, Hamre K (2009) Effects of protein hydrolysates in weaning diets to Atlantic cod (*Gadus morhua* L.) and Atlantic halibut (*Hippoglossus hippoglossus* L.). *Aquaculture Nutrition* **15**: 218–227.
- Lall SP (2002) The minerals. In: Halver JE, Hardy RW (eds) *Fish Nutrition*, 3rd edn, pp. 259–308. Academic Press Inc., San Diego, CA.
- Lall SP, Lewis-McCrea LM (2007) Role of nutrients in skeletal metabolism and pathology in fish – An overview. *Aquaculture* **267**: 3–19.
- Laue K, Jänicke M, Plaster N, Sonntag C, Hammerschmidt M (2008) Restriction of retinoic acid activity by Cyp26b1 is required for proper timing and patterning of osteogenesis during zebrafish development. *Development* **135**: 3775–3787.
- Lewis LM, Lall SP, Witten PE (2004) Morphological description of the early stages of spine and vertebral development in hatchery reared larval and juvenile Atlantic halibut (*Hippoglossus hippoglossus*). *Aquaculture* **241**: 47–59.
- Lewis-McCrea LM, Lall SP (2004) Development of the axial skeleton and skeletal abnormalities of Atlantic halibut (*Hippoglossus hippoglossus*) from first feeding through metamorphosis. *Aquaculture* **257**: 124–135.
- Lewis-McCrea LM, Lall SP (2007) Effects of moderately oxidized dietary lipid and the role of vitamin E on the development of skeletal abnormalities in juvenile Atlantic halibut (*Hippoglossus hippoglossus*). *Aquaculture* **262**: 142–155.
- Lewis-McCrea LM, Lall SP (2010) Effects of phosphorus and vitamin C deficiency, vitamin A toxicity, and lipid peroxidation on skeletal abnormalities in Atlantic halibut (*Hippoglossus hippoglossus*). *Journal of Applied Ichthyology* **26**: 334–343.
- Liang JJ, Tian LX, Liu YJ, Yang HJ, Liang GY (2012) Dietary magnesium requirement and effects on growth and tissue magnesium content of juvenile grass carp (*Ctenopharyngodon idella*). *Aquaculture Nutrition* **18**: 56–64.

- Lie KK, Moren M (2012) Retinoic acid induces two osteocalcin isoforms and inhibits markers of osteoclast activity in Atlantic cod (*Gadus morhua*) *ex vivo* cultured craniofacial tissues. *Comparative Biochemistry and Physiology. A, Comparative Physiology* **161**: 174–184.
- Lijalad M, Powell MD (2009) Effects of lower jaw deformity on swimming performance and recovery from exhaustive exercise in triploid and diploid Atlantic salmon *Salmo salar* L. *Aquaculture* **290**: 145–154.
- Lim C, Klesius PH (2003) Influence of dietary levels of magnesium on growth, tissue mineral content, and resistance of channel catfish *Ictalurus punctatus* challenged with *Edwardsiella ictaluri*. *Journal of the World Aquaculture Society* **34**: 18–28.
- Lobanov AV, Hatfield DL, Gladyshev VN (2008) Reduced reliance on the trace element selenium during evolution of mammals. *Genome Biology* **9**: R62.
- Lock E-J, Waagbø R, Wendelaar Bonga S, Flik G (2010) The significance of vitamin D for fish: a review. *Aquaculture Nutrition* **16**: 100–116.
- Loy A, Boglione C, Cataudella S (1999) Geometric morphometrics and morpho-anatomy: a combined tool in the study of sea bream (*Sparus aurata*, Sparidae) shape. *Journal of Applied Ichthyology* **15**: 104–110.
- Loy A, Boglione C, Gagliardi F, Ferrucci L, Cataudella S (2000) Geometric morphometrics and internal anatomy in sea bass shape analysis (*Dicentrarchus labrax* L., Moronidae). *Aquaculture* **186**: 33–44.
- Madsen L, Arnbjerg J, Dalsgaard I (2001) Radiological examination of the spinal column in farmed rainbow trout *Oncorhynchus mykiss* (Walbaum): experiments with *Flavobacterium psychrophilum* and oxytetracycline. *Aquaculture Research* **32**: 235–241.
- Marino G, Boglione C, Bertolini B, Rossi A, Ferreri F, Cataudella S (1993) Observations on development and anomalies in the appendicular skeleton of sea bass, *Dicentrarchus labrax* L. 1758, larvae and juveniles. *Aquaculture and Fisheries Management* **24**: 445–456.
- Massee KC, Rust MB, Hardy RM, Stickney RR (1995) The effectiveness of tricaine, quinaldine sulfate and metomidate as anesthetics for larval fish. *Aquaculture* **134** (3–4): 351–359.
- Matsuoka M (1987) Development of the skeletal tissues and skeletal muscles in the red sea bream. *Bulletin of the Seikai Regional Fisheries Research Laboratory* **65**: 1–114.
- Matsuoka M (2003) Comparison of meristic variations and bone abnormalities between wild and laboratory-reared red sea bream. *Japanese American Research Center* **37**: 21–30.
- Matsusato T (1986) Studies on skeletal anomaly of fishes. *Bulletin of the National Research Institute of Aquaculture* **10**: 57–179 (in Japanese with English abstract).
- Mazurais D, Darias MJ, Gouillou-Coustans MF, Le Gall MM, Huelvan C, Desbruyères E *et al.* (2008) Dietary vitamin mix levels influence the ossification process in European sea bass (*Dicentrarchus labrax*) larvae. *American Journal of Physiology, Regulatory Integrative and Comparative Physiology* **294**: 520–527.
- Mazurais D, Glynatsi G, Darias MJ, Christodoulopoulou S, Cahu CL, Zambonino-Infante JL *et al.* (2009) Optimal levels of dietary vitamin A for reduced deformity incidence during development of European sea bass larvae (*Dicentrarchus labrax*) depend on malformation type. *Aquaculture* **294**: 262–270.
- McDowell L (2000) *Vitamins in Animal and Human Nutrition*, 2nd edn. Iowa State University Press, Ames, Iowa.
- McLean RR, Jacques PF, Selhub J, Fredman L, Tucker KL, Samelson EJ *et al.* (2008) Plasma B vitamins, homocysteine, and their relation with bone loss and hip fracture in elderly men and women. *Journal of Clinical Endocrinology and Metabolism* **93**: 2206–2212.
- Merchie G, Lavens P, Dhert Ph, Pector R, Mai Soni AF, Abbes M *et al.* (1995) Live food mediated vitamin C transfer to *Dicentrarchus labrax* and *Clarias gariepinus*. *Journal of Applied Ichthyology* **11**: 336–341.
- Merchie G, Lavens P, Dhert Ph, Góamez MGU, Nelis H, De Leenheer A *et al.* (1996) Dietary ascorbic acid requirements during the hatchery production of turbot larvae. *Journal of Fish Biology* **49**: 573–583.
- Middaugh DP, Fournie JW, Hemmer MJ (1990) Vertebral abnormalities in juvenile inland silversides *Menidia beryllina* exposed to terbufos during embryogenesis. *Diseases of Aquatic Organisms* **9**: 109–116.
- Misra S, Peak D, Niyogi S (2010) Application of XANES spectroscopy in understanding the metabolism of selenium in isolated rainbow trout hepatocytes: insights into selenium toxicity. *Metallomics* **2**: 710–717.
- Mollan TA, Tonheim SK, Hamre K (2008) Pre-hydrolysis improves absorption of neutral lipids in Atlantic halibut (*Hippoglossus hippoglossus*, L.) larvae. *Aquaculture* **275**: 217–224.
- Moren M, Opstad I, Berntssen MHG, Zambonino Infante JL, Hamre K (2004) An optimum level of vitamin A supplements for Atlantic halibut (*Hippoglossus hippoglossus* L.) juveniles. *Aquaculture* **235**: 587–599.
- Moren M, Opstad I, Van der Meeren T, Hamre K (2006) Iodine enrichment of *Artemia* and enhanced levels of iodine in Atlantic halibut larvae (*Hippoglossus hippoglossus* L.) fed the enriched *Artemia*. *Aquaculture* **12**: 97–102.
- Moren M, Waagbø R, Hamre K (2011) Micronutrients. In: Holt GJ (ed.) *Larval Fish Nutrition*, pp. 117–149. Wiley-Blackwell, Oxford.
- Naess T, Germain-Henry M, Naas KE (1995) First feeding of Atlantic halibut (*Hippoglossus hippoglossus*) using different combinations of *Artemia* and wild zooplankton. *Aquaculture* **130**: 235–250.
- National Research Council (2011) *Nutrient Requirements of Fish*. National Academy Press, Washington, DC.
- Navarro JC, Henderson RJ, McEvoy LA, Bell MV, Amat F (1999) Lipid conversions during enrichment of *Artemia*. *Aquaculture* **174**: 155–166.

- Navarro A, Zamorano MJ, Hildebrandt S, Ginés R, Aguilera C, Afonso JM (2009) Estimates of heritabilities and genetic correlations for growth and carcass traits in gilthead seabream (*Sparus auratus* L.), under industrial conditions. *Aquaculture* **289**: 225–230.
- Nguyen VT, Satoh S, Haga Y, Fushimi H, Kotani T (2008) Effect of zinc and manganese supplementation in *Artemia* on growth and vertebral deformity in red sea bream (*Pagrus major*) larvae. *Aquaculture* **285**: 184–192.
- Nordvik K, Kryvi H, Totland GK, Grotmol S (2005) The salmon vertebral body develops through mineralization of two preformed tissues that are encompassed by two layers of bone. *Journal of Anatomy* **206**: 103–114.
- Okada N, Tanaka M, Tagawa M (2003) Bone development during metamorphosis of the Japanese flounder (*Paralichthys olivaceus*): differential responses to thyroid hormone. In: Browman HI, Skiftesvik AB (eds) *The Big Fish Bang. Proceedings of the 26th Annual Larval Fish Conference*, pp. 177–187. Institute of Marine Research, Postboks 1870 Nordnes, N-5817, Bergen, Norway. ISBN 82-7461-059-8.
- Oku H, Umino T (2008) Molecular characterization of peroxisome proliferator-activated receptors (PPARs) and their gene expression in the differentiating adipocytes of red sea bream *Pagrus major*. *Comparative Biochemistry and Physiology. B, Comparative Biochemistry* **151**: 268–277.
- Olsvik PA, Hansen BH, Nordtug T, Moren M, Holen E, Lie KK (2011) Transcriptional evidence for low contribution of oil droplets to acute toxicity from dispersed oil in first feeding Atlantic cod (*Gadus morhua*) larvae. *Comparative Biochemistry and Physiology C: Toxicology and Pharmacology* **154**: 333–345.
- Önal U, Langdon C (2009) Potential delivery of water-soluble protein hydrolysates to marine suspension feeders by three different microbound particle types. *Aquaculture* **296**: 174–178.
- Oppedal F, Taranger GL, Hansen T (2003) Growth performance and sexual maturation in diploid and triploid Atlantic salmon (*Salmo salar* L.) in seawater tanks exposed to continuous light or simulated natural photoperiod. *Aquaculture* **215**: 145–162.
- O'Reilly P, Wright JM (1995) The evolving technology of DNA fingerprinting and its application to fisheries and aquaculture. *Journal of Fish Biology* **47**: 29–55.
- Paperna I (1978) Swimbladder and skeletal deformations in hatchery bred *Sparus aurata*. *Journal of Fish Biology* **12**: 109–114.
- Paperna I, Ross B, Colorni A, Colorni B (1980) Disease of marine fish cultured in Eliat mariculture project. *Studies and Reviews – General Fisheries Council for the Mediterranean* **57**: 29–32.
- Parhami F, Morrow AD, Balucan J, Leitinger N, Watson AD, Tintut Y *et al.* (1997) Lipid oxidation products have opposite effects on calcifying vascular cell and bone cell differentiation. *Arteriosclerosis Thrombosis and Vascular Biology* **17**: 680–687.
- Park EH, Kim DS (1984) A procedure for staining cartilage and bone of whole vertebrate larvae while rendering all other tissues transparent. *Stain Technology* **59**: 269–272.
- Pearse AGE (ed.) (1985) *Histochemistry. Theoretical and Applied. Vol. 2: Analytical Technology*, 4th edn. Churchill Livingstone Inc., Edinburgh, UK.
- Penglas S, Nordgreen A, van der Meeren T, Olsvik PA, Sæle Ø, Sweetman JW *et al.* (2010) Increasing the level of selenium in rotifers (*Brachionus plicatilis* 'Cayman') enhances the mRNA expression and activity of glutathione peroxidase in cod (*Gadus morhua* L.) larvae. *Aquaculture* **306**: 259–269.
- Peruzzi S, Westgaard J-I, Chatain B (2007) Genetic investigation of swimbladder inflation anomalies in the European sea bass, *Dicentrarchus labrax* L. *Aquaculture* **265** (1–4): 102–108.
- Piferrer F, Beaumont A, Falguiere J-C, Flajshans M, Haffray P, Colombo L (2009) Polyploid fish and shellfish: production, biology and applications to aquaculture for performance improvement and genetic containment. *Aquaculture* **293** (3–4): 125–156.
- Pittman K, Jelmert A, Næss T, Harboe T, Watanabe K (1998) Plasticity of viable postmetamorphic forms of farmed Atlantic halibut, *Hippoglossus hippoglossus* L. *Aquaculture Research* **29**: 949–954.
- Polo A, Yúfera M, Pascual E (1991) Effects of temperature on egg and larval development of *Sparus aurata* L. *Aquaculture* **92**: 367–375.
- Poulsen RC, Moughan PJ, Kruger MC (2007) Long-chain polyunsaturated fatty acids and the regulation of bone metabolism. *Experimental Biology and Medicine* **232**: 1275–1288.
- Prestinicola L (2012) Environmental effects on the skeleton development in advanced teleost fish (PhD thesis in Evolutionary Biology and Ecology). XXIV Cycle University of Rome 'Tor Vergata', Faculty of Science, Biology Department, Rome.
- Price PA (1988) Role of vitamin-K-dependent proteins in bone metabolism. *Annual Review of Nutrition* **8**: 565–583.
- Ribeiro ARA, Riberio L, Saele O, Hamre K, Dinis MT, Moren M (2011) Iodine-enriched rotifers and *Artemia* prevent goitre in Senegalese sole (*Solea senegalensis*) larvae reared in a recirculation system. *Aquaculture Nutrition* **17**: 248–257.
- Ribeiro ARA, Riberio L, Saele O, Hamre K, Dinis MT, Moren M (2012) Iodine and selenium supplementation increased survival and changed thyroid hormone status in Senegalese sole (*Solea senegalensis*) larvae reared in a recirculation system. *Fish Physiology and Biochemistry* **38**: 725–734.
- Roberto V (2006) Gla protein localisation and histological characterisation of bone structures in relevant aquaculture fish (MSc Thesis). Faculdade de Ciências do Mare e do Ambiente, Universidade do Algarve, Faro.
- Robey PG (2002) Bone matrix proteoglycans and glycoproteins. In: Bilezikian JP, Raisz L, Rodan GA (eds) *Principles of Bone Biology*, 2nd edn, pp. 225–238. Academic Press, London.
- Robinson EH, Rawles SD, Yette HE, Greene LW (1984) An estimate of the dietary calcium requirement of fingerling *Tilapia aurea* reared in calcium-free water. *Aquaculture* **41**: 389–393.

- Rodrigues P, Gonçalves C, Bairos V (2004) Metabolic pathways and modulating effects of vitamin A. *Current Medicinal Chemistry: Immunology, Endocrine & Metabolic Agents* **4**: 119–142.
- Rønnestad I, Tonheim SK, Fyhn HJ, Rojas-García CR, Kamisaka Y, Koven W *et al.* (2003) The supply of amino acids during early feeding stages of marine fish larvae: a review of recent findings. *Aquaculture* **227**: 147–164.
- Rønnestad I, Yúfera M, Ueberschär B, Ribeiro L, Sæle Ø, Izquierdo M *et al.* (2013) Feeding behaviour and digestion physiology in larval fish – current knowledge and gaps and bottlenecks in research. *Reviews in Aquaculture* **5**: s59–s98.
- Roo FJ, Hernández-Cruz CM, Socorro JA, Fernández-Palacios H, Montero D, Izquierdo MS (2009) Effect of DHA content in rotifers on the occurrence of skeletal deformities in red porgy *Pagrus pagrus* (Linnaeus, 1758). *Aquaculture* **287**: 84–93.
- Rosenthal HL, Rosenthal RS (1950) Lordosis, a mutation in the guppy *Lebistes reticulatus*. *Journal of Heredity* **41**: 217–218.
- Ross SA, Caffery PJ, Dragner UC, De Luca LM (2000) Retinoids in embryonal development. *Physiological Reviews* **80**: 1021–1054.
- Roy P, Lall S (2007) Vitamin K deficiency inhibits mineralization and enhances deformity in vertebrae of haddock (*Melanogrammus aeglefinus* L.). *Comparative Biochemistry and Physiology. B, Comparative Biochemistry* **148**: 174–183.
- Russo T, Prestinicola L, Scardi M, Palamara E, Cataudella S, Boglione C (2010) Progress in modeling quality in aquaculture: an application of the self-organizing map to the study of skeletal anomalies and meristic counts in gilthead seabream (*Sparus aurata*, L. 1758). *Journal of Applied Ichthyology* **26**: 360–365.
- Russo T, Scardi M, Boglione C, Cataudella S (2011) Application of the Self-Organizing Map to the study of skeletal anomalies in aquaculture: the case of dusky grouper (*Epinephelus marginatus* Lowe, 1834) juveniles reared under different rearing conditions. *Aquaculture* **315**: 69–77.
- Saavedra M, Pousao-Ferreira P, Yúfera M, Dinis MT, Conceição LEC (2009) A balanced amino acid diet improves *Diplodus sargus* larval quality and reduces nitrogen excretion. *Aquaculture Nutrition* **15**: 517–524.
- Saavedra M, Conceição LEC, Barr Y, Helland S, Pousão-Ferreira P, Yúfera M *et al.* (2010) Tyrosine and phenylalanine supplementation on *Diplodus sargus* larvae: effect on growth and quality. *Aquaculture Research* **41**: 1523–1532.
- Sadler J, Pankhurst PM, King HR (2001) High prevalence of skeletal deformity and reduced gill surface area in triploid Atlantic salmon (*Salmo salar* L.). *Aquaculture* **198**: 369–386.
- Saele O, Solbakken JS, Watanabe K, Hamre K, Pittman K (2003) The effect of diet on ossification and eye migration in Atlantic halibut larvae (*Hippoglossus hippoglossus* L.). *Aquaculture* **220** (1): 683–696.
- Saele O, Solbakken JS, Watanabe K, Hamre K, Power D, Pittman K (2004) Staging of Atlantic halibut (*Hippoglossus hippoglossus* L.) from first feeding through metamorphosis, including cranial ossification independent of eye migration. *Aquaculture* **239**: 445–465.
- Santamaria JA, Andrades JA, Herráez P, Fernández-Llebreg P, Becerra J (1994) Perinotochordal connective sheet of gilthead sea bream larvae (*Sparus aurata*, L.) affected by axial malformations: an histochemical and immunocytochemical study. *The Anatomical Record* **240**: 248–254.
- Sargent JR, Tocher DR, Bell JG (2002) The lipids. In: Halver JE, Hardy RW (eds) *Fish Nutrition*, 3rd edn, pp. 182–259. Academic Press Inc., San Diego, CA.
- Satoh M, Kondo T, Yoshinaka R, Kuroshima R, Morimoto H, Ikeda S (1983) Effect of water temperature on the skeletal deformity in ascorbic acid-deficient rainbow trout. *Bulletin of the Japanese Society of Scientific Fisheries* **49**: 443–446.
- Satoh S, Takeuchi T, Watanabe T (1987) Availability to carp of manganese in white fish meal and of various manganese compounds. *Nippon Suisan Gakkaishi* **53**: 825–832.
- Sawada Y, Hattori M, Sudo N, Kato K, Takagi Y, Ura K *et al.* (2006) Hypoxic conditions induce centrum defects in red sea bream *Pagrus major* (Temminck and Schlegel). *Aquaculture Research* **37**: 805–812.
- Schreiber AM (2006) Asymmetric craniofacial remodeling and lateralized behavior in larval flatfish. *The Journal of Experimental Biology* **209**: 610–621.
- Setiadi E, Tsumura S, Kassam D, Yamaoka L (2006) Effect of saddleback syndrome and vertebral deformity on the body shape and size in hatchery-reared juvenile red spotted grouper, *Epinephelus akaara* (Perciformes: Serranidae): a geometric morphometric approach. *Journal of Applied Ichthyology* **22**: 49–53.
- Sfakianakis DG, Koumoundouros G, Anezaki L, Divanach P, Kentouri M (2003) Development of a saddleback-like syndrome in reared white seabream *Diplodus sargus* (Linnaeus, 1758). *Aquaculture* **217**: 673–676.
- Sfakianakis DG, Georgakopoulou E, Kentouri M, Koumoundouros G (2006a) Geometric quantification of lordosis effects on body shape in European sea bass, *Dicentrarchus labrax* (Linnaeus, 1758). *Aquaculture* **256**: 27–33.
- Sfakianakis DG, Georgakopoulou E, Papadakis IE, Divanach P, Kentouri M, Koumoundouros G (2006b) Environmental determinants of haemal lordosis in European sea bass, *Dicentrarchus labrax* (Linnaeus, 1758). *Aquaculture* **254**: 54–64.
- Sheffield VC, Seegmiller RE (1980) Impaired energy metabolism as an initial step in the mechanism for 6-aminonicotinamide-induced limb malformation. *Journal of Embryology and Experimental Morphology* **59**: 217–222.
- Silverstone AM, Hamell L (2002) Spinal deformities in farmed Atlantic salmon. *Canadian Veterinary Journal* **43**: 782–784.
- Skaala O, Hoyheim B, Glover K, Dahle G (2004) Microsatellite analysis in domesticated and wild Atlantic salmon (*Salmo salar* L.): allelic diversity and identification of individuals. *Aquaculture* **240**: 131–143.

- Small BC (2003) Anesthetic efficacy of metomidate and comparison of plasma cortisol responses to tricaine methanesulfonate, quinaldine and clove oil anesthetized channel catfish *Ictalurus punctatus*. *Aquaculture* **217**: 177–185.
- Solbakken JS, Berntssen MHG, Norberg B, Pittman K, Hamre K (2002) Different iodine and thyroid hormone levels between Atlantic halibut larvae fed wild zooplankton or *Artemia* from first exogenous feeding until post metamorphosis. *Journal of Fish Biology* **61**: 1345–1362.
- Stehr CM, Linbo TL, Incardona JP, Scholz NL (2006) The developmental neurotoxicity of fipronil: notochord degeneration and locomotor defects in zebrafish embryos and larvae. *Toxicological Sciences* **92**: 270–278.
- Sugama K, Taniguchi N, Seki S, Nabeshima H (1992) Survival, growth and gonad development of triploid red sea bream, *Pagrus major* (Temminck et Schlegel): use of allozyme markers for ploidy and family identification. *Aquaculture Research* **23**: 149–159.
- Sugiura SH, Hardy RW, Roberts RJ (2004) The pathology of phosphorus deficiency in fish – a review. *Journal of Fish Diseases* **27**: 255–265.
- Sullivan M, Reid SWJ, Ternent H, Manchester NJ, Roberts RJ, Stone DAJ *et al.* (2007) The aetiology of spinal deformity in Atlantic salmon, *Salmo salar* L.: influence of different commercial diets on the incidence and severity of the preclinical condition in salmon parr under two contrasting husbandry regimes. *Journal of Animal Physiology and Animal Nutrition* **30**: 759–767.
- Suzuki T, Oochara I, Kurokawa T (1999) Retinoic acid given at late embryonic stage depresses sonic hedgehog and Hoxd-4 expression in the pharyngeal area and induces skeletal malformation in flounder (*Paralichthys olivaceus*) embryos. *Development Growth and Differentiation* **41**: 143–152.
- Tacon AGJ (1992) *Nutritional Fish Pathology. Morphological Signs of Nutrient Deficiency and Toxicity in Farmed Fish*. FAO Fish Technical Paper No. 330. FAO, Rome.
- Tacon AGJ (1995) Application of nutrient requirement data under practical conditions: special problems of intensive and semi-intensive fish farming systems. *Journal of Applied Ichthyology* **11**: 205–214.
- Tacon AGJ (1996) Lipid nutritional pathology in farmed fish. *Archives of Animal Nutrition* **49**: 33–39.
- Takeuchi K (1966) 'Wavy-fused' mutants in the medaka, *Oryzias latipes*. *Nature* **211**: 866–867.
- Takeuchi A, Okano T, Kobayashi T (1991) The existence of 25-hydroxyvitamin D<sub>3</sub>-1-hydroxylase in the liver of carp and bastard halibut. *Life Sciences* **48**: 275–282.
- Takeuchi T, Dedi J, Ebisawa C, Watanabe T, Seikai T, Hosoya K *et al.* (1995) The effect of  $\beta$ -carotene and vitamin A enriched *Artemia* nauplii on the malformation and color abnormality of larval Japanese flounder. *Fisheries Science* **61**: 141–148.
- Takeuchi T, Dedi J, Haga Y, Seikai T, Watanabe T (1998) Effect of vitamin A compounds on bone deformity in larval Japanese flounder (*Paralichthys olivaceus*). *Aquaculture* **169**: 155–165.
- Tandler A, Anav FA, Choshniak I (1995) The effect of salinity on growth rate, survival and swimbladder inflation in gilt-head seabream, *Sparus aurata*, larvae. *Aquaculture* **135**: 343–353.
- Tarui F, Haga Y, Ohta K, Shima Y, Takeuchi T (2006) Effect of *Artemia* nauplii enriched with vitamin A palmitate on hypermelanosis on the blind side in juvenile Japanese flounder *Paralichthys olivaceus*. *Fisheries Science* **72**: 256–262.
- Taylor JF, Preston AC, Guy D, Migaud H (2011) Ploidy effects on hatchery survival, deformities, and performance in Atlantic salmon (*Salmo salar*). *Aquaculture* **315** (1–2): 61–68.
- Taylor JF, Leclercq E, Preston AC, Guy D, Migaud H (2012) Parr-smolt transformation in out-of-season triploid Atlantic salmon (*Salmo salar* L.). *Aquaculture* **362–363**: 255–263.
- Terova G, Saroglia M, Papp ZG, Cecchini S (1998) Dynamics of collagen indicating amino acids, in embryos and larvae of sea bass (*Dicentrarchus labrax*) and gilthead sea bream (*Sparus aurata*), originated from broodstocks fed with different vitamin C content in the diet. *Comparative Biochemistry and Physiology. A, Comparative Physiology* **121**: 111–118.
- Thorland I, Papaioannou N, Kottaras L, Refstie T, Papisolomontos S, Rye M (2007) Family based selection for production traits in gilthead seabream (*Sparus aurata*) and European sea bass (*Dicentrarchus labrax*) in Greece. *Aquaculture* **272**: S314.
- Tocher DR (2010) Fatty acid requirements in ontogeny of marine and freshwater fish. *Aquaculture Research* **41**: 717–732.
- Tocher DR, Bendiksen EA, Campbell PJ, Bell JG (2008) The role of phospholipids in nutrition and metabolism of teleost fish. *Aquaculture* **280**: 21–34.
- Toften H, Jobling M (1996) Development of spinal deformities in Atlantic salmon and Arctic charr fed diets supplemented with oxytetracycline. *Journal of Fish Biology* **49**: 668–677.
- Trotter AJ, Pankhurst PM, Battaglene SC (2004) Morphological development of the swim bladder in hatchery-reared striped trumpeter *Latris lineata*. *Journal of Applied Ichthyology* **20**: 395–401.
- Tseng W, Lu J, Bishop GA, Watson AD, Sage AP, Demer L *et al.* (2010) Regulation of interleukin-6 expression in osteoblasts by oxidized phospholipids. *Journal of Lipid Research* **51**: 1010–1016.
- Udagawa M (2001) The effect of dietary vitamin K (phyloquinone and menadione) levels on the vertebral formation in mummichog *Fundulus heteroclitus*. *Fisheries Science* **67**: 104–109.
- Udagawa M (2004) The effect of parental vitamin K deficiency on bone structure in mummichog *Fundulus heteroclitus*. *Journal of the World Aquaculture Society* **35**: 366–371.
- Udagawa M (2006) Studies on the distribution and physiological function of vitamin K in fish. *Bulletin of Fisheries Research Agency* **18**: 1–40.
- Urist MR, Iwata H (1973) Preservation and biodegradation of the morphogenetic property of bone matrix. *Journal of Theoretical Biology* **38**: 155–167.

- Uyan O, Koshio S, Ishikawa M, Uyan S, Ren T, Yokoyama S *et al.* (2007) Effects of dietary phosphorus and phospholipid level on growth, and phosphorus deficiency signs in juvenile Japanese flounder, *Paralichthys olivaceus*. *Aquaculture* **267**: 44–54.
- Van der Meer T, Olsen RE, Hamre K, Fyhn HJ (2008) Biochemical composition of copepods for evaluation of feed quality in production of juvenile marine fish. *Aquaculture* **274**: 375–397.
- Van Eeden FJ, Granato M, Schach U, Brand M, Furutani-Seiki M, Haffter P *et al.* (1996) Genetic analysis of fin formation in the zebrafish, *Danio rerio*. *Development* **123**: 255–262.
- Van Leeuwen CJ, Helder T, Seinen W (1986) Aquatic toxicological aspects of dithiocarbamates and related compounds. IV. Teratogenicity and histopathology in rainbow trout (*Salmo gairdneri*). *Aquatic Toxicology* **9**: 147–159.
- Verhaegen Y, Adriaens D, de Wolf T, Dhert P, Sorgeloos P (2007) Deformities in larval gilthead sea bream (*Sparus aurata*): a qualitative and quantitative analysis using geometric morphometrics. *Aquaculture* **268**: 156–168.
- Viegas MN, Dias J, Cancela ML, Laize V (2012) Polyunsaturated fatty acids regulate cell proliferation, extracellular matrix mineralization and gene expression in a gilthead seabream skeletal cell line. *Journal of Applied Ichthyology* **28**: 427–432.
- Villalta M, Estévez A, Bransden MP (2005) Arachidonic acid enriched live prey induces albinism in Senegal sole (*Solea senegalensis*) larvae. *Aquaculture* **245**: 193–209.
- Villeneuve L, Gisbert E, Le Delliou H, Cahu CL, Zambonino-Infante JL (2005a) Dietary levels of all-*trans* retinol affect retinoid nuclear receptor expression and skeletal development in European sea bass larvae. *British Journal of Nutrition* **93**: 1–12.
- Villeneuve L, Gisbert E, Zambonino-Infante JL, Quazuguel P, Cahu CL (2005b) Effects of lipids on European sea bass morphogenesis: implication of retinoid receptors. *British Journal of Nutrition* **94**: 877–884.
- Villeneuve L, Gisbert E, Moriceau J, Cahu CL, Zambonino-Infante JL (2006) Intake of high levels of vitamin A and polyunsaturated fatty acids during different developmental periods modifies the expression of morphogenesis genes in European sea bass (*Dicentrarchus labrax*). *British Journal of Nutrition* **95**: 677–687.
- Von Westernhagen H (1988) Sublethal effects of pollutants on fish eggs and larvae. In: Hoar WS, Randall DJ (eds) *The Physiology of Developing Fish – Eggs and Larvae Fish Physiology*, Vol. 11, Part A, pp. 253–346. Academic Press, New York.
- Waagbø R (2010) Water-soluble vitamins in fish ontogeny. *Aquaculture Research* **41**: 733–744.
- Wang J, Ai Q, Mai K, Xu W, Xu H, Zhang W *et al.* (2010) Effects of dietary ethoxyquin on growth performance and body composition of large yellow croaker *Pseudosciaena crocea*. *Aquaculture* **306**: 80–84.
- Wargelius A, Fjellidal PG, Hansen T (2005) Heat shock during early somitogenesis induces caudal vertebral column defects in Atlantic salmon (*Salmo salar*). *Development Genes and Evolution* **215**: 350–357.
- Wargelius A, Fjellidal PG, Nordgarden U, Hansen T (2009) Continuous light affects mineralization and delays osteoid incorporation in vertebral bone of Atlantic salmon (*Salmo salar* L.). *Journal of Experimental Biology* **212**: 656–661.
- Wargelius A, Fjellidal PG, Grini A, Gil-Martens L, Kvamme B-O, Hansen T (2010) MMP-13 (matrix metalloproteinase 13) expression might be an indicator for increased ECM remodeling and early signs of vertebral compression in farmed Atlantic salmon (*Salmo salar* L.). *Journal of Applied Ichthyology* **26**: 366–371.
- Watanabe T, Kiron V, Satoh S (1997) Trace minerals in fish nutrition. *Aquaculture* **151**: 185–207.
- Watkins BA, Li Y, Lippman HE, Seifert MF (2001) Omega-3 polyunsaturated fatty acids and skeletal health. *Experimental Biology and Medicine* **226**: 485–497.
- Williams ND, Holdway DA (2000) The effects of pulse-exposed cadmium and zinc on embryo hatchability, larval development, and survival of Australian crimson spotted rainbow fish (*Melanotaenia fluviatilis*). *Environmental Toxicology* **15**: 165–173.
- Wilson JG (1959) Experimental studies on congenital malformations. *Journal of Chronic Diseases* **10**: 111–130.
- Witten PE, Huysseune A (2009) A comparative view on mechanisms and functions of skeletal remodeling in teleost fish, with special emphasis on osteoclasts and their function. *Biological Reviews* **84**: 315–346.
- Witten PE, Gil Martens L, Hall BK, Huysseune A, Obach A (2005) Compressed vertebrae in Atlantic salmon (*Salmo salar*): evidence for metaplastic chondrogenesis as a skeletogenic response late in ontogeny. *Diseases of Aquatic Organisms* **64**: 237–246.
- Witten PE, Obach A, Huysseune A, Baeverfjord G (2006) Vertebrae fusion in Atlantic salmon (*Salmo salar*): development, aggravation and pathways of containment. *Aquaculture* **258**: 164–172.
- Witten PE, Gil Martens L, Huysseune A, Takle H, Hjelde K (2009) Classification and developmental relationships of vertebral body malformations in farmed Atlantic salmon (*Salmo salar*). *Aquaculture* **295**: 6–14.
- Woolley LD, Qin JG (2010) Swimbladder inflation and its implication to the culture of marine finfish larvae. *Reviews in Aquaculture* **2**: 181–190.
- Yamashita Y, Katagiri T, Pirarat N, Futami K, Endo M, Maita M (2009) The synthetic antioxidant, ethoxyquin, adversely affects immunity in tilapia (*Oreochromis niloticus*). *Aquaculture Nutrition* **15**: 144–151.
- Ytteborg E, Torgersen J, Baeverfjord G, Takle H (2010) Morphological and molecular characterization of developing vertebral fusions using a teleost model. *BMC Physiology* **10**: 13.
- Zambonino-Infante JL, Cahu CL (2010) Effect of nutrition on marine fish development and quality. In: Koumoundouros G (ed.) *Recent Advances in Aquaculture Research*, pp. 103–124. Transworld Research Network, Kerala, India.
- Zambonino-Infante JL, Cahu CL, Péres A (1997) Partial substitution of di- and tripeptides for native proteins in sea bass

- diet improves *Dicentrarchus labrax* larval development. *Journal of Nutrition* **127**: 608–614.
- Zanuy S, Carrillo M, Blázquez M, Ramos J, Piferrer F, Donaldson EM (1994) Production of monosex and sterile sea bass by hormonal and genetic approaches. *Publications Association Développement Aquaculture* **119**: 409–423.
- Zerekh JE (1993) Bone, growth, remodeling and repair: interaction of parathyroid hormone, calcitonin, vitamin D, growth factors and prostaglandins. In: Foa PP (ed.) *Humoral Factors in the Regulation of Tissue Growth: Blood, Blood Vessels, Skeletal System and Teeth*, pp. 160–193. Springer, New York.