

NECK SWELLINGS IN CHILDREN

Neck lumps are very common in the paediatric population. The majority of these lumps are enlarged lymph nodes that resolve either spontaneously or with antibiotics, however, a small number persist or enlarge and may cause considerable concern. The aim of this article is to assist with decision-making in the management of persistent neck lumps in children

It is useful to classify paediatric neck lumps into two broad categories: **midline** and **lateral**, as each group is managed differently. In general, midline neck masses are developmental until proven otherwise, and lateral neck masses are lymph nodes until proven otherwise.

Paediatric head and neck lumps differ from those in adults in that malignancy is much less likely, although occasionally tumours such as lymphoma or rhabdomyosarcoma may present as neck lumps.

The following discussion outlines some of the common neck swellings seen in children, with a logical approach to investigation and management of these conditions.

Lateral Neck Masses

When taking the history, it is important to note the age of the patient at onset of the mass, its duration, change in size, and any associated systemic symptoms. On examination, cystic masses can generally be distinguished

from solid masses, and it is important to look for any skin changes or sinus openings associated with the mass. The most useful investigation is fine needle aspiration (FNA) cytology.

The most common lateral neck mass seen in children is an enlarged lymph node due to viral or bacterial lymphadenitis, including infection with nontuberculous mycobacteria. Branchial cleft cysts are the second common cause, and there are a number of other possible diagnoses such as lymphangioma, haemangioma, and malignancy. Lymphadenopathy and branchial cleft cysts are briefly described below.

Lymphadenopathy (Benign Lymphoid Hyperplasia)

Cervical lymphadenopathy in children is commonly due to bacterial or viral infection, usually originating in the upper aerodigestive tract. These lymph nodes are usually less than 1 cm in diameter, often multiple, soft, and situated in the upper cervical region. They may remain enlarged for some weeks after the primary infection has resolved. Non-tuberculous *Mycobacterium* (NTM) is a cause of persistent lymphadenopathy. This should be referred for FNA or excision biopsy after a course of antibiotics and a period of observation.

Non-Tuberculous *Mycobacterium*

Infection with NTM, or atypical mycobacteria, most commonly affects children under the age of 5 years. It usually causes a unilateral lymph

JAMIE RYAN AND MURALI MAHADEVAN

Department of Paediatric Otolaryngology,
Head and Neck Surgery,
Starship Children's Hospital,
Auckland, New Zealand

Salient Points

- Lateral neck lumps are usually enlarged lymph nodes, and may be treated initially with antibiotics. Differential diagnoses include branchial cleft cyst, non-tuberculous *Mycobacterium*, and benign and malignant neoplasms
- A midline neck lump that moves on swallowing is thyroid in origin (this includes a thyroglossal duct cyst). Differential diagnoses include dermoid cyst, plunging ranula, lymph node, and lymphangioma
- Fine needle aspiration cytology is the most useful investigation for neck lumps in children, but may require a general anaesthetic
- Malignancy is still a consideration in the paediatric population

node enlargement, often adjacent to the submandibular or parotid gland. The child is usually well, with a non-tender neck mass and no systemic symptoms. The mass is often fixed to the skin and may be discharging through a sinus (Figure 1). The chest X-ray is normal in most cases. Over 95% of these infections are due to *Mycobacterium avium-intracellulare* complex (MAC).

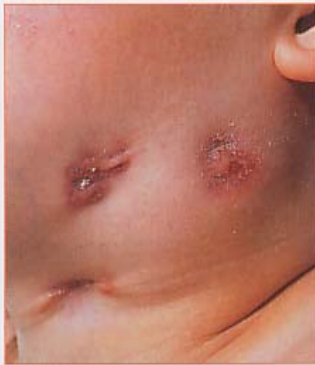

Figure 1. Lymphadenopathy due to non-tuberculous *Mycobacterium*. The three sinuses associated with the mass discharge intermittently.

NTM are found in soil, water, food, plants, and in the pharyngeal secretions of healthy people. There is no evidence for person-to-person transmission. The organism is thought to gain entry through the mucous membranes of the mouth, oropharynx or eye. Histology may demonstrate granulomatous inflammation, but there are no features specific to NTM. It is important to distinguish NTM from *Mycobacterium tuberculosis* as it has quite a different clinical course and treatment.

Treatment of NTM is by surgical excision of the mass. These organisms are often resistant to conventional anti-tuberculous medication. A review of recent cases at Starship Children's Hospital, Auckland, New Zealand showed that complete excision gives the best rate of healing compared with other procedures, such as needle aspiration, incision and drainage or curettage.

Branchial Cleft Cysts

Branchial cleft cysts are developmental anomalies, thought to arise from incomplete closure of embryological branchial clefts. They usually present in the first or second decade of life as a smooth, round, non-tender neck lump (Figure 2). The mass may become inflamed or form an abscess following an upper respiratory tract infection. The second branchial cleft cyst is the most common type, found high in the neck, deep to the anterior border of the sternomastoid muscle.

FNA cytology provides the most useful information. Ultrasound is generally not required, and CT/MRI scans may be useful for surgical planning.

Management is surgical excision, after treatment of any acute infection.

Management of Lateral Neck Masses

A diagnostic approach to managing lateral neck masses is shown in Figure 3.

It is usually possible to determine whether the mass is cystic or solid by palpation.

Cystic masses that appear infected should be referred to a surgeon for incision and drainage, with biopsy of the cyst wall and microbiological culture. Whether or not the mass subsequently resolves determines the need for imaging or further surgery. Cystic masses that are not infected should be referred for FNA cytology, as this will yield the diagnosis in most cases. In the case of a child, general anaesthetic is often required for FNA.

Solid lateral neck masses in children are most likely to be a lymph node, so empirical treatment with a 2-week course of a broad-spectrum antibiotic such as amoxicillin/clavulanic acid is appropriate. If the mass is still present 6 weeks after commencing the antibiotics, surgical referral is necessary.

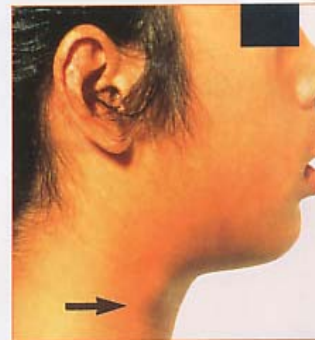


Figure 2. Branchial cleft cyst (arrow) at the anterior border of the sternomastoid muscle.

Midline Neck Masses

Midline neck swellings in children may be considered to be a different entity to lateral masses, as they comprise a different group of diagnoses and often require different investigations and treatment.

Important features in the history of a midline lump are the duration and progression of the mass, and whether there are any local symptoms such as pain. On examination, it is important to note whether the mass moves with swallowing or tongue protrusion, as well as whether the mass feels cystic or solid. Ultrasound scanning is useful for midline neck masses, as well as FNA.

The most common types of midline neck masses seen in children have a developmental aetiology, such as thyroglossal duct cyst and dermoid cyst. Midline lymph nodes and plunging ranula may also occur in children. Other causes include thyroid nodules, haemangioma and lymphangioma. Occasionally, normal anatomical structures are mistakenly thought to be neck masses. The thyroglossal duct cyst, dermoid cyst and plunging ranula are outlined below.

Thyroglossal Duct Cysts

This is the most common midline neck cyst. These cysts form in a persistent thyroglossal duct, so may occur anywhere between foramen caecum in the tongue and the thyroid

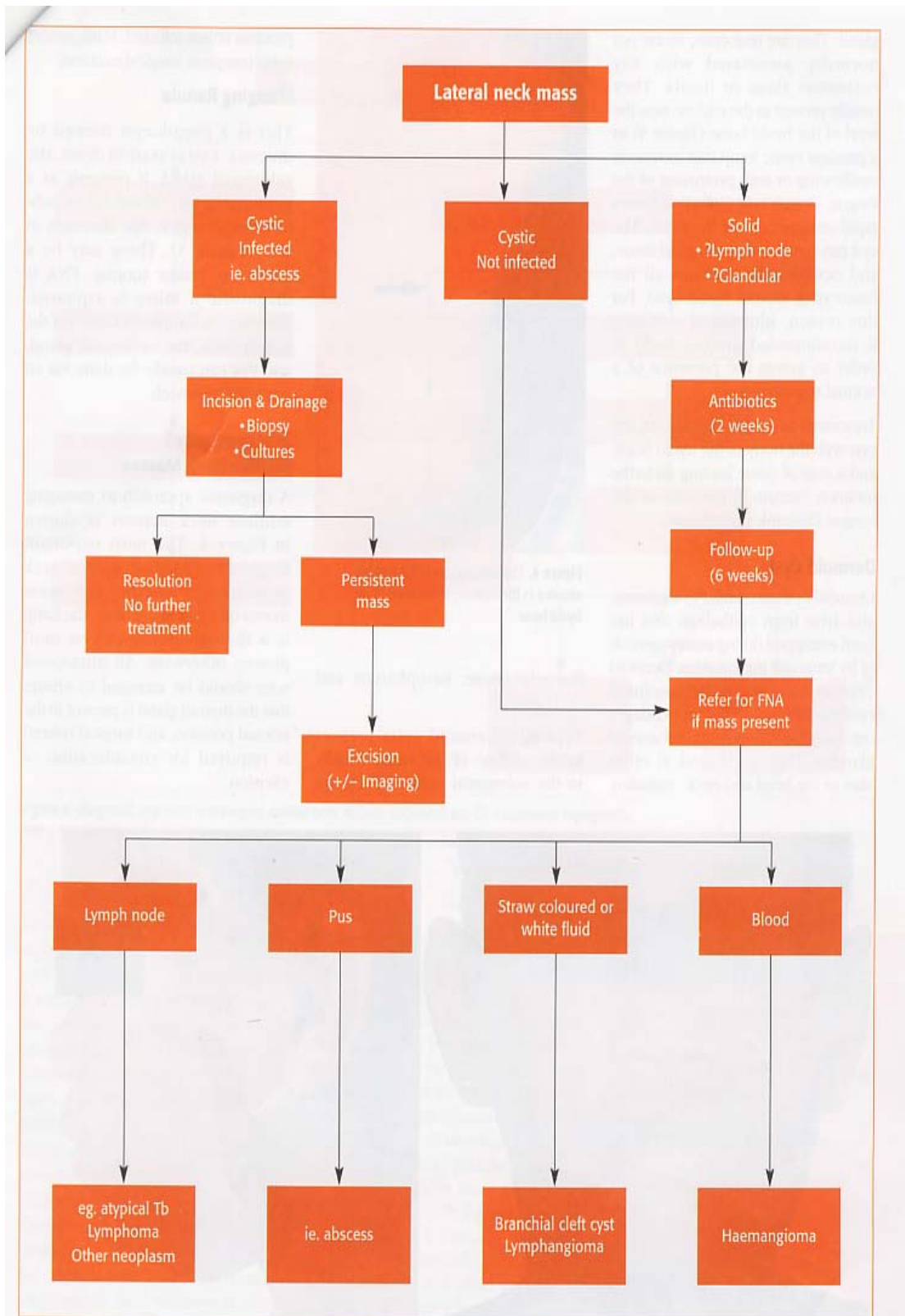


Figure 3. Diagnostic approach to managing lateral neck masses.

gland. They are true cysts, so are not normally associated with any cutaneous sinus or fistula. They usually present in the midline near the level of the hyoid bone (Figure 4) as a painless cystic lump that moves on swallowing or with protrusion of the tongue. Occasionally, infection causes rapid enlargement of the mass. The cyst can contain ectopic thyroid tissue, and occasionally contains all the functioning thyroid tissue (1%). For this reason, ultrasound scanning is recommended preoperatively in order to assess the presence of a normal thyroid gland.

Treatment involves excision of the cyst with the body of the hyoid bone, and a core of tissue leading up to the foramen caecum in the base of the tongue (Sistrunk's procedure).

Dermoid Cysts

Dermoid cysts are similar to teratomas, and arise from epithelium that has been entrapped during embryogenesis or by traumatic implantation. Dermoid cysts consist of epithelium-lined cavities filled with skin appendages (eg. hair, hair follicles, and sebaceous glands). They are found at other sites in the head and neck, including

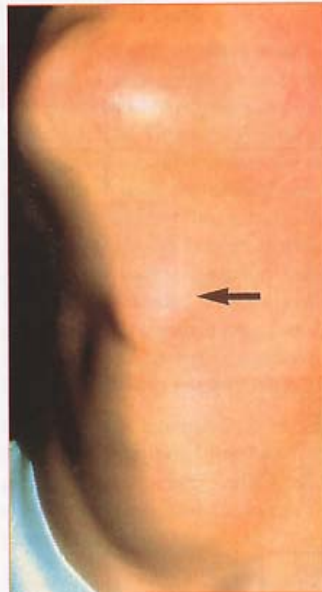


Figure 4. Thyroglossal duct cyst (arrow) situated in the midline, at the level of the hyoid bone.

the orbit, nose, nasopharynx and oral cavity.

Typically, dermoid cysts present in the midline of the neck, usually in the submental region. They are

painless unless infected. Management is by complete surgical excision.

Plunging Ranula

This is a pseudocyst formed by mucous extravasation from the sublingual gland. It presents as a swelling in the submental or submandibular region that fluctuates in size (Figure 5). There may be a history of minor trauma. FNA is diagnostic if saliva is aspirated. Treatment is complete excision of the ranula with the sublingual gland, and this can usually be done via an intra-oral approach.

Management of Midline Neck Masses

A diagnostic approach to managing midline neck masses is shown in Figure 6. The most important diagnostic feature of midline neck swellings is whether the mass moves on swallowing. If so, the lump is a thyroglossal duct cyst until proven otherwise. An ultrasound scan should be arranged to ensure that the thyroid gland is present in the normal position, and surgical referral is required for consideration of excision.

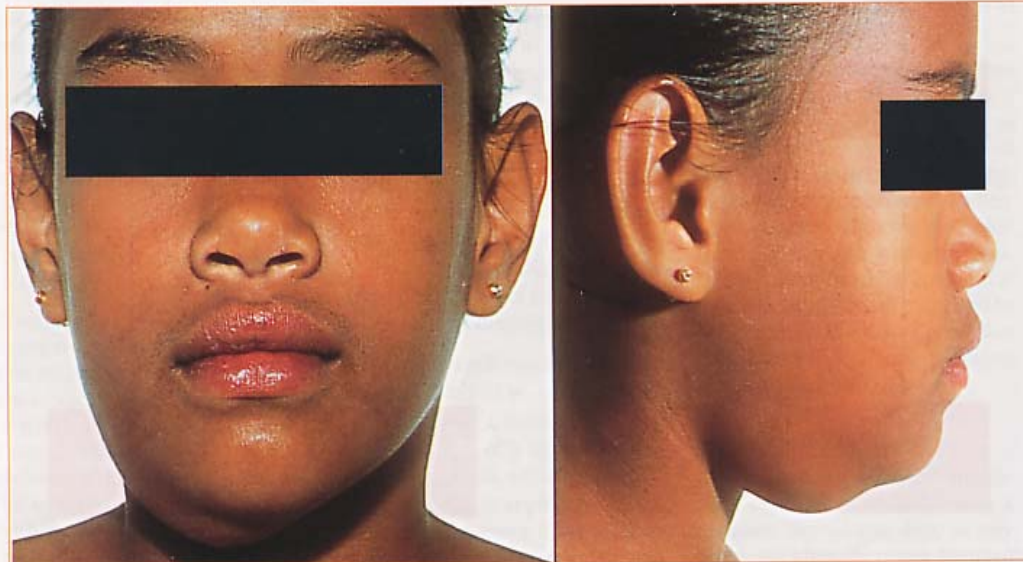

Figure 5. Plunging ranula. This ill-defined soft mass is situated just to the right of the midline in the submental/submandibular region.

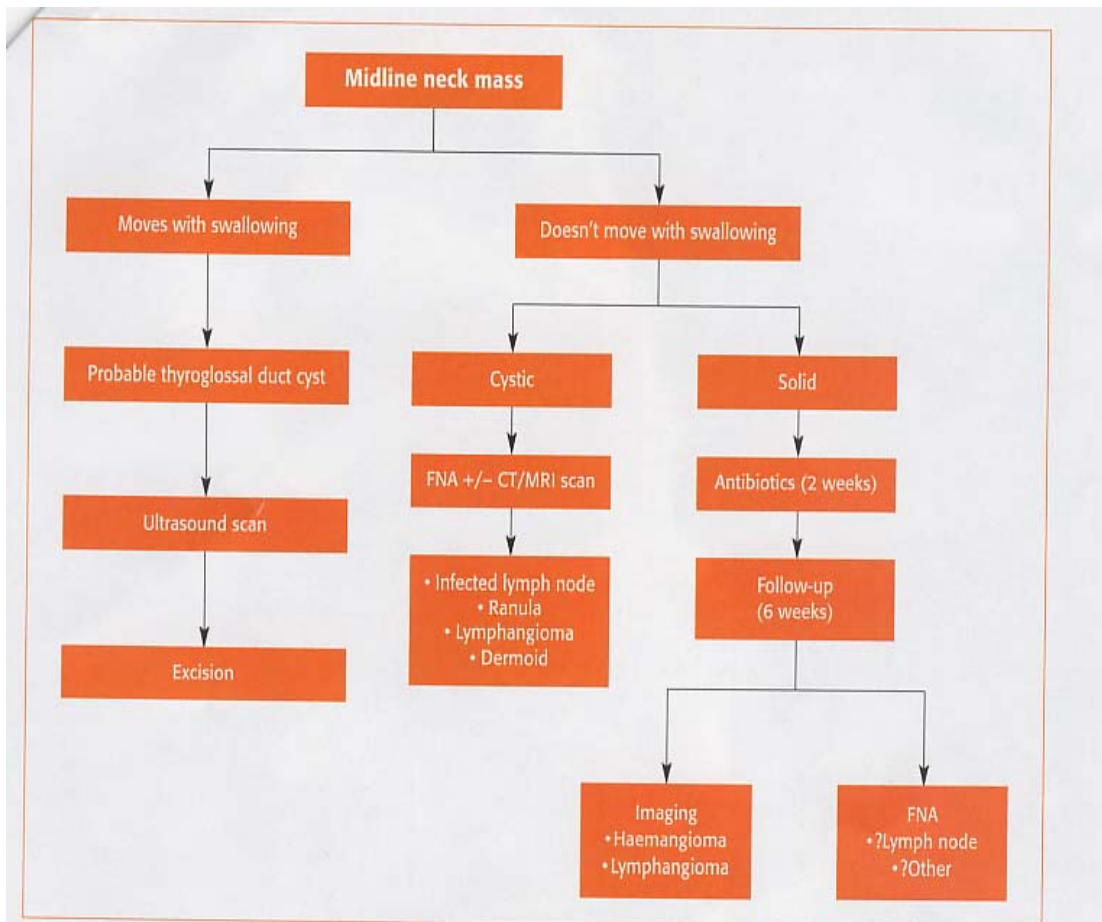


Figure 6. Diagnostic approach to managing midline neck masses. Abbreviations: CT = computed tomography; FNA = fine needle aspiration; MRI = magnetic resonance imaging.

If the lump doesn't move with swallowing then further management depends on whether the lump feels cystic or solid. If it feels solid, a 2-week course of antibiotics should be prescribed and the patient reviewed after 6 weeks. If the lump is no longer present, it was most likely an enlarged lymph node and no further treatment is required. If the lump is still present after 6 weeks then further imaging or FNA may be necessary to arrive at a diagnosis. On the other hand, if the lump feels cystic, the patient should be referred for FNA which may differentiate between an infected lymph node, ranula, dermoid, haemangioma or lymphangioma.

Summary

Neck lumps in children are best considered as midline or lateral. A lateral neck lump is most likely to be a lymph node, and a lump occurring in the midline is most likely to be developmental. FNA cytology is the most useful investigation, although this may require a general anaesthetic in children. Radiological investigations have a role in surgical planning once a diagnosis has been reached, but are not routinely required when evaluating lateral neck lumps. Ultrasound scan is recommended to evaluate the thyroid gland in a child presenting with a midline neck lump. The majority of persistent neck lumps are treated by surgical excision.

CT

This article has been peer reviewed.

Author Details

Jamie Ryan, MBChB, is an otolaryngology registrar and advanced trainee in otolaryngology, head and neck surgery, currently based at Starship Children's Hospital, Auckland, New Zealand.

Murali Mahadevan, MBChB, FRACS, is a consultant surgeon, and has been a paediatric otolaryngologist at Starship Children's Hospital since 1998, with fellowship training from the Royal Children's Hospital, Melbourne and Great Ormond St Children's Hospital, London, UK. His special interests include head and neck surgery and laryngology.

Correspondence: Dr Murali Mahadevan, Paediatric Otolaryngologist, Starship Children's Hospital, Park Road, Private Bag 92024, Auckland, New Zealand.