

UNIVERSITY OF MISSOURI COLLEGE OF AGRICULTURE
AGRICULTURAL EXPERIMENT STATION

F. B. MUMFORD, *Director*

Actinomycosis

(LUMP JAW, BIG JAW, AND WOODEN TONGUE)

in Cattle

J. W. CONNAWAY AND A. W. UREN

COLUMBIA, MISSOURI

SUMMARY

1. Lump jaw, big jaw, or wooden tongue are forms of the same disease affecting different organs or tissues of the mouth or throat region. All of the different forms of the disease are caused by the same infective agent—actinomyces—or ray fungus.

2. The actinomyces or ray fungus grows on grain crops and wild grasses. Animals become infected when grazing on pastures that contain bearded wild grasses that are infested with the ray fungus, or when running to a straw stack that is similarly infected.

3. The disease is not contagious from an infected animal to a well animal. All diseased animals are infected in the same manner—i. e., the awns or beards of infected grain crops or of infected wild grasses carry the actinomyces into the tissues.

4. To prevent animals becoming infected with actinomycosis they should not be allowed to graze on pastures or run to straw stacks where cases of the disease have developed.

5. **Treatment.**—The quickest and surest way to cure a diseased animal is to have the tumor removed surgically by a veterinarian. Where surgical treatment is impossible or dangerous the animals should be treated internally with potassium iodine.

Actinomycosis

(Lump Jaw, Big Jaw, and Wooden Tongue)

J. W. CONNAWAY AND A. W. UREN

An infectious disease known by the scientific term "actinomycosis," and by the common names "lump jaw," "big jaw," and "wooden tongue," occurs with considerable frequency among the cattle herds of Missouri and of many other stock raising states. The disease is also prevalent in the cattle raising districts of England and Scotland, as well as in Continental Europe, where it received scientific study more than 50 years ago. Successful treatment was developed in later years.

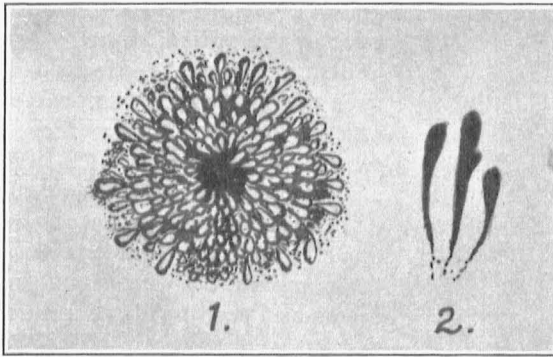


Fig. 1.—Represents at left (1) a clump of the actinomycetes or ray fungi separated from pus of a lump jaw abscess.—Note the radiating arrangement of the fungus clubs. At right (2) shows individual club shaped fungi, more highly magnified.

The common names indicate the location and gross features of the malady, as it is most frequently observed in the living animals; while the scientific term is derived from the name of the fungus which is found in the affected tissues.

When the disease occurs as movable or loose adherent tumors or lumps in the region of the jaw, or in the throat at angle of the jaw, the condition is popularly known as lump jaw; and when the disease invades the hard bony substance of the upper or lower jaw bone, it is known as big jaw. If the tongue is affected, causing an enlargement, ulceration and hardening of that organ, the condition is known as wooden tongue. These several conditions, however, are due to one and the same cause.

CAUSE

While the tumors and lesions in the locations mentioned may occasionally arise from injuries, and from simple wound infections, investigations have shown that they most frequently result from a specific infection or fungus, known as actinomyces, or ray fungus; so called from the radiating arrangement of the fungus filaments in the clumps or colonies occurring in the pus of the diseased tissues. (See Fig. 1.)

The name "actinomycosis," applied to the diseased condition is derived from the name of the fungus causing the inflammation.

This fungus finds very favorable conditions outside the animal body for its growth. And it is probable that its presence in the animal tissues is purely accidental, and that the infection is not of the type which is easily transmitted from one animal directly to another; but that, when several cattle on the same farm are affected, they have been accidentally inoculated from the same common source, and not directly from one another. The actinomyces, or ray fungus grows on the stems and seed heads of a number of forage grasses and grain crops; such as foxtail, rye, barley, bearded wheat, or oats. (See Fig. 2.)

MODE OF INOCULATION

In the greater number of cases the probabilities are that the fungi are carried into the tissues by means of the awns or beards of the bearded grasses mentioned. The writer has observed a number of cases to develop in cattle foraging for a time on stubble fields which have grown up in foxtail after harvesting the grain crop. Cases have also developed in herds of cattle which have wintered around straw stacks which contained bearded seed heads. An authentic instance of transmission of the infection from animal to animal by eating together from the same troughs, in the feed



Fig. 2.—Represents the stem (a) and seed head (b) of a stalk of bearded grain infested with actinomyces. The chalky white deposit is the fungus.

lots. has not been reported. The possibility does exist, however, that an open sore might infect a pasture or field and this might prove infectious to cattle the following year. This fungus, however, is so widespread in nature that the infestation of clean fields is more likely to occur from wind-blown straws that carry the fungi. The more common way of inoculation of an animal is evidently by means of the infected plants when taken as food.

DEVELOPMENT AND COMMON FORMS

The disease assumes different forms, in its gross aspects, according to the organs and tissues invaded. A brief description is given of the disease process and gross development of the different types. Clinical cases are also included to further illustrate the different forms.

Big Jaw Type.—The beards or bits of straw bearing the actinomycetes, when lodged between the teeth, may carry the fungi into the bony structure of the upper or lower jaw; and through inflammation produce a well marked thickening of the bones on each side of the teeth of the affected jaw. The inflammation and infiltra-

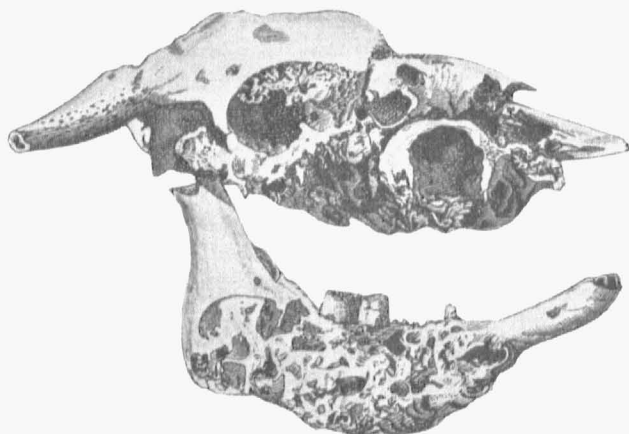


Fig. 3.—Illustration showing loss of molar teeth from upper and lower jaws, and honey-combing of the bone due to actinomycetes.

tion of pus, and the actinomycotic growth, spread apart the plates of the bone, and thus loosen the teeth. The periosteum is also considerably thickened, and the growth of fibrous tissue of the affected part is greatly increased. The bone is often honey-combed by the disease process, but the bony substance remains very dense. By examining the gums on each side of the molar teeth, yellowish ulcerated areas may be found penetrating into the substance of the bone.

An animal affected with the big jaw type of actinomycosis is liable to lose flesh from inability to masticate its food properly. Figures 3 and 6 illustrate some of the effects of actinomycosis of the maxillary bones.

The beards from an infected seed head may carry the actinomyces into the tongue, or into the soft connective tissues and glands of the throat; producing the conditions named above as wooden tongue and lump jaw. A description of these forms of actinomycosis follows.

Wooden Tongue.—In health, the posterior half of the tongue is softer than the anterior portion, and contains numerous taste buds and follicular depressions into which the actinomyces may be carried by the beards of infected seed heads. This portion of the tongue, when infected, is in many cases beset with yellowish sore

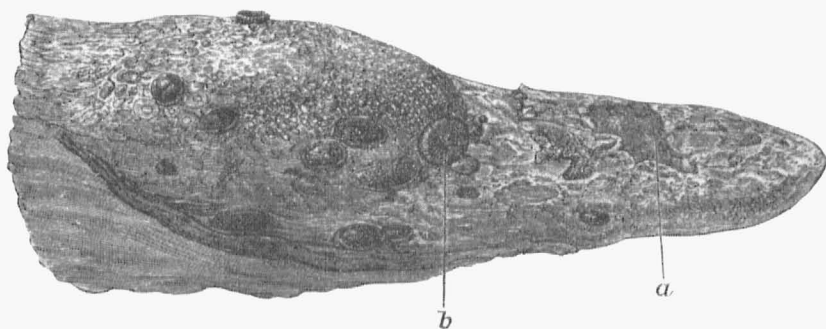


Fig. 4.—Disease of tongue due to actinomycosis infection.—Note the circular circumscribed ulcerations with clear cut margins on the back half of tongue and the denuded patches on forward half. Most of the cases of wooden tongue do not show such extensive lesions.

spots with well defined margins. The inflammation which results causes a swelling and hardening of the tongue, or the condition known as wooden tongue. The tongue when thus affected is very inflexible and has a swollen and more rounded appearance. The animal is unable to use it properly in taking food, and injuries occur on the tip and anterior portion of the tongue, such as the erosion of patches of epithelium. These conditions are illustrated by figure 4, representing the tongue of an animal that was not given treatment. Figure 5 represents an animal with the tongue affection. This animal shows some emaciation from inability to partake of sufficient food, and to masticate it properly.

Lump Jaw Type.—When the fungi are carried into the soft tissues covering the jaw or into the tissues beneath the tongue, or into the glands of the throat, the inflammation results in the lump jaw type of the disease. The tumors are movable or loosely adherent to the bone. They are very hard and do not fluctuate when

pressed upon, like tumors caused by pus abscesses which result from injury, and infection with the ordinary pus bacteria; and when cut into are found to be very fibrous and contain but little fluid pus. At a later stage pus formation may occur to an extent that causes a rupture of the skin, and the escape, by slow suppuration, of portions of the diseased tissues. The tumor, however, does not decrease to any appreciable extent after rupture of the skin. Figures 7, 8 and 9 show the lump jaw tumors. Figure 8 shows a complication of the lump jaw and big jaw types.

DIFFERENTIAL DIAGNOSIS

Thickening of the upper jaw resulting from other causes may also occur, as from abscesses at the roots of the teeth, or in the maxillary sinuses, or cavities of the jaw, due to bacterial infections. The veterinarian, however, can determine this by trephining into the tumor. Cancerous growths on the upper jaw, and particularly about the eyes, may also be mistaken for big jaw, but microscopical examination will correct the diagnosis.

There is some danger of mistaking a tuberculous tumor for the lump jaw form of actinomycosis, and especially when the glands of the throat are involved, as shown in Figure 9. It is therefore important to distinguish carefully between these two diseases on account of the more dangerous character of tuberculosis. A proper diagnosis should be made. The removal of the soft tumor by a competent veterinarian, and a microscopical examination of the pus at the veterinary laboratory will establish the diagnosis.

If the disease is actinomycosis, the fungi which are comparatively large organisms, are easily recognized in simple microscopic preparations by their clublike form, and by their characteristic radiating arrangement. If these fungi are not found, an examination for tuberculosis should be made.

A veterinarian who has had considerable experience in the treatment of lump jaw cases can make a fairly safe diagnosis of actinomycosis without a microscope, by the character of the pus. The actinomycotic pus is very tenacious and hard to dislodge from the tissues; being toughly gelatinous or elastic in character. Another indication is the presence of numerous minute yellow or sulphur-colored granules scattered throughout the pus. In actinomycotic pus these yellowish granules consist of clumps of the fungi or actinomyces. And whenever convenient, a few of these granules should be teased out with a needle, placed on an object glass, compressed under a cover glass, and examined microscopically. It would be well also to make stained preparations and study for the tubercle bacilli.

In ordinary abscesses, or in tuberculosis of the throat glands, the pus is more likely to be of a thick creamy consistency, and in some cases quite fluid. The tubercle germ is much more difficult to detect from an examination of the pus, because of its minute size and the more complicated method of examination that is necessary. A more satisfactory way where there is doubt in diagnosis is to give the tuberculin test. And in the case of breeding and dairy cows it is important that this test should be given, even if no animal is affected with lump jaw. Moreover, an animal may be affected with the two ailments at the same time.

Laboratory Aid and Diagnosis.—The veterinary laboratory of the College of Agriculture and Experiment Station gives aid in the diagnosis of this disease by making microscopical examination of specimens of pus and tumors. These specimens should be prepared in a way to prevent spoiling in warm weather. The specimens need not be large; a bit of the tumor an inch and a half to two inches thick, and containing pus pockets, is sufficient. The sample should be wrapped in several thicknesses of cotton gauze. The gauze should be moistened with a 5 per cent solution of carbolic acid, and the excess of fluid should be pressed out before wrapping the specimen. The specimen should then be enclosed in a proper mailing case and forwarded to the laboratory by prepaid parcels post.

Scrapings of pus from an open sore may be put in a wide mouthed vaseline jar, of one ounce capacity, provided with a screw cap, or snugly fitting cork stopper.

Other Organs Affected.—Other organs of the body than those mentioned may also become infected with the actinomycetes. Actinomycotic lesions have been found in the intestinal tract, lungs, and liver of cattle when slaughtered. The inoculation of the internal organs, however, is of comparatively rare occurrence and its diagnosis in the living animals in such cases is impossible.

Other Species Affected.—Actinomycosis is more prevalent in cattle than in other animals but swine, sheep, horses, dogs and even the human species are not exempt from accidental inoculation in the ways mentioned.

PREVENTION

On account of the difficulty of destroying the fungi on large pastures, preventive measures are not very satisfactory. Mention has been made of the relation of the barbed or bearded grasses as carriers of the fungi. The foxtail growth which springs up so luxuriantly in stubble fields is not a very nutritious grass, and if the stubble fields were plowed and sown in rye for green fall pasturage, fewer cases of actinomycosis would probably occur,

and more benefit would be derived than to let noxious grasses and weed pests go to seed. The larger use of clover and alfalfa, and corn silage as winter forage for cattle, instead of letting them run to straw stacks, will doubtless lessen the number of lump jaw, big jaw and wooden tongue cases, and from the viewpoint of nutrition will also prove profitable.

TREATMENT

The method of treatment to be followed in any individual case will depend upon the type of the disease present and the extent to which the lesions have developed before treatment is started.

Surgical Treatment.—The quickest and most certain results are obtained when the whole tumor can be removed intact. This can be done, however, only when the tumor is sharply circumscribed and is movable in the soft tissue. The tumors are usually located in the region of the head and neck where large blood vessels and important nerves and ducts are located, which should be injured as little as possible in the operation. For this reason it is recommended that a veterinarian be employed.

In actinomycosis of the tongue it is often possible to cut into the tumors and then by the use of a curette to remove most of the diseased tissue. Tincture of iodine should be applied to the operated areas daily until healing has taken place. In addition to surgical treatment of tumors of the tongue it is always advisable to give potassium iodine internally. (See directions under medical treatment.)

Deeply seated tumors, or tumors so closely associated with large blood vessels and nerves in the neck region that their surgical removal would be dangerous, can be satisfactorily treated as follows: An incision is made into the tumor, permitting the pus to escape. The cavity is then flushed out by injecting with a syringe a 3 to 5 per cent solution of any of the coal tar disinfectants. Copper sulphate crystals can then be packed into the cavity. The opening should then be packed with a piece of gauze and the incision closed by taking a stitch or two to keep the copper sulphate crystals from falling out. At the end of three or four days the stitches should be cut and the remaining crystals of copper sulphate removed. The wall of the cavity will have necrosed and can be easily removed with the fingers or with a forceps. No further treatment is usually necessary except during fly season, when the wound should be kept smeared with oil of tar to prevent flies from depositing eggs in the area and the wound from becoming infested with maggots or screw worms.

A very practical method, and one which is very satisfactory to use where facilities are limited, consists in injecting full strength formalin into the central cavity of the actinomycotic tumor. An ordinary hypodermic syringe can be used. The hypodermic needle is inserted into the center of the tumor and as much formalin injected as moderate pressure on the syringe will allow.

Following this method of treatment the tumor gradually disappears within a period of six to ten weeks. This treatment should not be used where the jaw bone is involved because it causes a sloughing of the bone.

Medical Treatment.—In cases of actinomycosis of the tongue (wooden tongue) or of the jaw bone (big jaw), or lumpy jaw that cannot be operated on the only alternative is to treat the animal by giving potassium iodine internally, and the application of tincture of iodine to the diseased part externally. Potassium iodine is considered to be a specific for the disease.

The dosage of potassium iodine is from one to three drachms once a day, dissolved in a pint of water and administered as a drench. The dose should vary with the size of the animal and the effects that are produced. Symptoms of iodine poisoning usually appear in a week or ten days following the daily drenching of the animal.

The skin becomes dry and scurfy, there is a watering from the eyes, catarrh of the nose, and loss of appetite. When these symptoms appear and become pronounced the administration of the potassium iodine should be discontinued for a few days and then resumed until the symptoms of poisoning are again pronounced. The treatment may have to be continued for three to six weeks before a cure is effected.

In cases affecting the tongue and jaws, in which chewing and swallowing of the food are rendered difficult, the proper feeding of the animal is an important part of the treatment. Soft or liquids foods which can be easily swallowed, and which contain adequate nourishment should be supplied.

In some cases neither surgical nor medical treatment will prove of much value, and it may be better in such cases to fatten even a valuable breeding animal as quickly as possible and sell on the butcher market.

The judgment of the local veterinary practitioner will be helpful in deciding what is best to be done in each case, and it will save money to have him examine the affected animals as soon as possible after the appearance of the tumors.

EDIBILITY OF THE MEAT

Several years ago the entire carcass of the beef which had actinomycotic lumps about the head was condemned and tanked for fertilizer; but at the present time the official inspectors condemn only the parts showing the localized areas of disease. The infection is usually confined to a comparatively small and easily visible area, and as a rule confined to the head which can be condemned without material loss. It is not a disease that is liable to produce a systemic infection or toxemia that would render the flesh unfit for human food.

If the animal is in a thrifty condition, and shows no constitutional symptoms of disease, and no lesions occur in the internal organs, there would be no more reason for condemning the entire carcass, than to throw away a potato or an apple which has only a small spot of decay.

CLINICAL CASES

Reports of Treatment.—A few reports of cases, with illustrations of the gross lesions, will give a fuller understanding of this disease and the result of treatment. The first case given (Fig. 5) is from the College Clinic, and is a case of actinomycosis of the tongue. The others are lump




Fig. 5.—Feeding steer affected with “wooden tongue.”

jaw and big jaw cases selected from quite a number which were treated with iodide of potash by Dr. Norgaard under the direction of Dr. D. E. Salmon, Chief of the United States Bureau of Animal Industry, and reported in the eighth and ninth annual reports of the Bureau published in 1893.

This steer was affected with actinomycosis of the tongue, the so-called wooden tongue, and showed considerable emaciation from inability to masticate and swallow sufficient food. The bulging mass (a), bagging down from the intermaxillary space, was very dense, and the tongue had a more rounded appearance than normal. The tip was not flexible, and showed sore spots from erosion of the epithelium. The sores at tip of tongue were probably due in part to mechanical injury in attempts to take in food. In this connection study figure 4 which shows lesions of the tongue in an untreated case.

The big jaw type of actinomycosis is shown in accompanying figure of a steer's head. "The facial bones of the right side of the head (a-a) were immensely swollen;" and there was a large ulcer or open sore (x) near the center of the bony tumor.

TREATMENT.—Removal of the bony tumor by surgical excision was out of the question. Internal treatment with iodide of potash was given. "Doses of three drachms or more were administered daily over a period of eight weeks with proper intervals." This resulted in drying up the ulcer but did

not lessen the size of the bony enlargement to any appreciable degree.

"When the animal was slaughtered, a section through the substance of the bone showed numerous minute cavities or pockets filled with pus and growths of actinomyces." Further treatment might have resulted in the complete healing of the affected bone. The poor circulation in the diseased bone may, however, have rendered further treatment useless. The carcass of this steer was condemned, although no signs of disease were found in the internal organs, nor in the flesh of the dressed carcass.

If the treatment of this steer had been given sooner, better results would doubtless have been obtained.




Fig. 6.—Feeding steer affected with "big jaw" or disease of the jaw bones.

This steer had two tumors; one a hard, fibrous lump (a), about the size of a goose egg, and located on the outside of the right cheek near the lower edge of the under jaw. The other lump, (b), about the size of "a double clenched fist," was located in the submaxillary space back of the first tumor. (Fig. 7.)

TREATMENT.—Both these tumors could no doubt have been removed by surgical operation, but this was not done as the animal was on an experiment to determine the effect of iodide of potash as a remedy. Ten grams, or two and a half drachms, of the iodide of potash were administered daily for about three weeks; the symptoms of "iodism" were produced, and the tumors shrank rapidly. The larger and softer submaxillary tumor had disappeared at the end of the period of treatment; and the harder fibrous tumor on the jaw had shrunken to the size of a walnut, and this also disappeared within three weeks

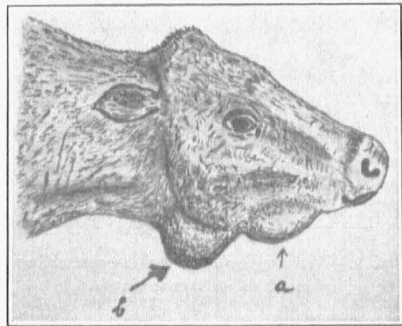


Fig. 7.—Feeding steer affected with "lump jaw."

after the treatment had been discontinued. The steer was slaughtered a few weeks later, and no traces of the tumor were found except a slight induration in the skin from the healed scar-tissue. No signs of the disease were found in the internal organs, and the carcass was passed for food.

This steer had three tumors; one about the size of two fists, on the left side of the throat (y); and a smaller one lying a little forward and in the submaxillary space (x); the third and smallest, about the size of a walnut, was located under the skin of the left cheek outside the second molar tooth, this tumor was hard and fibrous and only slightly movable.

TREATMENT.—The iodide of potash treatment was given, in two and a half drachm doses daily. In two weeks the two smaller tumors had disappeared. And at the end of four weeks, when the treatment was discontinued, only a small part of the largest tumor was left. The steer was slaughtered for beef two months later and only a small fibrous induration remained, in which no active disease process was found. "The carcass was passed as sound."

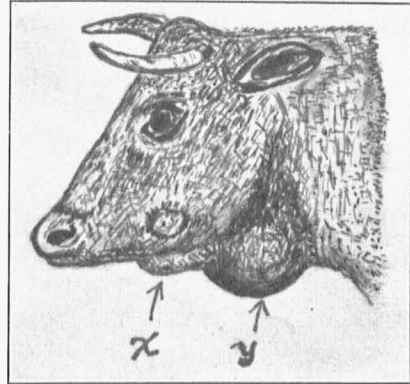


Fig. 8.—Steer showing both the lump jaw and beginning of big jaw type.




Fig. 9.—Actinomycosis of throat—resembling tuberculosis of throat glands.

size of a walnut." The systemic effect of the iodide of potash on the animal was well marked. The tumor had entirely disappeared when the steer was examined six weeks after the treatment was begun. And when the animal was slaughtered, no trace of the disease was found in the neck, nor other parts of the carcass. "The carcass was passed as sound."

Tumors like the above occurring in the loose tissues of the throat and neck may result from bruises, or from pus infections, or from tuberculosis, as well as from actinomycosis. It is therefore advisable to remove tumors of

This steer had a hard fibrous tumor the size of the clenched fist, on the right side of the throat just back of the angle of the jaw. This tumor was presumed to be of actinomycotic origin, although it was not opened for diagnosis.

TREATMENT.—This tumor could perhaps have been removed successfully by surgical operation; but the iodide of potash was administered to study the effect of that drug. Ten grams ($2\frac{1}{2}$ drachms) were given daily. "The tumor began to shrink from the fourth day, and in less than three weeks had gone down to the

this character by surgical operation, when this can be done, and have the specimens examined microscopically. If the disease should be tuberculosis, other organs of the body may be infected, and successful treatment of the animal should not be expected. When tumors develop in the throat of one or more animals of a breeding or milking herd, the tuberculin test should be applied, on account of the possibility of the two infections existing at the same time. It is not so important in beef steers, since the slaughter of the animal within a few weeks will decide whether the internal organs are affected, but in the case of breeding animals which are to be kept for a number of years, a coexistent tuberculous infection could be overlooked after removal of the tumor unless the tuberculin test is applied.

LITERATURE

The student who is interested in the fuller study of this disease is referred to the larger veterinary texts such as James Law's *Veterinary Medicine*, and to the files of the several veterinary journals.

A very full list of references to original articles on actinomycosis, from the first important publication by Rivolta in 1868 to within recent years will be found in the German edition of Friedberger & Froehner's *Pathology and Therapy*, and in the American edition of Hutyra & Marek's *Pathology and Therapeutics*.

It is fitting to mention a few historical facts. Thomassen of Utrecht brought to the attention of the European veterinarians the specific value of iodide of potash as a curative agent in this disease, by reporting remarkably favorable results in the treatment of eighty cases. Professor Nocard of France verified the results. Following these European successes, Dr. Salmon, Chief of the Bureau of Animal Industry instituted treatment on a large scale, and proved the value of the treatment in this country.

In this connection it is proper to state that although Thomassen and Nocard and Salmon demonstrated the value of the treatment in a large way, this treatment had been used by English veterinarians with success several years before Thomassen's publication in *L'ECHO VETERINAIRE*. A record of this can be found in *THE VETERINARIAN*, for the year 1882, three years before Thomassen's report. Prof. Axe of the Royal Veterinary College gives an account of examinations of diseased organs sent to his laboratory during the several preceding years, by veterinary practitioners. He also records treatments reported by the veterinarians. These records go back to 1876, or nine years before Thomassen's report. A quotation or two will be of interest. These particular cases referred to actinomycosis of the tongue. Mr. Goforth Wyer, veterinarian of Donnington wrote as follows,—after mentioning symptoms and conditions, "The treatment I have hitherto adopted consists of half drachm doses of calomel, occasionally, and iodide of potash daily." Dr. J. C. James of Thornburg, Gloucestershire says: "I give the animal nutritive food; and the administration of iodide of potash internally is very beneficial." Capt. Russell of Grantham gave purgative followed by tonics, and potassium iodide internally in two drachm doses daily for a week, and dressed the tongue with dilute tincture of iron; and he says: "If the disease is not far advanced and the owner will take

the trouble to continue the treatment, a cure is generally effected in a few weeks."

Previous to the discovery of the actinomyces as the cause, English veterinarians were treating the tongue cases as "cancer," and had conceived the notion that iodide of potash would be useful. Thomassen perhaps got the suggestion for his large test from results observed by veterinary practitioners. This should not detract from the credit which has come to him for the work he did. I am mentioning these historical facts to impress upon the veterinary practitioners the importance of their clinical observations in the progress of veterinary medicine. They should not only strive for the utmost accuracy in their clinical observations and interpretations, but should also get the habit of recording the facts fully and clearly, and reporting them. This is especially important in dealing with diseases concerning which there is still much to be discovered. And perhaps even in the case of actinomycosis all the facts have not yet been discovered.

ACKNOWLEDGMENTS

Figures 2 and 3 are from Kitt's *Bakterienkunde* and from his *Pathologische Anatomie* respectively. Figure 4 is from Ostertag's *Fleischbeschau*. Figures 6, 7, 8 and 9 from the United States Bureau of Animal Industry reports published in 1893.