

Essentials of Our Current Understanding: Abdominal Wall Blocks

Ki Jinn Chin, FRCPC,* John G. McDonnell, MD, FCARCSI, † Brendan Carvalho, MD, ‡ Aidan Sharkey, FCAI, † Amit Pawa, FRCA, § and Jeffrey Gadsden, MD, FRCPC, FANZCA||

Abstract: Abdominal wall blocks rely on the spread of local anesthetic within musculofascial planes to anesthetize multiple small nerves or plexuses, rather than targeting specific nerve structures. Ultrasonography is primarily responsible for the widespread adoption of techniques including transversus abdominis plane and rectus sheath blocks, as well as the introduction of novel techniques such as quadratus lumborum and transversalis fascia blocks. These blocks are technically straightforward and relatively safe and reduce pain and opioid requirements in many clinical settings. The data supporting these outcomes, however, can be inconsistent because of heterogeneity of study design. The extent of sensory blockade is also somewhat variable, because it depends on the achieved spread of local anesthetic and the anatomical course of the nerves being targeted. The blocks mainly provide somatic analgesia and are best used as part of a multimodal analgesic regimen. This review summarizes the anatomical, sonographic, and technical aspects of the abdominal wall blocks in current use, examining the current evidence for the efficacy and safety of each.

(*Reg Anesth Pain Med* 2017;42: 133–183)

Regional anesthesia of the trunk and abdominal wall has traditionally centered on epidural analgesia, but enthusiasm for this has waned with the increasing use of minimally invasive laparoscopic techniques, aggressive postoperative anticoagulation regimens, and emphasis on early ambulation. The popularity of abdominal wall blocks, on the other hand, has dramatically increased in the last decade, thanks to the introduction of simple yet effective techniques such as the transversus abdominis plane (TAP) block and the widespread availability of ultrasound (US) imaging. There has been an accompanying explosion in the scientific literature on abdominal wall blocks, and the purpose of this review is to summarize the current state of knowledge, with the aim of providing a guide to clinical application of these techniques, as well as future avenues of research. Toward these ends, the review describes the applied anatomy of the abdominal wall, as well as the sonoanatomy and basic technical considerations of the blocks in current use. These include the TAP block, ilioinguinal-iliohypogastric (II-IH) block, rectus sheath block, and the newer techniques of transversalis fascia plane (TFP) block and quadratus lumborum (QL) block. The evidence for clinical

outcomes of efficacy and safety associated with the various block techniques is discussed, including the specific application of abdominal wall blocks in the obstetric population.

ANATOMY OF THE ABDOMINAL WALL

The abdominal wall is a continuous cylindrical myofascial structure that attaches to the thoracic cage superiorly, the pelvic girdle inferiorly, and the spinal column posteriorly. The anatomical relationship between the muscles and fascial layers of the abdominal wall is complex, and it is useful from both a conceptual and practical standpoint to consider the anterolateral and posterior sections of the abdominal wall separately.

Anterolateral Abdominal Wall

The anterolateral abdominal wall extends between the posterior axillary lines on either side (Fig. 1). The superior boundaries are the costal margin of the 7th to 10th ribs and xiphoid process of the sternum, and the inferior boundaries are the iliac crests, inguinal ligament, pubic crest, and symphysis. The layers of the abdominal wall are (from superficial to deep) skin and subcutaneous tissue, the abdominal muscles and associated aponeuroses, transversalis fascia, extraperitoneal fat, and parietal peritoneum.

The anterolateral abdominal wall has 3 flat muscles (external oblique, internal oblique, transversus abdominis) arranged in concentric layers and 1 paired vertical muscle in the midline (rectus abdominis). A small number of individuals have a second small vertical midline muscle, the pyramidalis, which is of little clinical significance. All 3 flat muscles taper off into aponeuroses as they approach the midline, and these aponeuroses form the tendinous rectus sheath that encases the rectus abdominis muscle (RAM). They blend in the midline with the aponeuroses of the other side to form the linea alba. The specifics of how the muscles and their aponeuroses relate to each other, as well as the various points of reference on the abdominal wall (eg, midaxillary line, anterior axillary line, midclavicular line), will determine the layers visible on US at different transducer locations.

The external oblique muscle (EOM) originates on the external aspect of the 5th to 12th ribs, and its fibers descend in an inferomedial direction to insert on the anterior iliac crest, linea alba, and pubic tubercle (Fig. 1). Anteriorly, the EOM tapers off into an extensive aponeurosis medial to the midclavicular line and inferior to a line between the anterior superior iliac spine (ASIS) and the umbilicus; thus, in this area, only 2 muscle layers, internal oblique muscle (IOM) and transversus abdominis muscle (TAM), will be apparent on US imaging (Fig. 2). The inferior edge of the EOM aponeurosis forms the inguinal ligament; its medial edge blends with the aponeurosis of IOM to form the anterior rectus sheath.

The IOM originates from the iliac crest inferiorly and the thoracolumbar fascia posteriorly, and its fibers ascend in a superior-medial direction (perpendicular to those of the EOM) to insert on the inferior borders of the 10th to 12th ribs and the linea alba. It is a fleshy muscle that on US imaging often appears

From the *Department of Anesthesia, Toronto Western Hospital, University of Toronto, Toronto, Ontario, Canada; †Department of Anaesthesia, Clinical Sciences Institute, National University of Ireland, Galway, Ireland; ‡Department of Anesthesiology, Perioperative and Pain Medicine, Stanford University School of Medicine, Stanford, CA; §Department of Anaesthesia, Guy's and St Thomas' Hospitals, London, United Kingdom; and ||Department of Anesthesiology, Duke University Medical Center, Durham, NC.

Accepted for publication October 12, 2016.

Address correspondence to: Ki Jinn Chin, FRCPC, Department of Anesthesia, Toronto Western Hospital, University of Toronto, McL 2-405, 399 Bathurst St, Toronto, Ontario, Canada M5T 2S8 (e-mail: gasgenie@gmail.com).

The authors declare no conflict of interest.

Copyright © 2017 by American Society of Regional Anesthesia and Pain Medicine

ISSN: 1098-7339

DOI: 10.1097/AAP.0000000000000545

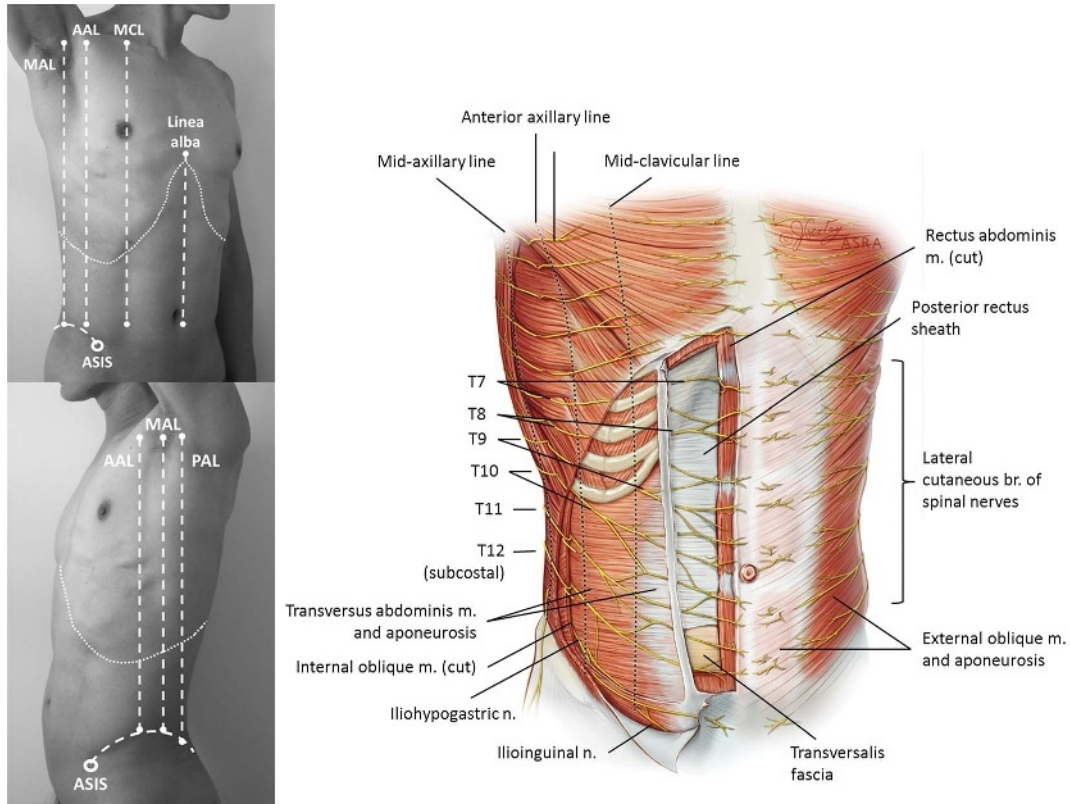


FIGURE 1. Surface anatomy, muscular layers, and nerves of the anterolateral abdominal wall. The EOM and IOM and aponeuroses have been cut away on the right to show the TAP. The lateral cutaneous branches arise from their respective spinal nerves at or posterior to the midaxillary line and supply the skin of the lateral abdominal wall up to the midclavicular line. The T7-T9 nerves enter the TAP at or medial to the midclavicular line. Communicating branches between the spinal nerves give rise to plexuses of nerves within the TAP and the rectus sheath. The rectus sheath is deficient midway between the umbilicus and pubis. AAL indicates anterior axillary line; MAL, midaxillary line; MCL, midclavicular line; PAL, posterior axillary line).

as the thickest of the 3 flat muscle layers (Fig. 3). Medial to the midclavicular line, the IOM tapers off into its aponeurosis and contributes to the formation of the rectus sheath.

The TAM originates on the internal aspect of the 7th to 12th costal cartilages, the thoracolumbar fascia, and iliac crest. As its name indicates, the fibers run transversely to insert on the linea alba and pubic tubercle. Like the EOM and IOM, it tapers off medially into an aponeurosis that blends with the others to form the rectus sheath (Fig. 1). The transition from muscle into aponeurosis occurs along a crescent-shaped line, and thus just inferior to the costal margin, TAM runs deep to rectus abdominis for a short distance before tapering off into its aponeurosis (Fig. 4).

The RAM is a paired muscle that originates on the pubic crest and symphysis and ascends vertically to insert on the xiphoid process and fifth to seventh costal cartilages (Fig. 1). It is encased within the rectus sheath and is attached to the anterior aspect of the rectus sheath by 3 or 4 transverse tendinous insertions. These insertions divide the anterior rectus sheath compartment into separate subcompartments, giving the RAM its “6-pack” appearance in thin muscular subjects and consequently impeding cranio-caudal spread of injectate. The posterior rectus sheath compartment, by comparison, is unsegmented and is thus a more logical place for local anesthetic injection.

The rectus sheath is formed by the blending of aponeuroses from the EOM, IOM, and TAM. In the superior three-quarters of the RAM, the anterior layer of the rectus sheath is formed by the EOM and IOM aponeuroses. The IOM aponeurosis splits into

2 layers and also contributes to the posterior layer of the rectus sheath together with the TAM aponeurosis (Fig. 5A). However, inferior to the level of the ASIS (at the arcuate line), all 3 aponeuroses pass anterior to the RAM and form the anterior layer of the rectus sheath. The inferior one-quarter of the RAM is therefore lined on its posterior aspect only by its epimysium and the transversalis fascia (Figs. 1 and 5B).

Posterior Abdominal Wall

Understanding the structure of the posterior abdominal wall is essential to the landmark-guided TAP block and the more novel US-guided abdominal wall blocks, such as the TFP block and QL block.

Of the 3 muscle layers of the anterolateral abdominal wall, the TAM and IOM taper off posteriorly into their origins from the thoracolumbar fascia. The EOM, on the other hand, ends posteriorly in a free edge, which abuts against the latissimus dorsi muscle (Fig. 6).

The thoracolumbar fascia is a complex tubular structure of blended aponeuroses and fascial layers that encases the deep muscles of the back and, as its name suggests, extends from the lumbar to thoracic spine.^{1,2} Tracing it laterally from its anchor point on the spinous processes and supraspinous ligament, the thoracolumbar fascia splits into 3 layers: the posterior and middle layers enclose the paraspinal (erector spinae) muscles, and the middle and anterior layers enclose the QL muscle (QLM), which is a quadrilateral

Ilioinguinal-Iliohypogastric Blocks

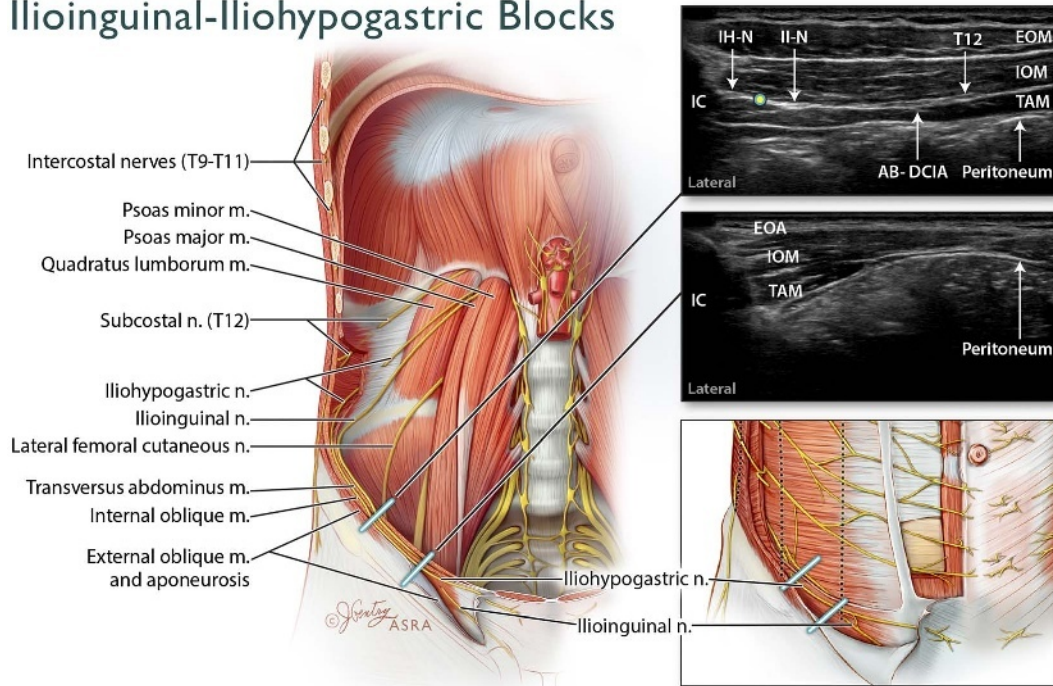


FIGURE 2. Anatomy of the US-guided II-N and IH-N block. The IH-N and II-N emerge from the lateral border of psoas major and run over the anterior surface of QL, then the deep aspect of TAM and its aponeurosis. Both nerves pierce TAM to enter TAP at a variable location posterior to the ASIS. The US probe may be placed in 1 of 2 locations (blue lines). (1) The recommended approach is to place the probe parallel and superior/posterior to the line connecting the umbilicus and the ASIS. The edge of the probe rests against the iliac crest (IC), which is visible as an acoustic shadow. In this position, the 3 muscular layers of the abdominal wall are visible. The II-N and IH-N are located in the TAP between IOM and TAM and lie very close to the iliac crest. The AB-DCIA lies more medially in the TAP, as does the subcostal nerve (T12). Injection of local anesthetic is performed in the TAP close to the IC (circle), avoiding the nerves if they are visible. (2) If the probe is placed inferior to the line connecting the umbilicus and the ASIS, only the IOM and TAM are visible as muscle layers. The EOM has tapered off into its aponeurosis (EOA). The ilioinguinal and iliohypogastric nerves in this area are ascending through IOM into more superficial and subcutaneous planes and are not easily visualized or consistent in their location. AB-DCIA indicates ascending branch of deep circumflex iliac artery; IC, iliac crest; IH-N, iliohypogastric nerve; II-N, ilioinguinal nerve.

muscle extending between the 12th rib and the (internal lip of the) iliac crest (Figs. 2 and 6). Medial and anterior to the QLM lies the psoas major muscle. The posterior and middle layers of thoracolumbar fascia fuse again lateral to the paraspinal muscles and merge with the aponeuroses of the IOM and TAM.^{1,2}

The transversalis fascia is a thin areolar tissue that lines the deep surface of TAM and separates it from the parietal peritoneum. It is 1 part of the larger endoabdominal fascia that lines the entire internal aspect of the abdominal wall. As such, it is continuous inferiorly with the fascia iliaca³ and medially with the investing fascia of QLM and psoas major muscle (Fig. 6). In fact, the terms “anterior layer of thoracolumbar fascia” and “transversalis fascia” may be used interchangeably when referring to the fascial layer investing the anterior surface of QLM.¹ The transversalis fascia follows the QLM and psoas major superiorly through the diaphragm, passing under the lateral and medial arcuate ligaments and blending with the endothoracic fascia of the thorax.^{4,5} These relationships of the thoracolumbar fascia, transversalis fascia and associated muscles have important implications for the potential spread of local anesthetic injected in the posterior abdominal wall.

The triangle of Petit (or inferior lumbar triangle) is the primary surface anatomical landmark for the TAP block. It is bordered inferiorly at its base by the iliac crest, laterally by the medial free edge of EOM and medially by the lateral edge of latissimus dorsi (Fig. 7). The triangle is covered superficially by skin and subcutaneous tissues, whereas its anterior (deep) floor is formed by IOM and the thoracolumbar fascia, which separates

it from the fat-filled retroperitoneal space. However, cadaveric studies indicate that there is significant anatomic variability in the triangle of Petit.^{7,8} It was quite small in the majority of subjects (3.6 cm² on average⁷) and even absent in 18% of subjects because of overlapping of the free edges of EOM and latissimus dorsi.⁸ This inconsistency limits its usefulness as a reliable surface anatomical landmark.

Innervation of the Anterior Abdominal Wall

The anterior abdominal wall is innervated by the thoracoabdominal nerves and the ilioinguinal and iliohypogastric nerves (Fig. 1). The thoracoabdominal nerves originate from the anterior rami of the lower 7 thoracic spinal nerves (T6-T12) and are the continuation of the respective intercostal nerves. The T12 nerve is often also referred to as the subcostal nerve. They each give off a lateral cutaneous branch in the midaxillary line, which ascends to enter the subcutaneous tissues along the anterior axillary line and supplies the lateral abdominal wall. The anterior branches of the thoracoabdominal nerves subsequently emerge from the costal margin and travel in the neurovascular TAP between IOM and TAM. Note that the upper segmental nerves T6-T9 only enter the TAP medial to the anterior axillary line (T6 enters it just lateral to the linea alba) and that the other nerves enter it progressively more laterally (Fig. 1).⁹ This has implications for the pattern of nerve involvement that can be expected by injection at different locations in the TAP. Within the TAP, the lower segmental nerves (T9-L1) give off multiple communicating branches

Transversus Abdominis Plane Blocks

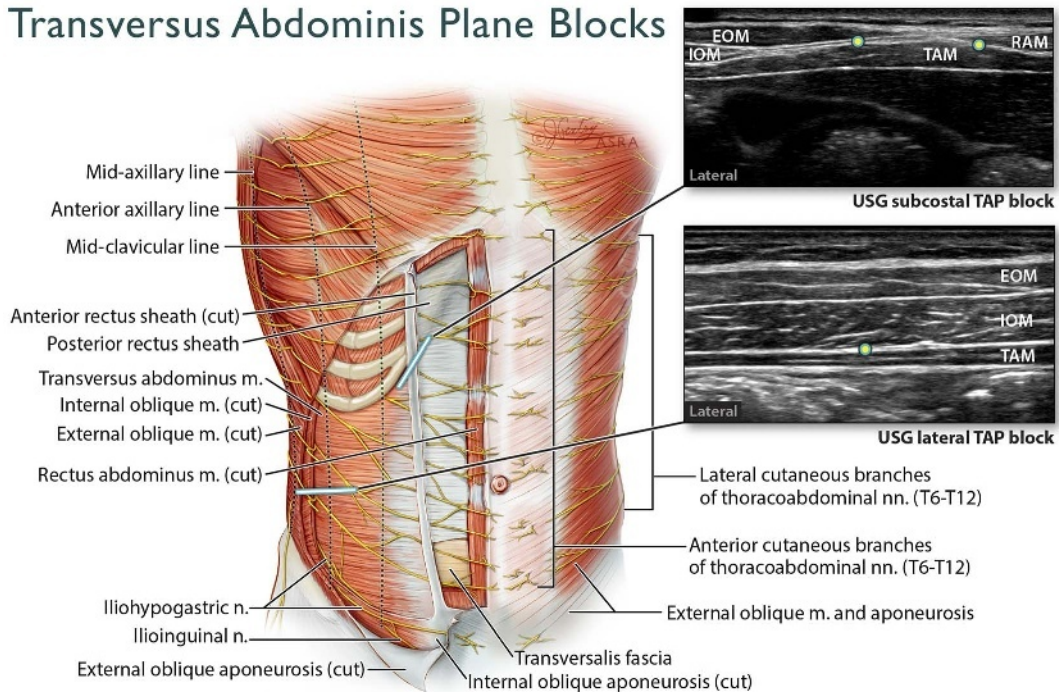


FIGURE 3. Anatomy of the anterolateral abdominal wall and the US-guided (USG) subcostal and lateral TAP blocks. The USG subcostal TAP block targets the T6 to T10 nerves, where they emerge into the TAP from under the costal margin. The probe is placed parallel and adjacent to the costal margin (blue line). Closer to the midline, the TAP is the plane between RAM and TAM. The EOM and IOM exist as aponeuroses in this region, which contribute to the formation of the anterior rectus sheath. The EOM and IOM become visible as the probe is moved more laterally along the costal margin. Injection may be performed at multiple points along the costal margin (circles) or a needle inserted in-plane in a continuous track along the costal margin (the oblique subcostal TAP block approach). Note that the lateral cutaneous branches of the thoracoabdominal nerves are not covered by the block. The USG lateral TAP block targets the T10 to T12-L1 nerves. The probe is placed in a transverse orientation between the costal margin and iliac crest and in the midaxillary line. Injection is performed in the TAP between IOM and TAM (circle), with the needle usually inserted in an anterior-to-posterior direction. The TAM has a characteristic darker hypoechoic appearance and is usually significantly thinner than the IOM.

to form a longitudinal TAP plexus, from which the terminal anterior branches arise.⁹

The terminal anterior cutaneous branches of the thoracoabdominal nerves enter the rectus sheath at its lateral margin (the linea semilunaris). In the vast majority of cases (89%), the nerves run deep to the posterior surface of RAM before ascending to pierce it 1.6 to 2.6 cm from its lateral edge.¹⁰ However, these nerves occasionally directly pierce the lateral edge of the RAM and thus may be missed by a rectus sheath block. Once again, the nerves branch and communicate to form a longitudinal rectus sheath plexus, before entering the subcutaneous tissue of the anterior abdominal wall.⁹

The existence of TAP and rectus sheath plexuses indicates that individual terminal nerves have multiple segmental origins and that the traditional depiction of the cutaneous innervation of the abdominal wall in terms of well-demarcated dermatomes is not wholly accurate.¹¹ This may be an explanation for the discrepancies between radiographically visualized spread of injectate in the TAP, apparent extent of clinical analgesia, and the cutaneous sensory block observed in studies.^{6,12,13}

The ilioinguinal and iliohypogastric nerves are classically described as terminal branches of the anterior ramus of the L1 spinal nerve with occasional contribution from T12. Although this is true in the majority of individuals, there is significant variability, with up to 20% having origins from the L2 and L3 nerve roots.¹⁴⁻¹⁶ Both nerves emerge at the lateral border of psoas major and run inferolaterally on the ventral surface of QLM and TAM, just

superior and parallel to the iliac crest (Fig. 2). The exact location at which the nerves pierce TAM and enter the TAP is variable, but this is usually in the region of the anterior third of the iliac crest rather than more posteriorly.^{14,17,18} The iliohypogastric nerve enters the TAP earlier in its course than the ilioinguinal nerve, and in a significant number of individuals, the ilioinguinal nerve only enters the TAP very close to the ASIS (medial to the anterior axillary line).⁹ Both nerves continue to ascend through the IOM and EOM to supply the abdominal wall in the inguinal and pubic regions. They pierce the IOM at a variable distance medial to the ASIS (approximately 3 ± 2 cm medial to ASIS and 1 cm superior to inguinal ligament in adults).¹⁴ The anatomic variability in their course contributes to the high failure rates for blockade of these nerves with the TAP block^{19,20} and the landmark-guided techniques of II-IH block.^{21,22}

Vasculature of the Anterior Abdominal Wall

There is a rich network of arteries and veins within the TAP, which supplies the anterior abdominal wall and promotes the absorption of local anesthetic injected in this plane. The main arteries are continuations of the lower thoracic intercostal arteries and the deep circumflex iliac arteries. Within the rectus sheath, bilateral superior epigastric arteries (continuations of the internal thoracic arteries) anastomose with the deep inferior epigastric arteries (which arise from the external iliac arteries) and are at risk of accidental puncture during rectus sheath block.

Rectus Sheath Blocks

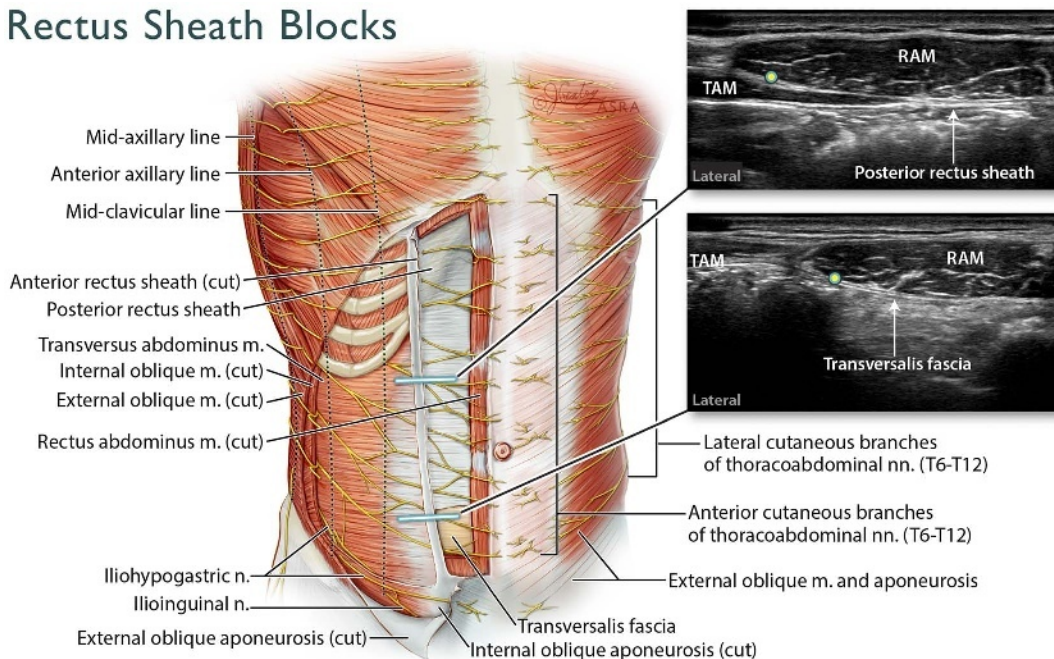


FIGURE 4. Anatomy of the anterolateral abdominal wall and the US-guided (USG) rectus sheath block. This block targets the terminal muscular branches and anterior cutaneous branches of the thoracoabdominal nerves. The probe is placed in a transverse orientation superior to the umbilicus to visualize the lateral aspect of the RAM and rectus sheath. Close to the costal margin, the TAM is often visible lying deep to RAM. If the probe is placed inferior to the midpoint between umbilicus and pubic symphysis, the posterior rectus sheath is absent, and the deep surface of RAM is bounded by its epimysium and transversalis fascia. Injection is performed in the posterior rectus sheath compartment between the lateral aspect of RAM and its deep investing layer of fascia (circles), to target the nerves before they ascend through RAM into their subcutaneous location.

TAP BLOCK

The landmark-guided TAP block was first described in 2001²³ and has since undergone multiple modifications. The “TAP block” is therefore a nonspecific term encompassing a heterogeneous group of approaches that share the common end point of local anesthetic injection into the neurovascular fascial plane superficial to the TAM. The aim in all cases is to block some or all of the lower 6 thoracic spinal nerves (T7-T12) and the iliohypogastric and ilioinguinal nerves (L1). The approaches differ primarily in the site of needle insertion and injection, which, because of the complex course of the lower thoracoabdominal nerves and interplay between muscular and aponeurotic layers of the abdominal wall at different locations, leads in turn to differences in the spread of local anesthetic and extent of analgesia. There has been a lack of consistency in the terminology used to describe the different US-guided approaches²⁴⁻²⁶ and this review uses the nomenclature outlined in Table 1.

Landmark-Guided TAP Block

Technique

The landmark-guided TAP block was first described by Rafi^{23,44} and later by McDonnell et al.⁶ Both authors describe the chief surface landmark as the insertion of the latissimus dorsi on the iliac crest. The site of needle insertion is immediately anterior to this “latissimoiliac point (LIP)”⁴⁴ and just superior to the iliac crest, in the triangle of Petit (Fig. 7). Given the variability in the size and presence of the triangle of Petit,^{7,8} the LIP may be a more accurate and consistent landmark.

McDonnell et al⁶ recommend seeking a “double-pop” as the end point for needle insertion, the first pop representing penetration of the EOM fascia and the second pop the deep fascia of IOM.

Rafi,⁴⁴ on the other hand, recommends contacting the external lip of the iliac crest and “walking” the needle tip over it until a single pop (penetration of the deep fascia of IOM) is obtained. Regardless, the subjective nature of tactile pops as end points for needle insertion may contribute to failure of the technique, particularly in inexperienced hands.⁴⁵

Pattern of injectate spread and sensory block

Radiological studies indicate that 20 to 40 mL of local anesthetic injected using the landmark-guided TAP approach will spread within the TAP from the iliac crest superiorly to the costal margin, anteriorly to the midaxillary line, and posteriorly to the lateral border of QLM.^{6,46} This TAP spread was thought to be responsible for block efficacy (hence the name) and has been the principle upon which subsequent modifications have been based. However, posterior extension of injectate spread into the plane between transversalis fascia and the ventral surface of QLM, and thence upward into the thoracic paravertebral space, has also been reported.⁴⁶ It is postulated that this may be the more important mechanism for producing analgesia, particularly above the T10 level, because the T7-T9 nerves only enter the TAP medial to the anterior axillary line and close to the costal margin. This pattern of posterior and cranial spread is not seen with any of the US-guided TAP approaches, and they may therefore have little in common with the landmark-guided TAP block apart from the name.

The extent of cutaneous sensory block that can be achieved is less clear. McDonnell et al⁶ reported achieving a sensory block of the anterior abdominal wall from T7 to L1 in 6 volunteers (12 blocks), but the precise sites of sensory testing were not described. Carney et al⁴⁶ mapped the extent of sensory loss in 8 blocks and found this was variable; in particular, blockade of the anterior

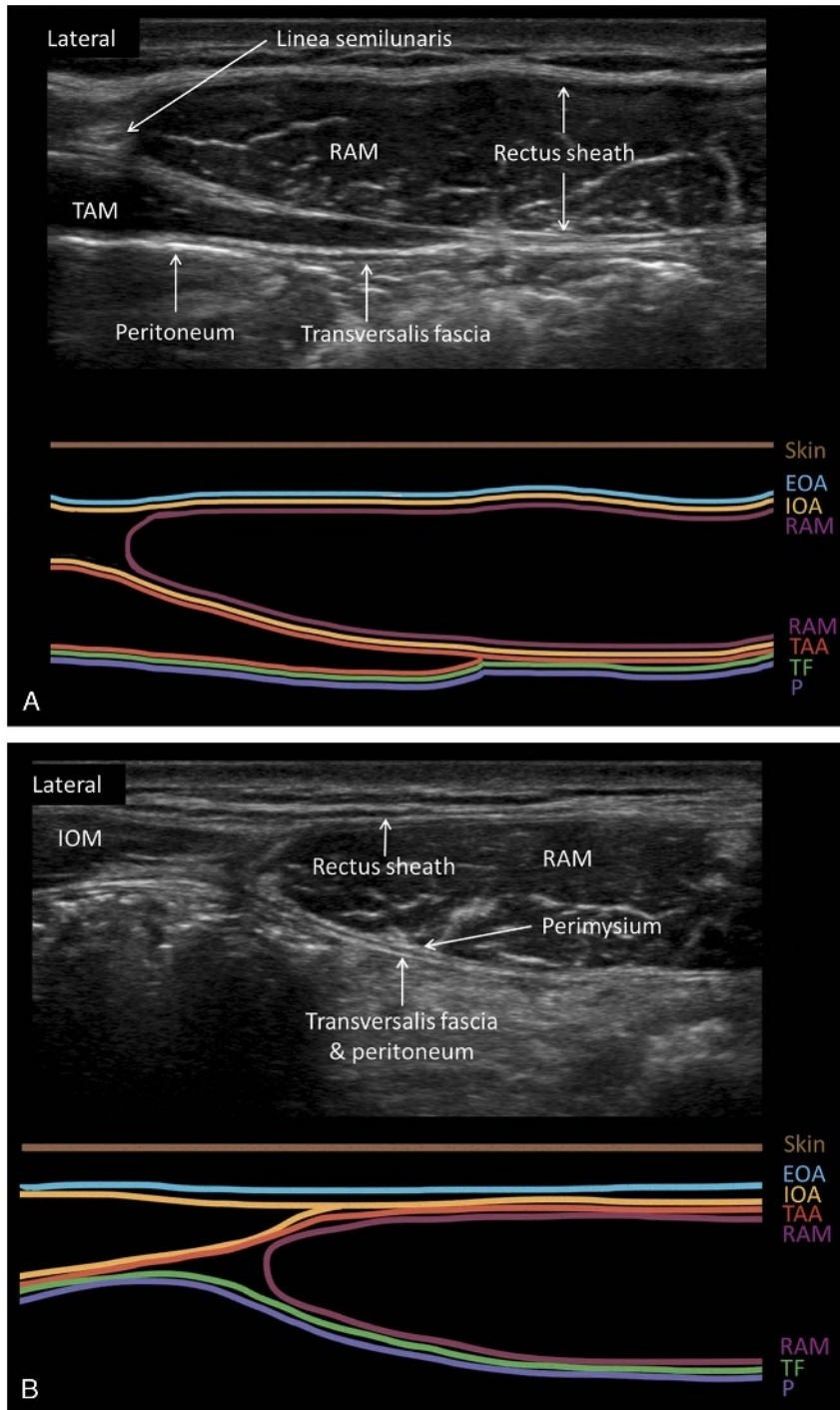


FIGURE 5. A, Sonoanatomy of the RAM and sheath in the supraumbilical region, with a corresponding schematic diagram showing the fascial and aponeurotic layers. The TAM is visible deep to the lateral edge of the RAM. Both the internal oblique aponeurosis and the transversus abdominis aponeurosis contribute to the posterior rectus sheath. The transversalis fascia and peritoneum lie deep to the posterior rectus sheath but cannot always be clearly distinguished as separate layers. B, Sonoanatomy of the RAM and sheath in the infraumbilical region below the arcuate line, with a corresponding schematic diagram showing the fascial and aponeurotic layers. Here, there is no posterior rectus sheath. The layer immediately deep to the perimysium of RAM is transversalis fascia. The aponeuroses of all 3 muscle layers contribute only to the anterior rectus sheath. EOA indicates external oblique aponeurosis; IOA, internal oblique aponeurosis; P, peritoneum; SC, subcutaneous tissue; TAA, transversus abdominis aponeurosis; TF, transversalis fascia.

Quadratus Lumborum Block

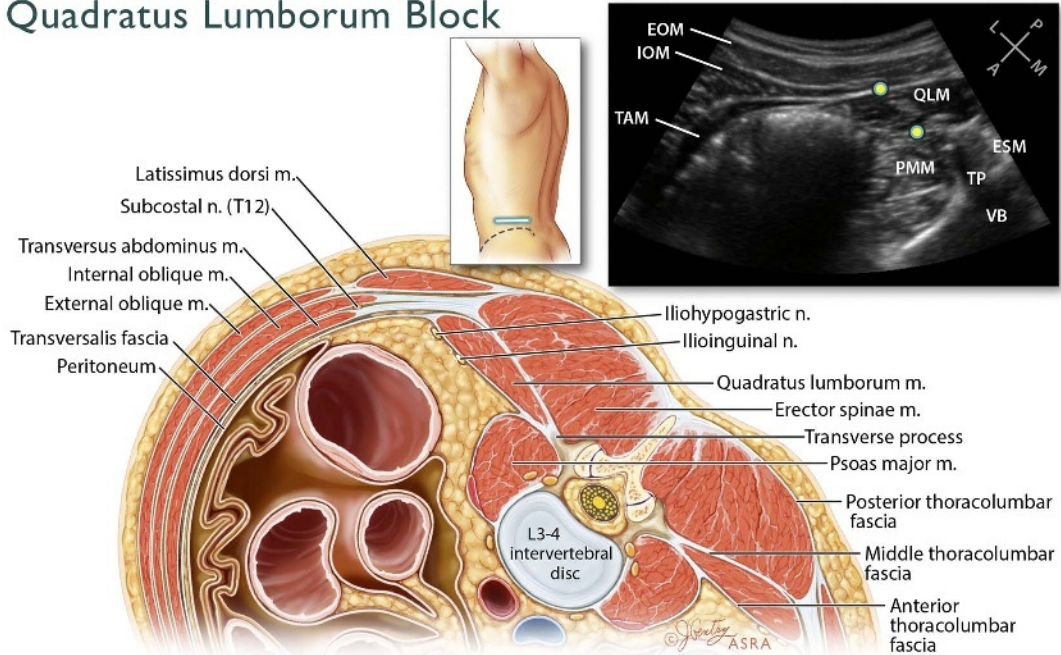


FIGURE 6. Anatomy of the posterior abdominal wall and the US-guided QL block. The EOM ends in a free edge abutting the latissimus dorsi. The IOM and TAM end in aponeuroses that blend with the thoracolumbar fascia. The thoracolumbar fascia itself splits into 3 layers (posterior, middle, and anterior) that envelop the QLM and ESM. The QL block is performed by placing a curvilinear probe on the posterolateral aspect of the abdominal wall in a transverse oblique orientation, between the iliac crest and costal margin (blue line). Key landmarks for identifying the QLM are the VB, TP, and PMM. At the L3-L4 level, the large intestine in the peritoneal cavity may be seen deep to the abdominal wall muscles (as it is here); at the L2-L3 level, the kidney is usually visible in the retroperitoneal space. The circles indicate points for local anesthetic injection either anterior or posterior to QLM. ESM indicates erector spinae muscle; PMM, psoas major muscle; TP, transverse process; VB, vertebral body.

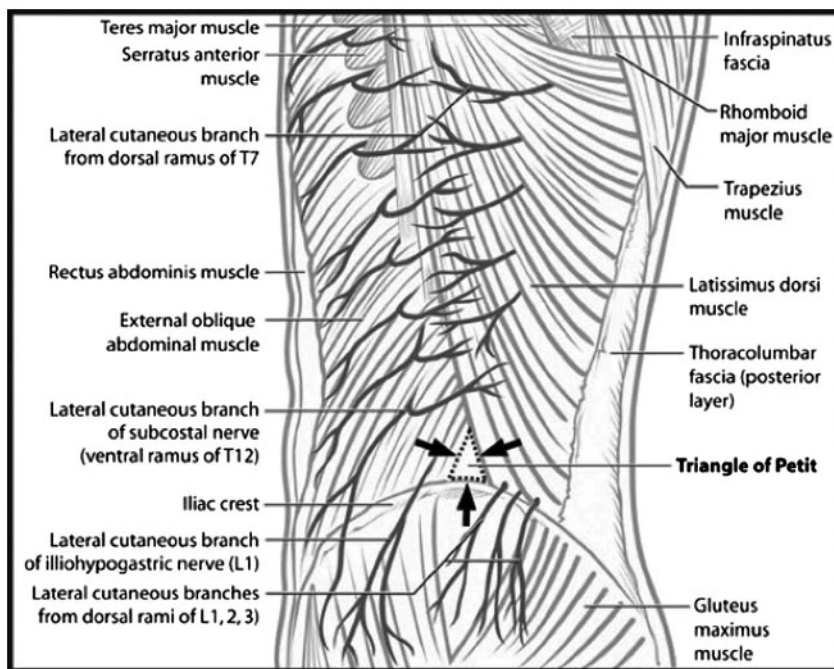


FIGURE 7. Line drawing of the surface anatomy of the abdominal wall, including the lumbar triangle of Petit (arrows). As can be seen from the diagram, the triangle is bounded posteriorly by the latissimus dorsi muscle and anteriorly by the external oblique with the iliac crest forming the base of the triangle. The floor of the triangle is formed by the IOM. Reproduced with permission from McDonnell et al.⁶

TABLE 1. Ultrasound-Guided Abdominal Wall Blocks

Block	Technique	Clinical Indication	Comments
Subcostal TAP block ^{27,28}	Probe position: placed lateral to xiphoid process; parallel to costal margin. Injection site: (1) Medial to linea semilunaris; deep to RAM and superficial to TAM where TAM tapers off medially into its fascial contribution to the posterior rectus sheath. (2) Lateral to linea semilunaris; deep to IOM and superficial to TAM. LA dosing: 0.2–0.3 mL/kg per block, concentration adjusted to keep within max recommended dose range (in mg).	Somatic analgesia for incisions in upper (T6–T7 to T9–T10) anterior abdominal wall.	Will not cover incisions lateral to anterior axillary line.
Oblique subcostal TAP block ^{29,30}	Probe position: Midclavicular line to anterior axillary line; parallel to costal margin. Injection site: Extensive injection track in TAP, deep to IOM and superficial to TAM, along the entire costal margin. LA dosing: 0.2–0.3 mL/kg per block, concentration adjusted to keep within max recommended dose range (in mg).	Somatic analgesia for incisions in upper (T6–T7 to T9–T10) anterior abdominal wall.	Technically challenging needle insertion. Will not cover incisions lateral to anterior axillary line.
Lateral (midaxillary) TAP block ^{31,32}	Probe position: Midaxillary line; parallel and superior to iliac crest. Injection site: Deep to IOM and superficial to TAM, in midaxillary line. LA dosing: 0.2–0.3 mL/kg per block, concentration adjusted to keep within max recommended dose range (in mg).	Somatic analgesia for incisions in lower (T10 to T12–L1) anterior abdominal wall.	Will not cover incisions lateral to anterior axillary line. L1 is not consistently covered.
Bilateral dual-TAP block ^{12,28,33}	Combination of bilateral subcostal and lateral TAP blocks. LA dosing: 0.15–0.2 mL/kg per block, concentration adjusted to keep within max recommended dose range (in mg).	Somatic analgesia for extensive (T7–T12) incisions in anterior abdominal wall.	Will not cover incisions lateral to anterior axillary line.
II-IH nerve block ^{34,35}	Probe position: Posterior and superior to ASIS, parallel to the line between ASIS and umbilicus. Injection site: Medial to acoustic shadow of ASIS within the TAP. LA dosing: 0.1–0.15 mL/kg, concentration adjusted to keep within max recommended dose range (in mg).	Somatic analgesia for incisions in the right or left iliac fossa of the abdomen.	Visualization of nerves is not always possible or necessary.
Rectus sheath block ^{36,37}	Probe position: Transverse orientation lateral to linea alba and just superior to umbilicus. Injection site: Medial to acoustic shadow of ASIS within the TAP. LA dosing: 0.1–0.2 mL/kg per side, concentration adjusted to keep within max recommended dose range (in mg).	Somatic analgesia for midline incisions in anterior abdominal wall.	Bilateral injections required. Divided injections superior and inferior to umbilicus may provide for better spread.
Anterior QL block ^{38–41}	Probe position: Posterior axillary line, parallel to iliac crest. Injection site: Anterior (deep) to QLM. LA dosing: 0.2–0.3 mL/kg per block, concentration adjusted to keep within max recommended dose range (in mg).	Analgesia for midlower (T8–T12) incisions in anterior abdominal wall.	Needle may be inserted in lateral-to-medial direction ^{38,39} or posterior-to-anterior (transmuscular approach ^{40,41}). Lumbar plexus block may occur with the posterior-to-anterior (transmuscular) approach.

<p>Posterior QL block³⁸</p>	<p>Probe position: Posterior axillary line, parallel to iliac crest. Injection site: Posterior (superficial) to QLM. LA dosing: 0.2–0.3 mL/kg per block, concentration adjusted to keep within max recommended dose range (in mg).</p>	<p>Analgesia for midlower (T8–T12) incisions in anterior abdominal wall.</p>	<p>Lumbar plexus block may occur.</p>
<p>TFP block^{42,43}</p>	<p>Probe position: Posterior axillary line, parallel to and against iliac crest, and angled slightly inferiorly. Injection site: Deep to tapered tip of TAM and superficial to transversalis fascia. LA dosing: 0.2–0.3 mL/kg per block, concentration adjusted to keep within max recommended dose range (in mg).</p>	<p>Analgesia for incisions over the anterior iliac crest, the anterior iliac crest itself, and L1 dermatome of the anterior abdominal wall.</p>	<p>Site of LA deposition is more inferior and anterior/lateral to that of the QL block. Lumbar plexus block may occur.</p>

LA indicates local anesthetic; USG, US-guided.

abdominal wall was patchy and incomplete. Areas that were consistently blocked were the area of injection, groin, and upper lateral thigh.

US-Guided Lateral TAP Block

Technique

The US-guided lateral TAP block was first described in 2007.^{31,47} Ultrasound allows direct visualization of the abdominal wall layers, needle placement, and local anesthetic spread in the TAP, and this was critical in popularizing the TAP block. Descriptions of the technique vary slightly in the published literature, but in general, the US transducer is placed in a transverse orientation midway between the costal margin and iliac crest and centered on the midaxillary line (Fig. 3).³² The needle is inserted in the anterior axillary line in-plane to the transducer and enters the TAP in the midaxillary line (Figs. 3 and 8). Although initially touted as a US-guided version of the landmark-guided TAP block, it is now clear that the US-guided lateral TAP is quite different with regard to where local anesthetic is injected. The point of needle entry into the TAP is anterior and superior to the LIP and triangle of Petit, which results in a different pattern of injectate spread.

Pattern of injectate spread and sensory block

Radiological studies indicate that the US-guided lateral TAP produces injectate spread confined to an area centered around the midaxillary line and that extends only as far as the costal margin, the iliac crest, and the anterior axillary line in most cases.^{46,48} Posterior spread beyond the midaxillary line is limited compared with the landmark-guided TAP block.^{33,46} Thoracoabdominal nerves that are consistently involved include T10, T11, T12, and, to a lesser extent, L1.^{19,48} T9 and above are usually not involved, as they enter only the TAP medial to the anterior axillary line.

The evidence for the extent of cutaneous sensory block is conflicting and may depend on whether assessment involves comprehensive area mapping or merely “point” testing using traditional dermatomal maps and surface landmarks. Studies using the latter approach indicate that craniocaudal coverage is variable, but the results are fairly consistent with the cadaveric dye studies. In general, the US-guided lateral TAP consistently provides blockade of the T11–T12 dermatomes and, in the majority of cases, also the T10 dermatome.^{12,19,49} The T9 and L1 dermatomes are blocked less than 50% of the time.¹⁹ Laterally, the block does not usually extend beyond the midclavicular or anterior axillary line,^{12,19} and this is attributed to failure to anesthetize the lateral cutaneous branches of the segmental nerves, which arise and leave the TAP posterior to the midaxillary line. Increasing the volume of injectate (eg, from 15 mL to 30 mL in an adult patient) does not appear to significantly increase the extent of spread.^{12,46}

On the other hand, in studies where the area of cutaneous sensory loss is systematically mapped out, this appears to be highly variable and to follow a nondermatomal distribution that does not extensively involve the anterior abdominal wall.^{13,46} Støving et al¹³ observed a greater proportion of sensory loss (76% vs 24%) lateral to the line passing through the ASIS rather than medial to it, suggesting that the lateral cutaneous branches may be anesthetized after all. As in previous studies, the craniocaudal extent of sensory loss was confined to the infraumbilical area. There was evidence of significant blockade of the abdominal musculature, which may partly explain the discrepancy between the limited pattern of cutaneous sensory loss observed in this study and clinical reports of good analgesic efficacy. The nondermatomal pattern may be due to the aforementioned existence of a TAP plexus and overlapping contribution of multiple spinal nerves to individual terminal branches.⁹

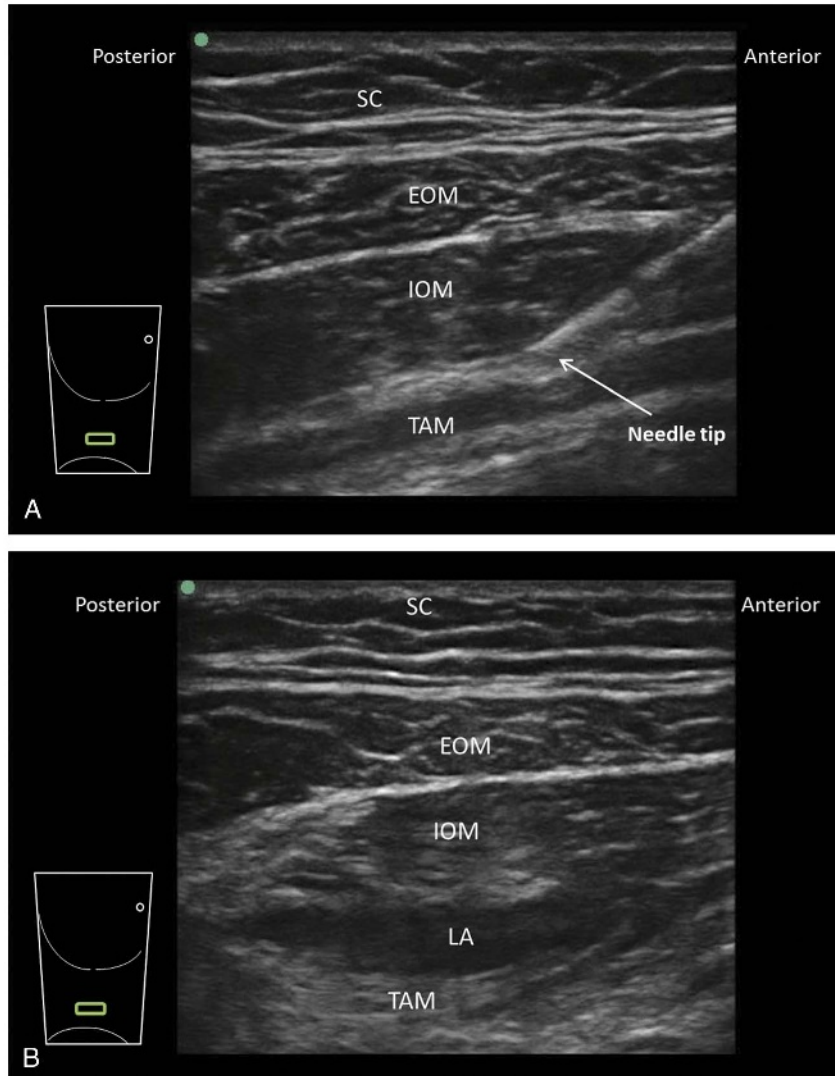


FIGURE 8. Ultrasound-guided lateral TAP block. A, Preinjection image. The US probe is placed in a transverse orientation between the costal margin and iliac crest in the midaxillary line. A needle is advanced in an anterior-to-posterior direction through the muscular layers of the abdominal wall to reach the TAP between IOM and TAM. The TAM has a characteristic darker hypoechoic appearance and is usually significantly thinner than the IOM. B, Postinjection image. Local anesthetic (LA) has distended the TAP, separating IOM and TAM. SC indicates subcutaneous tissue. Reproduced with permission from KJ Chin Medicine Professional Corporation.

US-Guided Subcostal TAP Block

Technique

The US-guided subcostal TAP block was described in 2008 as a means of reliably providing analgesia of the supraumbilical abdominal wall (T6-T9) and is based on the fact that these nerves enter the TAP at the costal margin and medial to the anterior axillary line (Fig. 3). The original description involved insertion of a 100- to 150-mm needle into the TAP close to the xiphoid process, advancing it in an inferolateral direction and injecting local anesthetic parallel to the costal margin and as far as the anterior iliac crest.²⁹ Alternatively, the needle may be inserted in the anterior axillary line and in a superomedial direction toward the xiphoid process; this allows preoperative placement of a catheter outside the surgical field.^{33,50} This approach, subsequently termed the “oblique subcostal TAP block,”³⁰ requires a high degree of technical skill. Subsequent modifications include performing multiple separate injections along the costal margin²⁷ or performing

a single “point” injection either medial to the linea semilunaris (between RAM and TAM)¹² or lateral to it (between IOM and TAM)^{27,51} (Fig. 9).

Pattern of injectate spread and sensory block

Cadaveric and volunteer studies support the potential to block the upper segmental nerves (T6-T9) as they emerge into the abdomen. However, the extent of sensory block seen with the subcostal TAP block is variable and may depend on where the local anesthetic is deposited in relation to where nerves emerge from under the costal margin into the TAP. Injection lateral to the linea semilunaris produces a block centered on T10-T11 and not extending higher than T9 most of the time.^{19,27} If T6-T8 coverage is desired, local anesthetic should be injected medial to the linea semilunaris, between RAM and TAM, and as close to the xiphoid process as possible.^{12,27} Even then, it appears difficult to achieve spread to T6 and T7 more than 50% to 70% of the time.^{28,33}

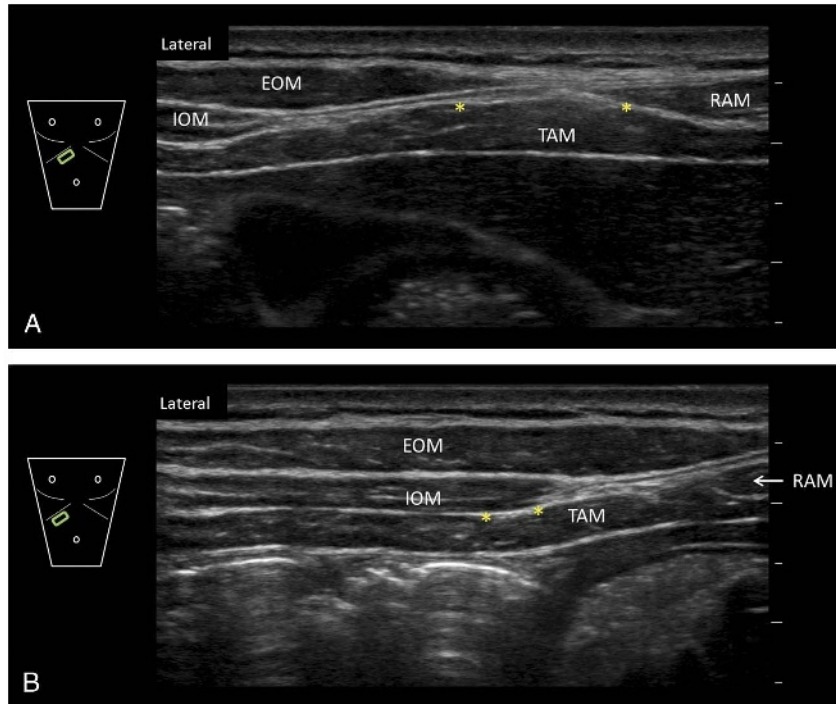


FIGURE 9. Sonoanatomy of the US-guided subcostal TAP block. The probe is placed parallel and adjacent to the costal margin. Closer to the midline (upper image A), the TAP is the plane between RAM and TAM. The EOM and IOM exist as aponeuroses in this region, which contribute to the formation of the anterior rectus sheath. The EOM and IOM become visible as the probe is moved more laterally along the costal margin (lower image B). The asterisks indicate suitable injection points for a US-guided subcostal TAP block. SC indicates subcutaneous tissue. Reproduced with permission from KJ Chin Medicine Professional Corporation.

Injection that extends to the lateral aspect of the costal margin and iliac crest can produce a block that extends inferiorly to T12 and occasionally the L1 dermatome.^{19,27} The lateral cutaneous branches are not blocked, and thus, incisional analgesia does not extend lateral to the anterior axillary line.^{33,52}

US-Guided Bilateral Dual TAP Block

Technique

A combination of the US-guided subcostal and lateral TAP blocks, termed the US-guided bilateral dual TAP block and involving a total of 4 injections, has been proposed as a method of providing analgesia to the entire anterior abdominal wall.^{12,28} In the original description, the subcostal block is performed by a “point” injection medial to the linea semilunaris, between RAM and TAM. Sondekoppam et al³³ have recently proposed a modification that utilizes an extended needle track similar to the oblique subcostal approach and is designed primarily to allow the preoperative insertion of catheters outside the surgical field. Needle insertion occurs in a lateral-to-medial direction, starting at the anterior axillary line and traveling along the costal margin superiorly to reach the linea semilunaris. The needle is then withdrawn and inserted inferiorly toward the pubic symphysis and parallel to the inguinal ligament to provide coverage of the lower abdomen.

Pattern of injectate spread and sensory block

In their evaluations of the US-guided bilateral dual-TAP block, Børglum et al¹² have shown that the lateral TAP block produces spread confined to the lower abdomen and a sensory block of T10-T12, whereas the subcostal TAP block produced spread in the upper abdominal TAP. By combining the two, they were able to consistently obtain a cutaneous sensory block of T9-T12 with

extension to T7-T8 in the majority of subjects and occasionally as high as T6.^{12,28}

Sondekoppam et al³³ evaluated their own modified technique in a small cadaveric study and similarly found dye spread involving T8 to L1 thoracoabdominal nerves in the majority of injections and spread to T7 in a small proportion. The lateral extent of dye spread was confined to an area between the anterior and midaxillary line, leading the investigators to conclude that the lateral cutaneous branches are unlikely to be covered in this approach.

Surgical TAP Block

Several surgical approaches to the TAP block have been described. In laparoscopic surgery, the surgeon inserts a block needle percutaneously, with entry into the TAP signaled by tactile pops and confirmed by visualization of inward bulging of the TAM as local anesthetic is injected.⁵³ An alternative technique has been described in open abdominal surgery, where the wound edges are retracted and a needle inserted from the interior of the abdomen through the parietal peritoneum and into the TAP as signaled by a single tactile pop.⁵⁴⁻⁵⁶ Finally, a technique of surgical dissection into the TAP, followed by direct injection or placement of a catheter, has been described in abdominoplasty⁵⁷ and abdominal flap breast reconstruction surgery.⁵⁸ Advantages cited for the surgical approach include better matching of the site of injection to site of surgery, ease and speed of performance, and accuracy of injection into the correct tissue plane. There are no studies examining the spread of injectate with surgically placed TAP blocks or catheters, and most of the clinical data come from case series and retrospective case-control studies.^{57,59-61} Although the latter suggest that surgical TAP blocks can reduce early postoperative

opioid requirements and improve pain scores, the limited randomized controlled trial (RCT) data available at present, mostly in the setting of laparoscopic abdominal^{54,56,62} and breast reconstruction surgery,⁶³ indicate only a modest analgesic benefit compared with placebo. In particular, Lapmahapaisan et al⁵⁶ failed to show analgesic benefit in pediatric open abdominal surgery, which they attributed to the limited ability of their TAP block to cover subcostal incisions.

Clinical Efficacy of the TAP Block

A recent meta-analysis of US-guided TAP block (encompassing all approaches and surgery types) concluded that it confers a statistically significant but clinically modest analgesic benefit (mean reductions of 6 and 11 mg of intravenously administered [IV] morphine at 6 and 24 hours, respectively) in adult patients undergoing abdominal laparotomy, laparoscopy, or cesarean delivery.⁶⁴ A similar meta-analysis of pediatric TAP and rectus sheath blocks also reported analgesic benefit but only in the early postoperative period (first 6-8 hours).⁶⁵ The authors in both articles rightly note that their findings should be viewed with caution in view of the pronounced heterogeneity in the included studies and their analysis. As presented previously, different TAP block approaches produce different patterns of local anesthetic spread,⁴⁶ which may in turn influence analgesic efficacy. This caveat must be borne in mind when interpreting the overall evidence for clinical efficacy of the TAP block in various surgical settings and may be partly responsible for some of the conflicting data. In particular, the landmark-guided TAP block appears to have a different mechanism of action from the US-guided TAP blocks. The posterior and cranial spread to the thoracic paravertebral space demonstrated with the landmark-guided TAP block may produce superior analgesia and thus explain the preponderance of favorable analgesic outcomes in studies that used this approach. In the following section, we present a qualitative review of the evidence for the different TAP block approaches according to type of surgery, with data from the RCTs summarized in Table 2.

Upper Abdominal Surgery

Major open upper abdominal surgery

The US-guided subcostal TAP is preferred to the US-guided lateral TAP block in upper abdominal surgery because it is more likely to cover the supraumbilical dermatomes. For extensive surgery, both approaches may be combined as in the bilateral dual-TAP block. There are no published data on the efficacy of the landmark-guided TAP block specifically in upper abdominal surgery.

Four studies compared the postoperative analgesia provided by US-guided TAP blocks with thoracic epidural analgesia in major upper abdominal surgery.^{50,52,66,67} Two of these utilized bilateral subcostal TAP catheters inserted at the end of surgery and an intermittent bolus regimen of local anesthetic^{52,66}; one utilized a preincisional single-shot subcostal TAP block⁶⁷; and the fourth inserted preincisional bilateral dual-TAP catheters (4 in total, using the approach described by Sondekoppam et al³³) with continuous infusion of local anesthetic.⁵⁰ On the whole, these studies indicate that subcostal TAP block is a useful alternative in upper abdominal surgery where epidural analgesia is contraindicated or undesirable and also has fewer adverse effects, particularly hypotension.^{50,66,67} Nevertheless, thoracic epidural analgesia is still likely to provide superior analgesia compared with the subcostal TAP block, particularly if the incision extends lateral to the anterior axillary line,⁵² if there is a large component of visceral pain, or if TAP catheters are not utilized to extend analgesic duration. Furthermore, TAP catheter insertion can be technically complex,

time consuming, and associated with technical failure⁵² when inserted postoperatively because of disruption of the normal tissue planes.

Laparoscopic cholecystectomy

Both US-guided subcostal and lateral TAP blocks have been studied in laparoscopic cholecystectomy. The subcostal TAP provides superior analgesia compared with the lateral TAP block,^{68,69} which is not surprising given that a standard laparoscopic cholecystectomy utilizes subcostal port sites in addition to a periumbilical one.

Although early studies suggested that the lateral TAP block may be of benefit,^{70,71} they suffered from methodological limitations, including use of a surgical technique utilizing only infraumbilical port sites, and lack of a multimodal analgesic regimen. Subsequent studies have shown marginal benefit of TAP blocks in reducing opioid consumption or pain scores.⁷²⁻⁷⁵ Overall, TAP blocks do not have a routine place in laparoscopic cholecystectomy, given the low pain scores that can be achieved with systemic multimodal analgesia and local anesthetic infiltration of port sites.^{72,75}

Bariatric surgery

Two RCTs have examined the analgesic efficacy of TAP blocks in laparoscopic gastric (roux-en-Y) bypass surgery, with conflicting results.^{51,76} Although Sinha et al⁷⁶ reported that a post-surgical US-guided TAP block reduced 24-hour opioid consumption and pain scores, no details on the TAP block technique and intraoperative or postoperative analgesic regimen were supplied, and it appears likely that multimodal analgesia was not administered. Albrecht et al,⁵¹ on the other hand, found that when added to a regimen of intraoperative ketorolac, local anesthetic infiltration of port sites, and postoperative acetaminophen a presurgical US-guided subcostal TAP block did not significantly reduce 24-hour opioid consumption, time to first analgesic request, or pain scores up to 48 hours. At this time, therefore, TAP blocks do not appear to be a useful addition to multimodal analgesia in this population.

Lower Abdominal Surgery (Nonobstetric)

Major gynecological surgery including total abdominal hysterectomy

Multiple studies have examined the role of bilateral TAP blocks in major open gynecological surgery, especially total abdominal hysterectomy. A 2013 meta-analysis of data from 4 published studies (one using the landmark-guided TAP block⁷⁷ and the others using the US-guided lateral TAP block⁷⁸⁻⁸⁰) reported that TAP blocks significantly reduced 24-hour opioid consumption and reduced rest and dynamic pain at 2 hours but not 24 hours following hysterectomy.¹¹⁰

More recent studies are less positive, however. Two studies that investigated the addition of bilateral US-guided lateral TAP blocks to a perioperative multimodal analgesia regimen of nonsteroidal anti-inflammatory drugs (NSAIDs) and acetaminophen found no difference in 24-hour opioid consumption.^{81,82} There were minimal reductions in rest and dynamic pain, with the greatest effect observed in the first 2 postoperative hours. Similarly, 2 studies^{83,84} comparing US-guided lateral TAP block to placebo in the setting of robotic surgery for gynecologic cancer found no difference in 24-hour opioid consumption or pain scores. Two additional studies, on the other hand, both using the landmark-guided TAP approach, reported that bilateral TAP blocks were beneficial in reducing postoperative opioid consumption and pain scores compared with either placebo⁸⁵ or wound infiltration.⁸⁶

TABLE 2. Summary of RCTs on TAP Blocks

Study	Standardized Management	Intervention	Comparator	Analgesic Outcomes	Other Outcomes/Comments
<p>Major upper abdominal surgery Niraj et al,⁵² 2011</p> <p>N = 62, open hepatobiliary or renal surgery (incision superior to T10). Intraop: GA + T7-T9 epidural 20 mL of 0.25% bupivacaine. Postop: PO acetaminophen 1 g every 6 h, IV tramadol 5-100 mg every 6 h prn.</p>	<p>Bilateral USG subcostal TAP catheters inserted at end of surgery. Intermittent boluses of 1 mg/kg 0.375% bupivacaine every 8 h for 72 h.</p>	<p>Postop patient-controlled epidural infusion of 0.125% bupivacaine + fentanyl 2 µg/mL at 6-12 mL/h.</p>	<p>Similar pain scores at rest and on coughing up to 72 h postop. Significantly (Sig) more tramadol use in TAP vs epidural group (median 400 mg vs 200 mg). 8 patients (30%) in the TAP group had pain from lateral incisions or drain sites.</p>	<p>Therapeutic success rate of 63% in TAP group vs 78% in epidural group (NS). Technical failure of TAP catheter insertion in 7%. 45% of TAP catheters had to be resited postop vs 7% of epidurals.</p>	
<p>Wahba and Kamal,⁶⁶ 2014</p> <p>N = 44, upper abdominal surgery. Intraop: GA + IV fentanyl infusion. Postop: IV PCA morphine. No systemic MMA.</p>	<p>Bilateral USG subcostal TAP catheters inserted at end of surgery. Loading dose of 20 mL followed by 15 mL of 0.25% bupivacaine every 8 h for 48 h.</p>	<p>T9-T10 thoracic epidural, inserted preop. Postop: loading dose of 10 mL of 0.125% bupivacaine followed by infusion at 6-8 mL/h.</p>	<p>Sig higher pain scores at rest and on coughing up to 48 h postop in the TAP group. Sig more patients needing IV PCA morphine in TAP vs epidural group (100% vs 73%). Sig shorter time to first morphine dose in TAP vs epidural group (mean 210 vs 311 min). Sig higher morphine use on POD 1 in TAP vs epidural group (median 18 vs 12 mg) and POD 2 (median 11 vs 7 mg).</p>	<p>Sig longer time to flatus in TAP vs epidural group (mean 52 vs 45 h). Sig shorter time to ambulation in TAP vs epidural group (mean 48 vs 63 h) Sig lower incidence of hypotension in TAP vs epidural group (9% vs 46%). Lower patient satisfaction in TAP vs epidural group (median 1 vs 3 on 0-to 3-point scale).</p>	
<p>Wu et al,⁶⁷ 2013</p> <p>N = 82, open radical gastrectomy. Intraop: GA + IV remifentanyl infusion + IV sufentanil boluses every 1.5 h. Postop: IV PCA morphine. No systemic MMA.</p>	<p>Bilateral preincisional USG oblique subcostal TAP blocks with 20 mL of 0.375% ropivacaine.</p>	<p>GA group: no block, systemic analgesia only. TEA group: T8-T9 thoracic epidural, inserted preop. Intraop: Loading dose 8 mL 0.25% ropivacaine, followed by 5 mL 0.25% ropivacaine every 1 h. Postop: infusion of 0.125% bupivacaine + morphine 8 µg/mL at 5 mL/h.</p>	<p>TAP vs GA groups: Sig lower dynamic pain scores at 0-6 h in TAP group, but similar rest and dynamic pain scores up to 72 h. Sig less morphine use at 0-6 h (median 5 vs 8 mg) in TAP group, but similar at all other intervals up to 72 h. TAP vs TEA groups: Similar rest and dynamic pain scores up to 72 h. Similar morphine use at 0-6 h (median 5 vs 3 mg) but sig higher in TAP group at all other intervals up to 72 h.</p>	<p>Technical failure of epidural insertion in 2 patients (7%) in TEA group. Higher intraop ephedrine requirement and incidence of postoperative hypotension in the TEA vs TAP or GA group (21% vs 0% vs 0%).</p>	

Continued next page

TABLE 2. (Continued)

Study	Standardized Management	Intervention	Comparator	Analgescic Outcomes	Other Outcomes/Comments
Ganapathy et al, ⁵⁰ 2015	N = 50, open laparotomy. Intraop: GA + IV fentanyl or hydromorphone bolus prn. Postop: acetaminophen 650 mg every 6 h, naproxen 500 mg every 12 h, gabapentin 300 mg every 12 h.	Bilateral preincisional USG dual-TAP catheters (4 in total) using lateral-to-medial approach. Loading dose 20 mL of 0.5% ropivacaine at each catheter site, followed by infusion of 0.35% ropivacaine at 4–5 mL/h into the 2 catheters on each side using a Y-connector and elastomeric pump. Postop: IV PCA hydromorphone	T7-T8 or T8-T9 thoracic epidural analgesia (TEA), inserted preop and loaded with 0.25% bupivacaine 5 mL + 3 mL prn to achieve a T6-T12 sensory block. Intraop: infusion of 0.1% bupivacaine + hydromorphone 10 µg/mL at 8 mL/h. Postop: infusion of 0.1% bupivacaine + hydromorphone 10 µg/mL at 8 mL/h with 3 mL PCA bolus every 20 min prn for 72 h.	Similar rest and dynamic pain scores in both groups up to 72 h. Similar morphine use at 0–24 h in TAP vs TEA group (mean 14 vs 16 mg) and 48–72 h (13 vs 10 mg), but sig higher in TAP group at 24–48 h (13 vs 5 mg). Fewer patients with pain scores >5/10 in TAP group (15% vs 29%, n.s.)	No block failures in either group. Similarly high patient satisfaction scores in both groups. Higher incidence of significant hypotension in TEA group (21% vs 0%). Longer block performance time in TAP group (mean 36 min vs 15 min).
Lapmahapaisan et al, ⁵⁶ 2015	N = 54, pediatric major open abdominal surgery (upper > lower). Intraop: GA + IV fentanyl prn. Postop: IV fentanyl or morphine prn. No MMA.	Group I: bilateral surgical TAP blocks with 0.5–1 mL/kg 0.25% bupivacaine at end of surgery.	Group II: Wound infiltration with 0.5–1 mL/kg 0.25% bupivacaine at end of surgery. Group III: No blocks.	No sig difference between groups in incidence of inadequate analgesia or proportion of pain-free patients. No sig difference in opioid use over 24 h or time to 1st analgesic use between groups.	
Laparoscopic cholecystectomy					
Bhatia et al, ⁶⁸ 2014	N = 60, laparoscopic cholecystectomy. Intraop: GA IV morphine 0.1 mg/kg. Postop: IV acetaminophen 1 g every 6 h, IV tramadol 1–2 mg/kg prn.	Group I: Bilateral USG lateral TAP. Group II: Bilateral USG subcostal TAP. Bolus injection of 15 mL 0.375% ropivacaine on each side; all blocks performed at end of surgery.	Group III: No blocks.	Sig lower rest and dynamic pain scores with (a) subcostal TAP vs no block up to 24 h; (b) lateral TAP vs no block up to 2 h; (c) subcostal TAP vs lateral TAP from 4–24 h. Lower 24 h tramadol use in subcostal TAP vs lateral TAP vs no block (mean 27 mg vs 89 mg vs 125 mg). Longer time to first request for opioid in subcostal TAP vs lateral TAP vs no block (mean 552 min vs 411 min vs 150 min).	No sig difference in nausea, vomiting, or sedation between groups. Mean dynamic pain scores (0–10) in patients receiving no block ranged from 2.5 to 4.2 during 1st 24 h.

Shin et al, ⁶⁹ 2014	N = 45, laparoscopic cholecystectomy. Intraop: GA + IV ketorolac 30 mg + IV fentanyl 1 pm. Postop: IV fentanyl, IV ketorolac 30 mg pm in PACU; IV nabuphine 10 mg pm in ward. No MMA.	Group II: Bilateral USG lateral TAP. Group III: Bilateral USG oblique subcostal TAP Bolus injection of 20 mL 0.375% ropivacaine per side; all blocks performed preincision.	Group 1: no blocks.	Sig lower rest and dynamic pain scores with (a) subcostal TAP vs no block up to 3 h; (b) lateral TAP vs no block up to 1 h; (c) subcostal TAP vs lateral TAP from 1–24 h. No sig difference in analgesic use between groups.	Oblique subcostal TAP tended to produce cutaneous sensory block from T9–T10 vs T12–L1 with lateral TAP (but not consistently seen). Mean dynamic pain scores (0–10) in patients receiving no block ranged from 3.0 to 4.7 at 3–24 h.
El-Dawlatly et al, ⁷⁰ 2009	N = 42, laparoscopic cholecystectomy using 4 infraumbilical ports. Intraop: GA + sufentanil 0.1 µg/kg pm. Postop: IV PCA morphine. No MMA.	Preincisional bilateral USG lateral TAP block with 15 mL 0.5% bupivacaine per side.	No blocks.	Sig less intraop sufentanil in TAP group (mean 8.6 µg vs 23.0 µg). Sig less morphine use in 24 h in TAP group (mean 10.5 mg vs 22.8 mg). Pain scores not assessed.	Fewer patients in either TAP group complained of sleep disturbance due to pain.
Ra et al, ⁷¹ 2010	N = 54, laparoscopic cholecystectomy. Intraop: GA (TIVA) + remifentanyl infusion. Postop: IV fentanyl 20 µg pm or IV ketorolac 30 mg pm in PACU, and IV ketorolac 30 mg every 8 h for 1st 24 h.	Preincisional bilateral USG lateral TAP blocks with 15 mL of LA per side. Group I: 0.25% bupivacaine. Group II: 0.5% bupivacaine.	Control group: no blocks.	Sig lower pain scores in both TAP groups vs control group up to 24 h. Similar pain scores between TAP groups. Fewer patients in either TAP group received ketorolac or fentanyl in PACU vs control.	
Petersen et al, ⁷² 2012	N = 74, laparoscopic cholecystectomy. Intraop: GA (TIVA) + remifentanyl infusion + IV sufentanil 0.2 µg/kg at end of surgery. Postop: PO acetaminophen 1 g every 6 h, PO ibuprofen 400 mg every 6 h. IV morphine 2.5 mg pm in 1st 2 h; PO ketobemidone 2.5 mg pm in 2–24 h.	Preincisional bilateral USG lateral TAP with 20 mL 0.5% ropivacaine per side.	No blocks.	Sig reduction in dynamic and rest pain over 24 h (measured as area under curve). Sig lower morphine use in TAP vs control groups at 0–2 h (median 5 mg vs 7.5 mg). No sig difference in ketobemidone use in TAP vs control groups at 2–24 h (median 0 mg vs 5 mg).	Similar incidence of nausea and vomiting, and level of sedation between groups. Graphical data indicate that differences in pain score are most marked up to 8 h, but similar at 24 h.
Tolchard et al, ⁷³ 2012	N = 43, laparoscopic cholecystectomy. Intraop: GA + fentanyl 3 µg/kg + acetaminophen 15–20 mg/kg + diclofenac 0.5 mg/kg. Postop: IV fentanyl 20 µg pm in PACU; IM morphine, PO tramadol, or PO codeine and “non-opioid” analgesics in ward.	Preincisional unilateral USG subcostal TAP block with 1 mg/kg of bupivacaine (mean volume 22 mL).	Postoperative LA infiltration of port sites with 1 mg/kg bupivacaine (mean volume 21 mL).	Sig lower pain scores in TAP group up to 4 h. Similar number of patients required fentanyl in PACU but dose was sig lower in TAP group (median 0.9 vs 1.5 µg/kg). Sig lower opioid use in TAP group over 8 h (median 9.2 mg vs 16.9 mg IV morphine equivalents).	Shorter time to discharge from PACU in TAP group (median 65 vs 110 min).
Chen et al, ⁷⁴ 2013	N = 40, laparoscopic cholecystectomy. Intraop: GA + IV fentanyl 0.5 µg/kg pm. Postop: IV morphine 0.05 mg/kg pm. No MMA.	Preincisional bilateral oblique subcostal TAP with 20 mL of 0.375% ropivacaine per side.	IV morphine 0.1 mg/kg post-induction of GA.	No sig difference in intraop fentanyl use in TAP vs control groups (mean 24.5 vs 31.3 µg) or in postop morphine use (0.0 mg vs 0.4 mg).	No sig difference in sedation or nausea and vomiting between groups. Sig shorter time to extubation in TAP group (mean 10.4 min vs 12.4 min).

Continued next page

TABLE 2. (Continued)

Study	Standardized Management	Intervention	Comparator	Analgescic Outcomes	Other Outcomes/Comments
Ortiz et al, ⁷⁵ 2012	N = 74, laparoscopic cholecystectomy. Intraop: GA + IV ketorolac 30 mg + IV fentanyl 50 µg pm + IV morphine pm at end of surgery. Postop: Hydrocodone 10 mg + acetaminophen 1 g every 6 h, IV morphine 4 mg every 3 h pm.	Preincisional bilateral USG lateral TAP blocks with 15 mL of 0.5% ropivacaine per side.	Preincisional infiltration of port sites with total of 20 mL of 0.5% ropivacaine.	No sig difference in pain scores between groups up to 24 h. No sig difference in intraop fentanyl use in TAP vs control groups (mean 237 vs 245 µg), intraop morphine use (mean 5.0 vs 5.8 mg), or 24 h morphine use (16.1 vs 15.4 mg)	Similar incidence of nausea between groups.
Bariatric surgery					
Sinha et al, ⁷⁶ 2013	N = 100, laparoscopic gastric bypass surgery. Intraop: GA, no analgesic details given. Postop: Tramadol (route, dose, and interval not specified). No MMA.	Postoperative bilateral USG TAP blocks (not specified if subcostal or lateral) with 20 mL of 0.375% ropivacaine per side.	No blocks.	Sig lower pain scores in TAP vs control group up to 24 h. Pain scores were highest at 1 h (median 2 vs 4) and lowest at 24 h (0 vs 1). Sig lower tramadol use in TAP vs control group over 24 h (mean 9 mg vs 48 mg).	Shorter time to ambulation in TAP vs control group (mean 6.3 h vs 8.0 h).
Albrecht et al, ⁵¹ 2013	N = 57, laparoscopic gastric bypass surgery. Intraop: GA + remifentanyl infusion + IV ketorolac 30 mg + LA infiltration of port sites with 20 mL of 0.25% bupivacaine. Postop: IV fentanyl + IV morphine pm in PACU. PO acetaminophen every 6 h + PO oxycodone 5–10 mg every 4 h pm, or IV morphine 2–6 mg IV every 3 h pm.	Preincisional bilateral USG subcostal TAP blocks with 30 mL of 0.25% bupivacaine per side.	No blocks.	Similar rest and dynamic pain scores up to 48 h. No sig difference in 24 h opioid use in TAP vs control group (mean 32.2 mg vs 35.6 mg IV morphine equivalents). No sig difference in time to 1st analgesic request in TAP vs control group (52 vs 25 min).	Similar rates of nausea and vomiting, pruritus and length of hospital stay between groups.
Major gynecological surgery					
Carney et al, ⁷⁷ 2008	N = 50, total abdominal hysterectomy. Intraop: GA + IV morphine 0.15 mg/kg + PR diclofenac 100 mg + PR acetaminophen 1 g. Postop: IV PCA morphine + PR acetaminophen 1 g every 6 h + PR diclofenac 100 mg every 16 h.	Preincisional bilateral LMG TAP block with 1.5 mg/kg of 0.75% ropivacaine (max 20 mL) per side.	Sham bilateral TAP blocks with 20 mL 0.9% saline.	Sig lower rest pain scores in TAP vs control group at 6 h (median 2 vs 4), 24 h, (median 1 vs 3) and 36 h (median 1 vs 3). Sig lower morphine use in TAP vs control group over 24 h (mean 21.1 vs 39.6 mg) and over 48 h (26.8 vs 55.3 mg). Sig longer time to 1st PCA morphine request in TAP vs control group (median 45 vs 12.5 min).	Sig lower rate of sedation in TAP vs control group (37% vs 63%). Similar rate and severity of nausea.

Atim et al., ⁷⁸ 2011	N = 60, total abdominal hysterectomy. Intraop: GA + IV diclofenac 75 mg + IV tramadol 0.5 mg/kg. Postop: IV PCA tramadol + IM pethidine 1 mg/kg prn. No MMA.	Group I: preincisional bilateral USG lateral. TAP blocks with 20 mL 0.25% bupivacaine per side. Group II: Wound infiltration with 20 mL 0.25% bupivacaine at end of surgery. No MMA.	Sham bilateral TAP blocks with 20 mL 0.9% saline.	Lower rest and dynamic pain scores, and tramadol use in TAP vs control group up to 24 h. Similar rest and dynamic pain scores in TAP vs infiltration group up to 4 h, but lower in TAP group at 6 h and 24 h. Lower tramadol use in TAP group up to 24 h. Sig lower rest and dynamic pain scores in infiltration vs control group up to 4 h.
Griffiths et al., ⁷⁹ 2010	N = 65, major gynecological surgery via midline incision. Intraop: GA + IV morphine 0.1–0.2 mg/kg + IV acetaminophen 1 g + IV parecoxib 40 mg. Postop: IV PCA morphine + PO/IV acetaminophen 1 g every 6 h.	Bilateral USG lateral TAP blocks with 20 mL of 0.5% ropivacaine per side after wound closure.	Sham bilateral USG TAP blocks with 0.9% saline.	No sig difference in incidence of severe rest or dynamic pain (>5/10) at 2 h or 24 h. No sig difference in morphine use in TAP vs control groups at 2 h (mean 11.9 vs 13.5 mg) or 24 h (36 vs 34 mg).
Shin et al., ⁸⁰ 2011	N = 32, gynecological surgery via transverse incision. Intraop: GA (TIVA) + remifentanyl infusion. Postop: IV PCA ketorolac-sufentanil. Rescue IV meperidine or ketorolac prn. No MMA.	Preincisional bilateral USG lateral TAP block with 20 mL 0.375% ropivacaine per side.	No TAP blocks.	Sig lower pain scores in TAP vs control group at 2 h (mean 3.0 vs 5.2), 24 h (mean 0.9 vs 2.2) but not 48 h (0.4 vs 1.6). No sig difference in IV PCA use in TAP vs control group over 48 h (102 mL vs 108 mL). Lower rescue analgesic use in TAP vs control group.
Røjskjær et al., ⁸¹ 2015	N = 46, total abdominal hysterectomy. Intraop: GA (TIVA) + remifentanyl infusion + IV sufentanil 0.3 µg/kg at end of surgery. Postop: IV PCA morphine + PO acetaminophen 1 g every 6 h + ibuprofen 600 mg every 6 h.	Preincisional bilateral USG lateral TAP block with 20 mL 0.75% ropivacaine per side.	Sham bilateral USG TAP blocks with 0.9% saline.	Sig lower rest pain scores in TAP vs control group at 2 h, and lower dynamic pain scores at 8 h. No sig differences in rest or dynamic pain at other time points. No sig difference in morphine use in TAP vs control group at 24 h (mean 36 vs 33 mg).
Gasanova et al., ⁸² 2013	N = 75, total abdominal hysterectomy. Intraop: GA + IV fentanyl/prn + IV morphine 0.1–0.15 mg/kg. Postop: IV PCA morphine.	Group I: Bilateral USG lateral TAP blocks with 20 mL 0.5% bupivacaine per side at end of surgery + IV ketorolac 30 mg + postop MMA. Group II: TAP blocks at end of surgery only.	Group III: Intraop IV ketorolac 30 mg. Postop MMA: IV ketorolac 30 mg every 6 h + PO acetaminophen 650 mg every 6 h.	No sig difference in resting pain scores between groups over 48 h. Sig difference in dynamic pain scores between groups I and III, but not between groups I and II, or II and III. No sig difference in morphine use between groups at 24 h (I vs II vs III: 38.4 vs 38.6 vs 42.6 mg).

Continued next page

TABLE 2. (Continued)

Study	Standardized Management	Intervention	Comparator	Analgasic Outcomes	Other Outcomes/Comments
Hotujec et al, ⁸³ 2015	N = 64, robotic-assisted laparoscopic gynecological oncology surgery. Intraop: GA. No other analgesics given. Postop: "standard management" with IV + PO opioids and NSAIDs.	Preincisional unilateral USG lateral TAP block with 30 mL 0.25% bupivacaine.	Sham TAP block with 0.9% saline.	No sig difference in pain scores at 24 h in TAP vs control group (mean 6.44 vs 6.97). No sig difference in morphine use at 24 h in TAP vs control group (mean 64.9 vs 69.3 mg).	No sig difference in patient satisfaction with analgesia between groups.
Torup et al, ⁸⁴ 2015	N = 65, robotic-assisted laparoscopic hysterectomy. Preop: PO acetaminophen 1 g + diclofenac 50 mg or ibuprofen 400 mg. Intraop: GA (TIVA) + remifentanyl infusion + IV morphine 0.2 mg/kg. Postop: IV PCA morphine + PO acetaminophen 1 g every 6 h + diclofenac 50 mg or ibuprofen 400 mg every 8 h.	Preincisional bilateral USG lateral TAP block with 20 mL 0.5% ropivacaine per side.	Sham TAP blocks with 0.9% saline.	No sig difference in pain scores in TAP vs control group at 1 h (median 4.2 vs 4.0) or over 24 h (2.0 vs 2.1). No sig difference in morphine use at 24 h in TAP vs control group (median 17.5 mg vs 17.5 mg).	No sig differences in nausea or vomiting between groups.
Amr and Amin, ⁸⁵ 2011	N = 68, total abdominal hysterectomy. Intraop: GA + IV fentanyl 1 µg/kg prn. Postop: IV morphine 20–50 µg/kg prn. No MMA.	Group I: Preincisional bilateral LMG TAP blocks with 20 mL 0.375% bupivacaine. Group II: TAP blocks at end of surgery.	Group III: Sham block.	Sig lower dynamic pain scores up to 48 h in both group I and II vs group III. Sig lower dynamic pain scores up to 48 h in group I vs II. Sig lower intraop fentanyl requirements in group I vs II vs III (mean 81 vs 170 vs 169 µg). Sig lower morphine use at 48 h in both group I and II vs group III (mean 21 mg vs 33 mg vs 66 mg). Sig longer time to first analgesic request in both group I and II vs group III (135 vs 120 vs 102 min).	Lower incidence of PONV in group I and II vs III (16% vs 29% vs 67%). Sig lower incidence of chronic pain in group I vs groups II and III. Failure of TAP block (absence of loss to cold sensation) was 6%. These patients were excluded from analysis.
Sivapurapu et al, ⁸⁶ 2013	N = 52, gynecological surgery (unspecified). Intraop: GA + IV fentanyl 0.5 µg/kg prn. Postop: IV PCA morphine. No MMA.	Bilateral LMG TAP block with 0.3 mL/kg of 0.25% bupivacaine per side at end of surgery.	Wound infiltration with 0.6 mL/kg of 0.25% bupivacaine.	Sig lower pain scores in TAP vs infiltration group up to 24 h. Sig lower morphine use in TAP vs infiltration group at 24 h (mean 22 vs 29 mg). Sig longer time to 1st analgesic use in TAP vs infiltration group (148 vs 85 min).	

De Oliveira et al, ⁸⁷ 2011	N = 75, laparoscopic hysterectomy. Intraop: GA + remifentanyl infusion + IV hydromorphone 10 µg/kg + IV ketorolac 30 mg. Postop: IV PCA hydromorphone + ibuprofen 600 mg every 6 h.	Group I: preincisional bilateral USG lateral TAP blocks with 20 mL 0.5% ropivacaine per side. Group II: preincisional bilateral USG lateral TAP blocks with 20 mL 0.25% ropivacaine per side.	Sig lower pain scores for both groups I and II vs group III up to 24 h. Sig lower opioid use in group I vs both groups II and III over 24 h (median 7.5 vs 15 vs 15 mg IV morphine equivalents).	Sig better quality of recovery scores in both group I and II vs group III.
Kane et al, ⁸⁸ 2012	N = 58, laparoscopic hysterectomy. Bilateral USG lateral TAP blocks with 20 mL 0.5% ropivacaine per side at the end of surgery. Intraop: GA + IV ketorolac 30 mg + unspecified analgesics prn Postop: "Standard" PO and IV analgesics (unspecified)	No TAP blocks.	No sig difference in pain scores in TAP vs control group at 2 h (median 5 vs 6) or 24 h (median 5 vs 5). No sig difference in morphine use in TAP vs control group on POD 0 (median 11.7 vs 11.8 mg) and POD 1 (median 7.5 vs 9.0 mg).	No sig difference in quality of recovery scores between groups.
Calle et al, ⁸⁹ 2014	N = 197, outpatient laparoscopic hysterectomy. Intraop: GA + remifentanyl infusion + IV morphine prn Postop: IV morphine prn in PACU. PO acetaminophen 1 g every 6 h + PO ibuprofen 400 mg every 8 h post-discharge.	Bilateral surgical TAP blocks with 1.5 mg/kg bupivacaine in 20 mL per side at the end of surgery.	Sig lower pain scores at discharge in TAP vs control group (mean 3.8 vs 3.1). No sig differences in pain scores between groups at 24 h, 48 h, or 72 h. No sig differences in perioperative morphine use in TAP vs control group (mean 1.8 vs 1.49 mg).	No sig difference in PACU or overall length of stay between groups.
Bhattacharjee et al, ⁹⁰ 2014	N = 90, total abdominal hysterectomy. Intraop: GA + IV fentanyl 0.5 µg/kg prn + IV acetaminophen 1 g. Postop: IV tramadol 2 mg/kg prn for 1st dose then every 8 h IV acetaminophen 1 g every 6 h.	Preinduction bilateral LMG TAP blocks with 0.5 mL/kg 0.25% bupivacaine per side.	Sham TAP blocks with 0.5 mL/kg 0.9% saline per side. Sham TAP blocks with 0.5 mL/kg 0.9% saline per side.	Sig lower pain scores immediately postop in TAP vs control groups at rest (median 0.3 vs 2.7) and on movement (median 0.8 vs 3.5). Sig lower intraop fentanyl use in TAP vs control group (median 81 vs 114 µg). Sig longer time to 1st analgesic use in TAP vs control group (median 290 vs 16 min).
Colorectal surgery		Bilateral LMG TAP with 20 mL 0.375% levobupivacaine per side.	Sig lower rest and dynamic pain scores in TAP vs control group during 1st 24 h. Sig lower morphine use in TAP vs control group at 24 h (mean 21.9 vs 80.4 mg). Sig longer time to 1st morphine use in TAP vs control group (157 vs 24 min).	Pain scores beyond 1 h were not reported. Similar incidence of nausea and vomiting.
McDonnell et al, ⁹¹ 2007	N = 32, open bowel resection. Intraop: GA + IV morphine 0.15 mg/kg + PR diclofenac 1 mg/kg + PR acetaminophen 1 g Postop: IV PCA morphine + PO acetaminophen 1 g every 6 h + PR diclofenac 100 mg every 18 h.	No TAP block.	Sig lower rest and dynamic pain scores in TAP vs control group during 1st 24 h. Sig lower morphine use in TAP vs control group at 24 h (mean 21.9 vs 80.4 mg). Sig longer time to 1st morphine use in TAP vs control group (157 vs 24 min).	Pain scores beyond 1 h were not reported. Similar incidence of nausea and vomiting.

Continued next page

TABLE 2. (Continued)

Study	Standardized Management	Intervention	Comparator	Anesthetic Outcomes	Other Outcomes/Comments
Keller et al, ⁶² 2014	N = 79, laparoscopic colorectal resection. Preop: diclofenac 100 mg + gabapentin 300 mg. Intraop: GA (details unspecified). Postop: IV PCA morphine + gabapentin 300 mg every 12 h + IV ketorolac 15 mg every 6 h + IV/PO acetaminophen 1 g every 6 h.	Bilateral surgical TAP block with 0.5 mL/kg 0.5% bupivacaine at end of surgery (max 30 mL).	Sham TAP blocks with 0.5 mL/kg 0.9% saline.	Sig lower pain scores in TAP vs control group in PACU (mean 2.1 vs 3.8). Sig lower pain scores in TAP vs control group throughout hospital stay. Sig lower hydromorphone use in TAP vs control group in PACU (mean 0.8 vs 1.8 mg). No sig difference between groups in opioid use beyond PACU.	No sig difference in TAP vs control group in hospital length of stay (mean 3.15 vs 2.87 d) or return to normal function (7.8 vs 10.8 d).
Walter et al, ⁹² 2013	N = 68, laparoscopic colorectal resection. Intraop: GA + IV morphine pm Postop: IV PCA morphine + IV acetaminophen 1 g every 6 h.	Preincisional USG lateral TAP blocks with 20 mL 1 mg/kg levobupivacaine (max 75 mg) per side.	No TAP block.	No sig difference in rest and dynamic pain scores between groups at all time points up to 24 h. Sig lower morphine use in TAP vs control group at 24 h (median 40 vs 60 mg).	No sig difference in hospital length of stay between groups.
Park et al, ⁹³ 2015	N = 59, laparoscopic colorectal resection. Intraop: GA + remifentanyl infusion. Postop: IV PCA morphine. No MMA.	Bilateral USG lateral TAP blocks with 20 mL 0.25% ropivacaine per side at end of surgery.	Wound and port site infiltration with 40 mL of 0.25% ropivacaine at end of surgery.	No sig difference in rest and dynamic pain scores between groups up to 48 h. Sig lower morphine use in TAP vs infiltration group at 24 h (16.6 vs 24.0 mg) and 48 h (23.6 vs 31.8 mg).	No sig difference in time to first flatus, first solid intake, first feces between groups. No sig difference in hospital length of stay between groups.
Niraj et al, ⁹⁴ 2014	N = 61, laparoscopic colorectal resection. Intraop: GA + preincisional epidural at T9-T11 with 20 mL 0.25% bupivacaine. Postop: acetaminophen 1 g every 6 h + diclofenac 150 mg every 24 h pm. IV PCA morphine started if therapeutic block failure identified in PACU despite resiting of catheters.	Bilateral USG dual-TAP (four-quadrant) blocks with total of 2.5 mg/kg 0.375% levobupivacaine, followed by insertion of lateral TAP catheters. Postop: TAP bupivacaine + 2 µg/mL fentanyl at 8–12 mL/h and PCA bolus of 2 mL every 30 min.	Preincisional epidural at T9-T11 with 20 mL 0.25% bupivacaine. Postop: epidural infusion of 0.125% bupivacaine + 2 µg/mL fentanyl at 8–12 mL/h and PCA bolus of 2 mL every 30 min.	No sig difference in rest or dynamic pain scores between groups up to 48 h. No sig difference in tramadol use in TAP vs epidural group at 48 h (median 12.5 vs 100 mg).	Catheter resited in 1 (3%) epidural vs 6 (17%) TAP patients. Therapeutic block failure in 4 (13%) epidural vs 2 (7%) TAP patients. Shorter time to removal or urinary catheter in TAP vs epidural group (44 vs 72 h). Sig higher No sig difference in time to get out of bed, to pass flatus, hospital length of stay, between groups.
McDonnell et al, ⁹¹ 2007	N = 32, open bowel resection. Intraop: GA + IV morphine 0.15 mg/kg + PR diclofenac 1 mg/kg + PR acetaminophen 1 g Postop: IV PCA morphine + PO acetaminophen 1 g every 6 h + PR diclofenac 100 mg every 18 h.	Bilateral LMG TAP with 20 mL 0.375% levobupivacaine per side.	No TAP block.	Sig lower rest and dynamic pain scores in TAP vs control group during 1st 24 h. Sig lower morphine use in TAP vs control group at 24 h (mean 21.9 vs 80.4 mg). Sig longer time to 1st morphine use in TAP vs control group (157 vs 24 min).	

Appendectomy

<p>Carney et al,⁹⁵ 2010</p>	<p>N = 40, open pediatric appendectomy. Intraop: GA + IV morphine 0.15 mg/kg + PR diclofenac 1 mg/kg + PR acetaminophen 20 mg/kg. Postop: PCA or nurse-administered IV morphine + PO acetaminophen 20 mg/kg + PR diclofenac 1 mg/kg.</p>	<p>Sham TAP block with 0.9% saline.</p>	<p>Sig lower rest and dynamic pain scores in TAP group vs control group during 1st 48 h. Sig lower morphine use in TAP vs control groups at 6 h time intervals up to 24 h. Sig lower cumulative morphine use in TAP vs control group at 48 h (mean 10.3 vs 22.3 mg). Shorter time to 1st morphine use in TAP vs control group (median 55 vs 16 min). Sig lower rest pain scores in TAP vs control group at 30 min (median 2 vs 5) and 24 h (2 vs 4). Sig lower dynamic pain scores in TAP vs control group at 30 min (median 4.5 vs 8.5) and 24 h (5.2 vs 8). Sig lower morphine use in TAP vs control group (mean 28 vs 50 mg).</p>	<p>No sig difference in incidence of nausea or sedation between groups.</p>
<p>Niraj et al,⁹⁶ 2009</p>	<p>N = 47, open adult appendectomy. Preincisional unilateral Intraop: GA + IV morphine 0.1 mg/kg + IV acetaminophen 1 g. Postop: IV PCA morphine + PO acetaminophen 1 g + PO diclofenac 50 mg.</p>	<p>No TAP blocks.</p>	<p>No TAP blocks.</p>	<p>No sig difference in PACU or hospital length of stay between groups.</p>
<p>Sandeman et al,⁹⁷ 2011</p>	<p>N = 93, laparoscopic pediatric appendectomy. Intraop: GA + IV fentanyl 1 µg/kg + port-site infiltration with 0.5 mL/kg 0.2% 0.2% ropivacaine. Postop: IV PCA morphine + PO acetaminophen 15 mg/kg.</p>	<p>No TAP blocks.</p>	<p>Sig lower pain scores in PACU in TAP vs control group (median 0 vs 2). No sig differences in morphine or other analgesic use between groups at 16 h. No sig difference in time to 1st analgesic use between groups.</p>	<p>No sig difference between groups in nausea, vomiting, length of PACU stay.</p>
<p>Tanggaard et al,⁹⁸ 2015</p>	<p>N = 56, laparoscopic adult appendectomy Intraop: GA + + + IV remifentanyl infusion + IV morphine 0.2 mg/kg + port-site infiltration of 20 mL of 0.25% bupivacaine. Postop: IV PCA morphine + PO acetaminophen 1 g every 6 h + ibuprofen 400 mg prn for shoulder pain.</p>	<p>Sham TAP blocks with 15 mL 0.9% saline per site.</p>	<p>Sig lower pain scores over 1st 12 h in TAP vs control groups at rest (median 2.5 vs 3.1) and on sitting (median 3.4 vs 5.0). No sig difference in morphine use in TAP vs control group (median 10 vs 20 mg).</p>	<p>No sig difference between groups in nausea, vomiting, length of PACU stay.</p>

Continued next page

TABLE 2. (Continued)

Study	Standardized Management	Intervention	Comparator	Anesthetic Outcomes	Other Outcomes/Comments
Inguinal surgery Petersen et al, ⁹⁹ 2013	N = 90, adult open inguinal hernia repair. Intraop: GA (TIVA) + remifentanyl infusion + IV sufentanil 0.2 µg/kg. Postop: IV morphine 2.5–5 mg prn in PACU + PO ketorolamidone 2.5 mg every 1 h prn + PO acetaminophen 1 g every 6 h + ibuprofen 400 mg every 6 h.	Group I: Preincisional unilateral USG lateral TAP block with 25 mL 0.75% ropivacaine + sham ilioinguinal block + sham infiltration.	Group II: Preincisional LMG II-IH block with 10 mL 0.375% ropivacaine + intraop infiltration with 40 mL 0.375% ropivacaine + sham TAP block. Group III: sham TAP block + ilioinguinal block + infiltration.	No sig difference in pain scores over 24 h in TAP (I) vs infiltration (II) vs control (III) groups at rest (mean 2.2 vs 1.9 vs 1.5) and on coughing (4.1 vs 3.7 vs 3.7). Sig higher pain scores over 1st 6 h in TAP group (I) vs infiltration group (II) at rest (mean 2.5 vs 1.0) and on coughing (4.0 vs 1.7). No sig difference in opioid use over 24 h between groups.	
Sahin ¹⁰⁰ 2013	N = 57, pediatric open inguinal hernia repair. Intraop: GA + PR acetaminophen 40 mg/kg. Postop: PO acetaminophen 15 mg/kg prn + IV morphine 0.05 mg/kg prn	Preincisional unilateral USG lateral TAP block with 0.5 mL/kg 0.25% levobupivacaine.	Wound infiltration with 0.2 mL/kg 0.25% levobupivacaine at end of surgery.	Sig lower pain scores in TAP vs infiltration group between 2–16 h but not at 1 h or 20–24 h. Sig lower acetaminophen use in TAP vs infiltration group (mean 19.7 vs 53 mg/kg). Sig longer time to 1st analgesic use in TAP vs infiltration group (mean 17 vs 4.7 h)	
Aveline et al, ¹⁰¹ 2011	N = 273, adult open inguinal hernia repair. Intraop: GA + IV acetaminophen 1 g + IV ketorolamidone 100 mg + IV sufentanil 0.1 µg/kg prn. Postop: IV morphine 3 mg prn in PACU; PO morphine 20 mg every 6 h prn + PO acetaminophen 1 g every 6 h + PO ketorolamidone 150 mg every 12 h.	Preincisional unilateral USG lateral TAP with 1.5 mg/kg 0.5% levobupivacaine.	Preincisional LMG II-IH nerve block with 1.5 mg/kg 0.5% levobupivacaine.	Sig lower rest pain scores in TAP vs control group at 4 h, 12 h, 24 h. No sig difference in rest or dynamic pain scores between groups in PACU, on POD1 and POD2. No sig difference in IV morphine use in PACU between groups (median 0 vs 0 mg). Sig lower PO morphine use in TAP vs control group over 48 h (median 3 vs 4 doses).	No sig difference in chronic pain at 6 mo between groups.
Fredrickson et al, ²⁰ 2010	N = 41, pediatric open inguinal surgery. Preop: PO acetaminophen 30 mg/kg. Intraop: GA + IV fentanyl 0.25 µg/kg every 2 min prn. Postop: IV morphine 0.05 mg/kg or PO ibuprofen in DSU; PO acetaminophen 15 mg/kg prn + PO ibuprofen 10 mg/kg prn.	Preincisional USG lateral TAP block with 0.3 mL/kg of 1:1 mixture of 1% lidocaine + 1% ropivacaine.	Preincisional USG II-IH nerve block with 0.3 mL/kg of 1:1 mixture of 1% lidocaine + 1% ropivacaine.	Sig higher incidence of pain in DSU in TAP vs control group (76% vs 45%). Sig higher pain scores in TAP vs control group in DSU (median 4 vs 0.5). Sig higher rate of ibuprofen use in DSU in TAP vs control group (62% vs 30%). No sig difference in morphine use in DSU in TAP vs control group (24% vs 5%).	No sig difference in post-discharge ibuprofen use, comfort scores, or parental satisfaction between groups.

Open radical retropubic prostatectomy

Elkassabany et al,¹⁰² 2013
 N = 32, ORRP. Preop: PO GA + IV morphine 0.1–0.15 mg/kg + IV ketorolac 30 mg. Postop: IV PCA morphine. No MMA.

Preincisional bilateral USG lateral TAP block with 20 mL 0.5% bupivacaine.

Sham TAP blocks with 0.9% saline.

Sig lower pain scores in TAP vs control group at 1 h (0 vs 6), 2 h (median 3 vs 6), and 6 h (median 3 vs 5). No sig difference in pain scores in TAP vs control group at 24 h (median 4 vs 4). Sig lower morphine use in TAP vs control group at 0–1 h (median 0 vs 3.1 mg), 1–2 h (2 vs 4 mg), and 2–6 h (4 vs 5.1 mg); but not at 6–24 h (median 25 vs 20 mg). Sig lower morphine use in TAP vs control group over 24 h (22.1 vs 45.5 mg)

Skjelsager et al,¹⁰³ 2013
 N = 73, ORRP. Preop: PO acetaminophen 1 g + ibuprofen 600 mg + abapentin 600 mg. Intraop: GA (TIVA) + remifentanyl infusion + IV morphine 0.15 mg/kg. Postop: IV PCA morphine + PO acetaminophen 1 g every 6 h + PO ibuprofen 600 mg every 8 h.

Group I: Bilateral USG lateral TAP block with 20 mL of 0.75% ropivacaine per side at the end of surgery + sham wound infiltration with 0.9% saline.
 Group II: Surgical wound infiltration with 40 mL of 0.75% ropivacaine at the end of surgery + sham TAP block. Group III: sham TAP block + wound infiltration.

No sig difference in rest or dynamic pain scores over 24 h between groups. No sig difference in morphine use over 24 h in TAP vs infiltration vs control group (median 15 vs 15 vs 15 mg)

No sig difference in nausea, vomiting, or sedation between groups.

Plastic/reconstructive abdominal surgery

Zhong et al,⁶³ 2014
 N = 93, abdominal breast reconstruction. Intraop: GA IV fentanyl 1 µg/kg prn. Postop: IV PCA hydromorphone + PO acetaminophen 1 g every 6 h.

Bilateral surgical TAP catheters inserted after abdominal flap harvest. Intermittent bolus of 0.2 mL/kg 0.25% bupivacaine every 8 h starting at the end of surgery until morning of POD3.

Placebo injections of 0.9% saline through catheter.

No sig difference in daily patient-reported rest or dynamic pain scores over 48 h between groups. Sig lower opioid use in TAP vs control group on POD 1 (mean 20.7 vs 30.0 mg IV morphine).

No sig differences in sedation, nausea, vomiting, time to ambulation, or length of stay between groups.

Renal transplantation

Soltani Mohammadi et al,¹⁰⁴ 2014
 N = 44, renal transplant recipients. Intraop: GA + IV fentanyl 1 µg/kg prn. Postop: IV PCA morphine. No MMA.

Preincisional unilateral USG lateral TAP block with 15 mL of 0.25% bupivacaine.

Sham TAP block with 0.9% saline.

Sig lower pain scores in TAP vs control group at all time points from 1 h (median 1 vs to 12 h (median 1 vs 3) up to 24 h (median 1 vs 2). Sig lower morphine use over 24 h in TAP vs control group (mean 10.8 vs 41.2 mg).

Continued next page

TABLE 2. (Continued)

Study	Standardized Management	Intervention	Comparator	Analgesic Outcomes	Other Outcomes/Comments
Freir et al, ¹⁰⁵ 2012	N = 65, renal transplant recipients. Intraop: GA + IV morphine 0.1 mg/kg + IV acetaminophen 1 g. Postop: IV PCA morphine + PO acetaminophen 1 g every 6 h.	Preincisional unilateral LMG TAP block with 20 mL 0.375% levobupivacaine.	Sham TAP block with 0.9% saline.	No sig difference in dynamic pain scores over 24 h between groups. No sig difference in morphine use in TAP vs control group in PACU (mean 4.0 vs 3.1 mg) or over 24 h (mean 31.6 vs 32.6 mg).	Sig higher incidence of nausea in TAP vs control group (53% vs 24%).
Gulyam Kuruba et al, ¹⁰⁶ 2014	N = 54, renal transplant recipients. Intraop: GA = IV morphine 0.1 mg/kg pm + IV acetaminophen 1 g. Postop: IV PCA morphine + IV acetaminophen 1 g every 6 h.	Preincisional unilateral USG lateral TAP block with 20 mL 0.5% levobupivacaine.	Sham TAP block with 0.9% saline.	No sig difference in pain scores at any time points up to 24 h between groups. No sig difference in intraop morphine use in TAP vs control group (mean 1.76 vs 1.76 mg). No sig difference in morphine use at any time point up to 24 h between groups.	No sig difference in nausea, vomiting, or sedation between groups.
Laparoscopic donor nephrectomy					
Hosgood et al, ¹⁰⁷ 2012	N = 46, laparoscopic donor nephrectomy. Intraop: GA (no details of intraop analgesia specified). Postop: IV PCA morphine.	Bilateral US-guided lateral TAP block with 20 mL 0.375% bupivacaine (no other details specified).	Sham TAP block with 0.9% saline.	Sig lower pain scores in TAP vs control group on POD1 (mean 1.9 vs 3.7) and POD (mean 1.1 vs 1.9) but not POD 3 (mean 1.3 vs 1.4). Sig lower morphine use in TAP vs control group at 6 h (mean 12.4 vs 21.2 mg). No sig difference in morphine use in TAP vs control group over total hospital stay (mean 45.6 vs 52.7 mg).	No significant difference in nausea, vomiting, hospital length of stay, or time to 1st fluid intake between groups.
Parikh et al, ¹⁰⁸ 2013	N = 60, laparoscopic donor nephrectomy. Intraop: GA + IM diclofenac 1.5 mg/kg. Postop: IV tramadol 1 mg/kg pm. No MIMA.	Unilateral USG lateral TAP block with 25 mL 0.375% bupivacaine at the end of surgery.	Sham TAP block with 0.9% saline.	Sig lower rest and dynamic pain scores up to 12 h in TAP vs control group, but not beyond. Sig lower tramadol use at 24 h in TAP vs control group (mean 104 vs 236 mg). Sig longer time to 1st analgesic use in TAP vs control group (mean 547 vs 49 min).	No sig difference in nausea or sedation between groups.

Aniskevich et al, ¹⁰⁹ 2014	N = 21, laparoscopic donor nephrectomy, Intraop: GA + IV fentanyl/prn. Postop: IV PCA morphine. No MMA.	Preincisional bilateral LMG TAP with 20 mL 0.5% ropivacaine per side.	Sham TAP blocks with 0.9% saline.	No sig difference in rest or dynamic pain scores between groups up to 12 h. Sig lower pain scores at 24 h in TAP vs control group at rest (median 1 vs 4) and on movement (median 1 vs 5). Sig lower morphine use at 24 h in TAP vs control group (median 26.6 vs 48.7 mg).	No sig difference in nausea, vomiting, or sedation between groups
---------------------------------------	---	---	-----------------------------------	---	---

All pain scores reported on a 0- to 10-point scale.

DSU indicates day surgery unit; GA, general anesthesia; LA, local anesthetic; MMA, multimodal analgesia; PCA, patient-controlled analgesia; postop, postoperative; PR, rectal; PO, oral; POD, postoperative day; prn, as needed; n.s., nonsignificant; TIVA, total IV anesthetic; USG, US-guided.

However, multimodal analgesia was not administered in either study. In addition, Amr and Amin⁸⁵ excluded failed blocks from analysis (6%), and Sivapurapu et al⁸⁶ did not clearly specify the nature of surgery, which limit the conclusions that can be drawn from their results.

There are similarly conflicting data for TAP blocks in laparoscopic total hysterectomy. A small retrospective study found that US-guided lateral TAP blocks significantly reduced length of hospital stay and postoperative opioid consumption.¹¹¹ This was supported by an RCT reporting that US-guided lateral TAP blocks significantly increased quality of recovery scores and reduced 24-hour opioid consumption and pain scores.⁸⁷ However, more recent RCTs utilizing US-guided lateral TAP⁸⁸ and surgically assisted TAP blocks⁸⁹ failed to confirm these results, reporting no significant difference in quality of recovery, opioid consumption, and pain scores.

Taken together, the evidence suggests that while TAP blocks can contribute to postoperative analgesia the benefit is limited to the early postoperative period and is marginal when added to a multimodal regimen of NSAIDs and acetaminophen. One reason for this may be that TAP blocks, particularly the US-guided approach, are primarily effective for somatic pain, whereas major gynecological surgery is associated with a relatively large component of visceral pain.¹¹²

Colorectal surgery

McDonnell et al⁹¹ showed early on that adding preoperative bilateral landmark-guided TAP blocks to a multimodal perioperative analgesic regimen of acetaminophen and NSAIDs significantly reduced pain scores and opioid consumption for up to 48 hours in open colorectal surgery. With regard to laparoscopic colorectal surgery, several retrospective reviews indicate that the addition of TAP blocks (US guided and surgical) to a standard clinical pathway can reduce opioid requirements,^{60,61,113-115} as well as promote earlier return of bowel function and shorten length of hospital stay.^{60,113,115} Three recent RCTs confirm the analgesic efficacy of single-shot surgical⁶² and US-guided lateral TAP blocks^{92,93} in this setting, with reported reductions in pain scores⁶² and opioid consumption,^{92,93} particularly in the early postoperative period. This benefit was seen even in the presence of systemic multimodal analgesia⁶² or when compared with wound infiltration.⁹³ Niraj et al⁹⁴ performed a more complex TAP technique involving postoperative bilateral dual-TAP injections followed by insertion of bilateral US-guided lateral TAP catheters and compared this with a group who received thoracic epidural analgesia. Both groups received multimodal analgesia with NSAIDs and acetaminophen, and they had similar pain scores and opioid consumption; however, duration of urinary catheterization was significantly longer in the thoracic epidural group. None of the RCTs reported a significant difference between groups in time to return of bowel function or hospital discharge.^{62,91-94}

Transversus abdominis plane blocks are therefore worth considering in enhanced recovery pathways for elective laparoscopic colorectal surgery, because they are simple to perform, are associated with few adverse effects, and can reduce opioid consumption, which may potentially facilitate earlier return of bowel function and hospital discharge.

Appendectomy

The TAP block is well suited to open appendectomy because the incision is unilateral and within the T11-T12 dermatomes in the right iliac fossa. Its analgesic efficacy has been demonstrated in both pediatric⁹⁵ and adult⁹⁶ open appendectomy, using landmark-guided TAP and US-guided lateral TAP block approaches, respectively. In both studies, all patients received perioperative

multimodal analgesia with NSAIDs and acetaminophen; nevertheless, the addition of a unilateral TAP block significantly reduced rest and dynamic pain scores, as well as opioid consumption up to 24 hours postoperatively.

The benefit is less clear in laparoscopic appendectomy, where pain is likely to have a larger visceral than somatic component. Bilateral US-guided lateral TAP blocks added to a regimen of intraoperative opioids, local anesthetic infiltration of port sites, and postoperative acetaminophen produced no analgesic benefit in a pediatric population.⁹⁷ In adults, the same intervention produced a modest reduction in pain scores but not postoperative opioid consumption over the first 12 hours.⁹⁸

Inguinal hernia surgery

The TAP block would also seem well suited to open inguinal hernia surgery, but the evidence for benefit is conflicting. Petersen et al⁹⁹ studied 90 adult patients randomized to 1 of 3 groups: US-guided lateral TAP block, II-IH nerve block plus wound infiltration, and placebo. All patients received postoperative multimodal analgesia. Pain scores were low in all groups and not significantly different over 24 hours; however, pain scores over the first 6 hours were lower in the infiltration group compared with both the TAP and placebo groups. There was no significant difference in opioid consumption between the TAP group and the other 2 groups. By contrast, in pediatric inguinal hernia repair, unilateral US-guided lateral TAP block significantly reduced early postoperative pain and 24-hour cumulative analgesic use when compared with wound infiltration.¹⁰⁰

Two other studies have compared US-guided lateral TAP block with II-IH nerve block. In the first, 273 adult patients received either a landmark-guided II-IH nerve block or US-guided lateral TAP block together with perioperative multimodal analgesia.¹⁰¹ Pain scores and opioid consumption were similar between groups in postoperative care unit (PACU), but the TAP group had lower pain scores at 4 to 24 hours and less opioid consumption over the first 2 postoperative days. A second smaller pediatric study²⁰ used a US-guided technique for both TAP and II-IH blocks and found that almost twice as many TAP group patients had pain requiring analgesia in PACU; however, there were no significant differences in postdischarge analgesic use and pain scores.

It therefore appears that while the TAP block can provide effective early postoperative analgesia for open inguinal hernia repair, it does not confer a clinically significant benefit over an analgesic regimen incorporating systemic multimodal analgesia and wound infiltration. The severity of pain beyond 24 hours does not warrant a continuous TAP block technique.¹¹⁶ It is unclear how it compares with an II-IH nerve block, and this may depend on the block failure rate associated with the individual operator and the exact techniques used. Cadaveric and volunteer studies have indicated that the L1 dermatome may not always be blocked by the US-guided lateral TAP block,^{19,117} although this may be overcome to some extent by the use of larger volumes.

Open radical retropubic prostatectomy

A small case series of 12 patients undergoing open radical retropubic prostatectomy (ORRP) suggested that a multimodal analgesic regimen incorporating bilateral landmark-guided TAP blocks was associated with low pain scores and opioid consumption.¹¹⁸ Since then, 2 small RCTs have produced conflicting results. In patients receiving a single dose of intraoperative ketorolac, bilateral US-guided lateral TAP blocks significantly reduced pain scores and opioid consumption in the first 6 postoperative hours (but not beyond) compared with placebo, with an overall reduction in 24-hour opioid consumption.¹⁰² Skjelsager

et al,¹⁰³ on the other hand, compared 3 groups of patients receiving bilateral US-guided lateral TAP blocks, wound infiltration, or placebo and administered a perioperative multimodal analgesic regimen of gabapentin, NSAIDs, and acetaminophen to all patients. There was no difference between groups in pain scores or opioid consumption over the first 24 hours postoperatively. Therefore, while TAP blocks may improve early postoperative analgesia following ORRP, they are of minimal benefit if patients are receiving optimal multimodal analgesia.

Plastic/reconstructive abdominal surgery involving the abdomen

The analgesic efficacy of surgically performed TAP blocks has been investigated in both abdominoplasty and breast reconstruction using abdominal flaps. The evidence in abdominoplasty is derived from small case series and retrospective comparative studies but indicates that TAP blocks reduce early postoperative opioid consumption.⁵⁷ However, they are less effective in larger flap resections, as in postbariatric abdominoplasty.^{119,120}

In a retrospective case-control study of surgical TAP catheters in abdominal flap breast reconstruction, Zhong et al⁵⁸ reported a significant reduction in 48-hour cumulative opioid consumption, but no difference in pain scores. They followed this with an RCT in the same population, in which TAP catheters were retained for 3 days.⁶³ The reduction in opioid consumption, although statistically significant, was less impressive and confined to only the first postoperative day. Once again, there were no differences in pain scores or other secondary outcomes. The evidence therefore does not support the routine use of surgical TAP blocks in reconstructive abdominal surgery at this time.

Renal transplantation

The classic incision for renal transplant recipients extends from pubic symphysis to ASIS in the lower abdominal quadrant and would thus seem to be well suited to coverage by the TAP block. One RCT reported that a US-guided lateral TAP significantly reduced 24-hour opioid consumption and pain scores compared with placebo; however, patients did not receive any co-analgesics.¹⁰⁴ In contrast, 2 other RCTs failed to show a significant impact of landmark-guided¹⁰⁵ or US-guided lateral TAP¹⁰⁶ on 24-hour opioid consumption or pain scores in patients receiving perioperative acetaminophen. Pain scores during the first 24 hours were low in all patients. Routine TAP blocks in this setting therefore appear to offer minimal additional benefit in patients receiving multimodal analgesia.

Laparoscopic donor nephrectomy

Three small RCTs have examined if US-guided lateral TAP blocks provide analgesic benefit in laparoscopic donor nephrectomy. Two of these indicate that both preincisional bilateral¹⁰⁷ and postsurgical unilateral¹⁰⁸ US-guided lateral TAP blocks can reduce early postoperative pain scores and opioid consumption. The third study was unable to demonstrate any analgesic benefits of bilateral preincisional TAP blocks; however, it was underpowered (n = 21), and an unspecified number of patients received a supraumbilical rather than infraumbilical retrieval incision, which is unlikely to have been covered by the TAP block.¹⁰⁹ None of the 3 studies utilized perioperative multimodal analgesia. Based on this limited evidence, TAP blocks may contribute to analgesia in the early postoperative period following laparoscopic donor nephrectomy, but the magnitude of benefit when added to a multimodal analgesic regimen is unclear.

Single-Shot Versus Continuous TAP Block

A major limitation of TAP blocks is the fixed duration of analgesia provided by a single-shot technique. Although pain scores and overall opioid consumption may be reduced in some settings for up to 24 to 48 hours,^{77,91} when block duration is measured by offset of sensory block or time to first request for rescue analgesia, volunteer and clinical studies of both landmark-guided^{77,90,91} and US-guided approaches^{13,28,121,122} indicate that this ranges from 6 to 10 hours on average with bupivacaine or ropivacaine. Although this can be overcome by placement of catheters in the TAP plane, either percutaneously or surgically, there are several issues to be considered.

The first is the question of timing of catheter insertion. Preoperative placement may require technical modification to avoid interference with the surgical field.⁵⁰ Postoperatively, surgical wound dressings and disruption of tissue planes (eg, by surgery, air) can make percutaneous US-guided insertion difficult and contribute to a primary technical failure rate of 20% to 45%.^{52,94} Second, bilateral catheters are needed for incisions crossing the midline, which necessitates the use of either 2 infusion pumps or specialized tubing incorporating a Y-connector. Coverage of both supraumbilical and infraumbilical regions requires insertion and management of 4 separate catheters,⁵⁰ which, although feasible, may be too complex for routine use. Third, there are no data to indicate whether a catheter dosing regimen of intermittent boluses⁵² or continuous infusion^{50,94} is preferable, what the optimal infusion rate is, and to what extent these choices are influenced by the TAP block technique and the type of surgery.

Finally, there is still relatively little evidence for the clinical benefit of continuous TAP blocks. It is unnecessary for surgery where postoperative pain is mild to moderate¹¹⁶ and may confer little additional benefit compared with single-shot TAP blocks,¹²³ given that the latter often have an analgesic effect that outlasts clinically apparent block duration.¹²⁴ Although TAP catheters are a logical alternative to epidural analgesia where this is contraindicated and may provide comparable analgesia,^{50,94} the technical and logistical issues involved would seem to preclude their widespread use.

Pharmacological Considerations for TAP Blocks

Long-acting local anesthetics such as bupivacaine, ropivacaine, and levobupivacaine are most commonly used for TAP blocks. There is wide variability in the doses used clinically in both adults and children, with reported total doses ranging between 2 and 3.5 mg/kg of ropivacaine and 1 and 2.5 mg/kg of bupivacaine.^{125–128} Volume is probably the primary consideration, given that the analgesic efficacy of TAP blocks is based on extent of spread, but there is little advantage in using volumes greater than 15 to 20 mL in adults.^{12,46,64} Local anesthetic concentration should be subsequently selected to ensure that maximum recommended doses^{129,130} are not exceeded. Doses at the high end of the recommended ranges often result in potentially toxic local anesthetic plasma concentrations,^{131–133} and calculations should be based on lean rather than actual body-weight subjects.¹³¹ At the same time, there is evidence that dilute concentrations (eg, 0.2%–0.25% ropivacaine) may be used without compromising efficacy.^{87,134,135} On balance therefore, reasonable dose and volume recommendations in adults would be 15 to 20 mL of 0.25% to 0.375% ropivacaine or 15 to 20 mL of 0.25% bupivacaine or levobupivacaine per side, with added epinephrine to reduce peak plasma concentrations.^{121,136} There are unfortunately much fewer pharmacokinetic and clinical data to guide dosing in children,¹²⁶ and this is additionally confounded by the variation in size and age. A recent small RCT showed that a higher

dose (2.5 vs 1.25 mg/kg of bupivacaine) was associated with a longer duration of analgesia.¹²⁷ One suggested approach is to start with a weight-based mass of drug within maximum recommended limits and to calculate volume and concentration accordingly.

Two small RCTs have looked at the effect of adding dexamethasone¹³⁷ and dexmedetomidine¹³⁸ to the local anesthetic mixture when performing TAP blocks for abdominal hysterectomy. Both studies noted an increased time to first analgesic request (by 2–3 hours on average) and lower opioid consumption in the group that received the adjuvant drug compared with control subjects. Although these early results look promising, further research is needed before the use of these adjuvants to increase duration and quality of analgesia can be recommended. In contrast, the addition of clonidine to TAP blocks did not significantly affect acute postoperative analgesia or wound hyperalgesia in patients undergoing cesarean delivery.¹³⁹

Research has also begun into the use of liposomal bupivacaine in TAP blocks, which may offer a potential solution to the problem of limited analgesic duration with single-shot TAP blocks while retaining the simplicity of the technique. Early observational data support the efficacy of liposomal bupivacaine injected into the TAP,^{140,141} and a recent RCT of subcostal TAP block in robotic-assisted hysterectomy reported a significant difference in pain scores and opioid consumption over the first 48 hours in patients who received liposomal bupivacaine compared with plain bupivacaine.¹⁴²

II-IH NERVE BLOCK

Landmark-Guided Technique

Several different surface landmark-guided techniques have been described,^{21,143–147} all of which are based on needle insertion at a prespecified distance medial and inferior to the ASIS, with an end point of either 1 or 2 tactile fascial pops. Unfortunately, the course and location of the II and IH nerves with regard to the ASIS vary significantly with age and between individuals.^{14,15,148} Cadaveric investigations in neonates have shown that the commonly used techniques are relatively inaccurate in pinpointing the II-IH nerves¹⁴⁹ and that the nerves lie much closer to the ASIS (3 mm on average; 95% confidence interval, 2.8–3.2 mm)¹⁶ than assumed.

The other major consideration is how to identify the correct tissue plane in which to inject. Posterior to the ASIS, the II and IH nerves lie in the TAP, although they often enter only the TAP close to the ASIS. Inferomedial to the ASIS, they ascend to pierce the IOM and lie in the plane between IOM and the EOM aponeurosis (Fig. 3). Most surface landmark-guided techniques recommend injecting in this latter plane, as signified by the single fascial pop of penetration of the EOM aponeurosis. However, the subtlety of this tactile end point^{150,151} combined with the thin muscular layers in children often leads to injection in the wrong layer. Weintraud et al¹⁵⁰ sonographically evaluated the site of injection in children receiving a single-pop landmark-guided II-IH block and noted that only 14% were in the TAP. Of the rest, the injections were most often intramuscular in TAM or IOM and occasionally too deep (in iliocostalis muscle) or superficial (in EOM or the subcutaneous layer). Almost half of these blocks were ultimately unsuccessful.

Seeking 2 fascial pops and performing dual injection into both the TAP and the plane above have been advocated as a means of addressing the anatomical variation in the course of II and IH nerves. The dual-injection approach produced similar block success rates (approximately 78%) regardless of whether the injection was performed 1 cm inferomedial, 1 to 2 cm medial, or 2 cm medial to the ASIS in a pediatric population 2 to 12 years old.¹⁵²

However, seeking a second fascial pop may increase the risk of excessively deep needle insertion and injection. Intraperitoneal injection leads to block failure and risks bowel perforation^{153,154} and vascular injury.¹⁵⁵ Injection deep to TAM can also lead to local anesthetic tracking inferiorly under the fascia iliaca (which is continuous with the transversalis fascia) and thus causing femoral nerve blockade.³

Given the anatomical considerations outlined previously, it is perhaps unsurprising that the failure rate of landmark-guided II-IH blockade is as high as 20% to 40%, even in experienced hands,^{21,22,152} and it is difficult to recommend 1 particular technique over any of the others. The most prudent approach would seem to be to insert the needle slightly medial (3–10 mm depending on age) and inferior to the ASIS, through the EOM aponeurosis (single pop), and to inject a relatively large volume to ensure spread to the II and IH nerves.

US-Guided Technique

There are 2 locations at which the II and IH nerves may be visualized and targeted on US (Fig. 2). The first is with the transducer placed medial to the ASIS and oriented along the spinoumbilical line (between umbilicus and ASIS).¹⁵⁶ In this position, the EOM has usually transitioned into its aponeurosis, and thus only 2 muscle layers are visible: IOM and TAM. Here, the nerves either may lie in the TAP or may have already pierced IOM to lie superficial to it. The second and preferred approach is to place the transducer superior and posterior to the ASIS.^{34,35} Here, all 3 abdominal wall muscle layers are visualized, and both nerves consistently lie in the TAP close to the iliac crest. The ascending branch of the deep circumflex artery and subcostal nerve also lies in the TAP but in a more medial location. It is relatively easy to learn to identify the ASIS and muscle layers (learning curve <20 scans¹⁵⁷), but identification of the nerves is more challenging. However, if they cannot be visualized, it is usually sufficient just to inject 0.1 to 0.2 mL/kg of local anesthetic into the TAP immediately medial to the ASIS (Fig. 2).

US-Guided Versus Landmark-Guided II-IH Block

The US-guided approach is recommended over the landmark-guided approach wherever possible.¹⁵⁸ Its primary advantage is the ability to clearly visualize the abdominal wall layers (and often the nerves) and thus to deposit local anesthetic in the appropriate plane. This translates into superior efficacy and safety, as well as a reduction in the local anesthetic volume required (Table 3).¹⁵⁶ A dose-finding study has shown that administering as little as 0.075 mL/kg of 0.25% levobupivacaine in a US-guided II-IH block can provide analgesia for at least 4 hours postoperatively following inguinal surgery.¹⁶⁵ The safety advantage of smaller volumes is particularly relevant as significantly higher plasma ropivacaine concentrations were reported with the US-guided versus landmark-guided approach following the same dose of ropivacaine.²² This may be related to proximity to the deep circumflex iliac vessels and more extensive spread when local anesthetic is injected precisely into the TAP versus injected intramuscularly.

Clinical Efficacy of the II-IH Block

The II-IH nerve block is a well-established regional anesthetic technique for inguinal surgery, for example, inguinal herniorrhaphy, herniotomy, and orchidopexy. It is, however, a somatic block and will not therefore cover visceral pain, for example, from the spermatic cord. Pain in the territory of the genitofemoral nerve may also impair the apparent success of the block. Anatomical variation in the course of II and IH nerves and the multitude of

landmark-guided approaches to the II-IH block further contribute to variability in reported block success rates. Despite this, landmark-guided II-IH blockade has been shown to be as effective as caudal analgesia in pediatric inguinal surgery^{159–161} and avoids many of the complications associated with the latter technique (urinary retention, motor block, hypotension) (Table 3). On the other hand, it does not offer additional analgesic benefit over surgical wound infiltration in herniotomy surgery.^{162,163}

There are fewer data on the US-guided II-IH block, but Fredrickson et al²⁰ have shown that it is superior to the US-guided lateral TAP block in pediatric inguinal surgery. In the setting of adult inguinal hernia repair, the addition of a US-guided II-IH block to an analgesic regimen of intraoperative morphine and wound infiltration resulted in superior analgesia in the early postoperative period.¹⁶⁴

RECTUS SHEATH BLOCK

Landmark-Guided Rectus Sheath Block

In the landmark-guided rectus sheath block, bilateral injections are performed medial to the linea semilunaris and just superior to the umbilicus. Following skin puncture, a tactile pop signals penetration of the anterior rectus sheath, and the needle is advanced through the RAM until its tip lies just superficial to the posterior rectus sheath, where 0.2 to 0.3 mL/kg of local anesthetic is injected. The original descriptions^{166,167} recommend seeking a “scratching” sensation by a back-and-forth motion of the needle as it is advanced, to confirm contact with the dense anterior and posterior layers of the rectus sheath. Note that a discrete fascial layer exists within the subcutaneous tissue¹⁶⁸ and may be mistaken for the anterior rectus sheath, particularly in obese adults.¹⁶⁹

A “4-quadrant” injection approach has also been described,¹⁷⁰ in which bilateral injections are performed superior to the umbilicus, as well as inferior to it. Although this may theoretically improve the longitudinal spread of local anesthetic, there are currently no data to indicate if it provides superior analgesia. Blind injection inferior to the arcuate line (approximately one-third to halfway between the umbilicus and pubic crest) should be avoided because the posterior rectus sheath is absent here (Fig. 4), and the risk of inadvertent peritoneal puncture is consequently increased.

In yet another variation, the paraumbilical block, a subcutaneous injection is made on each side in addition to injection within the rectus sheath.¹⁷¹ The aim is to anesthetize aberrant branches of the anterior cutaneous nerves that do not pass through the rectus sheath but instead pierce the rectus muscle directly or run superficial to the sheath. Once again, there are few clinical data on the efficacy of this approach.

US-Guided Rectus Sheath Block

In the US-guided rectus sheath block, the transducer is placed in a transverse orientation just superior to the umbilicus to visualize the linea alba and paired recti abdominis muscles and then slid laterally to visualize the lateral aspect of the rectus sheath and RAM (Fig. 4). The needle tip is placed between the hypoechoic RAM and the hyperechoic posterior rectus sheath^{36,37}; injection in the correct plane will create a visible pool of local anesthetic separating the RAM from the rectus sheath (Fig. 10). The superior and inferior epigastric arteries may be visible as hypoechoic pulsatile structures deep in the RAM¹⁷² and should be avoided. The recommended injection volume is 0.1 to 0.2 mL/kg (15–20 mL in adults) per side.^{36,37,173} Local anesthetic concentration should be adjusted as necessary to avoid exceeding maximum recommended doses.

TABLE 3. Summary of RCTs on II-IH Nerve Blockade

Study	Standardized Management	Intervention	Comparator	Analgesic Outcomes	Other Outcomes
US-guided vs landmark-guided II-IH block Willschke et al, ¹⁵⁶ 2005	N = 100, pediatric open inguinal surgery. Intraop: GA + IV fentanyl 3 µg/kg pm. Postop: PR acetaminophen 40 mg/kg pm.	Preincisional unilateral USG II-IH block with 0.25% levobupivacaine “until both nerves were surrounded” by LA.	Preincisional unilateral LMG II-IH block (single “pop”) with 0.3 mL/kg 0.25% levobupivacaine.	Sig lower rate of intraop fentanyl use in USG vs LMG group (4% vs 26%). Sig lower rate of postop acetaminophen use in USG vs LMG group (6% vs 40%).	Sig lower vol of LA used in USG vs LMG group (mean 0.19 vs 0.3 mL/kg).
Weintraud et al, ²² 2009	N = 66, pediatric open inguinal surgery. Intraop: GA + IV fentanyl 1 µg/kg pm. Postop: no details given.	Preincisional unilateral USG II-IH block with 0.25 mL/kg 0.5% ropivacaine.	Preincisional unilateral LMG II-IH block (single “pop”) with 0.25 mL/kg 0.5% ropivacaine.	Sig lower rate of intraop fentanyl use in USG vs LMG group (6% vs 26%).	Sig faster resorption and higher plasma concentrations of LA in USG vs LMG group.
II-IH versus other regional anesthetic techniques Markham et al, ¹⁵⁹ 1986	N = 52, pediatric open inguinal surgery. Intraop: GA. No analgesics given. Postop: IM diamorphine 0.1 mg/kg pm.	Preincisional LMG II-IH block with 0.5 mL/yr (age) 0.5% bupivacaine.	Preincisional caudal block with 1 mL/yr (age) 0.5% bupivacaine.	No sig difference in intraop respiratory or hemodynamic parameters between groups. No sig difference in pain scores, postop analgesic use between groups.	Sig lower incidence of urinary retention at 6 h in II-IH vs caudal group (19% vs 46%).
Hannallah et al, ¹⁶⁰ 1987	N = 44, pediatric orchidopexy. Intraop: GA. No analgesics given. Postop: IV fentanyl 1–2 µg/pm	Group I: LMG II-IH block with 4–6 mL 0.25% bupivacaine at the end of surgery.	Group II: Caudal block with 2.5 mL/yr (age) 0.25% bupivacaine at the end of surgery. Group III: no blocks.	No sig difference in pain scores in II-IH vs caudal group (median 1 vs 1).	
Cross and Barrett, ¹⁶¹ 1987	N = 41, pediatric herniotomy and orchidopexy. Intraop: GA. No analgesics given. Postop: no details specified.	Preincisional LMG II-IH block + + + skin infiltration with 2 mL/kg 0.25% bupivacaine (max 20 mL unilateral and 40 mL bilateral block).	Preincisional caudal block with 1.0 mL/kg (herniotomy) or 1.25 mL/kg (orchidopexy) 0.25% bupivacaine.	No sig difference in pain scores in II-IH vs caudal groups at 1 h (mean 0.5 vs 0.3), 3 h (mean 0.6 vs 0.6), 6 h (mean 0.9 vs 0.6) or 18 h (mean 1.5 vs 1.2) No sig difference in postop analgesics required between groups.	No sig difference in vomiting, time to 1st micturition between groups.
Reid et al, ¹⁶² 1987	N = 49, pediatric herniotomy. Intraop: GA. No analgesics given. Postop: no details specified.	Preincisional LMG II-IH block (single “pop”) with 0.5 mg/kg 0.25% bupivacaine.	Wound infiltration with 0.5 mg/kg 0.25% bupivacaine at end of surgery.	No sig difference in intraop respiratory and hemodynamic parameters between groups. No sig difference in pain between groups up to 2 h postop. No sig difference in incidence of post-discharge pain reported by II-IH vs infiltration group (33% vs 19%).	No sig difference in mood, vomiting, sleep quality between groups.
Trotter et al, ¹⁶³ 1995	N = 53, pediatric inguinal surgery. Intraop: GA. No analgesics given. Postop: PO acetaminophen 15 mg/kg pm.	Preincisional LMG II-IH block (single “pop”) with 0.5 mL/kg 0.25% bupivacaine.	Wound infiltration with 0.5 mL/kg 0.25% bupivacaine at end of surgery.	No sig difference in pain scores between groups. No sig difference in postop analgesic use between groups.	

Continued next page

TABLE 3. (Continued)

Study	Standardized Management	Intervention	Comparator	Analgesic Outcomes	Other Outcomes
Fredrickson et al, ²⁰ 2010	N = 41, pediatric open inguinal surgery. Preop: PO acetaminophen 30 mg/kg. Intraop: GA + IV fentanyl 0.25 µg/kg every 2 min prn. Postop: IV morphine 0.05 mg/kg or PO ibuprofen in DSU; PO acetaminophen 15 mg/kg prn + PO ibuprofen 10 mg/kg prn.	Preincisional USG II-IH block with 0.3 mL/kg of 1:1 mixture of 1% lidocaine + 1% ropivacaine.	Preincisional USG lateral TAP block with 0.3 mL/kg of 1:1 mixture of 1% lidocaine + 1% ropivacaine.	Sig lower incidence of pain in DSU in II-IH vs TAP group (45% vs 76%). Sig lower pain scores in II-IH vs TAP group in DSU (median 0.5 vs 4). Sig lower rate of ibuprofen use in DSU in II-IH vs TAP group (30% vs 62%). No sig difference in morphine use in DSU in II-IH vs TAP group (5% vs 24%).	No sig difference in post-discharge ibuprofen use, comfort scores, or parental satisfaction between groups.
Aveline et al, ¹⁰¹ 2011	N = 273, adult open inguinal hernia repair. Intraop: GA + IV acetaminophen 1 g + IV ketoprofen 100 mg + IV sufentanil 0.1 µg/kg prn. Postop: IV morphine 3 mg prn in PACU; PO morphine 20 mg every 6 h prn + PO acetaminophen 1 g every 6 h + PO ketoprofen 150 mg every 12 h.	Preincisional LMG II-IH nerve block with 1.5 mg/kg 0.5% levobupivacaine.	Preincisional unilateral USG lateral TAP with 1.5 mg/kg 0.5% levobupivacaine.	Sig higher rest pain scores in II-IH vs TAP group at 4 h, 12 h, 24 h. No sig difference in rest or dynamic pain scores between groups in PACU, on POD1 and POD2. No sig difference in IV morphine use in PACU between groups (median 0 vs 0 mg). Sig higher PO morphine use in II-IH vs TAP group over 48 h (median 4 vs 3 doses).	No sig difference in chronic pain at 6 mo between groups.
Berentzen et al, ¹⁶⁴ 2012	N = 74, adult open inguinal hernia repair. Intraop: GA (TIVA) + remifentanyl infusion + IV morphine 0.2 mg/kg + wound infiltration with 15 mL 0.25% bupivacaine. Postop: IV morphine 2.5 mg prn in PACU; PO morphine 5 mg prn.	Preincisional USG II-IH block with 20 mL 0.5% bupivacaine.	Sham II-IH block with 0.9% saline.	Sig lower rest and dynamic pain scores in II-IH vs control group up to time of PACU discharge. No sig difference in pain scores on POD1 and POD2 between groups. No sig difference in opioid use on POD0 or POD1.	No sig difference in length of PACU stay, nausea and vomiting, and return to activities of daily living on POD1 and POD2.

All pain scores reported on a 0- to 10-point scale.

DSU indicates day surgery unit; GA, general anesthesia; intraop, intraoperative; LMA, local anesthetic; MMA, multimodal analgesia; PCA, patient-controlled analgesia; postop, postoperative; PR, rectal; PO, oral; POD, postoperative day; prn, as needed; n.s., nonsignificant; TIVA, total IV anesthetic; USG, US-guided.

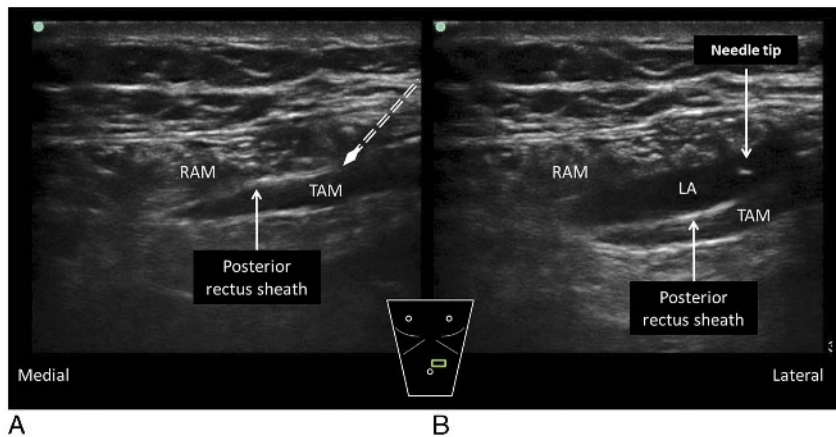


FIGURE 10. Ultrasound-guided rectus sheath block. A, Preinjection image. The probe is placed in a transverse orientation superior to the umbilicus to visualize the lateral aspect of the RAM and rectus sheath. The needle is inserted deep to the lateral edge of RAM but does not penetrate the posterior rectus sheath. B, Postinjection image. Injection here creates a pocket of LA between the RAM and the posterior rectus sheath. LA indicates local anesthetic. Reproduced with permission from KJ Chin Medicine Professional Corporation.

US-Guided Versus Landmark-Guided Rectus Sheath Block

As with II-IH nerve blockade, the chief advantage of the US-guided rectus sheath block is the ability to visualize the abdominal wall layers and appropriate plane for injection. Ultrasound significantly improved the precision of local anesthetic deposition into the rectus sheath by novices compared with the landmark-guided technique¹⁶⁹; however, the study (in an adult population undergoing laparoscopic surgery) did not report whether this resulted in superior analgesic efficacy. Ultrasound may also permit local anesthetic dose reduction; Willschke et al³⁶ were able to provide highly effective intraoperative and postoperative (up to 4 hours) analgesia for pediatric umbilical hernia repair with 0.1 mL/kg of 0.25% levobupivacaine, instead of the 0.2 mL/kg usually recommended in the landmark-guided technique.¹⁶⁷

Surgical Rectus Sheath Block

Local anesthetic may be directly administered into the rectus sheath by the surgeon before wound closure, either as a single injection¹⁷⁴ or through a catheter.^{175,176} Touted advantages include ease of performance, the lack of need for specialized anesthetic equipment and expertise, reduction in operating room times, accuracy, and improved congruency with the incision site.

Clinical Efficacy of the Rectus Sheath Block

The rectus sheath block has been used to provide somatic analgesia for midline incisions in a range of laparoscopic and open surgeries. It has been widely studied in umbilical hernia repair where data from case series indicate that it provides effective analgesia^{36,167,177} and may even be used for primary surgical anesthesia^{178–180} in selected adult patients. However, it is controversial as to whether it offers significant analgesic benefit over simple surgical wound infiltration.^{181,182} The chief advantage of the rectus sheath block is that it can be performed before incision and thus reduce the need for intraoperative opioids.¹⁸³ However, with regard to postoperative pain scores and opioid requirements, 1 small pilot study (n = 13) showed no difference,¹⁸⁴ whereas 3 other RCTs^{173,183,185} reported only a modest reduction with single-shot rectus sheath block versus wound infiltration (Table 4). It should also be noted that none of the studies used an optimal multimodal analgesic regimen.

Similarly, while single-shot rectus sheath blockade can provide somatic analgesia for midline incisions associated with laparoscopic surgery^{166,186,187,189} (Table 4), it is unclear if it confers a clinically significant benefit over wound infiltration and systemic multimodal analgesia.

Rectus sheath block has been proposed as a useful technique in neonates undergoing pyloromyotomy.^{190,191} It provides similar postoperative analgesia compared with surgical wound infiltration,¹⁹² but more importantly, if administered prior to surgical incision, it allows sparing of intraoperative opioid and volatile anesthetic. This in turn minimizes the concerns of postoperative apnea and adverse effects on neurological development, respectively.

The greatest potential benefit may lie in continuous rectus sheath blockade following major laparotomy surgery; however, it is currently supported only by case reports and series.^{193–195} One small RCT has been published to date that showed no difference in opioid consumption or pain scores over a 48-hour period between patients receiving intermittent boluses of either bupivacaine or saline through bilateral, surgically inserted rectus sheath catheters following midline laparotomy.¹⁸⁸ In contrast, 2 recent retrospective reviews of patients undergoing open colorectal surgery indicate that rectus sheath catheters may be as effective as epidural analgesia while offering a superior side-effect profile.^{196,197} A prospective RCT is in progress that may shed further light on the issue.¹⁹⁸

NEWER ABDOMINAL WALL BLOCKS

US-Guided Quadratus Lumborum Block

The US-guided QL block represents both the continued evolution of the US-guided TAP block and a return to the original intent of the landmark-guided TAP block approach. The promise of more extensive abdominal analgesia compared with the TAP block⁴⁹ accounts for the growing interest in this block. The QL block uses the QLM as its principal sonographic landmark. This muscle, along with the tough thoracolumbar fascia that envelops it, can be thought of as an anatomical bridge between the anterolateral musculature of the abdominal wall (EOM, IOM, TAM) and the lumbar paravertebral region (Fig. 6). It is easily imaged in most patients by placing a curvilinear transducer in a transverse orientation just above the iliac crest in the posterior axillary line. There are several descriptions regarding the ideal point of injection relative to the QLM, and this has led to some uncertainty

TABLE 4. Summary of RCTs on Rectus Sheath Block

Study	Standardized Management	Intervention	Comparator	Analgesic Outcomes	Other Outcomes
Isaac et al, ¹⁸⁴ 2006	Rectus sheath block versus other regional anesthetic techniques N = 13. Intraop: GA. No analgesics given. Postop: IV morphine 0.05 mg/kg prn.	Bilateral LMG rectus sheath block with 0.4 mL/kg 0.25% bupivacaine per side at end of surgery.	Wound infiltration with 0.8 mL/kg 0.25% bupivacaine at end of surgery.	No sig difference in pain scores between groups. No sig difference in morphine use in rectus sheath vs infiltration group (mean 0.1 vs 0.1 mg/kg).	No sig difference in anti-emetic use between groups. Sig higher peak plasma bupivacaine concentration in rectus sheath vs infiltration group.
Flack et al, 2014 ¹⁷³	N = 40, pediatric open umbilical hernia repair. Intraop: GA + IV fentanyl 1 µg/kg prn. Postop: IV morphine 30 µg/kg prn.	Preincisional bilateral USG rectus sheath block with 0.2 mL/kg 0.25% bupivacaine per side.	Preincisional IV fentanyl 2 µg/kg + wound infiltration with 0.4 mL/kg 0.25% bupivacaine at end of surgery.	No sig difference in max pain scores between groups. No intraop rescue analgesia required in either group. Sig lower morphine use in rectus sheath vs infiltration group (median 26.4 vs 58.5 µg/kg).	No sig difference in nausea or vomiting between groups.
Gumaney et al, ¹⁸³ 2011	N = 52, pediatric open umbilical hernia repair. Preop: PO acetaminophen 15 mg/kg. Intraop: GA + IV morphine 0.05 mg/kg prn. Postop: IV morphine 0.05 mg/kg prn or PO oxycodone 0.1 mg/kg.	Preincisional bilateral USG rectus sheath block with 0.25 mL/kg 0.25% bupivacaine per side.	Wound infiltration with 0.25 mL/kg 0.25% bupivacaine at end of surgery.	No sig difference in rest or dynamic pain scores between groups. Sig lower intraop morphine use in rectus sheath vs infiltration group (12% vs 54%). No sig difference in postop opioid use in rectus sheath vs infiltration group (mean 0.07 vs 0.1 mg/kg). Sig lower total opioid use in rectus sheath vs infiltration group (mean 0.07 mg/kg vs 0.13 mg/kg morphine).	No sig difference in nausea or vomiting between groups.
Dingeman et al, ¹⁸⁵ 2013	N = 52, pediatric open umbilical hernia repair. Intraop: GA + IV fentanyl 1 µg/kg + IV ketorolac 0.5 mg/kg. Postop: PO acetaminophen 12.5 mg/kg prn or IV morphine 0.05 mg/kg prn or PO codeine 1 mg/kg.	Bilateral USG rectus sheath block with 0.5 mL/kg 0.2% ropivacaine per side at the end of surgery.	Wound infiltration with 0.5 mL/kg 0.2% ropivacaine at end of surgery.	Sig lower pain scores in rectus sheath vs infiltration group in PACU. Sig more patients were pain-free in PACU in rectus sheath vs infiltration group. No sig differences in pain scores over 1st 24 h after discharge between groups. No sig difference in analgesic use in PACU or at home between groups.	No sig difference in length of PACU stay between groups.
Smith et al, ¹⁶⁶ 1988	N = 46, diagnostic gynecological laparoscopy. Intraop: GA. No analgesics given. Postop: IM papaveretum 0.3 mg/kg every 4 h prn.	Preincisional bilateral LMG rectus sheath block with 0.25 mL/kg 0.25% bupivacaine per side.	No rectus sheath block.	Sig lower pain scores in rectus sheath vs control group at 1 h (mean 7.1 vs 0.7), 6 h (mean 0.4 vs 4.3), 10 h (mean 1.6 vs 3.2). Sig lower need for postop rescue analgesia in rectus sheath vs control group at all time points up to 10 h.	

Azemati and Khosravi, ¹⁸⁶ 2005	N = 9, diagnostic gynecological laparoscopy. Intraop: GA. No analgesics given. Postop: No details on analgesia given.	Group I: Bilateral LMG rectus sheath block with 10 mL 0.25% bupivacaine per side at the end of surgery.	Group II: Intraabdominal instillation of 20 mL 0.125% bupivacaine in right subdiaphragmatic area at end of surgery. Group III: Wound infiltration with 10 mL 0.25% bupivacaine at end of surgery.	Sig lower pain scores in rectus sheath group vs both groups II and III at 6 h (median 3 vs 7 vs 6) and 10 h (2 vs 5 vs 3). No sig difference in pain scores at 24 h between groups.
Hamill et al, ¹⁸⁷ 2015	N = 130, pediatric laparoscopic appendectomy. Intraop: GA + IV morphine 0.3 mg/kg pm + IV fentanyl 2 µg/kg pm, acetaminophen 15 mg/kg + wound infiltration with 10 mL 0.25% bupivacaine. Postop: Opioids pm + "regular" acetaminophen + NSAIDs.	Preincisional bilateral USG rectus sheath block with ≤ 2.5 mg/kg 0.25% bupivacaine (max vol 20 mL).	No rectus sheath block.	Sig lower pain scores in rectus sheath vs control group in 1st 3 h (mean 2.1 vs 3.9) but no sig difference thereafter. No sig difference in analgesic use between groups. Sig shorter time to PACU discharge in rectus sheath group. No sig difference in length of hospital stay, quality of life score or satisfaction between groups.
Padmanabhan et al, ¹⁸⁸ 2007	N = 40, adult midline laparotomy. GA: + IV morphine (dose not specified). Postop: IV PCA morphine. No MMA.	Surgical insertion of rectus sheath catheter before wound closure, with bolus 20 mL 0.25% bupivacaine every 8 h for 48 h.	Placebo bolus injections of 0.9% saline.	No sig difference in mean pain score in rectus sheath vs control group on POD 1 (mean 2.24 vs 1.89) or POD 2 (2.22 vs 1.85). No sig difference in morphine use in rectus sheath vs control group in 0–24 h (mean 19.4 mg vs 21.4 mg) or in 24–48 h (30.5 vs 25.3 mg). Similar reductions in postoperative peak expiratory flow rate between groups.

All pain scores reported on a 0- to 10-point scale.

DSU indicates day surgery unit; GA, general anesthesia; intraop, intraoperative; L/A, local anesthetic; MMA, multimodal analgesia; PCA, patient-controlled analgesia; postop, postoperative; PR, rectal; PO, oral; POD, postoperative day; pm, as needed; n.s., nonsignificant; TIVA, total IV anesthetic; USG, US-guided.

about the manner by which the block exerts its effect as well as block nomenclature.

The QL block was first described in abstract form as a “no-pops” TAP block.¹⁹⁹ While this report lacked a detailed description of the technique, a subsequent letter by Blanco and McDonnell³⁸ provided clarification on the end point for needle advancement and outlined 2 separate versions of the QL block. The QL1 block was defined as an injection of local anesthetic adjacent to the lateral aspect of the QLM, immediately lateral to the tapered end of the TAM (Fig. 11). The needle is advanced in-plane in a lateral-to-medial direction to reach the plane between the IOM and TAM aponeurosis and the transversalis fascia. Injection here should result in visible spread along the anterior (ventral) surface of QLM, and some authors have described modifications that deliberately advance the needle tip into this location.^{39,200} In contrast, the QL2 block is an injection on the posterior (dorsal) surface of QLM, in the plane between QL and the investing layer of thoracolumbar fascia that separates it

from the overlying latissimus dorsi or paraspinal muscles (Fig. 11). The needle approach is similar to the QL1, advancing in a lateral-to-medial direction through the oblique muscles with a shallower trajectory. Injectate administered at this point should be observed pooling along the posterior aspect of the QLM.

A third approach was described by Børglum et al,⁴⁰ in which the QLM is identified where it borders the psoas major and attaches to the transverse process of the L4 vertebra. The needle is inserted in a posterior-to-anterior direction through the QLM until the tip reaches the plane between the anterior surface of QLM and psoas major (Fig. 11). The authors termed this the *transmuscular QL block*, but it has also been termed the QL3 block.²⁰¹

The pattern of injectate spread with QL blocks appears distinct from those achieved following US-guided lateral or subcostal TAP blocks. Carney et al⁴⁶ demonstrated in a small volunteer magnetic resonance imaging study that the QL1 block (which they called a *posterior TAP block*) resulted in pooling of contrast between the transversalis fascia, the QLM, and the psoas major, but noted a complete absence of spread to the TAP. Moreover, all subjects had some degree of thoracic paravertebral spread to at least the T10-T11 level and as high as T4-T5 in some cases. The transversalis fascia investing the QLM is continuous with the endothoracic fascia in the thorax,²⁰² and it is suggested that this is the pathway for cranial extension of local anesthetic spread to the thoracic paravertebral space. This is at present the primary mechanism of action proposed for the QL block, but further anatomical and imaging studies are needed to confirm this, as well as whether the different QL block approaches result in similar patterns of spread.

The literature on QL blocks is still sparse. The early descriptions exist primarily as conference abstracts and e-letters, and most of our knowledge comes from case reports.^{39,200,203–206} Blanco et al²⁰⁷ recently published the first RCT of the QL2 block and demonstrated that when added to a multimodal analgesic regimen of acetaminophen and NSAIDs (but no intrathecal morphine) in patients undergoing elective cesarean delivery it reduced opioid requirements and pain scores in the first 24 to 48 hours. In another study, Murouchi et al⁴⁹ compared a prospective cohort of 11 patients undergoing laparoscopic gynecologic surgery who received bilateral QL2 blocks to a historical cohort of patients who received bilateral TAP blocks. Those in the QL group had a significantly prolonged time to first request for rescue analgesia, with 8 of 11 subjects requiring no rescue analgesia in the first 24 hours. All of the subjects in the QL group had a sensory level from T8 to L1 (extending to T7 in just over half of subjects) compared with a sensory level of only T10 to L1 in the TAP group. This extensive cutaneous sensory block is consistent with case reports published to date.^{39,200,203,206} Promising results with continuous catheter techniques have also been reported for both children and adults.^{39,200,204,206} These early data are encouraging for the efficacy of the QL block, and further investigation is warranted.

Interestingly, the QL block may turn out to have utility beyond truncal analgesia. Because the transversalis fascia overlying the QLM extends caudally over psoas major and iliacus muscle, local anesthetic can spread to the lumbar plexus as well, and this has been confirmed in recent cadaveric studies.^{208,209} The efficacy of the QL block in hip surgery is supported by case reports^{210,211} and an RCT showing that patients who received a QL1 block for hip fracture surgery had better analgesia in the first 24 hours postoperatively compared with a low-volume US-guided femoral nerve block.²¹² This is also consistent with reports of cutaneous sensory block over the thigh with the landmark-guided TAP block⁴⁶ and the L2 dermatome with the QL block.²⁰⁰ At the same time, this means that practitioners must be aware of the potential risk for unanticipated quadriceps weakness and fall injury when performing QL blocks for abdominal surgery.

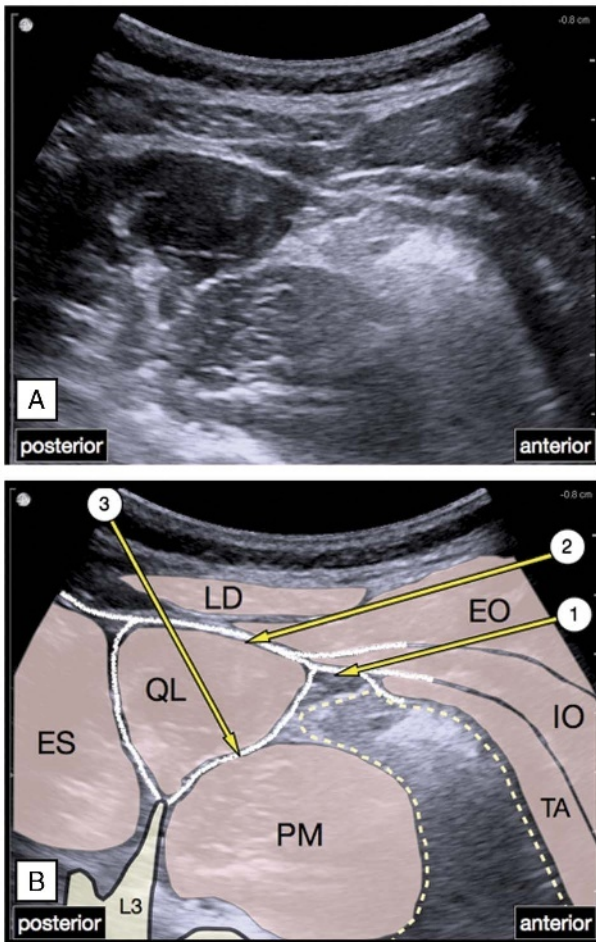


FIGURE 11. An illustration of 3 described approaches to the US-guided QL block. In the QL1 approach (1), the needle is advanced in a lateral-to-medial direction to reach the plane between the transversalis fascia (dotted line) and the internal oblique (IO) and transversus abdominis (TA) aponeurosis. In the QL2 approach (2), the same needle trajectory is used to reach the tissue plane posterior (dorsal) to QL muscle. In the transmuscular or QL3 approach (3), the needle is advanced in a posterior-to-anterior direction to reach the anterior (ventral) surface of QLM. EO indicates external oblique; ES, erector spinae; IO, internal oblique; LD, latissimus dorsi; PM, psoas major; TA, transversus abdominis.

The early data are encouraging for the efficacy of the QL block, and active investigation is ongoing, with new variants of the technique continuing to be described.^{41,213} However, until there is clinical evidence to suggest otherwise, it should not be assumed that all QL blocks are equal. Future studies should therefore clearly describe the approach that was used, which will facilitate interpretation of the literature should differences in clinical efficacy and safety begin to emerge as they did for the TAP block. A simplified nomenclature has been suggested in which any approach (regardless of needle trajectory) involving needle tip placement and local anesthetic spread posterior (dorsal) to the QLM is a “posterior QL block” (equivalent to the QL2 block), and any approach resulting in needle tip placement and spread anterior (ventral) to the QLM is an “anterior QL block” (equivalent to the QL3 or transmuscular QL block).²¹⁴

Transversalis Fascia Plane Block

The US-guided TFP block was first described in 2009⁴² as a technique for achieving proximal blockade of the T12 and L1 nerves, including their lateral cutaneous branches. In the TFP block, the transducer is placed in a transverse orientation just superior to the iliac crest, and the IOM and TAM are traced posteriorly until they are observed to taper off into their common aponeurosis and abut against the QLM. The needle is inserted in an anterior-to-posterior direction until the tip is deep to the tapered tip of the TAM. Injection occurs into the plane between the TAM and the transversalis fascia, creating a visible pocket of fluid (Fig. 12). Although this technique appears similar to the QL1 block, the point of injection is more caudal (adjacent to the iliac crest) and more anterior (deep to the muscular tip of TAM rather than the aponeurosis of TAM/IOM). This results in more localized spread, specifically targeting the II and IH nerves where they run deep to TAM before ascending into the TAP. At present, there are few published clinical data on the TFP block, apart from a small retrospective review demonstrating effective early postoperative analgesia in anterior iliac crest bone graft harvesting.⁴³ As with the QL block, there is a potential risk of spread under transversalis fascia to the lumbar plexus with ensuing quadriceps weakness.^{3,215}

ABDOMINAL WALL BLOCKS IN OBSTETRIC PATIENTS

The application of abdominal wall blocks in obstetric patients warrants a separate discussion because of the large body of literature dealing specifically with this patient population and the unique considerations for analgesia in cesarean delivery. The majority of modern cesarean deliveries are performed under neuraxial anesthesia with single-dose intrathecal or epidural morphine as the cornerstone of postoperative analgesia, supplemented with oral NSAIDs and acetaminophen.²¹⁶ Neuraxial morphine provides effective and prolonged (12-36 hours) analgesia for both incisional and visceral pain after abdominal surgery,^{216,217} whereas NSAIDs improve the visceral, cramping pain after cesarean delivery.^{218,219} Despite these analgesic interventions, pain is often incompletely relieved,²²⁰ and the majority of women still require additional opioid analgesia. Neuraxial opioids are also associated with adverse effects such as pruritus and nausea and vomiting, and the potential risk of delayed respiratory depression necessitates additional postoperative monitoring, all of which can present as a barrier to their use.²²¹

Abdominal wall blocks are therefore a valuable option in obstetric patients, especially as the infraumbilical Pfannenstiel incision of lower-segment cesarean delivery is ideally suited to coverage by TAP, II-IH, or QL block. There is minimal concern regarding local anesthetic use and breast-feeding because most local anesthetics (particularly ropivacaine) have very limited breast

milk transfer and are poorly bioavailable to the breast-feeding infant.²²²⁻²²⁶ These blocks should, however, be considered as adjuvants to, and not substitutes for, a multimodal analgesic strategy, because they are only effective against somatic incisional pain and not deep visceral uterine pain.²²⁷⁻²²⁹

TAP Blocks in Obstetric Patients

Transversus abdominis plane blocks are the most frequently utilized and studied truncal block in the obstetric setting.¹²⁸ Performing TAP blocks prior to delivery of the fetus is relatively contraindicated because of potential fetal injury and in utero exposure to local anesthetic drugs; they are therefore performed at the end of surgery after skin closure or as a rescue block in recovery. The US-guided lateral TAP block appears to be more popular than the landmark-guided TAP block,¹²⁸ presumably because of concerns regarding accuracy of needle placement⁴⁵ with the latter approach. It is currently unclear if one approach is more effective than another. Subgroup analysis in 1 meta-analysis has indicated that approaches using a more posterior injection site, such as the landmark-guided TAP block, may produce superior and more prolonged analgesia compared with the US-guided lateral TAP block.¹²⁴ As previously discussed, this may be due to more extensive local anesthetic spread, particularly to the thoracic paravertebral space,⁴⁶ in the former subgroup. However, the observed difference in effect size may also be due to the fact that none of the studies in the posterior injection subgroup utilized intrathecal morphine. In contrast, another meta-analysis that subdivided studies by whether intrathecal morphine was administered reported that both approaches were largely similar in analgesic efficacy, with any difference being in favor of the US-guided approach.²³⁰

TAP block in cesarean delivery under general anesthesia

Evidence for the efficacy of TAP block for postoperative cesarean delivery analgesia depends on the clinical setting. For cesarean delivery performed under general anesthesia, studies have shown TAP blocks performed at the end of surgery reduce analgesic requirements,^{231,232} as well as pain scores²³² (Table 5).

TAP block in cesarean delivery under neuraxial anesthesia

The analgesic efficacy of TAP blocks in cesarean delivery performed under neuraxial anesthesia depends on the utilization of intrathecal morphine. Pooled data from meta-analyses in women undergoing cesarean delivery under spinal anesthesia without intrathecal morphine show that TAP blocks are beneficial in the early postoperative period.^{230,250} Rest pain was reduced at 6, 12, and 24 hours but not at 48 hours, and dynamic pain was reduced at 6 and 12 hours but not 24 or 48 hours (Table 5).^{230,233-235,250} Transversus abdominis plane blocks also reduced opioid consumption at 6, 12, and 24 hours by 24 mg IV morphine on average, increased the time to first analgesic request by more than 2 hours, and increased satisfaction scores compared with control subjects.^{230,233-235,250} Transversus abdominis plane blocks reduced the incidence of postoperative nausea and vomiting in most studies; however, reductions in sedation and pruritus have been less clearly demonstrated.^{230,250}

Studies examining the analgesic effects of TAP blocks in women receiving intrathecal morphine, on the other hand, have shown no significant benefit.^{227,236} Meta-analysis data based on 2 studies found pain scores on movement were reduced at 6 hours, but there was no difference in rest or dynamic pain scores at 12, 24, or 48 hours.^{227,230,236,250} Opioid use and maternal satisfaction scores were also similar in both TAP block and control subjects.

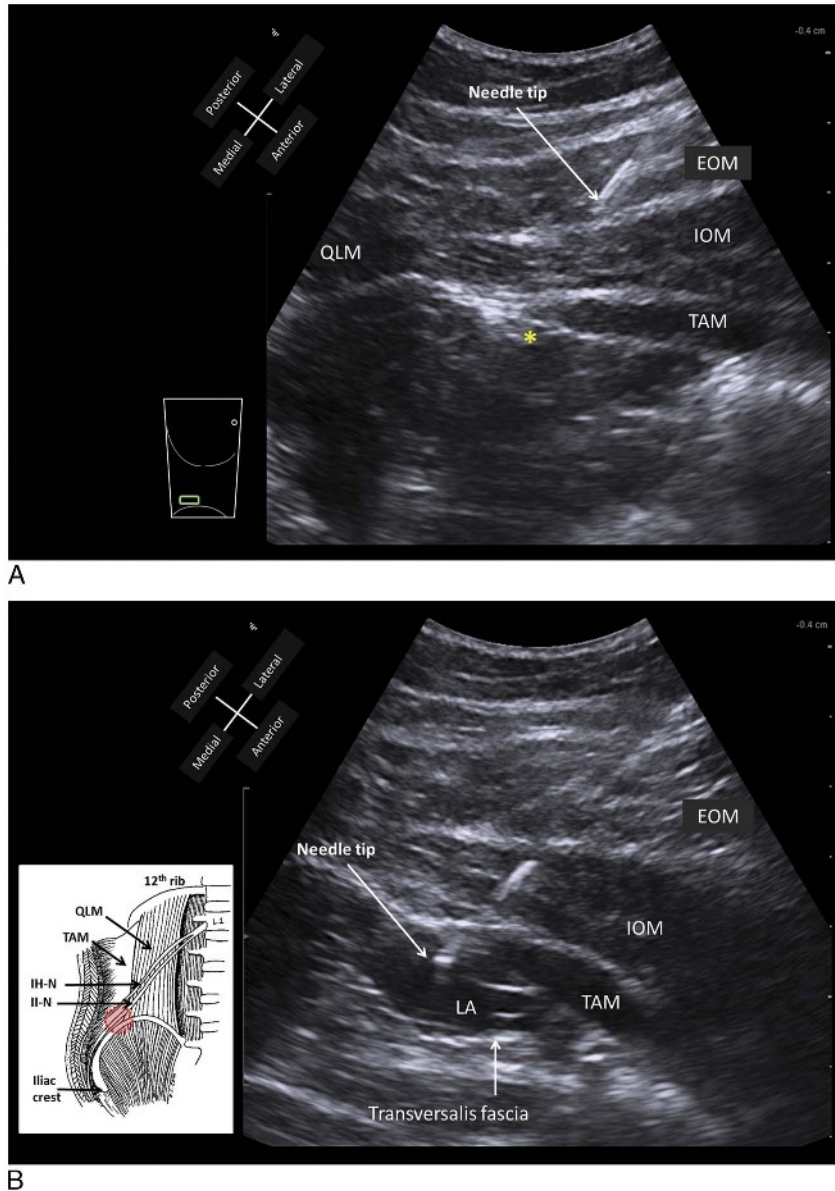


FIGURE 12. Ultrasound-guided TFP block. A, Preinjection image. The needle is advanced in an anterior-to-posterior direction, aiming to pierce the TAM where it tapers off into its aponeurosis. The target for needle tip position is immediately deep to TAM as indicated by the asterisk. B, Postinjection image. Correct needle tip position is indicated by formation of a visible pocket of local anesthetic (LA) expanding in the plane between TAM and the transversalis fascia, which lines the deep surface of TAM. The II-N and IH-N lie in this location immediately superior to the iliac crest (inset picture). IH-N indicates iliohypogastric nerve; II-N, ilioinguinal nerve; LA, local anesthetic. Reproduced with permission from KJ Chin Medicine Professional Corporation.

Since the 2012 meta-analyses, 3 further studies^{237–239} have been published that confirm that the addition of TAP blocks to intrathecal morphine does little to improve the post-cesarean delivery pain experience (Table 5).

TAP block versus intrathecal morphine in cesarean delivery

Most studies that have compared intrathecal morphine to TAP blocks show that intrathecal morphine provides slightly better post-cesarean delivery analgesia^{227–230,240} (Table 5). Meta-analysis²³⁰ shows that women receiving intrathecal morphine had a longer time to first analgesic request (8 vs 4 hours),

lower 24-hour opioid consumption (mean difference, 8 mg IV morphine), and lower dynamic pain scores at 24 hours (mean difference, 0.98 on a 0- to 10-point scale) but not at rest. Postoperative nausea and vomiting were more common in the women receiving intrathecal morphine²³⁰; however, no differences in pruritus, sedation, or respiratory depression were seen.

TAP block versus other analgesic strategies in cesarean delivery

There are limited data comparing TAP block with other analgesic modalities in cesarean delivery. In 1 nonrandomized study, TAP blocks were administered at patients' request after cesarean

TABLE 5. Summary of RCTs on Truncal Blocks in Cesarean Delivery

Study	Standardized Management	Intervention	Comparator	Analgic Outcomes	Other Outcomes
TAP blocks in cesarean delivery under general anesthesia					
Tan et al, ²³¹ 2012	N = 40, elective LSCS. Intraop: GA + IV morphine 0.15 mg/kg. Postop: IV PCA morphine.	Bilateral USG lateral TAP blocks using 20 mL 0.25% levobupivacaine per side at the end of surgery	No TAP blocks.	No sig differences in rest or dynamic pain scores between groups. Sig lower morphine use in TAP vs control group at 24 h (mean 12.3 vs 31.4 mg).	No sig differences in nausea or vomiting, sedation, or satisfaction between groups.
Eslamian et al, ²³² 2012	N = 48, elective LSCS. Intraop: GA + IV morphine 0.1 mg/kg + sufentanil 15 µg. Postop: PR diclofenac 100 mg every 24 h + IV tramadol 50 mg every 4 h prn	Bilateral LMG TAP blocks using 15 mL 0.25% levobupivacaine per side at the end of surgery.	No TAP blocks.	Sig lower rest pain scores in TAP vs control group up to 12 h, but not at 24 h. Sig lower dynamic pain scores in TAP vs control group at time points up to 24 h. Sig lower tramadol use in TAP vs control group (mean 75 vs 250 mg). Sig longer time to 1st opioid use in TAP vs control group (mean 210 vs 30 min).	
TAP blocks in cesarean delivery under neuraxial anesthesia without intrathecal morphine					
Baaj et al, ²³³ 2010	N = 40, elective LSCS. Intraop: spinal anesthesia; no IT morphine. Postop: IV PCA morphine. No MMA.	Bilateral USG lateral TAP blocks using 20 mL 0.25% bupivacaine per side at the end of surgery.	Sham TAP blocks with 0.9% saline.	Lower pain scores in TAP group vs control group. Sig lower morphine use at 24 h in TAP vs control group (mean 25.9 vs 62 mg).	Sig less nausea and vomiting in TAP vs control group (5% vs 10.5%).
Belavy et al, ²³⁴ 2009	N = 47, elective LSCS. Intraop: spinal anesthesia; no IT morphine. PR diclofenac 100 mg + PR acetaminophen 1 g. Postop: IV PCA morphine + PO acetaminophen 1 g every 6 h + PO ibuprofen 400 mg every 8 h.	Bilateral USG lateral TAP blocks using 20 mL 0.5% ropivacaine per side at the end of surgery.	Sham TAP blocks with 0.9% saline.	No sig difference in pain scores over 24 h in TAP vs control group (2.7 vs 2.3). Sig lower morphine use in TAP vs control group at 24 h (18 vs 31.5 mg). Sig shorter time to 1st opioid use in TAP vs control group (median 2 vs 3 h).	Sig higher patient satisfaction in TAP vs control group (9.6 vs 7.7 out of 10). Sig fewer patients received antiemetics in TAP vs control group
McDonnell et al, ²³⁵ 2008	N = 50, elective LSCS. Intraop: spinal anesthesia; no IT morphine. PR diclofenac 1 mg/kg + PR acetaminophen 1 g. Postop: IV PCA morphine + PO acetaminophen 1 g + PR diclofenac 100 mg every 18 h.	Bilateral LMG TAP blocks using 1.5 mg/kg ropivacaine per side at the end of surgery.	Sham TAP blocks with 0.9% saline.	Sig lower rest and dynamic pain scores in TAP vs control group up to 12 h but not beyond. Sig lower morphine use in TAP vs control group at 0-12 h (6 vs 33 mg), at 12-24 h (3 vs 19 mg) but not at 24-36 h or 36-48 h. Sig lower morphine use in TAP vs control group over 48 h. Sig longer time to 1st morphine use in TAP vs control group (median 220 vs 90 min).	Sig lower incidence of sedation in TAP vs control group (0% vs 36%). No sig difference in nausea between groups.

Continued next page

TABLE 5. (Continued)

Study	Standardized Management	Intervention	Comparator	Analgesic Outcomes	Other Outcomes
TAP blocks in cesarean delivery under neuraxial anesthesia with intrathecal morphine					
McMorrow et al, ²²⁷ 2011	N = 80, elective LSCS. Intraop: spinal anesthesia. Postop: IV PCA morphine + PO acetaminophen 1 g every 6 h + PR diclofenac 100 mg every 12 h.	Group I: Bilateral LMG TAP blocks with 1 mg/kg 0.375% bupivacaine per side at end of surgery + IT morphine 100 µg. Group II: Bilateral LMG TAP blocks with 1 mg/kg 0.375% bupivacaine per side at end of surgery; no IT morphine.	Group III: IT morphine 100 µg + sham TAP blocks. Group IV: no IT morphine + sham TAP blocks.	Sig difference in rest pain scores between groups at 6 h (0.9 vs 1.6 vs 2.9 vs 3.1; group I vs III vs IV vs II) and 24 h (1 vs 1.2 vs 2 vs 2.7; group III vs I vs IV vs II), but not at 48 h. Sig difference in dynamic pain scores between groups at 6 h (2 vs 2.75 vs 5.15 vs 5.2; group I vs III vs IV vs II), but not at 24 h or 48 h. Sig difference in morphine use between groups at 6 h (4.0 vs 5.0 vs 8.0 vs 12.0 mg; group III vs I vs II vs IV), 12 h (2.0 vs 5.0 vs 6.0 vs 10.5 mg; group III vs I vs IV vs II), 24 h (5.0 vs 6.0 vs 9.5 vs 15.0 mg; group I vs III vs IV vs II), but not 48 h.	Highest use of anti-emetics in group I. Pruritus most common in group III.
Costello et al, ²³⁶ 2009	N = 50, elective LSCS. Intraop: spinal anesthesia + IT morphine 100 µg + IV ketorolac 30 mg + PR acetaminophen 1.3 g. Postop: PO acetaminophen 1 g every 6 h + PO diclofenac 50 mg + SC/PO morphine prn.	Bilateral USG lateral TAP blocks with 20 mL 0.375% ropivacaine per side at end of surgery.	Sham TAP blocks with 0.9% saline.	No sig difference in rest or dynamic pain scores in TAP vs control group at any other time point up to 48 h. No sig difference in opioid use between groups.	No sig difference in patient satisfaction between groups.
Lee et al, ²³⁷ 2013	N = 51, elective LSCS. Intraop: CSE + IT morphine 250 µg. Postop: PO acetaminophen 1 g every 6 h prn, IV ketorolac or PO ibuprofen 800 mg every 6 h prn, PO acetaminophen 325 mg-oxycodone 5 mg 2 tabs every 6 h prn.	Bilateral USG lateral TAP blocks with 20 mL 0.5% ropivacaine per side at end of surgery.	Sham TAP blocks with 0.9% saline.	Sig lower pain scores in TAP vs control group at 2 h at rest (mean 0.5 vs 2.8) and movement (mean 1.9 vs 4.9). No sig differences in rest or dynamic pain scores between groups at 24 h and 48 h. Sig lower analgesic use in TAP vs control group in PACU. No sig differences in analgesic use at 48 h, or time to 1st analgesic use between groups.	No sig differences in nausea, sedation, dizziness, pruritus, or satisfaction between groups.
Singh et al, ²³⁸ 2013	N = 59, elective LSCS. Intraop: spinal anesthesia + IT morphine 150 µg + IV ketorolac 30 mg. Postop: PO acetaminophen 650 mg every 6 h + IV ketorolac every 6 h, PO oxycodone 5–10 mg every 4 h prn.	Group I: Bilateral USG lateral TAP blocks with 1.5 mg/kg 0.5% ropivacaine per side at end of surgery. Group II: Bilateral USG lateral TAP blocks with 0.75 mg/kg 0.5% ropivacaine per side at end of surgery.	Group III: sham TAP blocks with 0.9% saline.	Sig lower dynamic pain scores in group I vs both group II and III at 6 h and 12 h, but not between group II and III. No sig difference in dynamic pain at 24 h between groups. No sig difference in analgesic use between groups.	No sig difference in sedation, pruritus, nausea, quality of recovery, or patient satisfaction between groups.

McKeen et al, ²³⁹ 2014	N = 83, elective LSCS. Intraop: spinal anesthesia + IT morphine 100 µg + IV ketorolac 30 mg + PO acetaminophen 1 g. Postop: PO acetaminophen 1 g every 6 h + PO naproxen 250 mg every 8 h + PO oxycodone 2.5-5 mg every 4 h prn.	Bilateral USG lateral TAP blocks with 20 mL 0.25% ropivacaine per side at end of surgery.	Sham TAP blocks with 0.9% saline.	No sig differences in rest or dynamic pain scores at 24 h between groups. No sig differences in opioid use over 24 h between groups.	No sig differences in nausea, vomiting, pruritus, satisfaction at 48 h, or quality of recovery scores at 24 h between groups.
TAP blocks versus intrathecal morphine in cesarean delivery under neuraxial anesthesia					
Kanazi et al, ²²⁸ 2010	N = 57, elective LSCS. Intraop: spinal anesthesia + PR diclofenac 100 mg + IV acetaminophen 1 g. Postop: IV acetaminophen 1 g every 6 h + PR diclofenac 100 mg every 12 h + IV tramadol 100 mg every 8 h prn.	Bilateral USG lateral TAP blocks with 20 mL 0.375% bupivacaine per side at end of surgery.	IT morphine 200 µg + sham TAP blocks with 0.9% saline	Sig higher visceral pain scores in TAP vs IT morphine group at 0-4 h but not beyond. Sig higher tramadol use in TAP vs IT morphine group at 0-12 h (median 0 vs 0), but not 12-24 h (median 0 vs 0). Sig shorter time to 1st analgesic use in TAP vs IT morphine group (median 4 vs 8 h).	Sig lower incidence of nausea and pruritus in TAP vs IT morphine group. No sig difference in patient satisfaction between groups.
Loane et al, ²²⁹ 2012	N = 66, elective LSCS. Intraop: spinal anesthesia + PR naproxen 500 mg + PR acetaminophen 975 g. Postop: PO acetaminophen 1 g every 6 h + PO naproxen 500 mg every 12 h + PO hydromorphone 2-4 mg every 4 h prn.	Bilateral USG lateral TAP blocks with 1.5 mg/kg 0.5% ropivacaine per side at end of surgery.	100 µg IT morphine + sham TAP blocks with 0.9% saline	Sig higher rest and dynamic pains scores in TAP vs IT morphine group at 10 h, but not at other time points. Sig higher morphine use in TAP vs IT morphine group at 10-24 h (mean 7.5 vs 2.7 mg), but no sig difference at <10 h.	Sig less nausea, vomiting, pruritus in TAP vs IT morphine group.
Cánovas et al, ²⁴⁰ 2013	N = 90, elective LSCS. Intraop: spinal anesthesia. Postop: IV PCA morphine.	Group I: Bilateral USG lateral TAP blocks with 20 mL 0.5% levobupivacaine per side at end of surgery + IT fentanyl 10 µg.	Group II: IT fentanyl 10 µg. Group III: IT morphine 100 µg.	Sig lower rest pain scores in TAP group vs group II and III at 12 h (mean 1.9 vs 4.3 vs 2.1) and 24 h (2.3 vs 4.8 vs 4.7). Sig lower number of PCA boluses in 24 h in TAP group vs group II and III (mean 5 vs 38 vs 10). Time to 1st opioid use was longest in TAP group vs group II and III (mean 13.2 vs 2 vs 9.3 h).	Sig lower incidence of nausea and pruritus in TAP group compared with group II and III.
TAP blocks versus wound infiltration in cesarean delivery					
Telnes et al, ²⁴¹ 2015	N = 57, elective LSCS. Intraop: spinal anesthesia; no IT morphine. Postop: IV PCA morphine + PO acetaminophen 1 g every 6 h + diclofenac 50 mg every 8 h.	Bilateral USG lateral TAP blocks with 20 mL 0.25% bupivacaine per side + sham infiltration at end of surgery.	Wound infiltration with 20 mL 0.25% bupivacaine + sham TAP blocks at end of surgery.	No sig differences in rest and dynamic pain over 48 h between groups. No sig difference in morphine use in TAP vs infiltration group over 48 h (mean 41 vs 38 mg). No sig difference in time to 1st analgesic use in TAP vs infiltration group (mean 46 vs 64 min).	

Continued next page

TABLE 5. (Continued)

Study	Standardized Management	Intervention	Comparator	Analgasic Outcomes	Other Outcomes
Chandon et al, ²⁴² 2014	N = 65, elective LSCS. Intraop: spinal anesthesia; no IT morphine. Postop: PO acetaminophen 1 g every 6 h + PO ketoprofen 50 mg every 6 h + nefopam 20 mg every 6 h.	Bilateral USG lateral TAP blocks with 20 mL 0.375% levobupivacaine at end of surgery.	Surgical insertion of wound catheter, followed by infusion of 5 mL/h of 0.125% levobupivacaine.	No sig differences in rest and dynamic pain scores over 48 h between groups. No sig difference in morphine use between groups.	1 episode of LAST seizures following TAP block, leading to early study termination. Sig more nausea and vomiting in TAP group. No sig differences in sedation, pruritus, satisfaction, or length of hospital stay between groups.
Aydogmus et al, ²⁴³ 2014	N = 70, elective LSCS. Intraop: spinal anesthesia; no IT morphine. Postop: IM diclofenac 75 mg prn, IV tramadol 50 mg prn.	Bilateral USG lateral TAP blocks with 20 mL 0.25% levobupivacaine per side at end of surgery.	Wound infiltration with 40 mL 0.25% levobupivacaine at end of surgery.	Sig lower pain scores in TAP vs infiltration group at 2 h (median 4 vs 6), 6 h (median 4 vs 5), 12 h (2 vs 5), 24 h (2 vs 4). Sig longer time to 1st analgesic use in TAP vs infiltration group (mean 6.1 vs 2.6 h).	No sig difference in patient satisfaction between groups.
Quadratus lumborum blocks versus systemic analgesia					
Blanco et al, ²⁰⁷ 2015	N = 48, elective LSCS. Intraop: spinal anesthesia; no IT morphine. PR diclofenac 100 mg + IV acetaminophen 1 g. Postop: IV PCA morphine + PO acetaminophen 1 g every 6 h + PO diclofenac 50 mg every 8 h.	Bilateral USG QL blocks (QLBs) with 0.2 mL/kg 0.125% bupivacaine per side at end of surgery.	Sham QLBs with 0.9% saline.	Sig lower rest and dynamic pain scores in QLB vs control group at all time points up to 48 h (except rest pain at 24 h). Sig lower morphine use in QLB vs control group at 6 h (median 2 vs 7 mg) and 12 h (median 8 vs 14 mg), but not at 24 h and 48 h.	No sig differences in sedation, nausea, or pruritus between groups.
II-IH blocks in cesarean delivery without intrathecal morphine					
Bunting and McConachie, ²⁴⁴ 1988	N = 26, elective LSCS. Intraop: GA + IV fentanyl 100 µg. Postop: papaveretum prn.	Bilateral LMG II-IH blocks using 10 mL 0.5% bupivacaine per side at end of surgery.	No II-IH blocks.	Sig lower pain scores at all time points up to 24 h in II-IH vs control group. Sig lower analgesic use in II-IH vs control group.	No sig differences in nausea or pruritus between groups.
Bell et al, ²⁴⁵ 2002	N = 59, elective LSCS. Intraop: spinal or epidural anesthesia; no IT morphine. Postop: IV PCA morphine. No MMA.	Bilateral LMG II-IH blocks using 12 mL 0.5% bupivacaine per side at end of surgery.	Sham II-IH blocks with 0.9% saline.	No sig difference in pain scores in II-IH vs control group (mean 1.7 vs 2.2). Sig lower morphine use in II-IH vs control group over 24 h (mean 48 vs 67 mg).	No sig differences in nausea or pruritus between groups.
Ganta et al, ²⁴⁶ 1994	N = 62, elective LSCS. Intraop: GA. Postop: IM papaveretum in 1st 24 h.	Group I: preincisional bilateral LMG II-IH blocks using 10 mL 0.5% bupivacaine per side.	Group II: wound infiltration with 20 mL 0.5% bupivacaine. Group III: No local anesthetic.	Sig lower pain scores in group I vs III at 4-24 h. Sig lower analgesic use in group I vs III at 4-20 h. No sig difference in pain scores or analgesic use between group I and II.	There were sig differences in pain scores and analgesic use in group II vs III but only in the 1st 12 h.

Huffnagle et al,²⁴⁷ 1996
 N = 46, elective LSCS.
 Intraop: spinal or epidural anesthesia; no IT morphine.
 Postop: IV PCA morphine.
 No MMA.

Group I: preincisional bilateral LMG II-IH blocks using 10 mL 0.5% bupivacaine per side.
 Group II: bilateral LMG II-IH blocks using 10 mL 0.5% bupivacaine per side at end of surgery.

Group III: No II-IH blocks. Sig lower rest pain scores in group I vs II at 24 h. Patients in group II had the most dynamic and overall pain at 24 and 48 h. No sig difference in morphine use over 24 h between groups.

No sig differences in nausea or pruritus or patient satisfaction between groups.

II-IH blocks in cesarean delivery with intrathecal morphine

Vallejo et al,²⁴⁸ 2012
 N = 34, elective LSCS.
 Intraop: Spinal anesthetic + IT morphine 150–200 µg.
 Postop: IV ketorolac 30 mg every 6 h on POD 1, then IV or PO opioid and non-opioid analgesics.

Group I: Bilateral USG II-IH blocks at end of surgery using 10 mL 0.5% bupivacaine per side.
 Group II: Unilateral USG II-IH block at end of surgery using 10 mL 0.5% bupivacaine + sham block on the other side.

Group III: Sham II-IH blocks with 0.9% saline.

No sig differences in pain scores at all time periods over 48 h between groups. No sig differences in postop analgesic use over 48 h between groups.

No sig differences in nausea, vomiting, pruritus, or patient satisfaction between groups.

Wolfson et al,²⁴⁹ 2012
 N = 34, elective LSCS.
 Intraop: Spinal anesthetic + IT morphine 200 µg.
 Postop: IV ketorolac 30 mg x1 prn; PO acetaminophen 500 mg-oxycodone 5 mg 2 tab every 6 h prn; or IV PCA morphine.

Sham II-IH blocks with 0.9% saline.

Sig lower pain scores in II-IH vs control group at 6 h (median 0 vs 3), 12 h (median 1 vs 2), 18 h (median 1 vs 3), and 24 h (median 1.5 vs 4). Sig longer time to 1st analgesic use in II-IH vs control group (mean 14.4 vs 5.6 h). Sig fewer patients in II-IH vs control group used oral opioids (6% vs 71%).

No sig differences in nausea, vomiting, pruritus between groups.

All pain scores reported on a 0- to 10-point scale.

CSE indicates combined spinal-epidural anesthesia; II-IH, ilioinguinal = iliohypogastric; IT, intrathecal; LMG, landmark-guided; LSCS, lower-segment cesarean delivery; MMA, multimodal analgesia; PCA, patient-controlled analgesia; PO, oral; POD, postoperative day; PR, rectal; USG, US-guided.

delivery under combined spinal-epidural anesthesia with epidural morphine 2 mg.²⁵¹ Women receiving TAP blocks had improved time to first analgesic and morphine consumption.

Bilateral US-guided lateral TAP blocks have also been compared with wound site infiltration in 3 studies of cesarean delivery under spinal anesthesia without intrathecal morphine.^{241–243} Two of the studies^{241,242} reported no difference in analgesic outcomes between groups, whereas the third²⁴³ found that TAP blocks reduced pain scores and increased time to first analgesic request.

Continuous TAP block in cesarean delivery

There are no randomized controlled studies to confirm the utility of continuous TAP catheters following cesarean delivery, although 1 case report suggests they may have a role if prolonged analgesia is required.²⁵² The superior side-effect profile may make them preferable to epidural analgesia but must be balanced against the technical and logistical issues previously discussed.

QL Block in Obstetric Patients

To date, there is only 1 RCT of the US-guided QL block in the obstetric population.²⁰⁷ This demonstrated reduced opioid requirements and pain scores in the first 24 to 48 hours following cesarean delivery with spinal anesthesia (but without intrathecal morphine) when a posterior QL block was performed in addition to a multimodal analgesic regimen of acetaminophen and NSAIDs (Table 5). Further investigation is needed to define its role in this setting.

II-IH Nerve Block in Obstetric Patients

Four studies have examined the effect of bilateral landmark-guided II-IH blocks in patients undergoing cesarean delivery without intrathecal morphine. Three of the studies^{244–246} reported that II-IH blocks reduced analgesic requirements and pain scores compared with control subjects, but the fourth²⁴⁷ found no significant differences.

There are conflicting data on the value of adding II-IH blocks to intrathecal morphine in cesarean delivery. Valjejo et al²⁴⁸ found that bilateral US-guided II-IH blocks did not improve postoperative analgesia or decrease opioid-related adverse effects (nausea, vomiting, and pruritus). In contrast, Wolfson et al²⁴⁹ reported that bilateral multi-injection landmark-guided II-IH nerve blocks produced lower pain scores and analgesic requirements, longer time to first analgesic use, and higher satisfaction scores compared with intrathecal morphine alone.

It has also been proposed that it may be more effective to combine TAP block with II-IH nerve block, given that these nerves are inconsistently blocked by US-guided TAP blocks.²⁵³ However, no studies have compared the analgesic efficacy of TAP and II-IH blocks in cesarean delivery. Finally, the potential of continuous II-IH nerve blockade for cesarean delivery analgesia has been highlighted in a small case series.²⁵⁴ Bilateral catheters were inserted under US guidance, and 0.2% ropivacaine at 4 mL/h was administered for 72 hours. Patients had minimal pain and analgesic requirements despite receiving no intrathecal morphine.

In summary, II-IH blocks have been used to treat post-cesarean delivery pain with varying success. The heterogeneity and small number of available studies make it difficult to conclude if this reflects failure rates inherent in the specific technique used or a true lack of efficacy in this setting. The addition of intrathecal morphine may also reduce the apparent analgesic benefit, as it does with TAP blocks. Ilioinguinal-iliohypogastric blocks may be an alternative rescue block technique where other modalities have failed.²⁵⁵

Rectus Sheath Block in Obstetric Patients

There are only isolated case reports of rectus sheath blocks in the obstetric setting.^{256,257} In 1 report, bilateral US-guided rectus sheath block at the level of the umbilicus was performed 3 days after surgery to relieve neuropathic incisional pain.²⁵⁶ In another report, bilateral landmark-guided rectus sheath block was performed after midline incision cesarean delivery under general anesthesia.²⁵⁷ Despite this, the patient continued to require large doses of opioids for analgesia. The utility of rectus sheath blocks for Pfannenstiel incisions is questionable. The posterior rectus sheath is deficient below the arcuate line, and the II and IH nerves have no relationship to the RAM, given the absence of a posterior rectus sheath below the arcuate line.

The Overall Role of Truncal Blocks in Obstetric Patients

At present, the greatest weight of evidence favors the use of TAP blocks over other abdominal wall blocks in cesarean delivery, although further studies on the QL block are awaited. As in the nonobstetric population, any attempt to summarize the literature on TAP blocks is hampered by the recent realization that the landmark-guided and US-guided approaches may differ in their mechanism of action. However, the vast majority of obstetric studies utilize the US-guided lateral TAP block, and the recommendations shown in Table 6 apply to this approach. The current evidence demonstrates that in women receiving general anesthesia or neuraxial anesthesia without intrathecal opioids TAP blocks improve postoperative analgesia in the first 24 hours and are at least as good as, if not better than, wound infiltration. Intrathecal morphine confers an improvement in pain scores and opioid consumption compared with TAP block, but this needs to be weighed against the increased risk of adverse effects, particularly nausea and vomiting. In women who do receive intrathecal morphine and multimodal analgesia, the benefit of TAP blocks is modest at best and confined to the early (6 hours) postoperative period. In these patients, TAP blocks may therefore be better suited as a rescue analgesic technique for severe breakthrough pain following surgery, rather than as a routine block in all patients. This was illustrated by a case series of TAP blocks administered for severe incisional pain after resolution of the spinal block following cesarean delivery.²⁵⁸ The blocks provided excellent pain relief for 10 to 19 hours and prevented further escalation in IV opioid requirements. Isolated case reports have also described the successful application of TAP blocks for intractable incisional neuropathic pain²⁵⁹ and pain from an abdominal wall hematoma²⁶⁰ following cesarean delivery, as well as abdominal wall pain during pregnancy.²⁶¹ However, visceral pain will not be relieved by TAP blocks, and it is therefore important to determine the nature of pain (incisional or cramping) before proceeding.

TABLE 6. Clinical Settings Where TAP Blocks Are Indicated for the Provision of Cesarean Delivery Analgesia

Setting	Indication
At time of surgery after wound closure	Cesarean delivery under general anesthesia; cesarean delivery with spinal anesthesia without the use of intrathecal morphine
In recovery or on postpartum floor	Rescue analgesic for severe incisional pain; postoperative analgesic technique for high or escalating IV opioid requirements
Patient-specific factors	NSAIDs contraindicated or withheld because of obstetric concerns; Opioid-dependent

SAFETY CONCERNS IN ABDOMINAL WALL BLOCKS

Reports of complications associated with abdominal wall blocks are fortunately relatively rare¹²⁶ and can be divided into 3 main categories: needle or mechanical trauma, maldistribution of local anesthetic, and local anesthetic systemic toxicity (LAST).

Needle Trauma

The major concern with abdominal wall blocks, particularly the landmark-guided approaches where entry into the correct tissue plane is guided only by subjective tactile pops, is excessively deep needle insertion. Intraperitoneal injection per se is relatively harmless, apart from resulting in block failure. However, visceral injury has been reported with all the major truncal block techniques, including liver trauma following TAP block²⁶² and intestinal trauma following II-IH block.^{153,154,263} Vascular injury resulting in pelvic¹⁵⁵ and retroperitoneal hematoma²⁶⁴ has also been described with II-IH block and rectus sheath block, respectively. The use of US guidance should significantly minimize this risk, but misadventure may still occur if needle tip visualization is inadequate.²⁶⁵

There have been no reports of neurological injury associated with truncal blocks to date, and this can be attributed to the fact that tissue planes, rather than nerves, are targeted and that any nerves in the target area are small and thus unlikely to be directly involved in needle trauma. For this reason, it is generally accepted that truncal blocks may be performed under general or neuraxial anesthesia.

Maldistribution of Local Anesthetic

Inadvertent femoral nerve block is a well-recognized complication of II-IH nerve block in both pediatric^{266,267} and adult²⁶⁸ populations; but it has also been reported with TAP block.^{269,270} This is more likely with the landmark-guided techniques as the mechanism is excessively deep injection of local anesthetic into the plane between transversus abdominis and transversalis fascia, which then tracks inferiorly under the iliopsoas fascia to the femoral nerve and lumbar plexus.³ Lumbar plexus block is therefore also a possible consequence of the US-guided QL^{208,212} and TFP blocks,²¹⁵ which specifically involve injection into the TFP close to psoas major. All patients receiving truncal blocks (with the exception of rectus sheath blocks) should be warned of the possibility of transient quadriceps weakness and appropriate precautions taken when mobilizing postoperatively.

Local Anesthetic Systemic Toxicity

Abdominal wall blocks have significant potential for LAST due primarily to the fact that the intermuscular tissue plane presents a large well-vascularized surface for local anesthetic absorption. Contributing factors include the use of relatively large injection volumes to ensure adequate spread and bilateral blocks to cover midline incisions. This is particularly pertinent in the obstetric population as physiological changes of pregnancy may increase the risk of LAST in parturients.²⁷¹

Several measures may help mitigate the risk of LAST and should be used whenever possible. Epinephrine will reduce peak local anesthetic plasma concentration^{121,136} and should always be added to the injectate solution. Ropivacaine and levobupivacaine are less cardiotoxic than racemic bupivacaine, and it is therefore logical to prefer their use. Doses with US-guided approaches should be lower than with landmark-guided approaches because they are associated with higher local anesthetic plasma concentrations.²² Local anesthetic doses can also be minimized by using more dilute concentrations (eg, ropivacaine 0.2%–0.25%

instead of 0.5%), which do not appear to compromise analgesic efficacy.^{87,134,135} Lean body-weight dosing should be used in overweight subjects,¹³¹ and maximum recommended doses of local anesthetics^{129,130} always adhered to. Patients should also be closely monitored for at least 30 to 45 minutes because this is the average time to peak plasma concentration following truncal blocks.^{22,49,122,132,136,173,272}

Consent Issues

In light of the small but real risk for serious complications, consent is an essential requirement before performing abdominal wall blocks. If preincisional blocks are not part of the anesthetic plan, it is prudent to obtain consent for postoperative rescue blocks in the event of significant pain. A United Kingdom-based survey of obstetric anesthesiologists found that only 65% of respondents obtained consent for TAP blocks¹²⁸; however, this may reflect the fact that general anesthesia for cesarean delivery is often done emergently with little or no time to adequately consent patients for a regional block.

CONCLUSIONS

Abdominal wall blocks, particularly when performed with US guidance, are technically simple and have favorable safety and side-effect profiles. They are therefore attractive alternatives to epidural and paravertebral blocks for truncal analgesia, particularly because they can be performed during general anesthesia and in the supine position. At the same time, their limitations must be recognized. The fixed analgesic duration of single-shot blocks is an issue because continuous catheter techniques, although feasible, are complex and cumbersome. Further research is awaited to see if local anesthetic additives or liposomal bupivacaine will prove to be a solution.

In addition, the extent of analgesia varies with the specific technique, and this must be matched to the surgical site. This applies in particular to the TAP block, which encompasses multiple approaches with different clinical applications. For example, the US-guided subcostal TAP should be used to cover supraumbilical incisions, whereas the US-guided lateral TAP block is best suited to incisions in the T10–T12 area. With the possible exception of the QL block and landmark-guided TAP block, abdominal wall blocks generally do not provide analgesia for incisions extending lateral to the anterior axillary line and provide limited additional benefit in surgeries with either a large component of visceral pain or only a small component of somatic pain. These factors, coupled with the interindividual variability in spread and efficacy observed in most studies, mean that these blocks are most useful as part of a multimodal analgesic regimen.

It is increasingly apparent that the abdominal wall is anatomically complex, particularly with regard to the relationships between muscles, fascial layers, and the planes that exist between them. Most abdominal wall blocks are based on injection into a particular tissue plane, and as the evolution of TAP blocks has shown, apparently small anatomical differences in needle tip placement can result in clinically significant differences between what seem to be otherwise similar techniques. When it comes to the efficacy of abdominal wall blocks, the devil may be in the details. We would therefore encourage investigators to be as specific as possible in their anatomical and technical descriptions going forward. We also recommend using block nomenclature that is simple yet informative and, ideally, reflects the anatomical basis of the block as accurately as possible.

REFERENCES

- Willard FH, Vleeming A, Schuenke MD, Danneels L, Schleip R. The thoracolumbar fascia: anatomy, function and clinical considerations. *J Anat.* 2012;221:507–536.
- Schuenke MD, Vleeming A, van Hoof T, Willard FH. A description of the lumbar interfascial triangle and its relation with the lateral raphe: anatomical constituents of load transfer through the lateral margin of the thoracolumbar fascia. *J Anat.* 2012;221:568–576.
- Rosario DJ, Jacob S, Luntley J, Skinner PP, Raftery AT. Mechanism of femoral nerve palsy complicating percutaneous ilioinguinal field block. *Br J Anaesth.* 1997;78:314–316.
- Saito T, Den S, Tanuma K, Tanuma Y, Carney E, Carlsson C. Anatomical bases for paravertebral anesthetic block: fluid communication between the thoracic and lumbar paravertebral regions. *Surg Radiol Anat.* 1999;21:359–363.
- Karmakar MK, Gin T, Ho AM. Ipsilateral thoraco-lumbar anaesthesia and paravertebral spread after low thoracic paravertebral injection. *Br J Anaesth.* 2001;87:312–316.
- McDonnell JG, O'Donnell BD, Farrell T, et al. Transversus abdominis plane block: a cadaveric and radiological evaluation. *Reg Anesth Pain Med.* 2007;32:399–404.
- Jankovic ZB, du Feu FM, McConnell P. An anatomical study of the transversus abdominis plane block: location of the lumbar triangle of Petit and adjacent nerves. *Anesth Analg.* 2009;109:981–985.
- Loukas M, Tubbs RS, El-Sedfy A, et al. The clinical anatomy of the triangle of Petit. *Hernia.* 2007;11:441–444.
- Rozen WM, Tran TM, Ashton MW, Barrington MJ, Ivanusic JJ, Taylor GI. Refining the course of the thoracolumbar nerves: a new understanding of the innervation of the anterior abdominal wall. *Clin Anat.* 2008;21:325–333.
- Rozen WM, Ashton MW, Murray AC, Taylor GI. Avoiding denervation of rectus abdominis in DIEP flap harvest: the importance of medial row perforators. *Plast Reconstr Surg.* 2008;122:710–716.
- Ladak A, Tubbs RS, Spinner RJ. Mapping sensory nerve communications between peripheral nerve territories. *Clin Anat.* 2014;27:681–690.
- Børglum J, Jensen K, Christensen AF, et al. Distribution patterns, dermatomal anesthesia, and ropivacaine serum concentrations after bilateral dual transversus abdominis plane block. *Reg Anesth Pain Med.* 2012;37:294–301.
- Støving K, Rothe C, Rosenstock CV, Aasvang EK, Lundstrøm LH, Lange KHW. Cutaneous sensory block area, muscle-relaxing effect, and block duration of the transversus abdominis plane block: a randomized, blinded, and placebo-controlled study in healthy volunteers. *Reg Anesth Pain Med.* 2015;40:355–362.
- Ndiaye A, Diop M, Ndoye JM, et al. Emergence and distribution of the ilioinguinal nerve in the inguinal region: applications to the ilioinguinal anaesthetic block (about 100 dissections). *Surg Radiol Anat.* 2010;32:55–62.
- Klaassen Z, Marshall E, Tubbs RS, Louis RG, Wartmann CT, Loukas M. Anatomy of the ilioinguinal and iliohypogastric nerves with observations of their spinal nerve contributions. *Clin Anat.* 2011;24:454–461.
- van Schoor AN, Bosman MC, Bosenberg AT. Revisiting the anatomy of the ilio-inguinal/iliohypogastric nerve block. *Paediatr Anaesth.* 2013;23:390–394.
- Jamieson RW, Swigart LL, Anson BJ. Points of parietal perforation of the ilioinguinal and iliohypogastric nerves in relation to optimal sites for local anaesthesia. *Q Bull Northwest Univ Med Sch.* 1952;26:22–26.
- Papadopoulos NJ, Katrakis ED. Some observations on the course and relations of the iliohypogastric and ilioinguinal nerves (based on 348 specimens). *Anat Anz.* 1981;149:357–364.
- Lee THW, Barrington MJ, Tran TM, Wong D, Hebbard PD. Comparison of extent of sensory block following posterior and subcostal approaches to ultrasound-guided transversus abdominis plane block. *Anaesth Intensive Care.* 2010;38:452–460.
- Fredrickson MJ, Paine C, Hamill J. Improved analgesia with the ilioinguinal block compared to the transversus abdominis plane block after pediatric inguinal surgery: a prospective randomized trial. *Paediatr Anaesth.* 2010;20:1022–1027.
- Lim SL, Ng Sb A, Tan GM. Ilioinguinal and iliohypogastric nerve block revisited: single shot versus double shot technique for hernia repair in children. *Paediatr Anaesth.* 2002;12:255–260.
- Weintraud M, Lundblad M, Kettner SC, et al. Ultrasound versus landmark-based technique for ilioinguinal-iliohypogastric nerve blockade in children: the implications on plasma levels of ropivacaine. *Anesth Analg.* 2009;108:1488–1492.
- Rafi AN. Abdominal field block: a new approach via the lumbar triangle. *Anaesthesia.* 2001;56:1024–1026.
- Børglum J, Abdallah FW, McDonnell JG, Moriggl B, Bendtsen TF. TAP block terminology. *Anaesthesia.* 2014;69:1055–1056.
- Hebbard P. TAP block nomenclature. *Anaesthesia.* 2015;70:112–113.
- Mokini Z, Vitale G. Yet more on TAP block nomenclature. *Anaesthesia.* 2015;70:369–370.
- Barrington MJ, Ivanusic JJ, Rozen WM, Hebbard P. Spread of injectate after ultrasound-guided subcostal transversus abdominis plane block: a cadaveric study. *Anaesthesia.* 2009;64:745–750.
- Børglum J, Maschmann C, Belhage B, Jensen K. Ultrasound-guided bilateral dual transversus abdominis plane block: a new four-point approach. *Acta Anaesthesiol Scand.* 2011;55:658–663.
- Hebbard P. Subcostal transversus abdominis plane block under ultrasound guidance. *Anesth Analg.* 2008;106:674–675.
- Hebbard PD, Barrington MJ, Vasey C. Ultrasound-guided continuous oblique subcostal transversus abdominis plane blockade: description of anatomy and clinical technique. *Reg Anesth Pain Med.* 2010;35:436–441.
- Hebbard P, Fujiwara Y, Shibata Y, Royse C. Ultrasound-guided transversus abdominis plane (TAP) block. *Anaesth Intensive Care.* 2007;35:616–617.
- Sviggum HP, Niesen AD, Sites BD, Dilger JA. Trunk blocks 101: transversus abdominis plane, ilioinguinal-iliohypogastric, and rectus sheath blocks. *Int Anesthesiol Clin.* 2012;50:74–92.
- Sondekoppam RV, Brookes J, Morris L, Johnson M, Ganapathy S. Injectate spread following ultrasound-guided lateral to medial approach for dual transversus abdominis plane blocks. *Acta Anaesthesiol Scand.* 2015;59:369–376.
- Eichenberger U, Greher M, Kirchmair L, Curatolo M, Moriggl B. Ultrasound-guided blocks of the ilioinguinal and iliohypogastric nerve: accuracy of a selective new technique confirmed by anatomical dissection. *Br J Anaesth.* 2006;97:238–243.
- Tagliafico A, Bignotti B, Cadoni A, Perez MM, Martinoli C. Anatomical study of the iliohypogastric, ilioinguinal, and genitofemoral nerves using high-resolution ultrasound. *Muscle Nerve.* 2015;51:42–48.
- Willschke H, Bösenberg A, Marhofer P, et al. Ultrasonography-guided rectus sheath block in paediatric anaesthesia—a new approach to an old technique. *Br J Anaesth.* 2006;97:244–249.
- Salinas FV. How I do it: ultrasound-guided bilateral rectus sheath blocks. *Am Soc Reg Anesth Pain Med News.* 2014;5–8.
- Blanco R, McDonnell JG. Optimal point of injection: the quadratus lumborum type I and II blocks. 2013. Available at <http://www.respond2articles.com/ANA/forums/post1550.aspx>. Accessed November 28, 2015.
- Visoiu M, Yakovleva N. Continuous postoperative analgesia via quadratus lumborum block - an alternative to transversus abdominis plane block. *Paediatr Anaesth.* 2013;23:959–961.

40. Børglum J, Jensen K, Moriggl B, et al. Ultrasound-Guided Transmuscular Quadratus Lumborum Blockade. *BJA Out of Blue e-Letters*. 2013. Available at http://bja.oxfordjournals.org/forum/topic/brjana_el%3b9919.
41. Dam M, Hansen CK, Børglum J, Chan V, Bendtsen TF. A transverse oblique approach to the transmuscular Quadratus Lumborum block. *Anaesthesia*. 2016;71:603–604.
42. Hebbard PD. Transversalis fascia plane block, a novel ultrasound-guided abdominal wall nerve block. *Can J Anaesth*. 2009;56:618–620.
43. Chin KJ, Chan V, Hebbard P, Tan JS, Harris M, Factor D. Ultrasound-guided transversalis fascia plane block provides analgesia for anterior iliac crest bone graft harvesting. *Can J Anaesth*. 2012;59:122–123.
44. Rafi AN. Abdominal field block via the lumbar triangle revisited. *Anaesthesia*. 2012;67:1399–1401.
45. McDermott G, Korba E, Mata U, et al. Should we stop doing blind transversus abdominis plane blocks? *Br J Anaesth*. 2012;108:499–502.
46. Carney J, Finnerty O, Rauf J, Bergin D, Laffey JG, Mc Donnell JG. Studies on the spread of local anaesthetic solution in transversus abdominis plane blocks. *Anaesthesia*. 2011;66:1023–1030.
47. Shibata Y, Sato Y, Fujiwara Y, Komatsu T. Transversus abdominis plane block. *Anesth Analg*. 2007;105:883; author reply 883.
48. Tran TM, Ivanusic JJ, Hebbard P, Barrington MJ. Determination of spread of injectate after ultrasound-guided transversus abdominis plane block: a cadaveric study. *Br J Anaesth*. 2009;102:123–127.
49. Murouchi T, Iwasaki S, Yamakage M. Quadratus lumborum block: analgesic effects and chronological ropivacaine concentrations after laparoscopic surgery. *Reg Anesth Pain Med*. 2016;41:146–150.
50. Ganapathy S, Sondekoppam RV, Terlecki M, et al. Comparison of efficacy and safety of lateral-to-medial continuous transversus abdominis plane block with thoracic epidural analgesia in patients undergoing abdominal surgery: a randomised, open-label feasibility study. *Eur J Anaesthesiol*. 2015;32:797–804.
51. Albrecht E, Kirkham KR, Endersby RV, et al. Ultrasound-guided transversus abdominis plane (TAP) block for laparoscopic gastric-bypass surgery: a prospective randomized controlled double-blinded trial. *Obes Surg*. 2013;23:1309–1314.
52. Niraj G, Kelkar A, Jeyapalan I, et al. Comparison of analgesic efficacy of subcostal transversus abdominis plane blocks with epidural analgesia following upper abdominal surgery. *Anaesthesia*. 2011;66:465–471.
53. Favuzza J, Delaney CP. Laparoscopic-guided transversus abdominis plane block for colorectal surgery. *Dis Colon Rectum*. 2013;56:389–391.
54. Bharti N, Kumar P, Bala I, Gupta V. The efficacy of a novel approach to transversus abdominis plane block for postoperative analgesia after colorectal surgery. *Anesth Analg*. 2011;112:1504–1508.
55. Owen DJ, Harrod I, Ford J, Luckas M, Gudimetla V. The surgical transversus abdominis plane block—a novel approach for performing an established technique. *BJOG*. 2011;118:24–27.
56. Lapmahapaisan S, Tantemsapya N, Aroonpruksakul N, Maisat W, Suraseranivongse S. Efficacy of surgical transversus abdominis plane block for postoperative pain relief following abdominal surgery in pediatric patients. *Paediatr Anaesth*. 2015;25:614–620.
57. Araco A, Pooney J, Araco F, Gravante G. Transversus abdominis plane block reduces the analgesic requirements after abdominoplasty with flank liposuction. *Ann Plast Surg*. 2010;65:385–388.
58. Zhong T, Wong KW, Cheng H, et al. Transversus abdominis plane (TAP) catheters inserted under direct vision in the donor site following free DIEP and MS-TRAM breast reconstruction: a prospective cohort study of 45 patients. *J Plast Reconstr Aesthet Surg*. 2013;66:329–336.
59. Favuzza J, Delaney CP. Outcomes of discharge after elective laparoscopic colorectal surgery with transversus abdominis plane blocks and enhanced recovery pathway. *J Am Coll Surg*. 2013;217:503–506.
60. Favuzza J, Brady K, Delaney CP. Transversus abdominis plane blocks and enhanced recovery pathways: making the 23-h hospital stay a realistic goal after laparoscopic colorectal surgery. *Surg Endosc*. 2013;27:2481–2486.
61. Keller DS, Ermlich BO, Delaney CP. Demonstrating the benefits of transversus abdominis plane blocks on patient outcomes in laparoscopic colorectal surgery: review of 200 consecutive cases. *J Am Coll Surg*. 2014;219:1143–1148.
62. Keller DS, Ermlich BO, Schiltz N, et al. The effect of transversus abdominis plane blocks on postoperative pain in laparoscopic colorectal surgery: a prospective, randomized, double-blind trial. *Dis Colon Rectum*. 2014;57:1290–1297.
63. Zhong T, Ojha M, Bagher S, et al. Transversus abdominis plane block reduces morphine consumption in the early postoperative period following microsurgical abdominal tissue breast reconstruction: a double-blind, placebo-controlled, randomized trial. *Plast Reconstr Surg*. 2014;134:870–878.
64. Baeriswyl M, Kirkham KR, Kern C, Albrecht E. The analgesic efficacy of ultrasound-guided transversus abdominis plane block in adult patients: a meta-analysis. *Anesth Analg*. 2015;121:1640–1654.
65. Hamill JK, Rahiri JL, Liley A, Hill AG. Rectus sheath and transversus abdominis plane blocks in children: a systematic review and meta-analysis of randomized trials. *Paediatr Anaesth*. 2016;26:363–371.
66. Wahba SS, Kamal SM. Analgesic efficacy and outcome of transversus-abdominis plane block versus low thoracic-epidural analgesia after laparotomy in ischemic heart disease patients. *J Anesth*. 2014;28:517–523.
67. Wu Y, Liu F, Tang H, et al. The analgesic efficacy of subcostal transversus abdominis plane block compared with thoracic epidural analgesia and intravenous opioid analgesia after radical gastrectomy. *Anesth Analg*. 2013;117:507–513.
68. Bhatia N, Arora S, Jyotsna W, Kaur G. Comparison of posterior and subcostal approaches to ultrasound-guided transverse abdominis plane block for postoperative analgesia in laparoscopic cholecystectomy. *J Clin Anesth*. 2014;26:294–299.
69. Shin HJ, Oh AY, Baik JS, Kim JH, Han SH, Hwang JW. Ultrasound-guided oblique subcostal transversus abdominis plane block for analgesia after laparoscopic cholecystectomy: a randomized, controlled, observer-blinded study. *Minerva Anesthesiol*. 2014;80:185–193.
70. El-Dawlatly AA, Turkistani A, Kettner SC, et al. Ultrasound-guided transversus abdominis plane block: description of a new technique and comparison with conventional systemic analgesia during laparoscopic cholecystectomy. *Br J Anaesth*. 2009;102:763–767.
71. Ra YS, Kim CH, Lee GY, Han JI. The analgesic effect of the ultrasound-guided transverse abdominis plane block after laparoscopic cholecystectomy. *Korean J Anesthesiol*. 2010;58:362–368.
72. Petersen PL, Stjernholm P, Kristiansen VB, et al. The beneficial effect of transversus abdominis plane block after laparoscopic cholecystectomy in day-case surgery: a randomized clinical trial. *Anesth Analg*. 2012;115:527–533.
73. Tolchard S, Davies R, Martindale S. Efficacy of the subcostal transversus abdominis plane block in laparoscopic cholecystectomy: comparison with conventional port-site infiltration. *J Anaesthesiol Clin Pharmacol*. 2012;28:339–343.
74. Chen CK, Tan PC, Phui VE, Teo SC. A comparison of analgesic efficacy between oblique subcostal transversus abdominis plane block and intravenous morphine for laparoscopic cholecystectomy. A prospective randomized controlled trial. *Korean J Anesthesiol*. 2013;64:511–516.
75. Ortiz J, Suliburk JW, Wu K, et al. Bilateral transversus abdominis plane block does not decrease postoperative pain after laparoscopic

- cholecystectomy when compared with local anesthetic infiltration of trocar insertion sites. *Reg Anesth Pain Med.* 2012;37:188–192.
76. Sinha A, Jayaraman L, Punhani D. Efficacy of ultrasound-guided transversus abdominis plane block after laparoscopic bariatric surgery: a double blind, randomized, controlled study. *Obes Surg.* 2013;23:548–553.
 77. Carney J, McDonnell JG, Ochana A, Bhinder R, Laffey JG. The transversus abdominis plane block provides effective postoperative analgesia in patients undergoing total abdominal hysterectomy. *Anesth Analg.* 2008;107:2056–2060.
 78. Atim A, Bilgin F, Kilickaya O, et al. The efficacy of ultrasound-guided transversus abdominis plane block in patients undergoing hysterectomy. *Anaesth Intensive Care.* 2011;39:630–634.
 79. Griffiths JD, Middle JV, Barron FA, Grant SJ, Popham PA, Royse CF. Transversus abdominis plane block does not provide additional benefit to multimodal analgesia in gynecological cancer surgery. *Anesth Analg.* 2010;111:797–801.
 80. Shin H-J, Kim ST, Yim KH, Lee HS, Sim JH, Shin YD. Preemptive analgesic efficacy of ultrasound-guided transversus abdominis plane block in patients undergoing gynecologic surgery via a transverse lower abdominal skin incision. *Korean J Anesthesiol.* 2011;61:413–418.
 81. Røjskjær JO, Gade E, Kiel LB, et al. Analgesic effect of ultrasound-guided transversus abdominis plane block after total abdominal hysterectomy: a randomized, double-blind, placebo-controlled trial. *Acta Obstet Gynecol Scand.* 2015;94:274–278.
 82. Gasanova I, Grant E, Way M, Rosero EB, Joshi GP. Ultrasound-guided transversus abdominal plane block with multimodal analgesia for pain management after total abdominal hysterectomy. *Arch Gynecol Obstet.* 2013;288:105–111.
 83. Hotujec BT, Spencer RJ, Donnelly MJ, et al. Transversus abdominis plane block in robotic gynecologic oncology: a randomized, placebo-controlled trial. *Gynecol Oncol.* 2015;136:460–465.
 84. Torup H, Bøgeskov M, Hansen EG, et al. Transversus abdominis plane (TAP) block after robot-assisted laparoscopic hysterectomy: a randomised clinical trial. *Acta Anaesthesiol Scand.* 2015;59:928–935.
 85. Amr YM, Amin SM. Comparative study between effect of pre- versus post-incisional transversus abdominis plane block on acute and chronic post-abdominal hysterectomy pain. *Anesth Essays Res.* 2011;5:77–82.
 86. Sivapurapu V, Vasudevan A, Gupta S, Badhe AS. Comparison of analgesic efficacy of transversus abdominis plane block with direct infiltration of local anesthetic into surgical incision in lower abdominal gynecological surgeries. *J Anaesthesiol Clin Pharmacol.* 2013;29:71–75.
 87. De Oliveira GS, Milad MP, Fitzgerald P, Rahmani R, McCarthy RJ. Transversus abdominis plane infiltration and quality of recovery after laparoscopic hysterectomy: a randomized controlled trial. *Obstet Gynecol.* 2011;118:1230–1237.
 88. Kane SM, Garcia-Tomas V, Alejandro-Rodriguez M, Astley B, Pollard RR. Randomized trial of transversus abdominis plane block at total laparoscopic hysterectomy: effect of regional analgesia on quality of recovery. *Am J Obstet Gynecol.* 2012;207:419.e1–5.
 89. Calle GA, López CC, Sánchez E, et al. Transversus abdominis plane block after ambulatory total laparoscopic hysterectomy: randomized controlled trial. *Acta Obstet Gynecol Scand.* 2014;93:345–350.
 90. Bhattacharjee S, Ray M, Ghose T, Maitra S, Layek A. Analgesic efficacy of transversus abdominis plane block in providing effective perioperative analgesia in patients undergoing total abdominal hysterectomy: a randomized controlled trial. *J Anaesthesiol Clin Pharmacol.* 2014;30:391–396.
 91. McDonnell JG, O'Donnell B, Curley G, Heffernan A, Power C, Laffey JG. The analgesic efficacy of transversus abdominis plane block after abdominal surgery: a prospective randomized controlled trial. *Anesth Analg.* 2007;104:193–197.
 92. Walter CJ, Maxwell-Armstrong C, Pinkney TD, et al. A randomised controlled trial of the efficacy of ultrasound-guided transversus abdominis plane (TAP) block in laparoscopic colorectal surgery. *Surg Endosc.* 2013;27:2366–2372.
 93. Park JS, Choi GS, Kwak KH, et al. Effect of local wound infiltration and transversus abdominis plane block on morphine use after laparoscopic colectomy: a nonrandomized, single-blind prospective study. *J Surg Res.* 2015;195:61–66.
 94. Niraj G, Kelkar A, Hart E, et al. Comparison of analgesic efficacy of four-quadrant transversus abdominis plane (TAP) block and continuous posterior TAP analgesia with epidural analgesia in patients undergoing laparoscopic colorectal surgery: an open-label, randomised, non-inferiority trial. *Anaesthesia.* 2014;69:348–355.
 95. Carney J, Finnerty O, Rauf J, Curley G, McDonnell JG, Laffey JG. Ipsilateral transversus abdominis plane block provides effective analgesia after appendectomy in children: a randomized controlled trial. *Anesth Analg.* 2010;111:998–1003.
 96. Niraj G, Searle A, Mathews M, et al. Analgesic efficacy of ultrasound-guided transversus abdominis plane block in patients undergoing open appendectomy. *Br J Anaesth.* 2009;103:601–605.
 97. Sandeman DJ, Bennett M, Dilley AV, Perczuk A, Lim S, Kelly KJ. Ultrasound-guided transversus abdominis plane blocks for laparoscopic appendectomy in children: a prospective randomized trial. *Br J Anaesth.* 2011;106:882–886.
 98. Tanggaard K, Jensen K, Lenz K, et al. A randomised controlled trial of bilateral dual transversus abdominis plane blockade for laparoscopic appendectomy. *Anaesthesia.* 2015;70:1395–1400.
 99. Petersen PL, Mathiesen O, Stjernholm P, et al. The effect of transversus abdominis plane block or local anaesthetic infiltration in inguinal hernia repair: a randomised clinical trial. *Eur J Anaesthesiol.* 2013;30:415–421.
 100. Sahin L, Sahin M, Gul R, Saricicek V, Isikay N. Ultrasound-guided transversus abdominis plane block in children: a randomised comparison with wound infiltration. *Eur J Anaesthesiol.* 2013;30:409–414.
 101. Aveline C, Le Hetet H, Le Roux A, et al. Comparison between ultrasound-guided transversus abdominis plane and conventional ilioinguinal/iliohypogastric nerve blocks for day-case open inguinal hernia repair. *Br J Anaesth.* 2011;106:380–386.
 102. Elkassabany N, Ahmed M, Malkowicz SB, Heitjan DF, Isserman JA, Ochroch EA. Comparison between the analgesic efficacy of transversus abdominis plane (TAP) block and placebo in open retropubic radical prostatectomy: a prospective, randomized, double-blinded study. *J Clin Anesth.* 2013;25:459–465.
 103. Skjelsager A, Ruhnau B, Kistorp TK, et al. Transversus abdominis plane block or subcutaneous wound infiltration after open radical prostatectomy: a randomized study. *Acta Anaesthesiol Scand.* 2013;57:502–508.
 104. Soltani Mohammadi S, Dabir A, Shoeibi G. Efficacy of transversus abdominis plane block for acute postoperative pain relief in kidney recipients: a double-blinded clinical trial. *Pain Med.* 2014;15:460–464.
 105. Freir NM, Murphy C, Mugawar M, Linnane A, Cunningham AJ. Transversus abdominis plane block for analgesia in renal transplantation: a randomized controlled trial. *Anesth Analg.* 2012;115:953–957.
 106. Gulyam Kuruba SM, Mukhtar K, Singh SK. A randomised controlled trial of ultrasound-guided transversus abdominis plane block for renal transplantation. *Anaesthesia.* 2014;69:1222–1226.
 107. Hosgood SA, Thiagarajan UM, Nicholson HF, Jayapalan I, Nicholson ML. Randomized clinical trial of transversus abdominis plane block versus placebo control in live-donor nephrectomy. *Transplantation.* 2012;94:520–525.
 108. Parikh BK, Waghmare VT, Shah VR, et al. The analgesic efficacy of ultrasound-guided transversus abdominis plane block for retroperitoneoscopic donor nephrectomy: a randomized controlled study. *Saudi J Anaesth.* 2013;7:43–47.
 109. Aniskevich S, Taner CB, Perry DK, et al. Ultrasound-guided transversus abdominis plane blocks for patients undergoing laparoscopic

- hand-assisted nephrectomy: a randomized, placebo-controlled trial. *Local Reg Anesth.* 2014;7:11–16.
110. Champaneria R, Shah L, Geoghegan J, Gupta JK, Daniels JP. Analgesic effectiveness of transversus abdominis plane blocks after hysterectomy: a meta-analysis. *Eur J Obstet Gynecol Reprod Biol.* 2013;166:1–9.
 111. Pather S, Loadsman JA, Gopalan PD, Rao A, Philp S, Carter J. The role of transversus abdominis plane blocks in women undergoing total laparoscopic hysterectomy: a retrospective review. *Aust N Z J Obstet Gynaecol.* 2011;51:544–547.
 112. Cervero F, Laird JM. Visceral pain. *Lancet.* 1999;353:2145–2148.
 113. Alvarez MP, Foley KE, Zebley DM, Fassler SA. Comprehensive enhanced recovery pathway significantly reduces postoperative length of stay and opioid usage in elective laparoscopic colectomy. *Surg Endosc.* 2015;29:2506–2511.
 114. Conaghan P, Maxwell-Armstrong C, Bedford N, et al. Efficacy of transversus abdominis plane blocks in laparoscopic colorectal resections. *Surg Endosc.* 2010;24:2480–2484.
 115. Ris F, Findlay J, Hompes R, et al. Addition of transversus abdominis plane block to patient controlled analgesia for laparoscopic high anterior resection improves analgesia, reduces opioid requirement and expedites recovery of bowel function. *Ann R Coll Surg Engl.* 2014;96:579–585.
 116. Heil JW, Nakanote KA, Madison SJ, et al. Continuous transversus abdominis plane (TAP) blocks for postoperative pain control after hernia surgery: a randomized, triple-masked, placebo-controlled study. *Pain Med.* 2014;15:1957–1964.
 117. Børglum J, Christensen AF, Hoegberg LCG, et al. Bilateral-dual transversus abdominis plane (BD-TAP) block or thoracic paravertebral block (TPVB)? Distribution patterns, dermatomal anaesthesia and la pharmacokinetics [Abstract]. *Reg Anesth Pain Med.* 2012;1: E137–E139.
 118. O'Donnell BD, McDonnell JG, McShane AJ. The transversus abdominis plane (TAP) block in open retroperic prostatectomy. *Reg Anesth Pain Med.* 2006;31:91. [Erratum in *Reg Anesth Pain Med.* 2006;31:286].
 119. Gravante G, Castri F, Araco F, Araco A. A comparative study of the transversus abdominis plane (TAP) block efficacy on post-bariatric vs aesthetic abdominoplasty with flank liposuction. *Obes Surg.* 2011;21:278–282.
 120. Araco A, Araco F, Gravante G. The transversus abdominis plane block after postbariatric abdominoplasty: reasons for pitfalls. *Am Surg.* 2013;79:1316–1319.
 121. Corvetto MA, Echevarría GC, de la Fuente N, Mosqueira L, Solari S, Altermatt FR. Comparison of plasma concentrations of levobupivacaine with and without epinephrine for transversus abdominis plane block. *Reg Anesth Pain Med.* 2012;37:633–637.
 122. Murouchi T, Iwasaki S, Yamakage M. Chronological changes in ropivacaine concentration and analgesic effects between transversus abdominis plane block and rectus sheath block. *Reg Anesth Pain Med.* 2015;40:568–571.
 123. Maeda A, Shibata SC, Kamibayashi T, Fujino Y. Continuous subcostal oblique transversus abdominis plane block provides more effective analgesia than single-shot block after gynaecological laparotomy: a randomised controlled trial. *Eur J Anaesthesiol.* 2015;32:514–515.
 124. Abdallah FW, Laffey JG, Halpern SH, Brull R. Duration of analgesic effectiveness after the posterior and lateral transversus abdominis plane block techniques for transverse lower abdominal incisions: a meta-analysis. *Br J Anaesth.* 2013;111:721–735.
 125. Abdallah FW, Chan VW, Brull R. Transversus abdominis plane block: a systematic review. *Reg Anesth Pain Med.* 2012;37:193–209.
 126. Long JB, Birmingham PK, de Oliveira GS, Schaldenbrand KM, Suresh S. Transversus abdominis plane block in children: a multicenter safety analysis of 1994 cases from the PRAN (Pediatric Regional Anesthesia Network) database. *Anesth Analg.* 2014;119:395–399.
 127. Suresh S, Taylor LJ, de Oliveira GS. Dose effect of local anesthetics on analgesic outcomes for the transversus abdominis plane (TAP) block in children: a randomized, double-blinded, clinical trial. *Paediatr Anaesth.* 2015;25:506–510.
 128. Kearns RJ, Young SJ. Transversus abdominis plane blocks; a national survey of techniques used by UK obstetric anaesthetists. *Int J Obstet Anesth.* 2011;20:103–104.
 129. Berde CB, Strichartz GR. Local anesthetics. In: *Miller's Anesthesia.* 1043. Philadelphia, PA: Elsevier; 2015.
 130. Dadure C, Sola C, Dalens B, Capdevila X. Regional anesthesia in children. In: *Miller's Anesthesia.* 2718. Philadelphia, PA: Elsevier; 2015.
 131. Griffiths JD, Le NV, Grant S, Bjorksten A, Hebbard P, Royce C. Symptomatic local anaesthetic toxicity and plasma ropivacaine concentrations after transversus abdominis plane block for caesarean section. *Br J Anaesth.* 2013;110:996–1000.
 132. Griffiths JD, Barron FA, Grant S, Bjorksten AR, Hebbard P, Royce CF. Plasma ropivacaine concentrations after ultrasound-guided transversus abdominis plane block. *Br J Anaesth.* 2010;105:853–856.
 133. Torup H, Mitchell AU, Breindahl T, Hansen EG, Rosenberg J, Møller AM. Potentially toxic concentrations in blood of total ropivacaine after bilateral transversus abdominis plane blocks; a pharmacokinetic study. *Eur J Anaesthesiol.* 2012;29:235–238.
 134. De Oliveira GS Jr, Fitzgerald PC, Marcus RJ, Ahmad S, McCarthy RJ. A dose-ranging study of the effect of transversus abdominis block on postoperative quality of recovery and analgesia after outpatient laparoscopy. *Anesth Analg.* 2011;113:1218–1225.
 135. Abdul Jalil RM, Yahya N, Sulaiman O, et al. Comparing the effectiveness of ropivacaine 0.5% versus ropivacaine 0.2% for transabdominis plane block in providing postoperative analgesia after appendectomy. *Acta Anaesthesiol Taiwan.* 2014;52:49–53.
 136. Kitayama M, Wada M, Hashimoto H, Kudo T, Takada N, Hirota K. Effects of adding epinephrine on the early systemic absorption kinetics of local anesthetics in abdominal truncal blocks. *J Anesth.* 2014;28:631–634.
 137. Ammar AS, Mahmoud KM. Effect of adding dexamethasone to bupivacaine on transversus abdominis plane block for abdominal hysterectomy: a prospective randomized controlled trial. *Saudi J Anaesth.* 2012;6:229–233.
 138. Almarakbi WA, Kaki AM. Addition of dexmedetomidine to bupivacaine in transversus abdominis plane block potentiates post-operative pain relief among abdominal hysterectomy patients: a prospective randomized controlled trial. *Saudi J Anaesth.* 2014;8:161–166.
 139. Bollag L, Richebe P, Siauly M, Ortner CM, Gofeld M, Landau R. Effect of transversus abdominis plane block with and without clonidine on post-caesarean delivery wound hyperalgesia and pain. *Reg Anesth Pain Med.* 2012;37:508–514.
 140. Feierman DE, Kronenfeld M, Gupta PM, Younger N, Logvinskiy E. Liposomal bupivacaine infiltration into the transversus abdominis plane for postsurgical analgesia in open abdominal umbilical hernia repair: results from a cohort of 13 patients. *J Pain Res.* 2014;7:477–482.
 141. Oppenheimer AJ, Fiala TGS, Oppenheimer DC. Direct transversus abdominis plane blocks with exparel during abdominoplasty [published online ahead of print November 5, 2015]. *Ann Plast Surg.* 2015.
 142. Hutchins J, Vogel RI, Ghebre R, et al. Ultrasound-guided subcostal transversus abdominis plane infiltration with liposomal bupivacaine for patients undergoing robotic-assisted hysterectomy: a retrospective study. *Int J Gynecol Cancer.* 2015;25:937–941.
 143. Polaner D, Suresh S, Cote C. Pediatric regional anesthesia. In: Cote CJ, Todres ID, Goudsouzian NG, Ryan JF, eds. *A Practice of Anesthesia for Infants and Children.* Philadelphia, PA: Saunders; 2001:651–658.
 144. Schulte-Steinberg O. *Regional Anesthesia in Children.* Norwalk, CT: Appleton & Lange/Mediglobe; 1990.

145. Epstein RH, Larijani GE, Wolfson PJ, Ala-Kokko TI, Boerner TF. Plasma bupivacaine concentrations following ilioinguinal-iliohypogastric nerve blockade in children. *Anesthesiology*. 1988;69:773–776.
146. Ross A. Pediatric regional anesthesia. In: Motoyama EK, Davis PJ, eds. *Smith's Anesthesia for Infants and Children*. Philadelphia, PA: Mosby Elsevier; 2002:492–494.
147. Dalens B. Regional anesthetic techniques. In: Bissonnette BDB, ed. *Pediatric Anesthesia—Principles and Techniques*. New York: McGraw Hill; 2002:563–565.
148. Hong J-Y, Kim WO, Koo BN, Kim YA, Jo YY, Kil HK. The relative position of ilioinguinal and iliohypogastric nerves in different age groups of pediatric patients. *Acta Anaesthesiol Scand*. 2010;54:566–570.
149. van Schoor AN, Boon JM, Bosenberg AT, Abrahams PH, Meiring JH. Anatomical considerations of the pediatric ilioinguinal/iliohypogastric nerve block. *Paediatr Anaesth*. 2005;15:371–377.
150. Weintraud M, Marhofer P, Bösenberg A, et al. Ilioinguinal/iliohypogastric blocks in children: where do we administer the local anesthetic without direct visualization? *Anesth Analg*. 2008;106:89–93.
151. Thibaut D, de la Cuadra-Fontaine JC, Bravo MP, de la Fuente R. Ilioinguinal/iliohypogastric blocks: where is the anesthetic injected? *Anesth Analg*. 2008;107:728–729.
152. Kundra P, Sivashanmugam T, Ravishankar M. Effect of needle insertion site on ilioinguinal-iliohypogastric nerve block in children. *Acta Anaesthesiol Scand*. 2006;50:622–626.
153. Jöhr M, Sossai R. Colonic puncture during ilioinguinal nerve block in a child. *Anesth Analg*. 1999;88:1051–1052.
154. Amory C, Mariscal A, Guyot E, Chauvet P, Leon A, Poli-Merol ML. Is ilioinguinal/iliohypogastric nerve block always totally safe in children? *Paediatr Anaesth*. 2003;13:164–166.
155. Vaisman J. Pelvic hematoma after an ilioinguinal nerve block for orchialgia. *Anesth Analg*. 2001;92:1048–1049.
156. Willschke H, Marhofer P, Bösenberg A, et al. Ultrasonography for ilioinguinal/iliohypogastric nerve blocks in children. *Br J Anaesth*. 2005;95:226–230.
157. Ford S, Dosani M, Robinson AJ, et al. Defining the reliability of sonoanatomy identification by novices in ultrasound-guided pediatric ilioinguinal and iliohypogastric nerve blockade. *Anesth Analg*. 2009;109:1793–1798.
158. Abrahams MS, Horn JL, Noles LM, Aziz MF. Evidence-based medicine: ultrasound guidance for truncal blocks. *Reg Anesth Pain Med*. 2010;35: S36–S42.
159. Markham SJ, Tomlinson J, Hain WR. Ilioinguinal nerve block in children. A comparison with caudal block for intra and postoperative analgesia. *Anaesthesia*. 1986;41:1098–1103.
160. Hannallah RS, Broadman LM, Belman AB, Abramowitz MD, Epstein BS. Comparison of caudal and ilioinguinal/iliohypogastric nerve blocks for control of post-orchiopepy pain in pediatric ambulatory surgery. *Anesthesiology*. 1987;66:832–834.
161. Cross GD, Barrett RF. Comparison of two regional techniques for postoperative analgesia in children following hemiotomy and orchidopexy. *Anaesthesia*. 1987;42:845–849.
162. Reid MF, Harris R, Phillips PD, Barker I, Pereira NH, Bennett NR. Day-case hemiotomy in children. A comparison of ilio-inguinal nerve block and wound infiltration for postoperative analgesia. *Anaesthesia*. 1987;42:658–661.
163. Trotter C, Martin P, Youngson G, Johnston G. A comparison between ilioinguinal-iliohypogastric nerve block performed by anaesthetist or surgeon for postoperative analgesia following groin surgery in children. *Paediatr Anaesth*. 1995;5:363–367.
164. Bærentzen F, Maschmann C, Jensen K, Belhage B, Hensler M, Børglum J. Ultrasound-guided nerve block for inguinal hernia repair: a randomized, controlled, double-blind study. *Reg Anesth Pain Med*. 2012;37:502–507.
165. Willschke H, Bösenberg A, Marhofer P, et al. Ultrasonographic-guided ilioinguinal/iliohypogastric nerve block in pediatric anesthesia: what is the optimal volume? *Anesth Analg*. 2006;102:1680–1684.
166. Smith BE, Suchak M, Siggins D, Challands J. Rectus sheath block for diagnostic laparoscopy. *Anaesthesia*. 1988;43:947–948.
167. Ferguson S, Thomas V, Lewis I. The rectus sheath block in paediatric anaesthesia: new indications for an old technique? *Paediatr Anaesth*. 1996;6:463–466.
168. Johnson D, Dixon AK, Abrahams PH. The abdominal subcutaneous tissue: computed tomographic, magnetic resonance, and anatomical observations. *Clin Anat*. 1996;9:19–24.
169. Dolan J, Lucie P, Geary T, Smith M, Kenny GN. The rectus sheath block: accuracy of local anesthetic placement by trainee anesthesiologists using loss of resistance or ultrasound guidance. *Reg Anesth Pain Med*. 2009;34: 247–250.
170. Kopacz DJ. Regional anesthesia of the trunk. In: Brown DL, ed. *Regional Anesthesia and Analgesia*. London: Saunders; 292–297.
171. Courreges P, Poddevin F, Lecoutre D. Para-umbilical block: a new concept for regional anaesthesia in children. *Paediatr Anaesth*. 1997;7:211–214.
172. de Jose Maria B, Götzens V, Mabrok M. Ultrasound-guided umbilical nerve block in children: a brief description of a new approach. *Paediatr Anaesth*. 2007;17:44–50.
173. Flack SH, Martin LD, Walker BJ, et al. Ultrasound-guided rectus sheath block or wound infiltration in children: a randomized blinded study of analgesia and bupivacaine absorption. *Paediatr Anaesth*. 2014;24: 968–973.
174. Crosbie EJ, Massiah NS, Achiampong JY, Dolling S, Slade RJ. The surgical rectus sheath block for post-operative analgesia: a modern approach to an established technique. *Eur J Obstet Gynecol Reprod Biol*. 2012;160:196–200.
175. Cornish P, Deacon A. Rectus sheath catheters for continuous analgesia after upper abdominal surgery. *ANZ J Surg*. 2007;77:84.
176. Bagenal J, Horsnell J, Loader J, West D. Rectus sheath catheterisation: a novel method of placement. *Ann R Coll Surg Engl*. 2013;95:443–444.
177. Alsaed AH, Thallaj A, Khalil N, Almutaq N, Aljazeerai A. Ultrasound-guided rectus sheath block in children with umbilical hernia: case series. *Saudi J Anaesth*. 2013;7:432–435.
178. Manassero A, Bossolasco M, Meineri M, Ugues S, Liarou C, Bertolaccini L. Spread patterns and effectiveness for surgery after ultrasound-guided rectus sheath block in adult day-case patients scheduled for umbilical hernia repair. *J Anaesthesiol Clin Pharmacol*. 2015;31:349–353.
179. Quek KH, Phua DS. Bilateral rectus sheath blocks as the single anaesthetic technique for an open infraumbilical hernia repair. *Singapore Med J*. 2014;55:e39–e41.
180. Phua DS, Phoo JW, Koay CK. The ultrasound-guided rectus sheath block as an anaesthetic in adult paraumbilical hernia repair. *Anaesth Intensive Care*. 2009;37:499–500.
181. Warner BW. Pain control after umbilical hernia repair: how difficult can we make it? *JAMA Surg*. 2013;148:713–714.
182. Rajwani KM, Butler S, Mahomed A. In children undergoing umbilical hernia repair is rectus sheath block effective at reducing post-operative pain? Best evidence topic (bet). *Int J Surg*. 2014;12:1452–1455.
183. Gurnaney HG, Maxwell LG, Kraemer FW, Goebel T, Nance ML, Ganesh A. Prospective randomized observer-blinded study comparing the analgesic efficacy of ultrasound-guided rectus sheath block and local anaesthetic infiltration for umbilical hernia repair. *Br J Anaesth*. 2011; 107:790–795.
184. Isaac LA, McEwen J, Hayes JA, Crawford MW. A pilot study of the rectus sheath block for pain control after umbilical hernia repair. *Paediatr Anaesth*. 2006;16:406–409.

185. Dingeman RS, Barus LM, Chung HK, et al. Ultrasonography-guided bilateral rectus sheath block vs local anesthetic infiltration after pediatric umbilical hernia repair: a prospective randomized clinical trial. *JAMA Surg.* 2013;148:707–713.
186. Azemati S, Khosravi MB. An assessment of the value of rectus sheath block for postlaparoscopic pain in gynecologic surgery. *J Minim Invasive Gynecol.* 2005;12:12–15.
187. Hamill JK, Liley A, Hill AG. Rectus sheath block for laparoscopic appendectomy: a randomized clinical trial. *ANZ J Surg.* 2015;85:951–956.
188. Padmanabhan J, Rohatgi A, Niaz A, Chojnowska E, Baig K, Woods WG. Does rectus sheath infusion of bupivacaine reduce postoperative opioid requirement? *Ann R Coll Surg Engl.* 2007;89:229–232.
189. Mugita M, Kawahara R, Tamai Y, et al. Effectiveness of ultrasound-guided transversus abdominis plane block and rectus sheath block in pain control and recovery after gynecological transumbilical single-incision laparoscopic surgery. *Clin Exp Obstet Gynecol.* 2014;41:627–632.
190. Breschan C, Jost R, Stettner H, et al. Ultrasound-guided rectus sheath block for pyloromyotomy in infants: a retrospective analysis of a case series. *Paediatr Anaesth.* 2013;23:1199–1204.
191. Bailie K, Cullen A, Eggleton A. Ultrasound-guided rectus sheath blocks for open pyloromyotomy: a chance to turn down the gas. *Paediatr Anaesth.* 2014;24:356–357.
192. Kumar A, Wilson GA, Engelhardt TE. Ultrasound guided rectus sheath blockade compared to peri-operative local anesthetic infiltration in infants undergoing supraumbilical pyloromyotomy. *Saudi J Anaesth.* 2014;8:229–232.
193. Malchow R, Jaeger L, Lam H. Rectus sheath catheters for continuous analgesia after laparotomy—without postoperative opioid use. *Pain Med.* 2011;12:1124–1129.
194. Bakshi S, Mapari A, Paliwal R. Ultrasound-guided rectus sheath catheters: a feasible and effective, opioid-sparing, post-operative pain management technique: a case series. *Indian J Anaesth.* 2015;59:118–120.
195. Dutton TJ, McGrath JS, Daugherty MO. Use of rectus sheath catheters for pain relief in patients undergoing major pelvic urological surgery. *BJU Int.* 2014;113:246–253.
196. Godden AR, Marshall MJ, Grice AS, Daniels IR. Ultrasonography guided rectus sheath catheters versus epidural analgesia for open colorectal cancer surgery in a single centre. *Ann R Coll Surg Engl.* 2013;95:591–594.
197. Tudor E, Yang W, Brown R, Mackey PM. Rectus sheath catheters provide equivalent analgesia to epidurals following laparotomy for colorectal surgery. *Ann R Coll Surg Engl.* 2015;97:530–533.
198. Wilkinson KM, Krige A, Brearley SG, et al. Thoracic Epidural analgesia versus Rectus Sheath Catheters for open midline incisions in major abdominal surgery within an enhanced recovery programme (TERSC): study protocol for a randomised controlled trial. *Trials.* 2014;15:400.
199. Blanco R. TAP block under ultrasound guidance: the description of a “no pops” technique [Abstract]. *Reg Anesth Pain Med.* 2007;32:S1–S130.
200. Chakraborty A, Goswami J, Patro V. Ultrasound-guided continuous quadratus lumborum block for postoperative analgesia in a pediatric patient. *A A Case Rep.* 2015;4:34–36.
201. Elsharkawy H. Ultrasound-guided quadratus lumborum block: how I do it. *Am Soc Reg Anesth Pain Med Newsl.* 2015:36–42.
202. Skandalakis PN, Zoras O, Skandalakis JE, Mirilas P. Transversalis, endoabdominal, endothoracic fascia: who's who? *Am Surg.* 2006;72:16–18.
203. Kadam VR. Ultrasound-guided quadratus lumborum block as a postoperative analgesic technique for laparotomy. *J Anaesthesiol Clin Pharmacol.* 2013;29:550–552.
204. Kadam VR. Ultrasound guided quadratus lumborum block or posterior transversus abdominis plane block catheter infusion as a postoperative analgesic technique for abdominal surgery. *J Anaesthesiol Clin Pharmacol.* 2015;31:130–131.
205. Baidya DK, Maitra S, Arora MK, Agarwal A. Quadratus lumborum block: an effective method of perioperative analgesia in children undergoing pyeloplasty. *J Clin Anesth.* 2015;27:694–696.
206. Shaaban M, Esa WA, Maheshwari K, Elsharkawy H, Soliman LM. Bilateral Continuous Quadratus Lumborum Block for Acute Postoperative Abdominal Pain as a Rescue After Opioid-Induced Respiratory Depression. *A A Case Rep.* 2015;5:107–111.
207. Blanco R, Ansari T, Girgis E. Quadratus lumborum block for postoperative pain after caesarean section: a randomised controlled trial. *Eur J Anaesthesiol.* 2015;32:812–818.
208. Adhikary SD, El-Boghdady K, Nasrallah Z, Sarwani N, Nixon AM, Chin KJ. A radiologic and anatomic assessment of injectate spread following transmuscular quadratus lumborum block in cadavers. *Anaesthesia.* 2017;72:73–79.
209. Carline L, McLeod GA, Lamb C. A cadaver study comparing spread of dye and nerve involvement after three different quadratus lumborum blocks. *Br J Anaesth.* 2016;117:387–394.
210. Ueshima H, Yoshiyama S, Otake H. The ultrasound-guided continuous transmuscular quadratus lumborum block is an effective analgesia for total hip arthroplasty. *J Clin Anesth.* 2016;31:35.
211. Hockett MM, Hembrador S, Lee A. Continuous quadratus lumborum block for postoperative pain in total hip arthroplasty: a case report. *A A Case Rep.* 2016;7:129–131.
212. Parras T, Blanco R. Randomised trial comparing the transversus abdominis plane block posterior approach or quadratus lumborum block type I with femoral block for postoperative analgesia in femoral neck fracture, both ultrasound-guided. *Rev Esp Anestesiol Reanim.* 2016;63:141–148.
213. Elsharkawy H. Quadratus lumborum block with paramedian sagittal oblique (subcostal) approach. *Anaesthesia.* 2016;71:241–242.
214. El-Boghdady K, Elsharkawy H, Short A, Chin KJ. Quadratus lumborum block nomenclature and anatomical considerations. *Reg Anesth Pain Med.* 2016;41:548–549.
215. Lee S, Goetz T, Gharapetian A. Unanticipated motor weakness with ultrasound-guided transversalis fascia plane block. *A A Case Rep.* 2015;5:124–125.
216. American Society of Anesthesiologists Task Force on Obstetric Anesthesia. Practice guidelines for obstetric anesthesia: an updated report by the American Society of Anesthesiologists Task Force on Obstetric Anesthesia. *Anesthesiology.* 2007;106:843–863.
217. Meylan N, Elia N, Lysakowski C, Tramèr MR. Benefit and risk of intrathecal morphine without local anaesthetic in patients undergoing major surgery: meta-analysis of randomized trials. *Br J Anaesth.* 2009;102:156–167.
218. Angle PJ, Halpern SH, Leighton BL, Szalai JP, Gnanendran K, Kronberg JE. A randomized controlled trial examining the effect of naproxen on analgesia during the second day after cesarean delivery. *Anesth Analg.* 2002;95:741–745.
219. Elia N, Lysakowski C, Tramèr MR. Does multimodal analgesia with acetaminophen, nonsteroidal antiinflammatory drugs, or selective cyclooxygenase-2 inhibitors and patient-controlled analgesia morphine offer advantages over morphine alone? Meta-analyses of randomized trials. *Anesthesiology.* 2005;103:1296–1304.
220. Wrench IJ, Sanghera S, Pinder A, Power L, Adams MG. Dose response to intrathecal diamorphine for elective caesarean section and compliance with a national audit standard. *Int J Obstet Anesth.* 2007;16:17–21.
221. Carvalho B. Respiratory depression after neuraxial opioids in the obstetric setting. *Anesth Analg.* 2008;107:956–961.

222. Ilett KF, Kristensen JH. Drug use and breastfeeding. *Expert Opin Drug Saf.* 2005;4:745–768.
223. Hale TW. Anesthetic medications in breastfeeding mothers. *J Hum Lact.* 1999;15:185–194.
224. Matsota PK, Markantonis SL, Fousteri MZ, et al. Excretion of ropivacaine in breast milk during patient-controlled epidural analgesia after cesarean delivery. *Reg Anesth Pain Med.* 2009;34:126–129.
225. American Academy of Pediatrics Committee on Drugs. Transfer of drugs and other chemicals into human milk. *Pediatrics.* 2001;108:776–789.
226. Montgomery A, Hale TW, Academy Of Breastfeeding Medicine. ABM clinical protocol #15: analgesia and anesthesia for the breastfeeding mother, revised 2012. *Breastfeed Med.* 2012;7:547–553.
227. McMorro RC, Ni Mhuirchearthaigh RJ, Ahmed KA, et al. Comparison of transversus abdominis plane block vs spinal morphine for pain relief after caesarean section. *Br J Anaesth.* 2011;106:706–712.
228. Kanazi GE, Aouad MT, Abdallah FW, et al. The analgesic efficacy of subarachnoid morphine in comparison with ultrasound-guided transversus abdominis plane block after cesarean delivery: a randomized controlled trial. *Anesth Analg.* 2010;111:475–481.
229. Loane H, Preston R, Douglas MJ, Massey S, Papsdorf M, Tyler J. A randomized controlled trial comparing intrathecal morphine with transversus abdominis plane block for post-cesarean delivery analgesia. *Int J Obstet Anesth.* 2012;21:112–118.
230. Mishriky BM, George RB, Habib AS. Transversus abdominis plane block for analgesia after cesarean delivery: a systematic review and meta-analysis. *Can J Anaesth.* 2012;59:766–778.
231. Tan TT, Teoh WH, Woo DC, Ocampo CE, Shah MK, Sia AT. A randomised trial of the analgesic efficacy of ultrasound-guided transversus abdominis plane block after caesarean delivery under general anaesthesia. *Eur J Anaesthesiol.* 2012;29:88–94.
232. Eslamian L, Jalili Z, Jamal A, Marsoosi V, Movafegh A. Transversus abdominis plane block reduces postoperative pain intensity and analgesic consumption in elective cesarean delivery under general anesthesia. *J Anesth.* 2012;26:334–338.
233. Baaj JM, Alsatl RA, Majaj HA, Babay ZA, Thallaj AK. Efficacy of ultrasound-guided transversus abdominis plane (TAP) block for postcesarean section delivery analgesia—a double-blind, placebo-controlled, randomized study. *Middle East J Anaesthesiol.* 2010;20:821–826.
234. Belavy D, Cowlshaw PJ, Howes M, Phillips F. Ultrasound-guided transversus abdominis plane block for analgesia after caesarean delivery. *Br J Anaesth.* 2009;103:726–730.
235. McDonnell JG, Curley G, Carney J, et al. The analgesic efficacy of transversus abdominis plane block after cesarean delivery: a randomized controlled trial. *Anesth Analg.* 2008;106:186–191.
236. Costello JF, Moore AR, Wiczorek PM, Macarthur AJ, Balki M, Carvalho JC. The transversus abdominis plane block, when used as part of a multimodal regimen inclusive of intrathecal morphine, does not improve analgesia after cesarean delivery. *Reg Anesth Pain Med.* 2009;34:586–589.
237. Lee AJ, Palte HD, Chehade JM, Arheart KL, Ranasinghe JS, Penning DH. Ultrasound-guided bilateral transversus abdominis plane blocks in conjunction with intrathecal morphine for postcesarean analgesia. *J Clin Anesth.* 2013;25:475–482.
238. Singh S, Dhir S, Marmai K, Rehous S, Silva M, Bradbury C. Efficacy of ultrasound-guided transversus abdominis plane blocks for post-cesarean delivery analgesia: a double-blind, dose-comparison, placebo-controlled randomized trial. *Int J Obstet Anesth.* 2013;22:188–193.
239. McKeen DM, George RB, Boyd JC, Allen VM, Pink A. Transversus abdominis plane block does not improve early or late pain outcomes after cesarean delivery: a randomized controlled trial. *Can J Anaesth.* 2014;61:631–640.
240. Cánovas L, López C, Castro M, Rodríguez AB, Pérez L. Contribution to post-caesarean analgesia of ultrasound-guided transversus abdominis plane block [in Spanish]. *Rev Esp Anesthesiol Reanim.* 2013;60:124–128.
241. Telnes A, Skogvoll E, Lonnée H. Transversus abdominis plane block vs. wound infiltration in caesarean section: a randomised controlled trial. *Acta Anaesthesiol Scand.* 2015;59:496–504.
242. Chandon M, Bonnet A, Burg Y, et al. Ultrasound-guided Transversus Abdominis plane block versus continuous wound infusion for post-caesarean analgesia: a randomized trial. *PLoS One.* 2014;9:e103971.
243. Aydogmus M, Sinikoglu S, Naki M, Ocak N, Sanli N, Alagol A. Comparison of analgesic efficiency between wound site infiltration and ultra-sound-guided transversus abdominis plane block after cesarean delivery under spinal anaesthesia. *Hippokratia.* 2014;18:28–31.
244. Bunting P, McConachie I. Ilioinguinal nerve blockade for analgesia after caesarean section. *Br J Anaesth.* 1988;61:773–775.
245. Bell EA, Jones BP, Olufolabi AJ, et al. Iliohipogastric-ilioinguinal peripheral nerve block for post-cesarean delivery analgesia decreases morphine use but not opioid-related side effects. *Can J Anaesth.* 2002;49:694–700.
246. Ganta R, Samra SK, Maddineni VR, Furness G. Comparison of the effectiveness of bilateral ilioinguinal nerve block and wound infiltration for postoperative analgesia after caesarean section. *Br J Anaesth.* 1994;72:229–230.
247. Huffnagle HJ, Norris MC, Leighton BL, Arkoosh VA. Ilioinguinal iliohypogastric nerve blocks—before or after cesarean delivery under spinal anesthesia? *Anesth Analg.* 1996;82:8–12.
248. Vallejo MC, Steen TL, Cobb BT, et al. Efficacy of the bilateral ilioinguinal-iliohypogastric block with intrathecal morphine for postoperative cesarean delivery analgesia. *ScientificWorldJournal.* 2012;2012:107316.
249. Wolfson A, Lee AJ, Wong RP, Arheart KL, Penning DH. Bilateral multi-injection iliohypogastric-ilioinguinal nerve block in conjunction with neuraxial morphine is superior to neuraxial morphine alone for postcesarean analgesia. *J Clin Anesth.* 2012;24:298–303.
250. Abdallah FW, Halpern SH, Margarido CB. Transversus abdominis plane block for postoperative analgesia after caesarean delivery performed under spinal anaesthesia? A systematic review and meta-analysis. *Br J Anaesth.* 2012;109:679–687.
251. Onishi Y, Kato R, Okutomi T, Tabata K, Amano K, Unno N. Transversus abdominis plane block provides postoperative analgesic effects after cesarean section: additional analgesia to epidural morphine alone. *J Obstet Gynaecol Res.* 2013;39:1397–1405.
252. Bollag L, Richebe P, Ortner C, Landau R. Transversus abdominis plane catheters for post-cesarean delivery analgesia: a series of five cases. *Int J Obstet Anesth.* 2012;21:176–180.
253. Mei W, Jin C, Feng L, et al. Bilateral ultrasound-guided transversus abdominis plane block combined with ilioinguinal-iliohypogastric nerve block for cesarean delivery anesthesia. *Anesth Analg.* 2011;113:134–137.
254. Gucev G, Yasui GM, Chang TY, Lee J. Bilateral ultrasound-guided continuous ilioinguinal-iliohypogastric block for pain relief after cesarean delivery. *Anesth Analg.* 2008;106:1220–1222.
255. Coffman JC, Fiorini K, Small RH. Ilioinguinal-iliohypogastric block used to rescue ineffective transversus abdominis plane block after cesarean delivery. *Int J Obstet Anesth.* 2015;24:394–395.
256. Kato J, Gokan D, Hirose N, Iida R, Suzuki T, Ogawa S. Appearance of burning abdominal pain during cesarean section under spinal anesthesia in a patient with complex regional pain syndrome: a case report. *Pain Med.* 2013;14:293–296.
257. Templeton T. Rectus block for postoperative pain relief. *Reg Anesth.* 1993;18:258–260.

258. Mirza F, Carvalho B. Transversus abdominis plane blocks for rescue analgesia following cesarean delivery: a case series. *Can J Anaesth*. 2013; 60:299–303.
259. Cowlshaw P, Belavy D. Transversus abdominis plane block for neuropathic pain. *Reg Anesth Pain Med*. 2009;34:183.
260. Randall IM, Costello J, Carvalho JC. Transversus abdominis plane block in a patient with debilitating pain from an abdominal wall hematoma following cesarean delivery. *Anesth Analg*. 2008;106:1928.
261. Miller EC, Szeto M, Boet S. Unilateral Transversus abdominis plane block catheter for the treatment of abdominal wall pain in pregnancy: a case report. *Reg Anesth Pain Med*. 2015;40:720–722.
262. Farooq M, Carey M. A case of liver trauma with a blunt regional anesthesia needle while performing transversus abdominis plane block. *Reg Anesth Pain Med*. 2008;33:274–275.
263. Frigon C, Mai R, Valois-Gomez T, Desparmet J. Bowel hematoma following an iliohypogastric-ilioinguinal nerve block. *Paediatr Anaesth*. 2006;16:993–996.
264. Yuen PM, Ng PS. Retroperitoneal hematoma after a rectus sheath block. *J Am Assoc Gynecol Laparosc*. 2004;11:448.
265. Lancaster P, Chadwick M. Liver trauma secondary to ultrasound-guided transversus abdominis plane block. *Br J Anaesth*. 2010;104:509–510.
266. Lipp AK, Woodcock J, Hensman B, Wilkinson K. Leg weakness is a complication of ilio-inguinal nerve block in children. *Br J Anaesth*. 2004; 92:273–274.
267. Shivashanmugam T, Kundra P, Sudhakar S. Iliac compartment block following ilioinguinal iliohypogastric nerve block. *Paediatr Anaesth*. 2006;16:1084–1086.
268. Ghani KR, McMillan R, Paterson-Brown S. Transient femoral nerve palsy following ilio-inguinal nerve blockade for day case inguinal hernia repair. *J R Coll Surg Edinb*. 2002;47:626–629.
269. Walker G. Transversus abdominis plane block: a note of caution! *Br J Anaesth*. 2010;104:265.
270. Manatakis DK, Stamos N, Agalinos C, Karvelis MA, Gkiaourakis M, Davides D. Transient femoral nerve palsy complicating “blind” transversus abdominis plane block. *Case Rep Anesthesiol*. 2013; 2013:874215.
271. Bern S, Weinberg G. Local anesthetic toxicity and lipid resuscitation in pregnancy. *Curr Opin Anaesthesiol*. 2011;24:262–267.
272. Wada M, Kitayama M, Hashimoto H, et al. Brief reports: plasma ropivacaine concentrations after ultrasound-guided rectus sheath block in patients undergoing lower abdominal surgery. *Anesth Analg*. 2012;114: 230–232.