



Available Online at

<http://www.ijcpa.in>

July-September 2020

DOI: <http://dx.doi.org/10.21276/ijcpa>

International Journal of
CHEMICAL AND PHARMACEUTICAL
ANALYSIS

eISSN: 2348-0726; pISSN: 2395-2466

Review Article

Volume-7

Issue-4

Article ID: 0043

LITHOPEDIIONS: A CASE REPORT AND REVIEW

Nilesh K. Gorde^{1,*}, Sandeep Waghulde¹, Tushar A. Deshmukh², Ajay A. Kharche¹, Amol Chandekar¹, Bharat Tekade³, Mohan Kale⁴

¹Assistant Professor, Konkan Gyanpeeth Rahul Dharkar College of Pharmacy and Research Institute, Karjat, Dist: Raigad-410201, India.

²Principal & Professor, Arunamai College of Pharmacy, Mamurabad, Dist: Jalgaon (Maharashtra), India.

³Professor, Konkan Gyanpeeth Rahul Dharkar College of Pharmacy & Research Institute, Karjat, Dist : Raigad-410201, India.

⁴Principal and Professor, Konkan Gyanpeeth Rahul Dharkar College of Pharmacy & Research Institute, Karjat, Dist: Raigad-410201, India.

*Corresponding Author: Email: nileshgorde83@gmail.com

Received: 19 July 2020/ Revised: 25 August 2020 / Accepted: 21 September 2020 / Available online 30 September 2020

ABSTRACT

The word Lithopedion is derived from the Greek word Lithos meaning stone and pedion meaning child thus implying a foetus that has become stony. Diagnosis confirmed by plain abdominal X-ray and computed tomography and patient consequently undergone laparotomy. Once the diagnosis of an abdominal pregnancy is made, surgical intervention is necessary because of the high mortality and morbidity of the advanced pregnancy. Other causes of death are infections, disseminated intravascular coagulopathy, pulmonary embolism and fistulae caused by penetration of fetal bones. Patient ages vary between 30 and 100 years, while duration of lithopedion withholding ranges from 4 to 60 years. Lithopedion may come about from 14 weeks of gestation to full term. Occurrence of a lithopedion is rarer than ever and it is usually found only where modern health services are unavailable. We presented some interesting cases of lithopedion seen all over the world and that discovered incidentally on abdominal x-ray, at surgery, or autopsy.

Keywords – Lithopedion, Stone boy, X-ray

1. INTRODUCTION

A lithopedion – also spelled lithopaedion or lithopedion (Ancient Greek: λίθος = stone; Ancient Greek: παιδίον = small child, infant), or stone baby, is a unusual phenomenon which occurs most generally when a fetus dies at some stage in an abdominal pregnancy, is too large to be reabsorbed by the body, furthermore calcifies on the outside as part of a maternal foreign body reaction, shielding the mother's body from the dead tissue of the fetus and preventing infection¹. The occurrence of abdominal pregnancy is 1:11,000 pregnancies and its incidence being accounted as 1.5–2.0% of all ectopic pregnancies, and the occurrence of ectopic pregnancy is 0.3–1.0% of the entirety of gestations. As a consequence, less than 300 cases have been depicted in 400 years of world medical literature^{2–6}.

In 1881, Kuchenmeister⁷ recognized that calcification may include either the foetus, membranes or the placenta or a mix of any of the above. Giving the following classification:

1. Lithokelyphos (stone sheath), layers alone get calcified shaping a hard shell encompassing the embryo. The embryo may experience minor change just, or might be totally skeletonised, yet isn't worried during the time spent calcification.
2. Lithokelyphopedion (stone sheath child), in which independently the layers and the baby are calcified.
3. True lithopedion (stone child), in which the foetus is invaded with calcium salts and calcification of the membranes is insignificant. The progress of lithopedion arises under specific conditions: (1) extra-uterine pregnancy; (2) failure of medicinal discovery (3) the egg must be sterile; (4) fetal demise following 3 months of pregnancy; (5) presence of conditions favorable for the deposition of calcium ^{8,9}.

Tien gathered 114 instances of lithopedions. 74 of them were the consequence of tubal pregnancy and 13 started in ovarian pregnancy. Following tubal or ovarian gestational sac crack, the hatchling wound up in the guts, at long last getting to be calcified. Eight lithopedions were the consequence of essential stomach pregnancy, and 5 patients began in the horn of a bicornute uterus. ¹⁰.

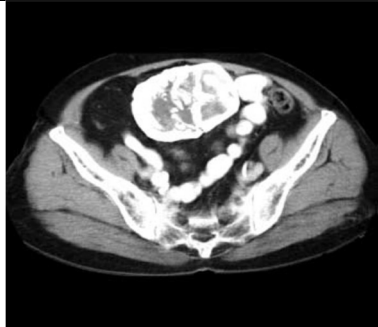

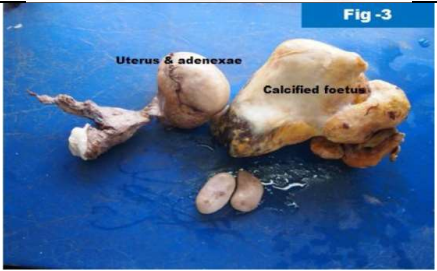


Patient ages fluctuate in the vicinity of 30 and 100 years, while length of lithopedion retention ranges from 4 to 60 years. Lithopedion may occur from 14 weeks of gestation to full term. Sluggish local blood flow, a sterile fetus and conditions helpful for calcium deposition are all around perceived factors in the pathogenesis. It is regularly normal that stone baby to stay undiscovered for a considerable length of time and discovered unexpectedly when taking plane films or ultrasonography for different reasons. ^{3,5}. A lithopedion is here and there identified as a discernable stomach or pelvic mass on a routine physical examination; however, most cases are unexpectedly found amid surgery or on radiographic investigations of the belly or pelvis ⁶. Complications after lithopedion development incorporate volvulus of the cecum ¹¹, intestinal obstruction ¹², and abscess formation ¹³.

Symptomatology is all the time nonspecific and of a chronic nature. In spite of the fact that side effects, for example, pelvic pain, abdominal tenderness and compressive indications to the urinary bladder and rectum may happen, most cases stay asymptomatic for long period and represent to coincidental discoveries on imaging studies, surgery or necropsy ¹⁴. A plain X-ray is a valuable and economical screening apparatus that for the most part affirms the conclusion. Further examinations, for example, computed tomography (CT), magnetic resonance imaging (MRI) and barium enema are likewise valuable ^{15,16}. Once the diagnosis of an abdominal pregnancy is made, surgical intercession is vital as a result of the high mortality and morbidity of the advanced pregnancy, and the methotrexate treatment is contraindicated because of the potential sepsis and death¹⁷. The mortality chance from abdominal pregnancy is higher than that of tubal pregnancy, and intra-uterine pregnancy. In these patients the mortality is generally due to intra- abdominal bleeding, which leads to anemia. Different reasons for death are infections, pulmonary embolism, disseminated intravascular coagulopathy and fistulae caused by penetration of fetal bones ¹⁸.

2. CASE STUDIES

Today the incidence of a lithopedion is uncommon than ever; it is unidentified among women who receive adequate prenatal care or usual medical examinations, so it is usually found only where modern health services are not available or when a gross error has been made. The majority cases of lithopedion are identified incidentally on abdominal x-ray, at surgery, or autopsy. A few cases of lithopedion are reported in the table 1.

Table 1: Reported Cases

Sr. No.	Age of patient	Age of Lithopedion	Country	History	Lithopedion
1	63	40	Korea	suffered from urinary frequency and lower abdominal discomfort and was recommended for further evaluation of the mass at a local clinic ¹⁹ .	
2	50	28	India	complain of intermittent dull aching pain in the right iliac fossa for 28 years ²⁰ .	
3	70	35	India	complaining of stomach pain for some time ²¹ .	
4	54	09	Jamaica	Vaginal bleeding lasted for as long as 15 to 21 days. It was accompanied by considerably lower abdominal pain and was frequently quite profuse, enough to soak the newspapers with which she attempted to control it. ²²	
5	20	02	India	Complaints of inability to conceive. Her menstrual cycles were regular except for a single missed cycle which occurred about 18 months back. ²³	


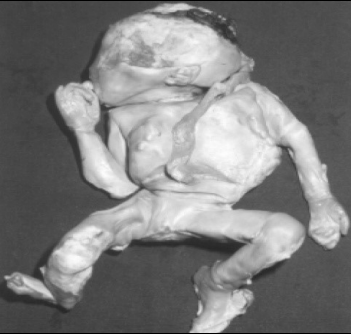



Sr. No.	Age of patient	Age of Lithopedion	Country	History	Lithopedion
6	32	02	Africa	With a history 2 years ago of a miscarriage pregnancy at 5 months of gestation was admitted urgently for abdominal pain lasting for 72 hours. The miscarriage was not followed by any operation to empty the uterus as the patient lived in a village located 320Km from our hospital and away from any qualified health center. ²⁴	
7	40	18	Brazil	The patient reported regular abdominal growth and healthy fetal activity from a pregnancy that happened 18 years earlier. She had never done pre-natal follow-up. In the third trimester, she had started to feel strong cramps in the lower abdomen at the same time that fetal activity disappeared. She had not looked for medical assistance and some weeks later she had eliminated a dark red mass through the vagina with a placental appearance ²⁵ .	
8	76	50	China	Experienced an intractable abdominal pain at the age of 26. She was told by her physician of the presence of a benign tumor in the pelvic cavity. Surgical operation was suggested but she re fused. The abdominal pain disappeared two months later without any medical or surgical management, and it had never appeared again. Doctors believe that an abdominal pregnancy developed at that time. The lithopedion was therefore formed and retained in the maternal peritoneal cavity for 50 years ²⁶ .	
9	51	Not known	Africa	Female presented to the Accident and Emergency department with acute onset of expressive aphasia. The patient has a history of hypertension and previous cerebrovascular accident. On examination, she was fully conscious and had a facial nerve palsy, and hemiplegia on the right side. Examination of the abdomen revealed a bony-hard mass extending to the level of the umbilicus. ²⁷	

Fig. 2. Plain abdominal X-ray showing a well-formed foetus with matured skeleton in the abdomen.

Sr. No.	Age of patient	Age of Lithopedion	Country	History	Lithopedion
10	69	25	Africa	Woman with 3 previous uneventful term pregnancies and a background history of peripheral vascular disease presented to our emergency room with a gangrenous left foot. She had been referred from a rural area of the Northern Cape. Physical examination confirmed dry gangrene up to the mid-tibial level and a hard painless solid mass in the right upper quadrant. Pelvic and rectal examinations were unremarkable. ²⁸	

3. DISCUSSION

Sometimes an abdominal pregnancy undergoes calcification instead of being absorbed, resulting in a lithopedion, but this is extremely rare and difficult to diagnose and manage.

If the dead fetus is too large to be absorbed by the mother body it becomes a foreign body to mothers immune system to protect itself from the possible infection the mothers body will encase the fetus in calciferous substance and the fetus is gradually mummified resulting in a stone baby. Lithopedion may occur from 14 weeks of gestation to full term. It is often usual that stone baby to remain undiagnosed for decades and found incidentally when taking plane films or ultrasonography for various other reasons. Patient ages vary between 30 and 100 years, while duration of lithopedion retention ranges from 4 to 60 years. Our finding correlates with published reports, which suggest that advanced abdominal pregnancies are invariably linked to low socioeconomic status and poor access to antenatal care^{14,16}. The risk factors for ectopic pregnancies in general are infertility, previous pelvic infection, congenital anomalies, endometriosis, previous ectopic pregnancy and tubal surgery²⁹. Some cases of retained abdominal pregnancy may remain stable without surgical intervention, while others may need early surgical intervention after thorough consideration of the morbidity and the risk of complications if not treated accordingly. It is also known that there is an increase in morbidity when surgery is performed in elderly patients, rendering it necessary to evaluate the risk/benefit relationship of an operative approach in these cases¹⁹. The description of the lithopedion remains a harsh reminder of the poor antenatal care that currently prevails in the developing world.

4. CONCLUSION

Discoveries of lithopedion implies lack of sufficient medical attention or to a certain extent some serious mistakes in medical findings. The surgical management is unproblematic but the lithopedion remains an entity which is supposed to be completely disappear with the antenatal consultation and the early diagnosis and appropriate treatment of abdominal pregnancy.

REFERENCES

1. Perper JA. Chapter III: Time of Death and Changes after Death. Part 1: Anatomical Considerations. In: Spitz, W.U. & Spitz, D.J. (eds): Spitz and Fisher's Medicolegal Investigation of Death. Guideline for the Application of Pathology to Crime Investigations (Fourth edition), Charles C. Thomas, 2006, pp.: 871-27; Springfield, Illinois.
2. Costa SD, Presley J, Bastert G. Advanced abdominal pregnancy. *Obstetrical & Gynecological Survey*, 1991, 46: 515-25.
3. Frayer CA, Hibbert ML. Abdominal pregnancy in a 67-year-old woman undetected for 37 years: a case report. *Journal of Reproductive Medicine*, 1999, 44: 633-5.
4. Irick MB, Kitsos CN, O'Leary JA. Therapeutic aspects in the management of a lithopedion. *American Surgeon*, 1970, 36: 232-4.
5. Spiritos NM, Eisenkop SM, Mishell DR. Lithokelyphos: a case report and literature review. *Journal of Reproductive Medicine*, 1987, 32: 43-6.
6. Fagan CJ, Schreiber MH, Amparo EG. Lithopedion: stone baby. *Archives of Surgery*, 1980, 115: 764-6.
7. Kuchenmeister F. *Arch. Gynaek*, 1881, 17: 153.
8. Emmanuel G, Peter AG. A true lithopedion: report of a case. *Obstetrics & Gynecology*, 1966, 28: 12-4.
9. Elechi EN, Elechi GN. Mummified and calcified abdominal pregnancy (lithopedion). *Trop Doctor*, 1995, 25: 125-6.
10. Tien DSP. Lithopedion: general discussion and case report. *Chinese Medical Journal*, 1949, 67: 451-60.
11. Glass BA, Abramson PD. Volvulus of cecum due to lithopedion. *American Journal of Surgery*, 1953, 86: 348-52.
12. Zaheer SA. Acute intestinal obstruction caused by lithopedion. *British Journal of Surgery*, 1971, 58: 401-2.
13. Jain T, Eckert LO. Abdominal pregnancy with lithopedion formation presenting as a pelvic abscess. *Obstetrics & Gynecology*, 2000, 95, 808-10.
14. Lachman N, Satyapal KS, Kalideen JM, Moodley TR. Lithopedion: a case report. *Clinical Anatomy*, 2001, 14: 52-4.
15. N'Gbesso RD, Coulibaly A, Quenum G. A rare etiology of abdominal calcifications: lithopedion. *Journal of Radiology*, 1998, 79: 683-686.
16. Ede J, Sobnach S, Castillo F, Bhyat A, Corbett JH. The lithopedion – an unusual cause of an abdominal Mass. *South African Journal of Surgery*, 2011, 49(3): 140-1.
17. Berek JS, Adashi EY, Hillard PA. *Novak's Gynecology*. In: Stoval TG, McCord ML, eds. Early pregnancy loss and ectopic pregnancy. 12th ed. Baltimore: Williams and Wilkins, 1996: 487-523.
18. Kun KY, Wong PY, Ho MW. Abdominal pregnancy presenting as a missed abortion at 16 weeks' gestation. *Hong Kong Medical Journal*, 2000, 6(4): 425-427.
19. Kim SM, Park S, Lee TS. Old Abdominal Pregnancy Presenting as an Ovarian Neoplasm. *Journal of Korean Medical Science*, 2002, 17: 274-5.
20. Banabihari M. Lithopedion: A Case Report Presenting with Intestinal Obstruction and Review of Literature. *International Journal of Scientific Study*, 2016, 3(10): 177-179.
21. Saritha S, Gouri. Lithopaedion: A case report. *International Journal of Anatomy and Research*, 2014, 2(1): 283-86.
22. Chase AL. Lithopedion. *Canadian Medical Association Journal*, 1968, 99(5): 226-30.
23. Robin M, Banashree N, Mangal PK. Lithopedion diagnosed during infertility workup: a case report. *SpringerPlus*, 2014, 3: 151.
24. Allode SA, Mensah E, Dossou FM. Acute Small Bowel Obstruction due to Intra-Abdominal Lithopedion, *Surgery*, 2012, 2: 1-2.
25. Passini R, Knobel R, Parpinelli MA, et. al. Calcified abdominal pregnancy with eighteen years of evolution: case report. *São Paulo Medical Journal*, 2000, 118 (6): 192-4.
26. Chang CM, Yu KJ, Lin JJ, Sheu MH. Lithopedion. *Chinese Medical Journal*, 2001, 64: 369-372.
27. Nkabinde CM, Motswaledi MH. Lithopedion in a Patient with Hypertensive and Cerebrovascular Accident. *International Journal of Case Reports in Medicine*, 2014: 1-5.
28. Ede J, Sobnach S, Castillo F, MD, Bhyat A. The lithopedion – an unusual cause of an abdominal mass. *South African Journal of Surgery*; 2011, 49(3): 140-41.
29. Cotter A, Izquierdo L, Heredia F. (2000). Abdominal pregnancy [monograph on the internet] *The Fetus.net*, [2000-10-22-11] Available from: <http://www.thefetus.net/page.php?id=1032>.