

## Treatment of inferior turbinate pathology: a review and critical evaluation of the different techniques\*

Myrthe K.S. Hol and Egbert H. Huizing

Department of Otorhinolaryngology, University Medical Centre Utrecht, the Netherlands

### SUMMARY

*At least 13 surgical techniques have been used over the past 130 years to treat hypertrophy of the inferior turbinate. These methods are reviewed and critically analyzed in this article. Our review of the literature revealed a serious lack of qualified studies. Research meeting the criteria for a prospective comparative randomized surgical study is extremely rare. In our opinion, the purpose of surgically reducing the inferior turbinates should be to diminish complaints while preserving function. From that perspective, it seems that electrocautery, chemocautery, (subtotal) turbinectomy, cryosurgery, and laser surface surgery should not be used, as these techniques are too destructive. Intratubinal turbinate reduction (intratubinal turbinoplasty) would seem to be the method of choice.*

*Key words: inferior turbinate pathology, treatment, electrocautery, turbinectomy, turbinoplasty, laser surgery.*

### INTRODUCTION

One of the major causes of chronic nasal airway obstruction is pathology of the inferior turbinate. However, there is no agreement on how to deal with this problem. Pharmacological therapy is generally the treatment of choice. In many cases intranasal topical steroids, antihistamines and decongestants often yield good results. Patients who do not respond will usually be treated by surgical reduction of the turbinate. Since the last quarter of the 19th century, at least 13 different techniques have been introduced. Some of them have already been abandoned, whereas others are still in use or have been reintroduced. There is considerable controversy over the merits of the various techniques, however (Jackson and Koch, 1999).

Some authors consider turbinectomy as an appropriate method, while others condemn it as too aggressive and irreversibly destructive. Another controversial technique is laser treatment. Although numerous authors have recently advocated this modality, many rhinologists disapprove of it, as laser destroys the mucosa and permanently impairs its functioning. In the light of these and other controversies this article reviews and evaluates the literature on the surgical treatment of hypertrophied turbinates.

### THE FUNCTION OF THE TURBINATES

In order to critically evaluate the various methods of turbinate reduction, we must above all consider the function of the turbinates. We will then have to define the criteria that a given

surgical method must meet in order to be considered acceptable.

The turbinates, particularly the inferior ones, serve several important functions. First of all, they contribute to inspiratory resistance, which is necessary for normal breathing. The greater the nasal resistance, the greater the negative intrathoracic pressure needed for inspiration. Greater negative pressure, in turn, enhances pulmonary ventilation and venous backflow to the lungs and the heart (Butler, 1960; Haight and Cole, 1983). This is what we would like to call the 'resistor function' of the turbinates. Secondly, as part of the valve area, the inferior turbinate helps change the inspiratory lamellar airstream into a turbulent flow. Turbulence in the outer layers of air increases the interaction between air and nasal mucosa. Humidification, warming up, and cleansing of the air is thus enhanced. Thanks to their large mucosal surface and extensive blood supply, the inferior turbinates play a major role in this process. This role may be called the 'diffusor function' of the inferior turbinates. Finally, they are essential to the nasal defence system (mucociliary transport, humoral and cellular defence). All of these functions require a large amount of normally functioning mucosa, submucosa, and turbinate parenchyma.

### CRITERIA FOR EVALUATING METHODS OF REDUCING TURBINATE VOLUME

All methods should be judged by two basic criteria: 1. the efficacy of the technique in alleviating breathing obstruction,

\* Received for publication October 23, 2000; accepted October 27, 2000

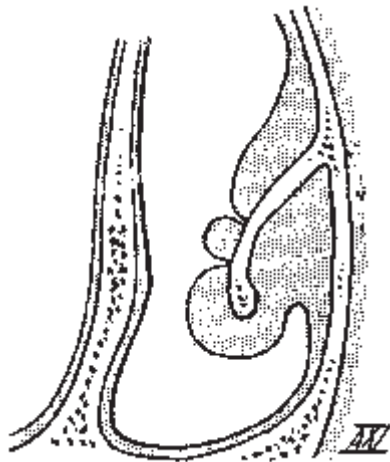


Figure 1. Technique of surface electrocoagulation (from Laurens' textbook, 1924).



Figure 2. Bipolar intratubinal coagulation (from Hurd, 1931).

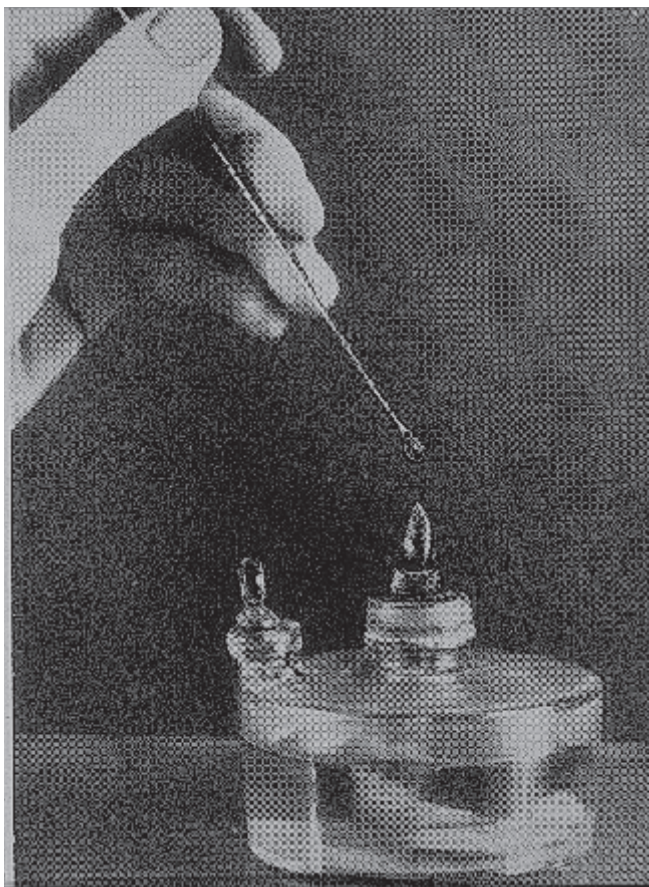

Figure 3. Melting chromic acid to a pearl for chemocauterizing the mucosal surface (from Seiffert's textbook, 1936).

hypersecretion, sneezing and headaches; 2. the side effects occurring in the short and the long term. In other words: to what extent the functional tasks of the nose have been respected and kept intact. It would be a mistake to only focus exclusively on the degree of widening the nasal passages in terms of endoscopic findings, rhinomanometry, and acoustic rhinometry. A wider nasal cavity does not necessarily mean the nose functions better. The goal of surgical treatment should be to "diminish complaints while preserving function" and "optimal volume reduction with preservation of function" (Huizing, 1998). With that concept in mind, this review assesses the various methods of inferior turbinate reduction which have been used in the past or are in use today. They are briefly described and critically evaluated in chronological order. A general overview of the findings is presented in Table 1.

1. THERMAL COAGULATION-ELECTROCAUTERY

The first method to treat hypertrophied inferior turbinates was electrocautery. Its use was suggested as early as 1845 by Heider from Vienna and Crusel from St Petersburg.

After the thesis by Middeldorff (1854) and the reports by von Bruns and Voltolini (1871) this method gradually gained in popularity. Eventually, it came into widespread use after the introduction of cocaine as a topical anaesthetic (Koller, 1884) and adrenaline (epinephrine) as a vasoconstrictor (1897). In the 1880's electrocautery of the nasal mucosa was used not only to treat nasal diseases but also for other ailments like dysmenorrhea, abortion, gastric pain, etc. 'Nasal reflex neurosis' (Fliess, 1893) was a common superstition in that day. Electrocautery was increasingly criticized for its casual application and because it led to serious complications such as synechias and stenosis. In 1890, at the World Congress in Berlin, the method was the target of some ridicule: Und dann wird die Nase ausgebrannt, denn das hilft immer wie bekannt! (And then the nose is burned out, because this always helps as we know!).

*Surface electrocautery.* The first method was surface electrocautery using a galvanic current (Voltolini, 1871). The standard technique consisted of coagulating from posterior to anterior two parallel furrows into the medial wall of the turbinate. The heat coagulates the tissues, causing necrosis, which is followed by fibrosis and shrinkage of the turbinate (Figure 1). While bleeding was rare, temporary complaints of crust formation were developed. Over the years, various types of galvanocaustic instruments have been developed. Later, high-frequency surface diathermy was introduced (e.g. Bourgeois and Poyet, 1922; Castex, 1929; Sinsky, 1932; Jaros, 1933). This technique was applied to destroy the tissues over a wide area or to achieve linear coagulation.

Surface electrocautery is obviously a destructive procedure. It causes mucosal atrophy, metaplasia, loss of cilia, and impairment of mucociliary transport. Permanent crusting and synechia between the septum and turbinate may occur. Although it is known to have these undesirable effects it is still one of the most practised methods.

Table 1. Different modalities of treatment for inferior turbinate hypertrophy.

Method	Year(s) of introduction	Still in use	Abandoned
Thermal coagulation, Electrocautery	1845-1880	+	
Chemocoagulation, Chemotherapy	1869-1890	+	
Turbinectomy	1882	+	
Lateralization, Lateropexia	1904	+	
Submucous resection of the turbinate bone	1906-1911	+	
Crushing + trimming, partial resection	1930-1953	+	
Injection of corticosteroids	1952		+
Injection of sclerosing agents	1953		+
Vidian neurectomy	1961		+
Cryosurgery	1970		+
Turbinoplasty	1982	+	
Laser surgery	1977	+	
Powered instruments	1994	+	

*Coblation* ('controlled ablation') was a quite recently introduced method of high frequency bipolar diathermy. As the effect is achieved at low temperatures, damage to the neighbouring tissue is said to be minimal (Smith et al., 1999).

*Intratubinal coagulation.* Because surface electrocautery does produce considerable damage to the mucosa, intratubinal thermocoagulation was introduced. Neres (1907) buried a gold needle in the turbinate and then ran a galvanic current through it for several seconds. Horn (1908) described a similar submucosal technique. Later, high-frequency diathermy was introduced. Beck (1930) was apparently the first to describe the use of a unipolar electrode to make a submucous linear burn. Hurd (1931) for the first time reported on bipolar intratubinal diathermy. Through an anterior puncture, the two parallel wires were buried in the length of the turbinate (Figure 2). Then 2-4 mm-deep parallel horizontal grooves were burned into the turbinate tissue in a postero-anterior direction. After World War II, Richardson (1948) and Shahinian (1953) again reported on submucous diathermy. Like Hurd, they both used a bipolar electrode to ensure an accurate prediction of the current. Simpson and Grooves (1958) advocated using a unipolar electrode, as a single wire would be easier to position. The effect of submucous diathermy is achieved by coagulation of the venous sinusoids within the turbinate, leading to submucosal fibrosis (Woodhead et al., 1989). The method has several drawbacks. First of all, the amount of deep tissue reduction is difficult to dosage (Wengraf et al., 1986). Secondly, its effect is often limited or temporary, so that the procedure has to be repeated (Jones and Lancer, 1987; Meredith, 1988). The most common complications are delayed haemorrhage, prolonged nasal discharge and crusting (Meredith, 1988; Williams et al., 1991). In spite of these disadvantages, submucous diathermy is still the treatment of choice for many ENT doctors, simply because it is easy to perform and causes relatively few complications.

## 2. CHEMOCOAGULATION- CHEMOCAUTERY

The use of chemical coagulation of the turbinate surface to reduce its size also came into use during the last decades of the 19th century. In the beginning, a saturated solution of trichloric

acid (TCA) was applied to the mucosa (e.g. von Stein, 1889); later, chromic acid melted to form a pearl was also used (Figure 3). Already in 1903, controversy arose about the merits of chemocoagulation. In many clinics, the results were considered favourable, but microscopic studies revealed considerable necrosis of the mucosa (Meyer, 1903). This author recommended applying TCA intensively, hypothesising that the epithelium will then recover better as new epithelium will overgrow the necrotic tissue.

This method has become less and less popular. Because of its limited effect on turbinate volume, the procedure had to be repeated several times. Secondly, it led to serious mucosal damage, with the characteristic symptoms of atrophic rhinitis. From the viewpoint of 'optimal volume reduction with preservation of function', this technique must be strongly condemned. It seems to be the worst imaginable method: while reducing the turbinate only slightly, it causes massive destruction of the functional structures of the mucosa, cilia, and glands. Remarkably, the application of chemocautics has recently been advocated again as a safe and effective means to reduce hypersecretion in patients with nasal hyperreactivity and allergy (Yao et al., 1988, 1995).

## 3. TURBINECTOMY

Resection and surgical reduction of the turbinates dates from the last decades of the 19th century. Jarvis (1882) to our knowledge, was the first to describe resection of parts of the inferior turbinate using a cold wire snare. Then, in the 1890s, Hartmann describes his experiences with inferior turbinate surgery (cited by Mabry, 1988). Later, Jones (1895) and Holmes (1900) advocated total turbinectomy. This method of irreversible resection was soon criticized. Spielberg (1924), for instance, warned of the overzealous rhinologist who does not feel content until he has excised, resected or cauterized every intranasal structure that can be found in the nose. The disadvantages of turbinectomy were evident. Some patients suffered from atrophic rhinitis or what became known as secondary ozaena with symptoms of nasal dryness, crusting, bleeding, pain, and headache. (e.g. Dutrow, 1935; Harris, 1936; House, 1951; Tremble, 1960). Turbi-

Table 2. Occurrence of dryness and crusting after (sub)total resection of the inferior turbinates according to recent studies.

Author	Dryness and crusting
Courtiss and Goldwyn '83, '90	No
Martinez et al.'83	No
Moore et al. '85	Yes
Ophir '85, '90	No
Odetoyinbo '87	No
Thompson '89	No
Wight '90	Yes
Salam and Wengraf '93	Yes
Carrie et al. '96	Yes
Berenholz' 98	Yes

nectomy fell into discredit; many surgeons preferred more conservative techniques like lateralization and submucous resection. Nevertheless, total turbinectomy was again recommended by several authors in the 1970s and 1980s (Fry, 1973; Courtiss et al., 1978; Martinez et al., 1983; Pollock and Rohrich, 1984; Ophir et al., 1985; Odetoyinbo, 1987; Thompson, 1989; Wight et al., 1990). Several of these authors disputed claims that it led to a post-turbinectomy or 'empty nose' syndrome as it has recently been named (Stenquist and Kern, 1997). Arguing that these undesired after-effects had never been documented Courtiss and Goldwyn (1990) wrote, "Fears for dry nose syndromes are unfounded". Others disagreed, reporting lasting signs and symptoms of crusting, dryness, and pain in quite a few patients. (Moore et al., 1985; Salam and Wengraf, 1993; Garth et al., 1995; Neves-Pinto, 1995; Berenholz et al., 1998). An overview of the conflicting reports is given in Table 2.

A recurrent feeling of nasal obstruction has also been reported (Otsuka et al., 1988; Wight et al., 1990; Carrie et al., 1996). Apart from the late sequelae, some early complications have to be taken into account as well, in particular severe haemorrhage (Fry, 1973; Dawes, 1987).

In our opinion, there is no justification for performing a total or subtotal turbinectomy in patients with a hypertrophic inferior turbinate. Turbinectomy is not compatible with the goal of 'preservation of function'. Turbinectomy is irreversible and deprives the nose of one of its important organs. There is thus no place for this technique in modern functional nasal surgery.

There are more conservative surgical methods to achieve the desired effect. This standpoint was recently confirmed in a prospective comparative randomized study by Passali et al. (1999). These authors compared the long-term results of six different techniques with respect to the patient symptom severity score, rhinomanometry, acoustic rhinometry, measurement of mucociliary transport time, and determination of secretory IgA before and after surgery. Turbinectomy ended up as the most damaging technique (Table 3).

4. LATERALIZATION, LATEROPEXIA

In reaction to the adverse effects of turbinectomy, Killian introduced lateralization (lateral displacement) of the inferior turbinate in 1904. The turbinate was outfractured and pushed laterally by means of a flat elevator or a long-bladed speculum. It is a simple procedure and entails no particular risks or complications (Salam and Wengraf, 1993). On the other hand, it does not seem to be very effective either. Lateralization works best when the inferior meatus is large enough to accommodate the displaced turbinate. Otherwise, it tends to resume its original position (Goode, 1978). Lateralization is an acceptable technique in the sense that it preserves function. Since its effect is limited, it may be used as a complementary procedure, e.g. in combination with septal surgery.

Lateropexia (or conchopexy) includes displacement of the outfractured turbinate into the maxillary sinus after removal of part of the lateral nasal wall (Fateen, 1967; Legler, 1974, 1976). Understandably, this method did not enjoy much popularity.

5. SUBMUCOUS RESECTION OF TURBINATE BONE

The complications of turbinectomy induced several surgeons to look for more conservative surgical methods to reduce the size of the inferior turbinate. Submucous resection of the turbinate bone was the first surgical alternative to be introduced (Low, 1906; Linhart, 1908; Würdemann, 1908; Zarniko, 1910). Würdemann declared himself to be "adverse in nearly every case to a complete excision of the inferior turbinal bodies" and wanted "to prevent disastrous results". A more delicate variant of this new principle was described by Freer in 1911: "a relatively small vertical incision is made to submucously uplift the covering of

Table 3. Main results of the prospective randomized study of six different modes of inferior turbinate reduction, as carried out by Passali et al., (1999).

Technique	Effect on obstruction	Recurrent obstruction	Effect on function	Complications
Electrocautery	+	+	-	+
Cryosurgery	+	+	-	+
Laser surgery	+	+	=	+
Submucous turb. Reduction	+	+	=	+
Subm.turb.red.+lateralization	+	-	=	0
Turbinectomy	+	-	-	0

the turbinate with a sharp elevator, completing the denudation with a sharp raspatory in this way allowing longitudinal resection of the lower turbinate" (Figure 4). Despite its convincing this technique gained only limited popularity (Strandberg, 1924; Odeneal, 1930; Harris, 1936). In 1951, Howard House revived the method. Good results were later reported by Loibl and Pfretzschner (1972) and Tolsdorff (1981), who combined the method with lateral displacement. Mabry (1982, 1984) further refined the technique and introduced the term 'turbino-plasty'. Following his patients he found the turbinates to be normal in size and function one year postoperatively. In the study by Passali et al. (1999), submucous bone resection combined with lateral displacement was considered the best method in terms of results and preservation of function.

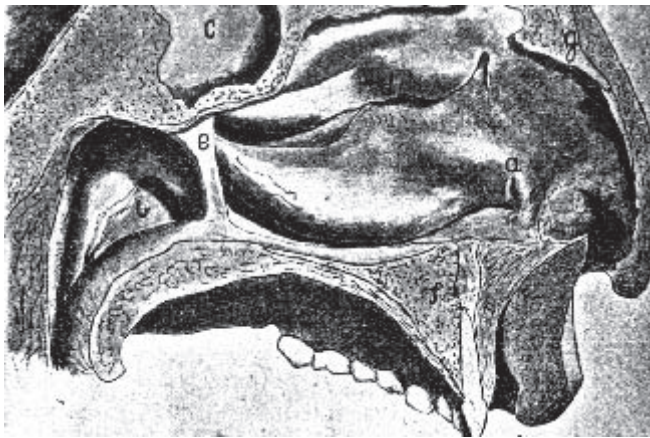


Figure 4. Intratubinal resection of turbinate bone and parenchyma through a vertical incision (a) at the turbinate head (from Freer, 1911).

#### 6. INJECTION OF CORTICOSTEROIDS

In 1952, injection of a long-acting corticosteroid solution was introduced as a new modality of reducing a hypertrophied turbinate (Semenov, 1952). Several authors reported that injections with corticosteroids are effective in reversible hyperreactive nasal disease, regardless of aetiology (Semenov, 1952; Simmons, 1960, 1964; Baker and Strauss, 1963). Corticosteroid injections are minimally invasive, but the subjective relief of nasal obstruction is brief. The technique is beneficial in reducing turbinate edema only for a period of 3-6 weeks (Mabry, 1979, 1981). Later, a number of authors discouraged turbinate injections, as they may produce acute homolateral blindness (Baker, 1979; Byers, 1979; Evans et al., 1980; Mabry, 1982; Saunders, 1982; Rettinger and Christ, 1989).

#### 7. INJECTION OF SCLEROSING AGENTS

Injection of a sclerosing solution, such as sodium morrhuate or sodium psylliate, into the turbinate parenchyma was introduced by Shahinian in 1953. The technique did not become widely used because of its unpredictable results and the risk of complications.

#### 8. VIDIAN NEURECTOMY

A completely different approach to the problem was introduced in 1961 by Golding-Wood. He proposed cutting the parasympathetic nerve fibres in the Vidian canal to decrease the parasympathetic tone to the nasal mucosa. In this way, he hoped to diminish the complaints of hypersecretion and nasal obstruction. The technique was devised in an era when drug therapy for hypersecretion was still very limited. Various approaches to the Vidian canal were subsequently developed. In the beginning, a transtrantral approach was used (Golding-Wood, 1973; Ogale et al., 1988), followed later by the endonasal method with coagulation of the ganglion (Portmann et al., 1982). Vidian neurectomy was widely used, but its effect turned out to be limited (Krant et al., 1979; Krajina, 1989). The hypersecretion was diminished but not the blockage (Principato, 1979). For this reason, the technique was abandoned at the beginning of the 1980s.

#### 9. CRYOSURGERY

In the 1970s, cryosurgery was introduced by Ozenberger (1970). This method involves freezing turbinate is frozen under local anaesthesia with a cryoprobe that uses nitrous oxide or liquid nitrogen as a cooling agent. The necrosis produced by freezing was found to be different from that produced by cautery. It was assumed that new respiratory epithelium would replace the frozen tissue. While the method came into widespread use, different success rates were reported (Grahne and Holopainen, 1971; Puhakka and Rantanen, 1977; Principato, 1979; Bumstead, 1984; Chiossone et al., 1990; Hartley and Willatt, 1995). The overall short-term results were satisfactory, but the benefit was usually not sustained (Warwick-Brown and Marks, 1987; Haight and Gardiner, 1989; Rakover and Rosen, 1996). According to Puhakka and Rantanen (1977), the success rate may improve with repeated application.

Apart from transient headache there are no postoperative sequelae (Moore and Bicknell, 1980). After one month, there was a marked reduction in glandular acini, scar tissue had formed, and the cilia appeared normal (Principato, 1979; Kellerhans and Schlageter, 1988). Yet, in some studies, the mucociliary clearance rate did not return to normal (Wengraf et al., 1986; Elwany and Harrison, 1990). According to some authors, cryosurgery would be more effective in allergic rhinitis than in non-allergic turbinate hypertrophy, as it is especially effective in controlling rhinorrhea (Principato, 1979; Rakover and Rosen, 1996).

Cryosurgery was gradually abandoned as a technique for several reasons. The amount of volume reduction was hard to predict. Furthermore, compared to other methods, the long-term results were disappointing, as was recently confirmed in the study of Passali et al. (1999).

#### 10. CRUSHING AND TRIMMING - PARTIAL RESECTION

The long-term complications of total turbinectomy convinced many nasal surgeons that a partial resection of the inferior turbinate would be a better option. Several techniques were advocated: crushing and trimming; horizontal or diagonal resection of

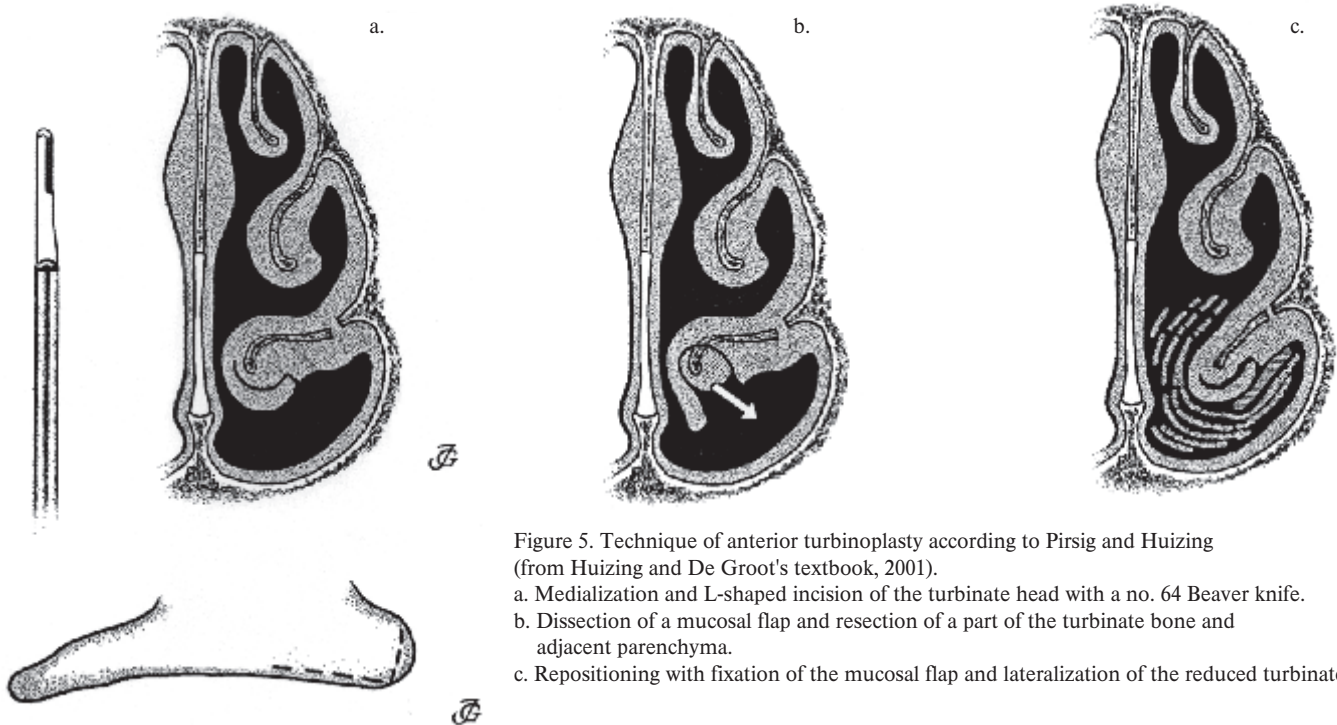


Figure 5. Technique of anterior turbinoplasty according to Pirsig and Huizing (from Huizing and De Groot's textbook, 2001).

- Medialization and L-shaped incision of the turbinate head with a no. 64 Beaver knife.
- Dissection of a mucosal flap and resection of a part of the turbinate bone and adjacent parenchyma.
- Repositioning with fixation of the mucosal flap and lateralization of the reduced turbinate.

the inferior margin; resection of the posterior part and resection of the anterior part.

In 1930, Kressner introduced crushing with a specially devised blunt forceps followed by trimming. This method has since been used by several surgeons. The technique has also been successfully applied in our department (Huizing, 1988).

Resection of the posterior part of the turbinate was carried out by Proetz (1953), among others, as he assumed that in most cases the posterior half of the inferior turbinate causes the obstruction.

Resection of the anterior part has been advocated by Goode (1978), Pollock and Rohrich (1984), Fanous (1986), and many others. Unlike Proetz, they consider the turbinate head to be the most frequent obstruction.

Horizontal inferior resection of the inferior margin was recommended by Courtiss and Goldwyn (1990), Dessi et al. (1992), Ophir et al. (1992), and Percodani et al. (1996). This method avoids the risk of bleeding from the sphenopalatine artery (Garth et al., 1995). According to some authors it only offers a partial solution since symptoms tend to reappear (often because of renewed hyperplasia) and the success rate deteriorates with time (Courtiss and Goldwyn, 1983, 1990; Warwick-Brown and Marks, 1987; Wight et al., 1990; Schmelzer et al., 1999).

Diagonal resection of more than half of the turbinate was carried out by Spector (1982). With this method the functionally important turbinate head is preserved. Serious posterior epistaxis may occur, however as the major blood supply of the turbinate is cut through by this method (Padgham and Vaughan-Jones, 1991).

From the viewpoint of preserving function, all of the above variations of partial turbinectomy appear to be acceptable, provided they are performed in a conservative way. Personally, we prefer crushing followed by horizontal trimming, as this seems

to represent the best compromise between desired results and side effects. In our view, resection of the turbinate head would seem too destructive. It may remove an anterior obstruction, but it partially deprives the nose of its resistor and diffusor function. Resection of a part of the posterior end of the turbinate would seem functionally acceptable, but it is only effective in patients with pathology restricted to the turbinate tail.

#### 11. TURBINOPLASTY

In the 1980s, the term 'turbinoplasty' was introduced (Mabry, 1982, 1984). It covers various methods of intratubinal surgical reduction of the inferior turbinate with preservation of the mucosa. Recently, several authors have elaborated and propagated methods of intratubinal reduction of the inferior turbinate (Gray, 1965; Lenders and Pirsig, 1990; Grymer et al., 1993; King and Mabry, 1993; Illum, 1997; and Marks, 1997; Huizing, 1998). After medialization of the turbinate, an L-shaped incision is made at its lateral-inferior margin. A mucosal flap is elevated and part of the turbinate bone and parenchyma is resected, as required. The mucosal flap is then redraped and fixated.

When the resection of bone and parenchyma is restricted to the anterior part of the turbinate, we speak of an 'anterior turbinoplasty'. This technique is applied in patients with inspiratory breathing obstruction due to hyperplasia of the turbinate head. Another technique is 'partial inferior turbinoplasty'. In this method two separate incisions are made that join in the centre of the concha. A wedge-shaped piece of the turbinate is then removed and the margins of the resulting defect are brought together (Schmelzer et al., 1999). Intratubinal turbinoplasty allows reduction of the turbinate while all mucosal functions are preserved, as was recently demonstrated by Passali et al. (1999) in their comparative study. A second advantage is its very low incidence of postoperative bleeding and crusting. From the

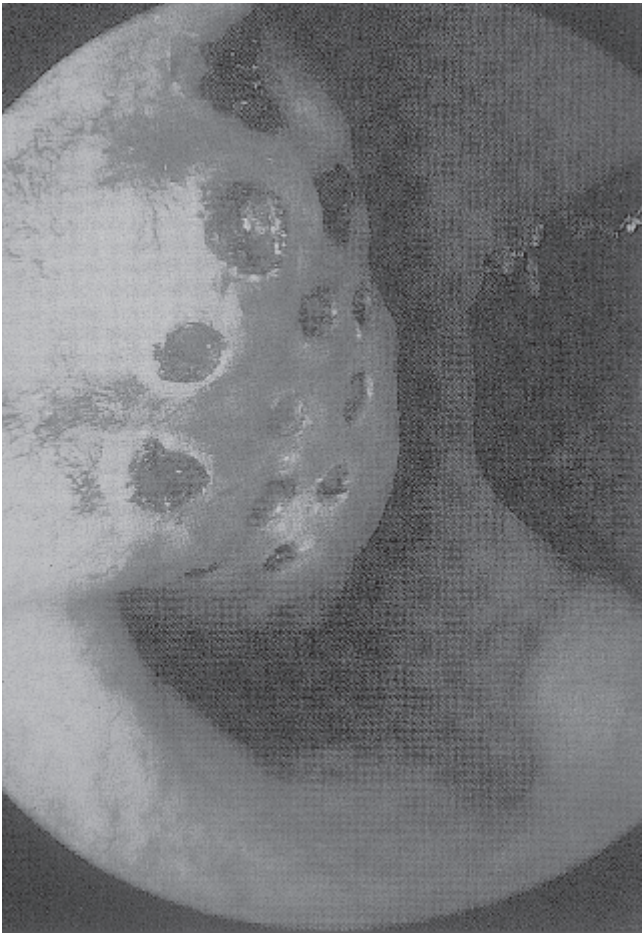

Figure 6. Laser treatment of the inferior turbinate (from Werner and Lippert, *Rhinology* 35: 33-36, 1997).

standpoint of 'optimal volume reduction with preservation of function', intratubinal turbinoplasty is the method of choice in treating turbinate hypertrophy. It is a tissue-reducing procedure and can be tailored according to the pathology without compromising the mucosal function.

## 12. LASER SURGERY

The use of laser technology to reduce the size of the inferior turbinate was reported for the first time by Lenz in 1977, who used the Argon-laser (Lenz et al., 1977; Lenz, 1985). In later years, several other types of laser were applied: the CO<sub>2</sub> laser (Mittelman, 1982; Simpson et al., 1982; Fukutake et al., 1986; Kawamura et al., 1993; Kubota, 1995; Lippert and Werner, 1997; Lagerholm et al., 1999; Papadakis et al., 1999; Katz et al., 2000); the Potassium-Titanyl Phosphate (KTP) laser (Levine, 1989, 1991); the Neodymium-Yag laser (Werner and Rudert, 1992); the Diode laser (Min et al., 1996); and the Holmium-Yag laser (Serrano et al., 1998).

Lasers produce a beam of coherent light that is absorbed by the tissues; the extent of absorption depends on its wavelength. Its energy thereby released evaporates the tissue. The depth of the lesion thus created depends on the wavelength, the extent of tissue absorption, and the amount of energy applied. Its diameter depends on the spot size of the laser beam. Thus, laser techno-

logy can be used in different ways depending on the parameters used. One of the parameters is the mode of application, either continuous or pulsed. Most authors use pulsed laser treatment, as a continuous laser beam causes damage in a wider area. A number of dots or small craters are produced in the mucosa at a distance of 1-2mm (Figure 5). The laser energy can be delivered directly (CO<sub>2</sub> laser) or through an optical fibre (KTP, Nd-YAG, Diode, Ho-YAG). Some authors prefer to make linear incisions as done in the electrocautery procedure. Continuous applied lasers enhance thermal damage in a wider area. Laser can also be used for resecting tissue in partial (or total) turbinectomy, and intratubinal tissue reduction. Laser technology can thus be used to perform a partial turbinectomy and for intratubinal tissue reduction. The laser may be used where others use a knife or scissors. We should emphasize that laser surgery is not a new operation but a new means to perform an operation.

Light microscopic studies of laser-treated mucosa have demonstrated that the ciliated epithelium regenerates only to a limited degree, while the number of seromucinous glands and cavernous blood spaces are decreased permanently (Kubota, 1995; Elwany and Abdel-Moneim, 1997). In another study, the superficial layer of the submucosa was found to be markedly degenerated and replaced by granulation tissue while after a year scar tissue could be seen (Fukuta et al., 1986).

Laser surgery of the turbinates can be performed under local anaesthesia on an out-patient basis. The haemostatic properties of laser treatment are such that postoperative bleeding is very rare and endonasal packing is unnecessary. Temporary crusting is common, and synechia may occur, however.

The results of laser surgery of the turbinates that have been published vary considerably (from '43% successful' to 'excellent results'). Almost all studies are retrospective and non-comparative, however. They have therefore little or no value and are consequently not reviewed here. We know of only one prospective comparative study in which the results of different types of laser surgery have been compared. In that study no significant difference could be established (DeRowe et al., 1998).

Laser surgery of the turbinates does not meet the requirement of 'optimal volume reduction in combination with preservation of function'. If a limited amount of mucosa and submucosa is evaporated, the volume reduction is probably insufficient. If the mucosal volume is sufficiently reduced, the functional damage will be severe and irreversible. Laser surgery is therefore not compatible with modern concepts of functional nasal surgery and should not be used to treat a hypertrophic inferior turbinate.

## 13. POWERED INSTRUMENTS

Recently, powered instruments like 'shavers' have come into use in turbinate surgery (Setcliff and Parsons, 1994). These instruments are used on the turbinate surface as well as intratubinally, often in combination with the endoscope. It has been claimed that they permit precise removal of soft tissue. Some surgeons resect parts from the lateral and inferior borders of the turbinate, while others use the shaver intratubinally (Friedman et al., 1999; Van Delden et al., 1999). The technique is said to be

fast, effective, and well tolerated and to have a low morbidity (Davis and Nishioka, 1996).

The use of powered instruments appears to be a matter of personal preference. It depends not so much on the instrument that is used. Rather, it is the surgical concept that counts in reducing the size of a turbinate.

#### CONCLUSION

When analysing the advantages, the disadvantages, and the complications of the various methods to treat inferior turbinate hypertrophy, it is difficult to draw firm conclusions.

*Lack of qualified studies.* First of all, we are faced with a serious lack of qualified studies. Most authors either advocate a new method or report on a retrospective study of their own results and offer unproven personal opinions. Studies comparing different modalities of treatment are very rare. Studies that meet all the criteria of a prospective comparative surgical study do not exist, with the notable exception of the recently published study by Passali et al. (1999).

*Criteria to be fulfilled in the ideal study.* The ideal study should meet the following criteria: the study should be prospective and comparative; patients should be randomly assigned to the study groups and all should suffer from the same disease; preoperative and postoperative parameters should include patient symptoms (VAS score), function tests (breathing, mucociliary transport, nasal defence etc.), complications, and follow-up until 3-5 years. We realize how difficult it is to meet with all these requirements. However, we would all agree that only studies of this type would really help us to find answers to the many still remaining questions.

#### ACKNOWLEDGEMENT

The authors gratefully acknowledge the support of Prof. Pirsig of Ulm in preparing this article.

#### REFERENCES

- Baker DC, Strauss RB (1963) Intranasal injections of long acting corticosteroids. *Ann Otol Rhinol Laryngol* 71: 525-531.
- Baker DC (1979) Intranasal steroid injections: Indication, technique, results, complications. *Laryngoscope* 89: 998-1003.
- Beck JC (1930) Pathology and intramural electrocoagulation of the inferior turbinate. *Ann Otol Rhinol Laryngol* 39: 349-363.
- Berenholz L, Kessler A, Sarfati S, Eviater E, Segal S (1998) Chronic sinusitis: A sequela of inferior turbinate resection. *Am J Rhinology* 12: 257-261.
- Bourgeois H, Poyet G (1922) *Rev Laryng* 43: 883, Bordeaux.
- Bumstead RM (1984) Cryotherapy for chronic vasomotor rhinitis: technique and patient selection for improved results. *Laryngoscope* 94: 539-544.
- Butler J (1960) The work of breathing through the nose. *Clin Sci* 19: 55-62.
- Byers B (1979) Blindness secondary to steroid injections into the nasal turbinates. *Arch Ophthalmol* 97: 79-80.
- Carrie S, Wright RG, Jones AS, Stevens JC, Parker AJ, Yardley MPJ (1996) Long-term results of trimming of the inferior turbinates. *Clin Otolaryngol* 21: 139-141.
- Castex G (1929) *Rev Laryng* 50: 226, Bordeaux.
- Chiossone E, Gutierrez JR, Emmanuelli JL (1990) Cryosurgery of the inferior nasal turbinates. *Auris Nasus Larynx* 17: 87-93.
- Courtiss EH, Goldwyn RM, OBrien JJ (1978) Resection of obstructing inferior nasal turbinates. *Plastic and Reconstructive Surgery* Vol 62-2: 249-257.
- Courtiss EH, Goldwyn RM (1983) Resection of obstructing inferior turbinates: A 6-year follow-up. *Plast Reconstr Surg* 72: 913.
- Courtiss EH, Goldwyn RM (1990) Resection of obstructing inferior nasal turbinates: A 10-year follow-up. *Plast Reconstr Surg* 86: 152-154.
- Davis WE, Nishioka GJ (1996) Endoscopic partial inferior turbinate resection using a power microcutting instrument. *J ENT* 75: 49-50.
- Dawes PJD (1987) The early complications of inferior turbinate resection. *J Laryngol Otol* 101: 1136-1139.
- Delden, MR van, Cook PR, Davis WE (1999) Endoscopic partial inferior turbinate resection. *Otolaryngol Head and Neck Surg* 121(4): 406-409.
- DeRowe A, Landsberg R, Leonov Y, Katzir A, Ophir D (1998) Subjective comparison of Nd:YAG, diode and CO<sub>2</sub> lasers for endoscopically guided inferior turbinate reduction surgery. *Am J Rhinology* 12: 209-212.
- Dessi P, Triglia JM, Portaspana T, Zanaret M, Cannoni M (1992) La turbinectomie inférieure sous guidage endoscopique. *Ann Otol Laryngol* 109: 311-315.
- Dutrow HV (1935) Conservative surgical treatment of hypertrophic rhinitis. *Arch Otolaryngol* 21: 59.
- Elwany S, Harrison R (1990) Inferior turbinate resection: Comparison of four techniques. *J Laryngol Otol* 104: 206-209.
- Elwany S, Abdel-Moneim MH (1997) Carbon dioxide laser turbinate resection. An electron microscopic study. *J Laryngol Otol* 111(10): 931-34.
- Evans DE, Zahorchak JA, Kennerdell JS (1980) Visual loss as a result of primary optic nerve neuropathy after intranasal corticosteroid injection. *Am J Ophthalmol* 90: 641-644.
- Fanou N (1986) Anterior turbinate resection. *Arch Otolaryngol Head Neck Surg* 112: 850-852.
- Fateen M (1967) Concho-antropexy (C.A.P.) in vasomotor rhinitis and chronic nasal obstruction. *Rhinology* 5: 20-24.
- Fliess W (1893) *Neue Beiträge zur Klinik und Therapie der nasalen Reflexneurose*. Leipzig Deuticke.
- Freer OT (1911) The inferior turbinate: Its longitudinal resection for chronic intumescence. *Laryngoscope* 21: 1136-1144.
- Friedman M, Tanyeri H, Lim J, Landsberg R, Caldarelli, D (1999) A safe, alternative technique for inferior turbinate reduction. *Laryngoscope* 109(11): 1834-1837.
- Fry HJH (1973) Judicious turbinate resection for nasal obstruction. *Austr New Zealand J Surg* 42: 291-294.
- Fukutake T, Yamashita T, Tomoda K, Kumazawa T (1986) Laser surgery for allergic rhinitis. *Arch Otolaryngol Head Neck Surg* 112: 1280-1282.
- Garth RJN, Cox HJ, Thomas MR (1995) Haemorrhage as a complication of inferior turbinate resection: a comparison of anterior and radical trimming. *Clin Otolaryngol* 20: 236-238.
- Golding-Wood PH (1961) Observations on petrosal and vidian neurectomy in chronic vasomotor rhinitis. *J Laryngol Otol* 75: 232.
- Golding-Wood PH (1973) Vidian neurectomy: Its results and complications. *Laryngoscope* 83: 1673.
- Goode R (1978) Surgery of the turbinates. *J Otolaryngol* 7: 262-268.
- Grahne B, Holopainen E (1971) Cryosurgery in vasomotor rhinitis. *Rhinology* 9: 92-96.
- Gray L (1965) The deviated nasal septum II: Prevention and treatment. *J Laryngol* 79: 806-816.
- Grymer LF, Illum P, Hilberg O (1993) Septoplasty and compensatory inferior turbinate hypertrophy: a randomized study evaluated by acoustic rhinometry. *J Laryngol Otol* 107: 413-417.
- Haight JSJ, Cole P (1983) The site and function of the nasal valve. *Laryngoscope* 93: 49-55.
- Haight JSJ, Gardiner GW (1989) Nasal cryosurgery and cautery: should the septum be treated and is a diagnosis relevant? *J Otolaryngol* 18(4):144-150.
- Harris HI (1936) Improved technique for submucous resection. *Ann Otol Rhinol and Laryngol* 45:481-484.



41. Hartley C, Willatt DJ (1995) Cryotherapy in the treatment of nasal obstruction: indications in adults. *J Laryngol Otol* 109:729-732.
42. Holmes CR (1900) Hypertrophy of the turbinated bodies. *NY Med J* 72:529-534.
43. Horn H (1908) The treatment of intumescent rhinitis by a submucous method. *Ann Otol Rhinol Laryngol* 17:490-494.
44. House HP (1951) Submucous resection of the inferior turbinal bone. *Laryngoscope* 61:637-648.
45. Huizing EH (1988) Functional surgery in inflammation of the nose and paranasal sinuses. *Rhinology Suppl* 5: 5-15.
46. Huizing EH (1998) Functional surgery of the nasal turbinates. In: Ch Bunnach, K Muntarhorn (Eds) *Asian Rhinological Practice*. Siriyod, Bangkok pp 300-308.
47. Huizing EH, De Groot JAM (to appear 2001) Functional Reconstructive Nasal Surgery. Thieme Verlag Stuttgart.
48. Hurd LM (1931) Bipolar electrode for electrocoagulation of the inferior turbinate. *Arch Otolaryngol* 13: 442.
49. Illum P (1997) Septoplasty and compensatory inferior turbinate hypertrophy: long-term results after randomized turbinoplasty. *Eur Arch Otol Rhinol Laryngol* 254 (suppl 1): 89-92.
50. Jackson LE, Koch RJ (1999) Controversies in the management of inferior turbinate hypertrophy: A comprehensive review. *Plast Reconstr Surg* 103: 300-312.
51. Jarvis WMC (1882) Removal of hypertrophied turbinated tissue by érasement with the cold wire. *Arch Laryngol* 3: 105-111.
52. Jones AS, Lancer JM (1987) Does submucosal diathermy to the inferior turbinate reduce nasal resistance to airflow in the long term? *J Laryngol Otol* 101: 448-451.
53. Jones M (1895) Turbinal hypertrophy. *Lancet* 2 : 895.
54. Katz S, Schmelzer B, Vidts, G (2000) Treatment of the obstructive nose by CO<sub>2</sub>-laser reduction of the inferior turbinates: technique and results. *Am J Rhinol* 14(1): 51-55.
55. Kawamura S, Fukutake T, Kubo N, Yamashita T, Kumazawa T (1993) Subjective results of laser surgery for allergic rhinitis. *Acta Otolaryngol (Stockholm) Suppl* 500: 109-112.
56. Kellerhans B, Schlageter J (1988) Cryosurgery in vasomotor rhinopathy: experimental histopathology. *Otol Rhinol Laryngol* 38: 157-163.
57. Killian (1903) Die Nebenhöhlen der Nasen in ihren Beziehungen zu den Nachbarorganen.
58. Killian (1904) Lateralization.
59. King HC, Mabry RL (1993) A practical guide to the management of nasal and sinus disorders. Thieme Medical Publishers, New York pp 94-118.
60. Krajina Z (1989) Critical review of Vidian neurectomy. *Rhinology* 27: 271-276.
61. Krant JN, Wildervanck de Blecourt P, Dieges PH, de Heer LJ (1979) Long-term results of Vidian neurectomy. *Rhinology* 17: 231-235.
62. Kubota I (1995) Nasal function following carbon dioxide laser turbinate surgery for allergy. *Am J Rhinology* 9-3: 155-161.
63. Lagerholm S, Harsten G, Emgård P, Olsson B (1999) Laserturbinectomy: long-term results. *J Laryngol Otol* 113: 529-531.
64. Laurens G (1924) *Chirurgie de l'Oreille, du Nez, du Pharynx et du Larynx*. Masson, Paris.
65. Legler U (1974) Gedanken zur chirurgischen Behandlung entzündlicher Veränderungen der Nase und ihrer Nebenhöhlen. *HNO* 22: 261-266.
66. Legler U (1976) Surgery of the turbinate bone and the piriform crest. *Rhinology* 14: 65-71.
67. Lenders H, Pirsig W (1990) How can hyperreactive rhinopathy be modified surgically? I: Literature review. *Laryngorhinootologie* 69(5): 246-254.
68. Lenders H, Pirsig W (1990) How can hyperreactive rhinopathy be modified surgically? II: Acoustic rhinometry and anterior turbinoplasty. *Laryngorhinootologie* 69(6): 291-297.
69. Lenz H, Eichler J, Schafer G, Salk J (1977) Parameters for argon laser surgery of the lower human turbinates. In vitro experiments. *Acta Otolaryngol (Stockholm)* 83: 360.
70. Lenz H, Eichler J, Knof J, Salk J, Schafer G (1977) Endonasal Ar+-laser beam guide system and first clinical application in vasomotor rhinitis. *Laryngol Rhinol Otol (Stuttgart)* 56: 749.
71. Lenz H (1985) Acht Jahre Laserchirurgie an den unteren Nasenmuscheln bei Rhinopathia vasomotorica in Form der Laserstrichkarbonisation. *HNO* 33: 422-425.
72. Levine HL (1989) KTP/532 laser for nasal sinus disease. *Ann Otol Rhinol Laryngol* 98: 46-51.
73. Levine HL (1991) The potassium-titanyl phosphate laser for treatment of turbinate dysfunction. *Otolaryngol Head Neck Surg* 104: 247-251.
74. Linhart CP (1908) A submucous operation for the reduction of hypertrophied turbinals. *Laryngoscope* 18: 128-134.
75. Lippert BM, Werner JA (1997) Comparison of carbondioxide and neodymium: yttrium-aluminium-garnet lasers in surgery of the inferior turbinate. *Ann Otol Rhinol Laryngol* 106: 1036-1042.
76. Lippert BM, Werner JA (1997) CO<sub>2</sub> laser surgery of hypertrophied inferior turbinates. *Rhinology* 35: 33-36.
77. Loibl H, Pfrezschner C (1972) Operative Möglichkeiten in der Behandlung der allergischen und vasomotorischen Rhinopathie im Kindesalter. *Kinderärztliche Praxis* 40: 1.
78. Low S (1906) Eine neue Operation- Submucöse Turbinektomie. *J Clin Research* 320.
79. Mabry RL (1979) Intranasal corticosteroid injection: Indications, technique and complications. *Otolaryngol Head Neck Surg* 87: 207-211.
80. Mabry RL (1981) Medical management of the stuffy nose. *South Med J* 74: 984-988.
81. Mabry RL (1982) How I do it- Plastic surgery. Inferior turbinoplasty. *Laryngoscope* 92: 459-461.
82. Mabry RL (1984) Surgery of the inferior turbinate: How much and when? *Otolaryngol Head Neck Surg* 92: 571-576.
83. Marks S (1997) Endoscopic inferior turbinoplasty. *Am J Rhinology* 12: 405-407.
84. Meredith GM (1988) Surgical reduction of hypertrophied inferior turbinates: A comparison of electrofulguration and partial resection. *Pl Reconstr Surg* 81(6): 891-899.
85. Meyer (1903) Histologische Beiträge zur Wirkung der Trichloresigsäure und Chromsäure. *Z Ohrenheilk* 44: 81-88.
86. Min YG, Kim HS, Yun YS, Kim CS, Jang YJ, Jung TG (1996) Contact laser turbinate surgery for the treatment of idiopathic rhinitis. *Clin Otolaryngol* 21: 533-536.
87. Mittelman H (1982) CO<sub>2</sub>-laser turbinectomies for chronic, obstructive rhinitis. *Lasers Surg Med* 2: 29-36.
88. Moore JRM, Bicknell PG (1980) A comparison of cryosurgery and submucous diathermy in vasomotor rhinitis. *J Laryngol Otol* 94: 1411-1413.
89. Neres FE (1907) Voltaic turbinal puncture for the relief of intumescent and hypertrophic rhinitis. *J Am Med Ass* 49: 1435-1438.
90. Neves-Pinto RM (1995) Turbinates surgery: when and how to perform it. *Folha med. Cad. otorinolaring.* 111(suppl 2): 117-120.
91. Odeneal TH (1930) Submucous turbinectomy. *Arch Otolaryngol* 11: 215-216.
92. Odetoyinbo O (1987) Complications following total inferior turbinectomy: facts or myths? *Clin Otolaryngol* 12: 361-363.
93. Ogale SB, Shah A, Rao SC, Shah KL (1988) Is vidian neurectomy worthwhile? *J Laryngol Otol* 102: 62.
94. Ophir D, Shapira A, Marshak G (1985) Total inferior turbinectomy for nasal airway obstruction. *Arch Otolaryngol* 111: 93-95.
95. Ophir D, Schindel D, Halperin D, Marshak G (1992) Long-term follow-up of the effectiveness and safety of inferior turbinectomy. *Plast Reconstr Surg* 90: 980-984.
96. Otsuka H, Skaguchi Y, Watase T (1988) Extensive turbinotomy for allergic nasal obstruction. *Otolaryngol Head and Neck Surg Tokyo* 60: 139-144.
97. Ozenberger JM (1970) Cryosurgery in chronic rhinitis. *Laryngoscope* 80: 723-734.
98. Ozenberger JM (1973) Cryosurgery for the treatment of chronic rhinitis. *Laryngoscope* 83: 508-516.
99. Padgham N, Vaughan-Jones R (1991) Cadaver studies of the anatomy of arterial supply to the inferior turbinates. *J R Soc Med* 84(12): 728-730.

100. Papadakis CE, Skoulakis CE, Nikolidakis AA, Velegrakis GA, Bizakis JG, Helidonis ES (1999) Swiftlase inferior turbinoplasty. *Am J Rhinol* 13(6): 479-482.
101. Passali D, Lauriello M, Anselmi M, Bellusi L (1999) Treatment of hypertrophy of the inferior turbinate: Long-term results in 382 patients randomly assigned to therapy. *Ann Otol Rhinol Laryngol* 108(6): 569-575.
102. Percodani J, Nicolas R, Dessi P, Serrano E, Triglia JM (1996) La turbinectomie inférieure partielle chez l'enfant: indications, technique, résultats. *Rev Laryngol Otol Rhinol* 117(3): 175-178.
103. Pollock RA, Rohrich RJ (1984) Inferior turbinate surgery: an adjunct to successful treatment of nasal obstruction in 408 patients. *Pl Reconstr Surg* 74: 227-234.
104. Portmann M, Guillen G, Chabrol A (1982) How I do it- head and neck. A targeted problem and its solution. Electrocoagulation of the Vidian nerve via the nasal passage. *Laryngoscope* 92 (4): 453-455.
105. Principato JJ (1979) Chronic vasomotor rhinitis: cryogenic and other surgical methods of treatment. *Laryngoscope* 89: 619-638.
106. Proetz A (1953) Applied physiology of the nose. 2nd edition, pp 134 Annals Publishing Co, St Louis.
107. Puhakka H, Rantanen T (1977) Cryotherapy as a method of treatment in allergic and vasomotor rhinitis. *J Laryngol Otol* 91: 535-539.
108. Rakover Y, Rosen G (1996) A comparison of partial inferior turbinectomy and cryosurgery for hypertrophic inferior turbinates. *J Laryngol Otol* 110: 732-735.
109. Richardson JR (1948) Turbinate treatment in vasomotor rhinitis. *Laryngoscope* 58: 834-847.
110. Rettinger G, Christ P (1989) Visual loss following intranasal injection. *Rhinology Suppl* 9: 66-72.
111. Salam MA, Wengraf C (1993) Concho-antropexy or total inferior turbinectomy for hypertrophy of the inferior turbinates? A prospective randomized study. *J Laryngol Otol* 107: 1125-1128.
112. Saunders WH (1982) Surgery of the inferior nasal turbinates. *Ann Otol Rhinol Laryngol* 91: 445-447.
113. Schmelzer B, Katz S, Vidts G (1999) Long-term efficacy of our surgical approach to turbinate hypertrophy. *Am J Rhinol* 13(5): 357-361.
114. Seiffert A (1936) Die Operationen am Nase, Mund und Hals. Curt Kabitzsch, Leipzig.
115. Semenov H (1952) The pathology of the nose and paranasal sinuses in relation to allergy. *Trans Amer Acad Ophth Otol* 56: 121-170.
116. Serrano E, Percodani J, Yarden E, Lombard L, Laffitte F, Pessey JJ (1998) The Holmium: YAG laser for treatment of inferior turbinate hypertrophy. *Rhinology* 36: 77-80.
117. Setcliff RC, Parsons DS (1994) The Hummer: New instrumentation for functional endoscopic sinus surgery. *Am J Rhinol* 8(6): 275-277.
118. Shahinian L (1953) Chronic vasomotor rhinitis, treatment by submucous diathermic coagulation. *Arch Otolaryngol* 57: 475-489.
119. Simmons MW (1960) Intranasal injection of corticosteroids. *Calif Med* 92: 155-158.
120. Simmons MW (1964) Intranasal injection of corticosteroids in nasal disorders: further observations. *Pacific Coast Otoophthalmol Soc* 45: 95-103.
121. Simpson GT, Shapsay SM, Vaughn CW, Strong MS (1982) Rhinologic surgery with the carbon dioxide laser. *Laryngoscope* 92: 412-415.
122. Simpson JF, Grooves J (1958) Submucosal diathermy of the inferior turbinates. *J Laryngol Otol* 72: 292-301.
123. Smith TL, Correa AJ, Kuo T, Reinisch L (1999) Radiofrequency tissue ablation of the inferior turbinates using a thermocouple feedback electrode. *Laryngoscope* 109(11): 1760-1765.
124. Spector M (1982) Partial resection of the inferior turbinate. *ENT J* 61: 28-32.
125. Spielberg W (1924) The treatment of nasal obstruction by submucous resection of the inferior turbinate bone. *Laryngoscope* 34: 197-203.
126. Stenquist M, Kern EB (1997) Personal communication.
127. Strandberg O (1924) A method of total removal of the inferior turbinated bone. *J Laryngol Otol* 39: 65.
128. Thompson AC (1989) Surgical reduction of the inferior turbinate in children: extended follow-up. *J Laryngol Otol* 103: 577-579.
129. Tolsdorff P (1981) Eingriffe an den Nasenmuscheln unter besonderer Berücksichtigung der subperiostalen Conchectomie. *Laryngol Rhinol* 60: 615-619.
130. Tremble GE (1960) Methods of shrinking of the inferior turbinates to improve the airway. *Laryngoscope* 70: 175-186.
131. Voltolini R (1871) Die Anwendung der Galvanokaustik im innern des Kehlkopfes und Schlundkopfes. Wilhelm Braumüller, Wien.
132. Warwick-Brown NP, Marks NJ (1987) Turbinate surgery: How effective is it? *J Otol Rhinol Laryngol* 49: 314-320.
133. Wengraf CL, Gleeson MJ, Siodlak MZ (1986) The stuffy nose: a comparative study of two common methods of treatment. *Clin Otolaryngol* 11: 61-68.
134. Werner JA, Rudert H (1992) Der Einsatz des Nd:Yag-lasers in der Hals-, Nasen-, Ohrenheilkunde. *HNO* 40: 248-258.
135. Wight RG, Jones AS, Beckham E (1990) Trimming of the inferior turbinates- a prospective long-term study. *Clin Otol* 15: 347-350.
136. Williams HOL, Fisher EW, Golding-Wood DG (1991) Two-stage turbinectomy: Sequestration of the inferior turbinate following submucosal diathermy. *J Laryngol Otol* 105: 14-16.
137. Woodhead CJ, Wickham MH, Smelt GJC, Macdonald AW (1989) Some observations on submucous diathermy. *J Laryngol Otol* 103: 1047-1049.
138. Würdemann HV (1908) Submucous turbinectomy. *Laryngoscope* 18: 284-285.
139. Yao K, Shitara T, Takahashi H, Yagi A (1988) Chemosurgery to inferior turbinates trichloroacetic acid application. *J Otolaryngol* 91(7): 1031-1041.
140. Yao K, Shitara T, Takahashi H, Nishiyama K, Iguchi Y, Yamamoto K (1995) Chemosurgery with trichloroacetic acid for allergic rhinitis. *Am J Rhinology* 9-3: 163-168.
141. Zarniko C (1910) Turbinotomia submucosa. *Verhandl Vereins dtsh Laryngol* 17.

Egbert H. Huizing  
 Department of Otorhinolaryngology  
 University Medical Centre Utrecht  
 Heidelberglaan 100  
 3584 CX Utrecht  
 The Netherlands