



The Changing Face of Petrous Apicitis—A 40-Year Experience

Arun K. Gadre, MD, FACS, MS (Bom), DORL; Richard A. Chole, MD, PhD

Objectives/Hypothesis: Petrous apicitis (PA) is a rare complication of otitis media. Gradenigo syndrome, with the classic triad of otitis, deep pain, and abducens paralysis, is rarer still. The objective of this study was to determine if clinical presentation and management has changed over time.

Study Design: Retrospective chart review.

Methods: Forty-four patients with PA over a 40-year period were studied. Symptoms, signs, and management outcomes were studied. Historical review, surgical anatomy and approaches, pathology, and microbiology, and an illustrative case are included as appendices.

Results: The classical Gradenigo triad of retro-orbital pain, otitis, and abducens palsy occurred in only six of 44 patients (13.6%). Over the 40-year observation period, those needing surgery has decreased.

Conclusions: Antibiotics remain the primary treatment modality. Surgery is reserved for cases failing to respond to antibiotics. One of the 44 patients in this series died of his disease. Diagnosis and management algorithms based on these observations are suggested.

Key Words: Petrous apicitis, petrositis, Gradenigo's syndrome, lateral rectus palsy, abducens nerve, complications of otitis media, petrous apex, retro-orbital pain, facial pain, otorrhea.

Level of Evidence: 4.

Laryngoscope, 00:000-000, 2017

INTRODUCTION

"Lest we forget that this condition still occurs."
(DeWeese, 1958)¹

Petrous apicitis (PA) is a rare and potentially life-threatening condition. Due to its rarity, its incidence in adults today is largely unknown. In the past, it was thought to occur in two out of 100,000 children with acute otitis media.² The widespread use of antibiotics for otitis has presumably decreased the incidence of PA. Nevertheless, sporadic cases of PA continue to occur. The condition is largely underdiagnosed due to: 1) lack of awareness that PA is often insidious, 2) masking of symptoms due to antibiotics, and 3) a misconception that abducens nerve palsy is the sine quo non of PA. Early diagnosis of PA is helped by an alert clinician along with the availability of high-resolution computerized tomography (HRCT), magnetic resonance imaging (MRI), and radioisotope bone scans.

This retrospective study represents the largest reported series of patients with PA. The first eight cases were the subject of a previous communication.³

Additional Supporting Information may be found in the online version of this article.

From the Department of Otolaryngology–Head and Neck Surgery (A.K.G.) and Department of Surgery (A.K.G.), Heuser Hearing Institute, University of Louisville, Louisville, Kentucky; Department of Otolaryngology (R.A.C.), Washington University, St. Louis, Missouri, U.S.A.

Editor's Note: This Manuscript was accepted for publication February 13, 2017.

The authors have no funding, financial relationships, or conflicts of interest to disclose.

Send correspondence to Arun K. Gadre, MD, FACS, 3590 Camino Del Rio North Ste 101, San Diego, CA 92108-1716. E-mail: arungadre@yahoo.com

DOI: 10.1002/lary.26571

Supporting Appendix I covers historical controversy surrounding Gradenigo and his eponymous syndrome. Supporting Appendix II describes the surgical anatomy. Supporting Appendix III covers microbiology and surgical pathology. Supporting Appendix IV describes the evolution of surgical approaches. Appendix 5 describes an interesting case. Refer to the Supporting Information, Supporting Appendices, in the online version of this article.

BACKGROUND

PA was associated with considerable morbidity and mortality in the preantibiotic era. The discovery and use of antibiotics have succeeded in converting what was uncommon into a rarity. In 1937, Myerson⁴ estimated that suppuration in the petrous apex occurred once in every 300 cases of otitis media. Today, the incidence may be smaller than 2:100,000 patients with otitis media.²

In 1904, Professor G. Gradenigo of Turin, Italy (Fig 1), described a symptom complex that included paresis of the abducens nerve, severe pain in the distribution of the trigeminal nerve, and acute suppurative otitis media.⁵ This triad became known as Gradenigo's syndrome. In a subsequent article, he reported on 57 cases, of which only four cases were his own; the other 53 cases were compiled from the existing literature.⁶ Panse⁷ disagreed with Gradenigo that the classic triad was the hallmark of PA. In his second article, Gradenigo⁶ conceded that not all cases neatly fit the symptom complex. Nearly 30 years later Frenckner⁸ wrote a scholarly article regarding the controversy. Haymann⁹ introduced the term apicitis, and Profant¹⁰ introduced the term petrositis.

Infection was believed to spread along air-cell tracts,⁹⁻¹³ but Papale^{14,15} and Pietrantoni¹⁶ considered



Fig. 1. Professor Count Giuseppe Gradenigo (1859–1926). (Photo courtesy of Professor Maurizio Barbara, Rome, Italy, and Professor Diego Zanetti, Milan, Italy.)

lymphatic and vascular channels as routes for spread. The abducens nerve was believed to be involved in a suppurative process as it coursed through Dorello's canal,¹⁷ under the petrosphenoidal ligament. Uffenorde¹¹ observed that trigeminal irritability occurred more often than VI nerve involvement. Meltzer¹³ felt that inflammation of the pericarotid sympathetic plexus caused pain. Vogel,¹⁸ as quoted by Kopetzky and Almour,¹⁹ clarified that Gradenigo's triad was not the sine quo non for suppuration of the petrous apex.

Mortality rates approximating 20% were being reported by Frenckner in 1932.⁸ Gradenigo reported a mortality rate of 7%, but subsequent reports suggested a figure of 18% was more accurate.²⁰ This study reviews a 40-year experience with PA in the antibiotic era and represents the largest series reported.

DEFINITIONS

Chole²¹ classified the petrous apex into an anterior petrous apex and posterior petrous apex, separated by a coronal plane passing through the internal auditory canal (Fig. 2). Jackler and Parker²² described differences between infections of the petrous apex that involved the mucosa-lined spaces (petrous apicitis) versus those that involve the bone and marrow (osteomyelitis). Each one could be acute or chronic.

MATERIALS AND METHODS

This is a chart review that represents experiences with PA collected prospectively over a 40-year period (January 1, 1971–June 30, 2011). The study was performed after institutional review board approval (#201308024) at Washington University Medical School. Eight cases have been the subject of a previous communication.³ Inclusion criteria comprised patients with headache or facial pain, with or without ear discharge, and with cranial nerve deficits, associated with radiological findings suggestive of PA. One case of PA following malignant otitis externa has been included. Patients with serous effusion and cholesterol granulomas have been excluded from this study.²² Patients underwent a neurotologic examination, and where possible an audiological

evaluation was performed. Other than the early cases, most underwent HRCT scans and magnetic resonance imaging (MRI). Bone scans were performed in selected cases.

Bacteriologic cultures were obtained either from the ear canal following tympanocentesis or during surgery prior to the start of antibiotics where possible. Broad-spectrum antibiotics were used to cover gram-positive, gram-negative, and anaerobic organisms in all cases. Culture-directed antibiotics were used once sensitivities became available. Patients who did not respond to antibiotics or worsened within 24 to 48 hours were treated with surgery to facilitate drainage of the anterior petrous apex. Surgical approaches included infralabyrinthine, retrofacial, anterior peritubal, trans-sphenoidal, and middle cranial fossa (for surgical approaches see Supporting Appendix IV in the online version of this article) (Fig. 3). Worsening of the condition was evidenced by persistent or rising temperature and an unrelenting "picket-fence" fever. Other signs included the worsening of retro-orbital and facial pain, and progression of cranial nerve deficits associated with a rising neutrophil count, or an increase in C-reactive protein. Steroids were not used. Consultation from the infectious disease specialist, neurologist, or neurosurgeon was sought. Follow-up ranged from 3 months to 25 years.

RESULTS

Based on the inclusion criteria, 44 patients were diagnosed with PA. The cohort comprised 23 males and 21 females. Ages ranged between 8 and 76 years (mean age of 39.2 years). Only five of the 44 patients (11.4%) were in the pediatric age group; the rest were adults. All patients were treated with systemic antibiotics, and 24 of 44 patients (54.6%) underwent surgical intervention (including tympanostomy tubes) to achieve resolution of PA.

Signs and Symptoms

Severe retro-orbital pain was present in 24 of 44 patients (54.5%), and otitis media was present in 27

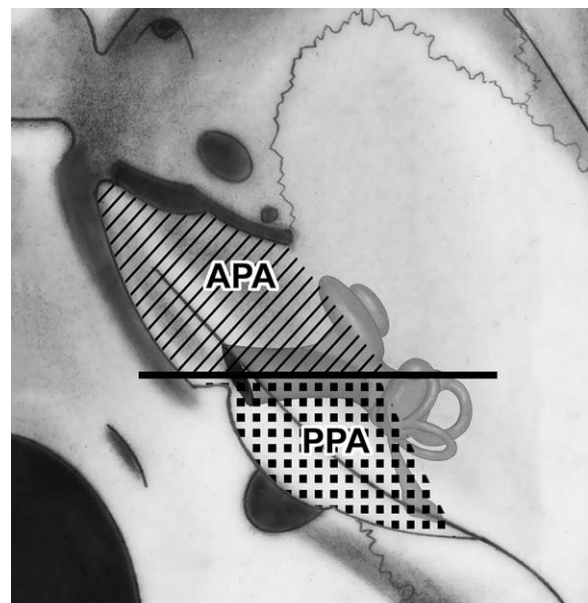


Fig. 2. Right petrous apex middle fossa view. APA = anterior petrous apex. PPA = posterior petrous apex. (Adapted from Chole and Donald³ with permission.)

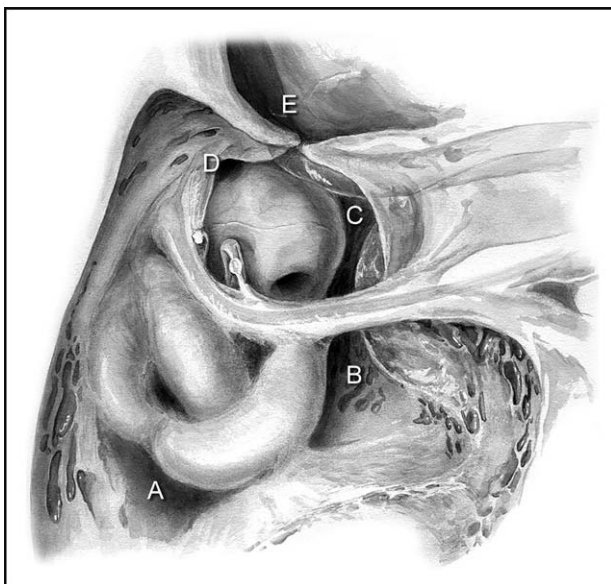


Fig. 3. Drawing showing approaches to the petrous apex. (A) Access to PPA via sinodural air cell tract. (B) Retrofacial infralabyrinthine tract gives access to PPA and APA. (C) Infralabyrinthine tract gives access to APA after tympanic plate is removed. (D) Air cell tract above eustachian tube leading to APA. (E) Wide exposure to APA after dissecting medial wall of glenoid fossa along internal carotid artery. APA = anterior petrous apex. PPA = posterior petrous apex.

patients (61.4%). Only seven of 44 patients (15.9%) demonstrated palsy of the abducens nerve. A patient with cavernous sinus thrombophlebitis suffered bilateral abducens palsy; the rest had unilateral lesions. Seventeen patients in this series did not have otitis media at the time of presentation but may have had a preceding bout. Of the 27 with otitis media, 16 patients (59.3%) had purulent otorrhea at the time of presentation. Facial pain along with otitis occurred in 37 of the 44 (84.1%). Fever was present in eight of 44 (18.2%) patients. Other associated conditions included, histiocytic lymphoma (n = 1), a sequestered mastoid (n = 1), malignant otitis (n = 1), severe dizziness (n = 1), cerebrospinal fluid leak (n = 1), and meningitis (n = 2). One patient with meningitis also had cavernous sinus thrombophlebitis (see Supporting Appendix V in the online version of this article). One patient had slurred speech and facial nerve weakness. Vague head and neck pain was also present in a one patient.

Ophthalmoplegia (deficits in cranial nerves III, IV, and VI) was present in two of 44 patients (4.5%). One of these was the same patient with otogenic cavernous sinus thrombophlebitis. Vision was lost in one eye but recovered following surgery in the other. The other patient with histiocytic lymphoma (a variant of non-Hodgkin lymphoma) was the only fatality in our series. However, there was no evidence of tumor in the petrous apex.

Trigeminal neuralgic pain was present in 24 of the 44 patients (54.5%), but motor deficits were not noted. Generalized headache along with retro-orbital pain involved 29 patients (65.9%). Facial nerve palsy occurred in three patients (6.8%), and sensorineural hearing loss

was documented in 10 of 44 patients (22.7%). Glosso-pharyngeal and vagus nerve involvement occurred in one out of 44 patients. This patient had malignant otitis externa, which progressed into PA. Accessory nerve and hypoglossal nerves were not involved in any of our patients. Of 21 patients who had both otitis and retro-orbital pain, six (28.6%) had abducens nerve palsy. The classic triad of Gradenigo syndrome occurred in only six of 44 patients (13.6%).

Of the 44 patients with PA, seven patients (15.9%) had cholesteatoma in the mastoid, and five (11.4%) had associated granulation tissue or middle ear polyps. Dural venous sinus thrombosis occurred in four of 44 patients (9.1%). Of these, three had sigmoid sinus thrombophlebitis and one had involvement of the cavernous sinus. One of the patients with dural sinus involvement who had histiocytic lymphoma died (25%). This was the only fatality in the series (i.e., 2% for the series).³

Imaging

Imaging studies are invaluable in the diagnosis and management of PA. HRCT scans demonstrate soft tissue and bony changes within the petrous apex and are a

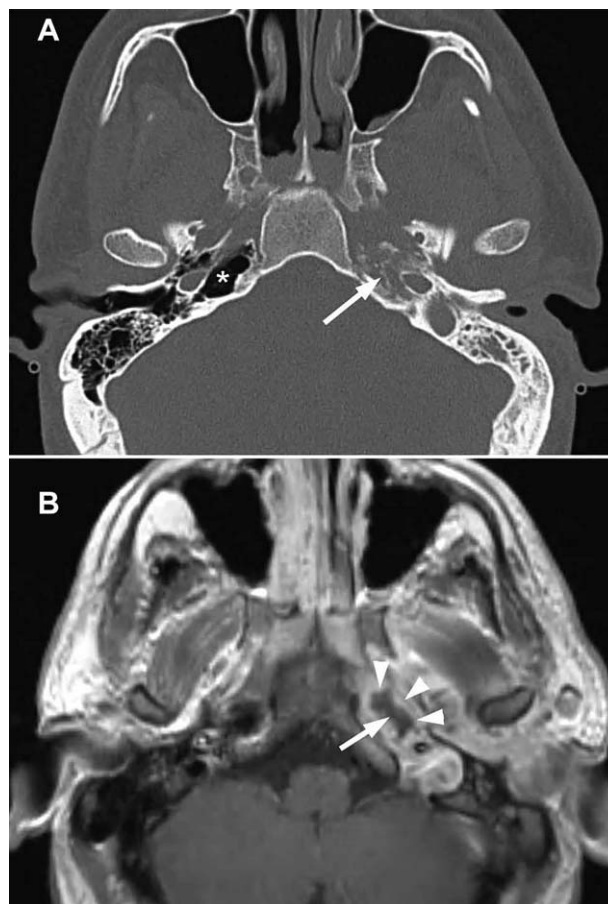


Fig. 4. (A) CT scan. Arrow shows a left infected opacified petrous apex with disruption of bony trabeculae. Right petrous apex is pneumatized (*). (B) MRI with gadolinium shows rim enhancement (arrow-heads) of inflamed lining with central necrosis within petrous apex. CT = computed tomography; MRI = magnetic resonance imaging.

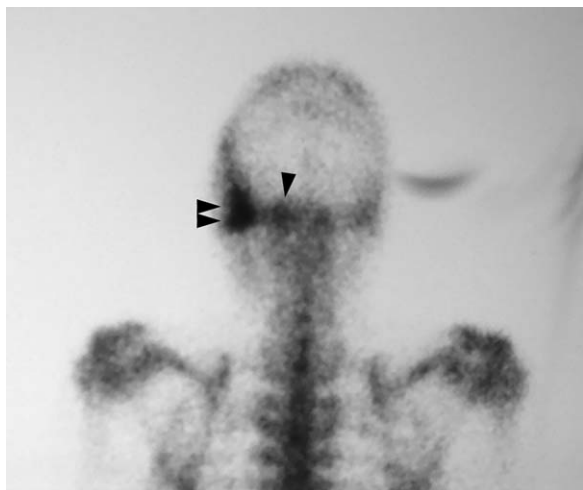


Fig. 5. A Tc99 scan showing increased uptake in right mastoid (double arrow head) and petrous apex (single arrowhead).

valuable adjunct to surgical management when necessary (Fig. 4). MRI scanning is often important when intracranial or dural sinus involvement is suspected (Fig. 4). Gallium scanning is an adjunct to treatment and may be used to assess the activity and resolution of the disorder (Fig. 5).

Management

Thirty-four of the 44 patients (77.3%) underwent medical management alone with or without tympanostomy and ventilation tube placement. Major surgical intervention was performed in 10 of 44 patients (22.7%); a transmastoid approach following fistulous tracts around vital structures was performed in five patients, translabyrinthine approach in two patients, transsphenoid approach in one patient, and middle cranial fossa approach in two patients. The remaining 77.3% had resolution of their symptoms with antibiotics alone.

Over 4 decades, the number of surgeries performed appear to have decreased (Table I and Fig. 6). During the period 1971 through 1980, 50% were treated surgically. Between 1981 and 1990, 28.6% underwent major surgery. Between 1991 and 2010, 15.4% underwent surgery. Between 2001 and 2011, only 12.5% diagnosed patients underwent surgery.

Microbiology

Cultures were positive in 15 patients (34%). Of these, the most common organism encountered was *Pseudomonas aeruginosa* in eight patients (53.3%). Two samples (13.3%)

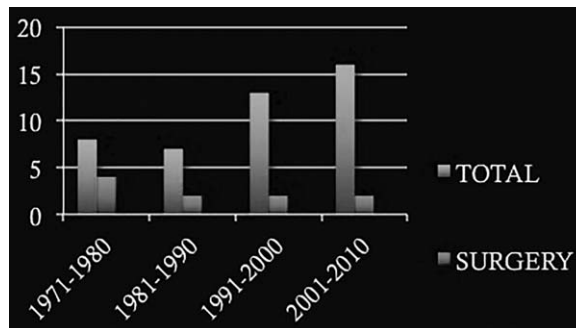


Fig. 6. Total number of cases diagnosed and operated upon by decade.

grew *Staphylococcus aureus*, one (6.7%) grew out *Propionibacterium* spp., one (6.7%) sample grew *Streptococcus pneumoniae*, two (13.3%) grew *S aureus* with *P aeruginosa*, and one (6.7%) grew *Provetella* spp.

DISCUSSION

Ever since Gradenigo⁵ first alerted the medical community about a triad of symptoms that bears his name, the question of whether the triad is a sine quo non for PA has been a controversial one. Three years later, Gradenigo⁶ identified four of his own cases and compiled another 53 from the available medical literature. He found that 24 of the 57 cases (42%) suffered the classic triad. In comparison, the classic triad was present in two of eight (25%) cases in a series reported by Chole and Donald,³ and in six of the 44 cases (13.6%) in the current series. Alluding to abducens nerve palsy, Chole and Donald³ wrote “we must not rely on that sign to make the diagnosis of petrous apicitis.” Deep facial pain was a more reliable indicator of PA. In contrast, Price and Fayad²³ reported on a case where abducens nerve palsy was the sole feature of PA, thereby underscoring the variable nature of its clinical presentation.

An argument can be made that the use of advanced imaging modalities and antibiotics may prevent the development of a full-blown Gradenigo triad. However, it must be stressed that even in the preantibiotic era, the classic triad was uncommon. In our opinion, therefore, Gradenigo syndrome and PA should not be used synonymously, and a patient with otitis media and retro-orbital pain should be investigated even in the absence of abducens nerve palsy.

The incidence of lesions of the facial and vestibulocochlear nerves and labyrinth taken together (29.5%) was almost twice as common as that involving the abducens nerve (16.9%). Despite this fact, in older series, there is little mention of sensorineural hearing losses or balance problems as being a prominent feature of the condition. One explanation for this is that in the presence of a potentially fatal condition, hearing loss and imbalance may not have been recorded.

The trigeminal nerve had the highest incidence of being involved. The close proximity of the abducens nerve and trigeminal ganglion render both susceptible to extradural inflammation in PA (Fig. 7).²⁴⁻²⁶ The variability of trigeminal and abducens nerve involvement may relate to a variability of the extradural inflammatory

TABLE I.

Distribution of Cases by Decade and Those Treated by Surgery.

Decade	Total Number Diagnosed	Number of Cases Treated by Surgery	%
1971-1980	8	4	50.0%
1981-1990	7	2	28.6%
1991-2000	13	2	15.4%
2001-2010	16	2	12.6%

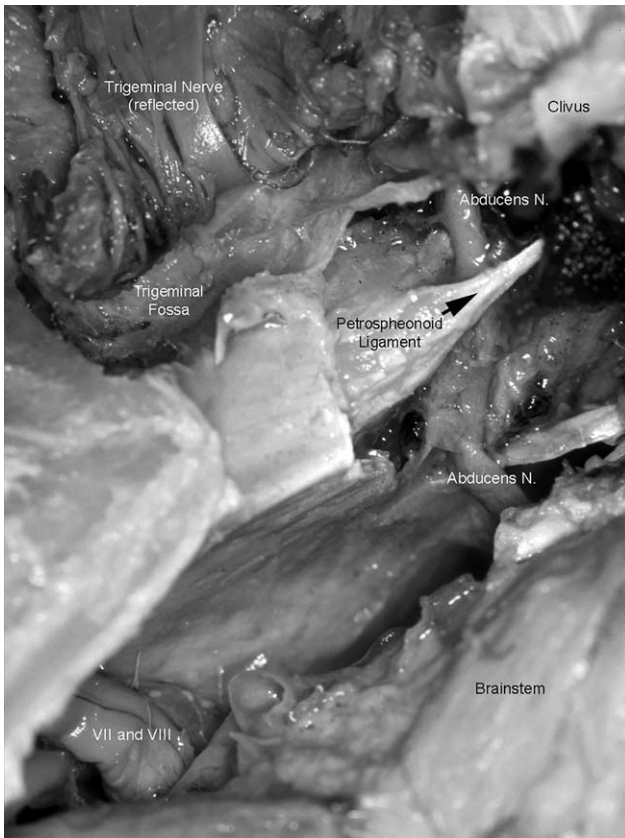
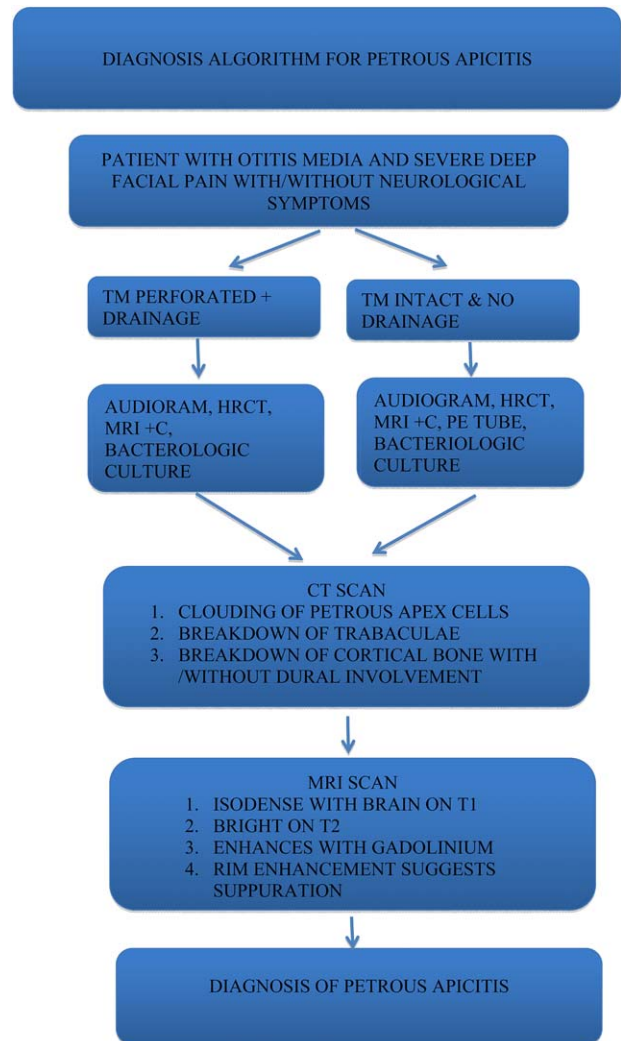


Fig. 7. Dissection of left petrous apex viewed from middle cranial fossa. Trigeminal nerve has been reflected anteriorly. Abducens nerve seen passing under the petrosphenoidal ligament of Grüber and entering the Dorello canal.

process.²⁷ In the course of cadaveric dissections, cortical bone in the floor of the trigeminal fossa is also thinner (at times deficient) than the bone under Dorello's canal. Additionally, dense fibrous connective tissue of Dorello's canal may actually protect the abducens nerve from infection. In Gradenigo's series of compiled cases, ages were recorded in 50 of the 57 patients.⁶ Of these, 22 (44%) were in the pediatric age group. In comparison, only five of 44 patients (11%) in our series were 18 years or younger. This decline in pediatric PA may be attributed to early and more effective medical and surgical treatment of otitis media today compared to the early 1900s.

HRCT and MRI scans complement each other in establishing the diagnosis (Fig. 4A,B). HRCT scans help identify normal petrous apex asymmetry, air-cell opacification, trabecular breakdown, or erosion of cortical bone. HRCT scans also help decide the optimal approach if surgery is contemplated.

Jackler and Parker²² summarized the MRI characteristics of common petrous apex lesion. Fatty bone marrow in petrous apices can be confused for petrous apicitis. This normal variation occurs in less than 5% of individuals.²⁸ A simple effusion in the petrous apex is seen in less than 1% of cases. Depending on its protein content, a variable signal on T1-weighted and increased T2-weighted signal is seen. Petrous apex cephaloceles or arachnoid cysts have similar signal characteristics and



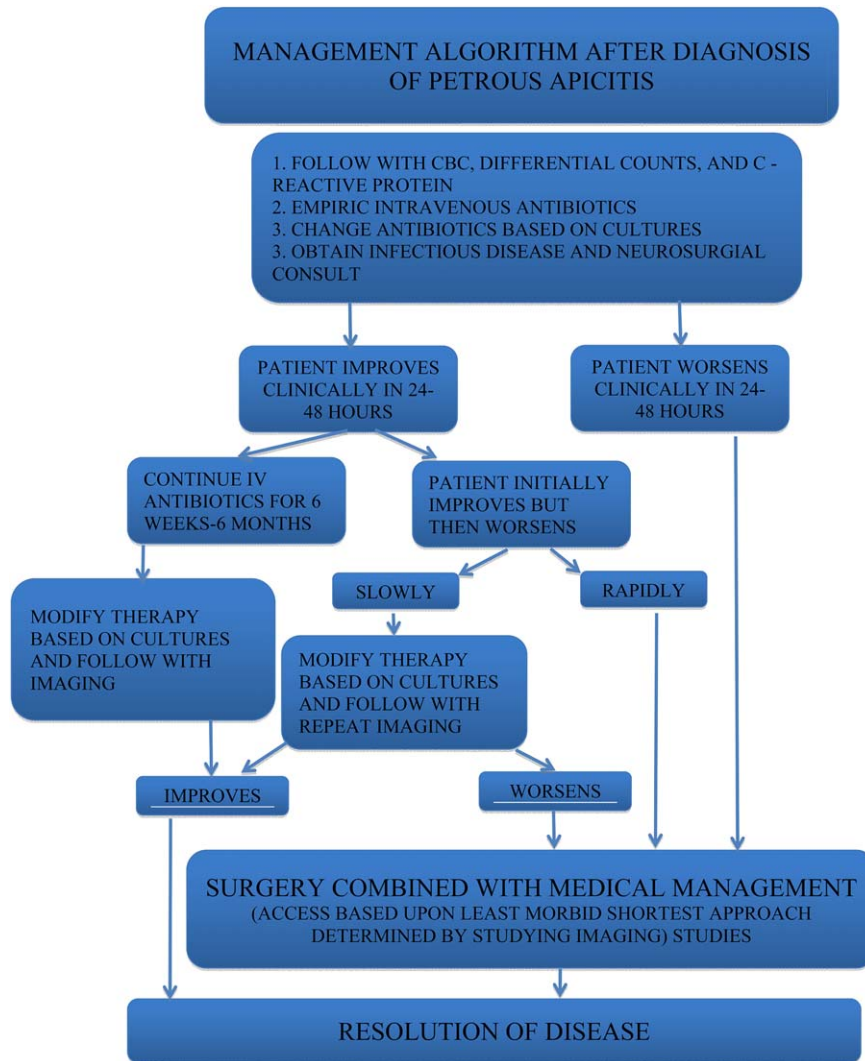
[Color figure can be viewed in the online issue, which is available at www.laryngoscope.com.]

can cause localized bony erosion. With PA there is diminished signal on T1 and an enhanced T2-weighted signal. Rim enhancement on post-Gadolinium T1 scan confirms the presence of suppuration in the PA (Fig. 4).

Differential diagnosis based on MRI characteristics alone includes neoplastic processes such as squamous cell carcinoma, lymphoma, or metastatic lesions. However, there is no elevation in erythrocyte sedimentation rate of C-reactive protein in these patients. Other lesions that may mimic PA on MRI include inflammatory pseudotumor, tuberculosis, and sarcoidosis.²⁸

In skull-base osteomyelitis, Gallium-67 single-photon emission computed tomography scans (⁶⁷Ga bone scan) are used to monitor progression or regression,²⁹ but must be used with caution in the pediatric age group due to the risk of radiation.³⁰ We use it sparingly to follow PA in the face of malignant otitis externa in adults. Follow-up MRI at 2- to 4-week intervals can be used to make certain that the condition is improving.

Retrograde thrombophlebitis involving the petrosal sinuses, but more especially the venules of the petrous



[Color figure can be viewed in the online issue, which is available at www.laryngoscope.com.]

apex, may play a role in the spread of infection in diploic nonpneumatized mastoids.³¹ This may explain the rare cases of cavernous sinus thrombophlebitis complicating PA.

Empiric antibiotic treatment should be started early and modified depending upon response or as culture reports become available. Our current choice includes ceftriaxone along with vancomycin and metronidazole. Recent reports have suggested the sole use of high-dose broad-spectrum antibiotics with intracranial penetration.^{27,30} Medical management is the primary modality of management as opposed to surgical options in the preantibiotic era. In our series, 77% of patients were treated solely with antibiotics. Only 23% underwent some kind of major surgical intervention. Where empiric medical management is concerned, frequently isolated organisms must be considered.²⁷ These include *S pneumoniae*, beta hemolytic streptococci, *Staphylococcus* spp., *Haemophilus influenza*, *Pseudomonas* spp., *Moraxella catarrhalis*, and various anaerobes.³² In chronic otitis media, where granulation tissue is present, gram-negatives and anaerobes predominate.³³ In our series, cultures were

positive in one-third of the patients. The most common organism encountered was *P aeruginosa* (53.3%), followed by *S aureus* (two), *S aureus* with *P aeruginosa* (two), *Propionibacterium* spp. (one), *Streptococcus pneumoniae* (one), and *Provetella* spp. (one). The low yield is most likely due to prior antibiotic use. Anaerobes should be covered even if they are not detected. Our current choice includes ceftriaxone along with vancomycin and metronidazole, and have been used for other intracranial complications.³⁴ Treatment is carried out for 6 weeks. Prolonged therapy of between 6 weeks and 6 months has also been advocated.²⁶ Use of steroids is controversial.

The presence of decreasing immunity from human immunodeficiency virus, diabetes, or immunosuppressive agents and chemotherapeutic drugs may also result in resurgence of infectious processes. Only two patients in the current series were immune compromised; the patient with lymphoma who succumbed to the disease was the sole fatality, whereas a second patient with diabetes and a malignant otitis externa did not.

When we divide our series by decades, a decreasing number required surgery (Tables I, Fig. 6). This may be due to early detection using imaging and the early institution of aggressive medical management.

Vigilance must be maintained when a patient diagnosed with PA fails to show improvement despite antibiotics within a reasonable length of time (24 to 48 hours). However, if the condition continues to progress rapidly, or if the condition worsens after a period of improvement, the surgical option must be pursued. Lempert³⁵ commented, "Nature may be a good doctor...but is a mighty poor surgeon."

Our algorithm is a suggestion to streamline management and help in rational decision making. The algorithm is a suggested solely as a guideline. Management in individual cases may vary. The importance of debridement of devitalized tissue as first-line management of osteomyelitis was stressed by Parsons and Strauss.³⁶ In foot and digit osteomyelitis, Henke et al.³⁷ concluded that preadmission antibiotics increased the development of antibiotic-resistant organisms with worse prognosis. In contrast, in PA, debridement is infrequently required and may be attributed to the rich vascularity of the region. The choice of surgical approach is predicated upon using the shortest least morbid route. Where possible, hearing and facial nerve function should be preserved. Surgery provides the opportunity to obtain cultures and specimens for histopathology. In addition to tumors, tuberculosis and sarcoidosis must be looked for. A high index of suspicion, combined with appropriate imaging studies and prompt therapy is of paramount importance for a favorable outcome in PA.

CONCLUSION

PA is a rare disease. Gradenigo's triad as a manifestation of PA is rarer still. Abducens nerve palsy is not a sine quo non of PA. Compared to the preantibiotic era, the incidence of PA in children appears to have decreased, and most cases are in adults. Changing epidemiologic trends and less reliance on surgery may be due to early detection with the use of imaging, along with the judicious use of antibiotics. A high level of vigilance and a familiarity with various surgical approaches is vital for the successful management of patients with this rare but still nonextinct condition.

Acknowledgments

The help of Professor Maurizio Barbara, Rome, Italy; Dr. Didier Portmann and Veronique Lombard of the Institut Portman, Bordeaux, France; Professor Diego Zanetti, Milan, Italy; and Dr. Bechara Ghorayeb, Houston, Texas is acknowledged.

BIBLIOGRAPHY

- DeWeese DD. Four unusual cases of temporal bone disease. *Laryngoscope* 1958;68:1028-1035.
- Goldstein NA, Casselbrant ML, Bluestone CD, et al. Intratemporal complications of acute otitis media in infants and children. *Otolaryngol Head Neck Surg* 1998;119:444-454.
- Chole RA, Donald PJ. Petrous apicitis clinical considerations. *Ann Otol Rhinol Laryngol* 1983;92:544-551
- Myerson MC. Suppuration of the petrous pyramid some views on its surgical management *Arch Otolaryngol* 1937;26:42-48.
- Gradenigo G. Ueber Circumscripthe Leptomeningitis mit spinalen Symptomen. *Arch Ohrenheilk* 1904;51:60-62.
- Gradenigo G. Ueber die Paralyse des Nervus abducens bei Otitis Gradenigo, G. *Arch Ohrenheilkunde* 1907;774:149-187.
- Panse R. Discussion. *Int Centralbl Ohrenheilk* 1905;3:51.
- Frenckner P. Some remarks on the treatment of apicitis (petrositis) with or without Gradenigo's syndrome. *Acta Otolaryngol* 1932;17:97-120.
- Haymann L. Zur Kenntnis der Entstehung der otogenen Meningitis. *Zeitschr HNO* 1927;18:319.
- Profant HJ. Gradenigo's Syndrome with a consideration of "Petrositis". *Arch Otolaryngol* 1931;13:347-378.
- Uffenorde W. Eine zu vielfachen Verwickelungen fuhrende, sehrausgedehnte perilyabyrinthare Eiterung im histologischen Bilde. *Arch Ohren Nasen Kehlkopf* 1929;122:288.
- Eagleton WP. Unlocking of the petrous pyramid for localized bulbar (pontine) meningitis secondary to suppuration of the petrous apex. Report of four cases with recovery in three. *Arch Otolaryngol* 1931;13:387-422.
- Meltzer PE. Gradenigo's Syndrome anatomic aspects. *Arch Otolaryngol* 1931;13:87-93.
- Papale. Contributo alla patogenesi della sindrome di Gradenigo. *Ref. Zentralbl. f. HNO Band 6*. In: Frenckner P. Some remarks on the treatment of apicitis (petrositis) with or without Gradenigo's Syndrome. *Acta Otolaryngol* 1932;17:97-120.
- Papale. Considerazioni sulla patogenesi della "sindrome di Gradenigo." *Ref. Zentralbl. f. HNO Band 11*. In: Frenckner P. Some remarks on the treatment of apicitis (petrositis) with or without Gradenigo's Syndrome. *Acta Otolaryngol* 1932;17:97-120.
- Pietrantonio. Sulle vie di propagazione dei processi infiammatori dall'orecchio medio aa'apice della roca petrosa etc. *Ref. Zentralbl. f. HNO Band 11*, 1928. In: Frenckner P. Some remarks on the treatment of apicitis (petrositis) with or without Gradenigo's Syndrome. *Acta Otolaryngol* 1932;17:97-120.
- Dorello P. Ueber die Ursache der Transitorischen Abduzenslaehmung. *Int Zentralbl Ohrenheilkunde Rhinologyngol* 1906;4:418-419.
- Vogel H. Der sogenannte Gradenigosche Symptomenkomplex. *Int Centralbl Ohrenheilk* 1920-1921;18:293 and 1922;19:1.
- Kopetzky SJ, Almour A. The suppuration of the petrous pyramid: pathology, symptomatology and surgical treatment. Part I. *Ann Otol Rhinol Laryngol* 1930-1931;39-40.
- Sears WH. Gradenigo Syndrome. *Laryngoscope* 1927;37:32.
- Chole RA. Petrous apicitis: surgical anatomy. *Ann Otol Rhinol Laryngol* 1985;94:251-257.
- Jackler RK, Parker DA. Radiographic differential diagnosis of petrous apex lesions. *Am J Otol* 1992;13:561-574.
- Price T, Fayad G. Abducens nerve palsy as the sole presenting symptom of petrous apicitis. *J Laryngol Otol* 2002;116:726-729.
- Homer JJ, Johnson IJ, Jones NS. Middle ear infection and sixth nerve palsy. *J Laryngol Otol* 1996;110:872-874.
- Motamed M, Kalan A. Gradenigo's syndrome. *Postgrad Med J* 2000;76:559-560.
- Gillanders DA. Gradenigo's syndrome revisited. *J Otolaryngol* 1983;12:169-174.
- Burston BJ, Pretorius PM, Ramsden JD. Gradenigo's syndrome: successful conservative treatment in adult and pediatric patients. *J Laryngol Otol* 2005;119:325-329.
- Connor SEJ, Leung R, Natas S. Imaging of the petrous apex: a pictorial review. *Br J Radiol* 2008;81:427-435.
- Lee YH, Lee NJ, Kim JH, Song JJ. CT, MRI and gallium SPECT in the diagnosis and treatment of petrous apicitis presenting as multiple cranial neuropathies. *Br J Radiol* 2005;78:948-951.
- Gibier L, Darrouzet V, Franco-Vidal V. Gradenigo syndrome without acute otitis media. *Pediatr Neurol* 2009;41:215-219.
- Gadre AK, Brodie HA, Fayad JN, O'Leary MJ. Venous channels of the petrous apex: their presence and clinical importance. *Otolaryngol Head Neck Surg* 1997;116:168-174.
- Canter R. Acute suppurative otitis media. In: Kerr A, Booth J, eds. *Scott-Brown's Otolaryngology*. 6th ed. London, United Kingdom: Butterworth-Heinemann; 1997;3/91-8.
- Ludman H. Complications of suppurative otitis media. In: Kerr A, Booth J, eds. *Scott-Brown's Otolaryngology*. 6th ed. London, United Kingdom: Butterworth-Heinemann; 1997;3/121-7.
- Wanna GB, Dharamsi LM, Moss JR, Bennett ML, Thompson RC, Haynes DS. Contemporary management of intracranial complications of Otitis media. *Otol Neurotol* 2010;31:111-117.
- Lempert J. Complete apicectomy. *New York State J Med* 1936;36:1210-1218.
- Parsons B, Strauss E. Surgical management of chronic osteomyelitis. *Am J Surg* 2004;188:57-66.
- Henke PK, Blackburn SA, Wainess, et al. Osteomyelitis of the foot and toe in adults is a surgical disease: conservative management worsens lower extremity salvage. *Ann Surg* 2005;241:885-894.