




Cranial nerves

Dalibor Kolesár
Department of Anatomy

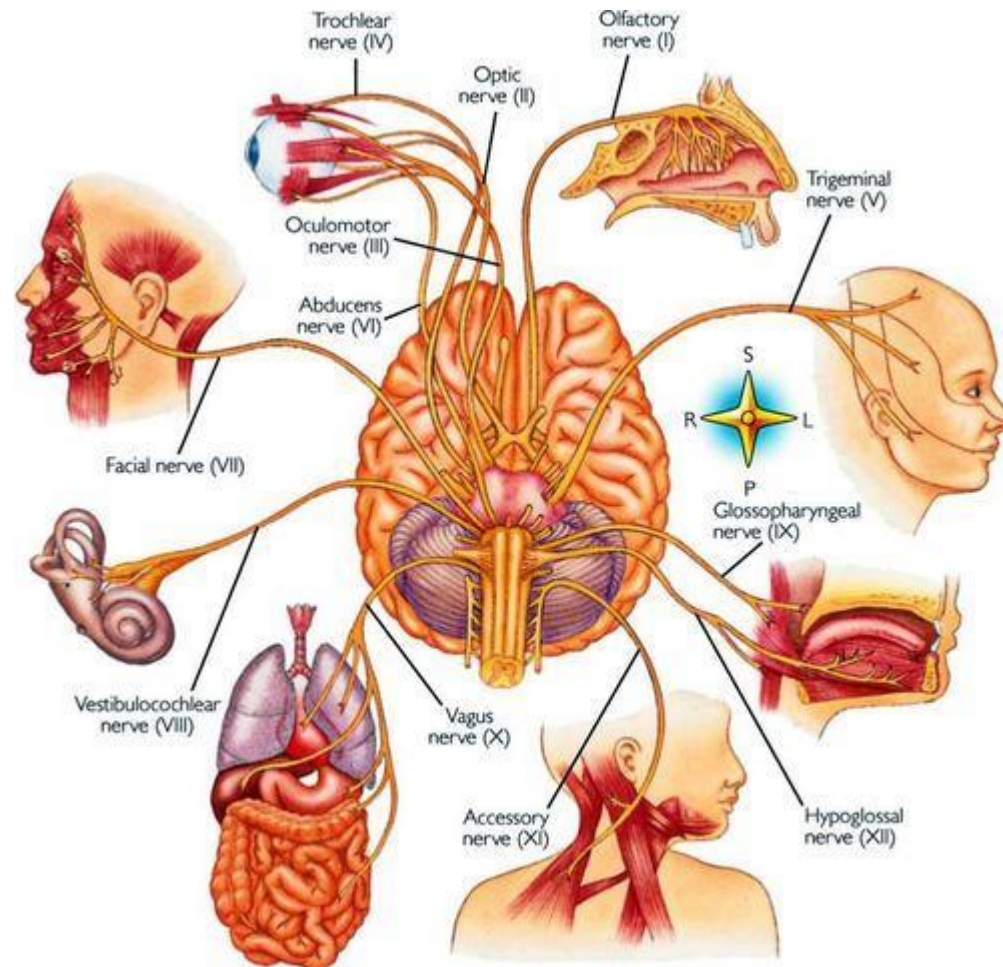


Co-funded by the
Erasmus+ Programme
of the European Union

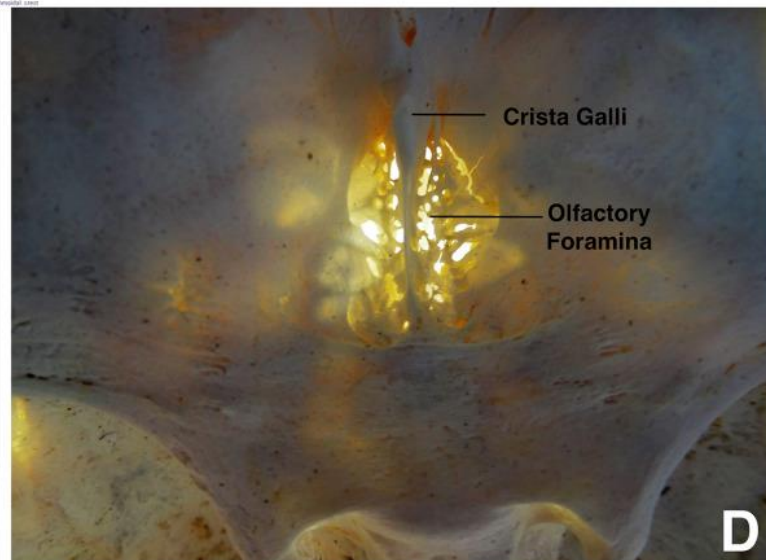
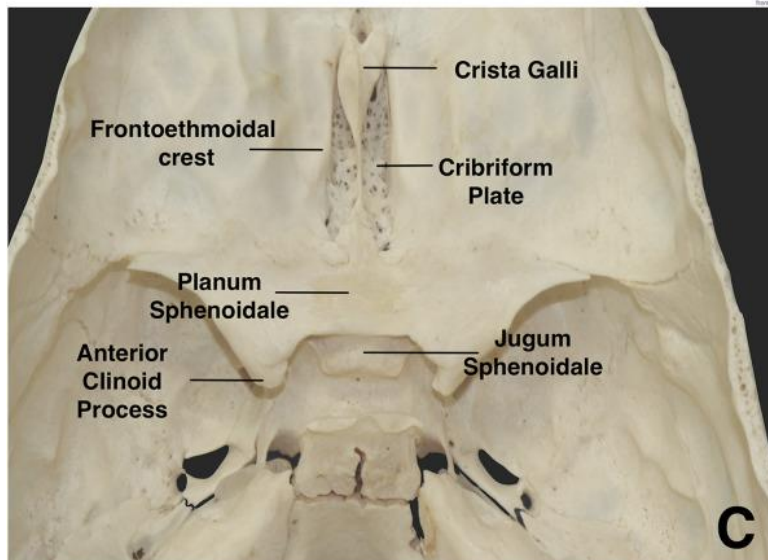
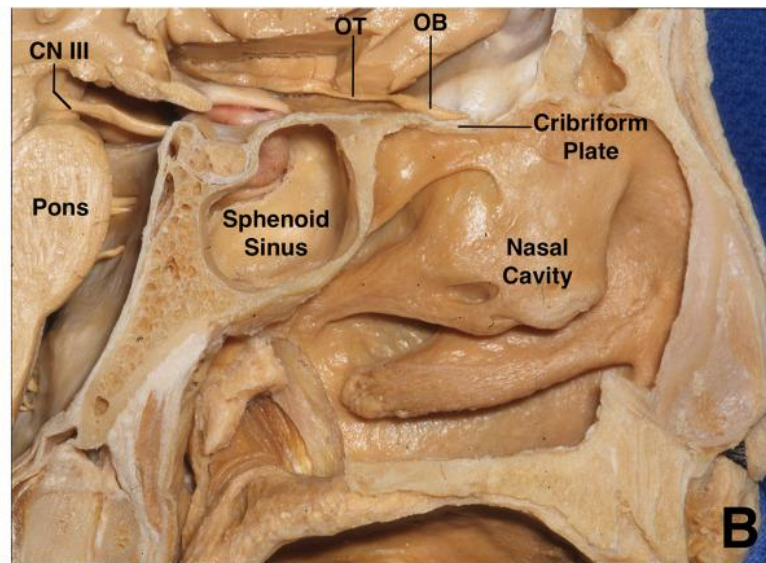
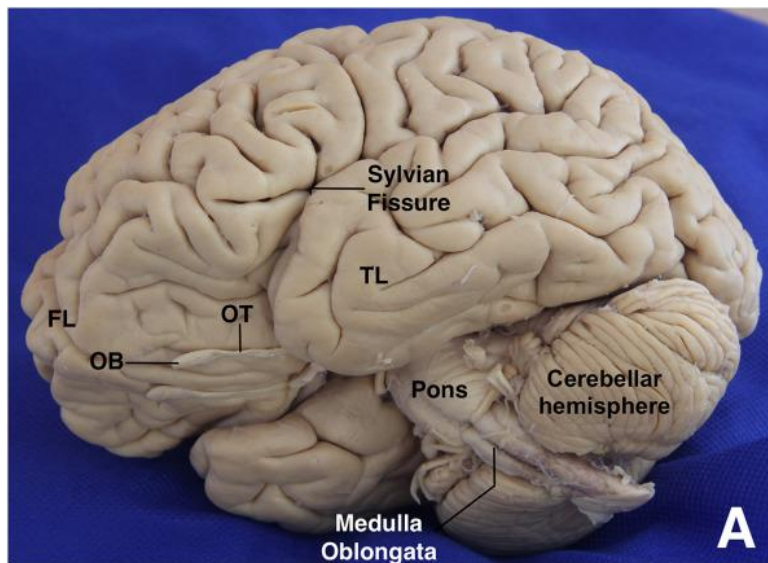
MediTec: Training for students
1. -15.9.2019 UPJŠ, Košice, Slovakia



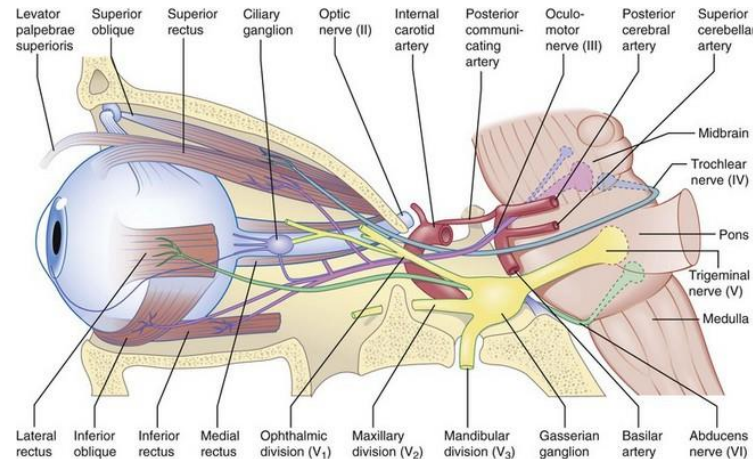
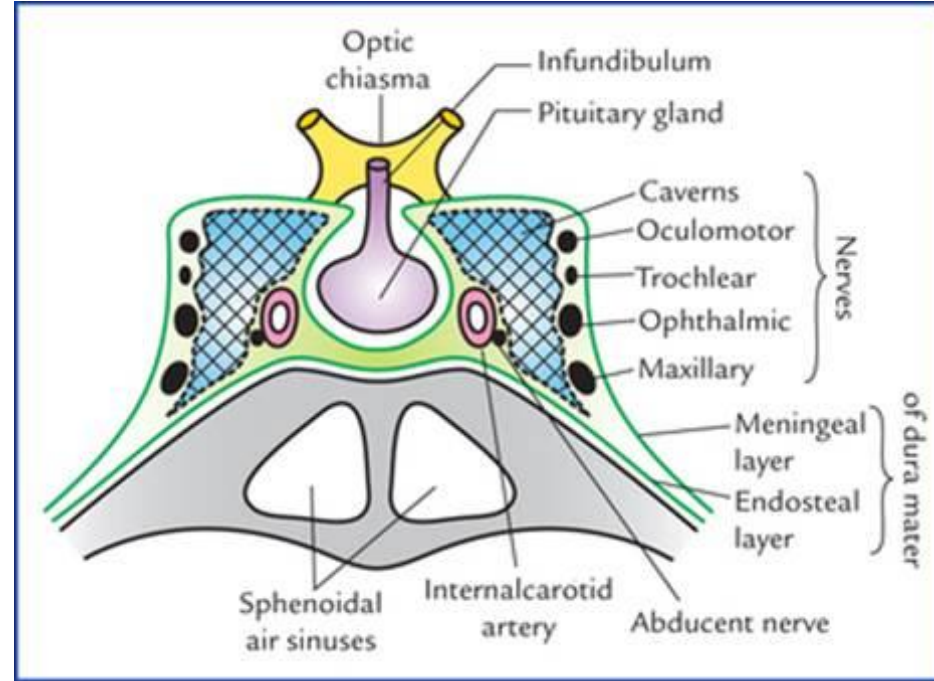
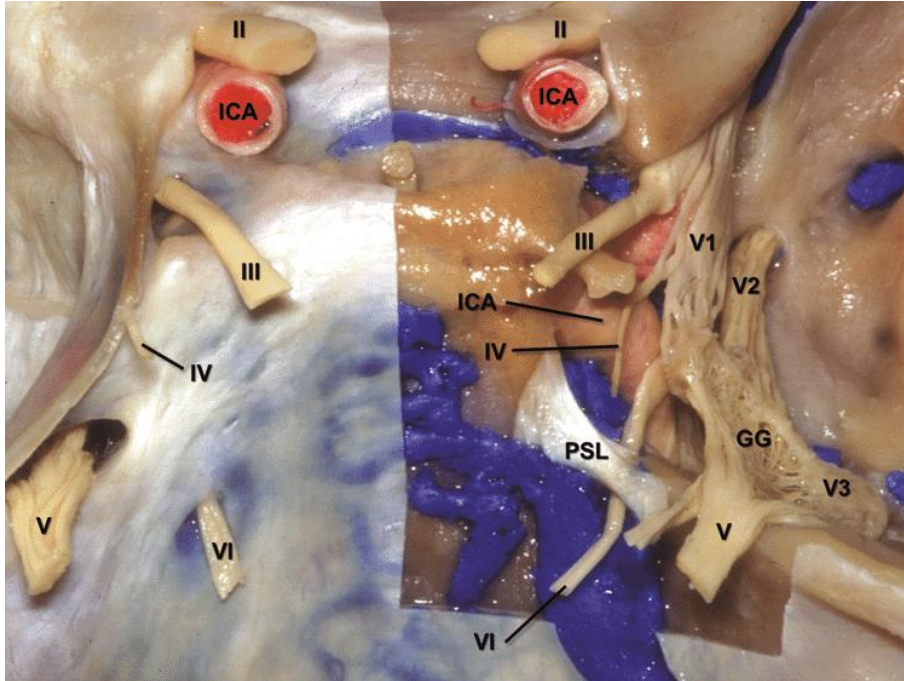
Nervi craniales I – VII, Plexus cervicalis (Cranial nerves I – VII, Cervical plexus)



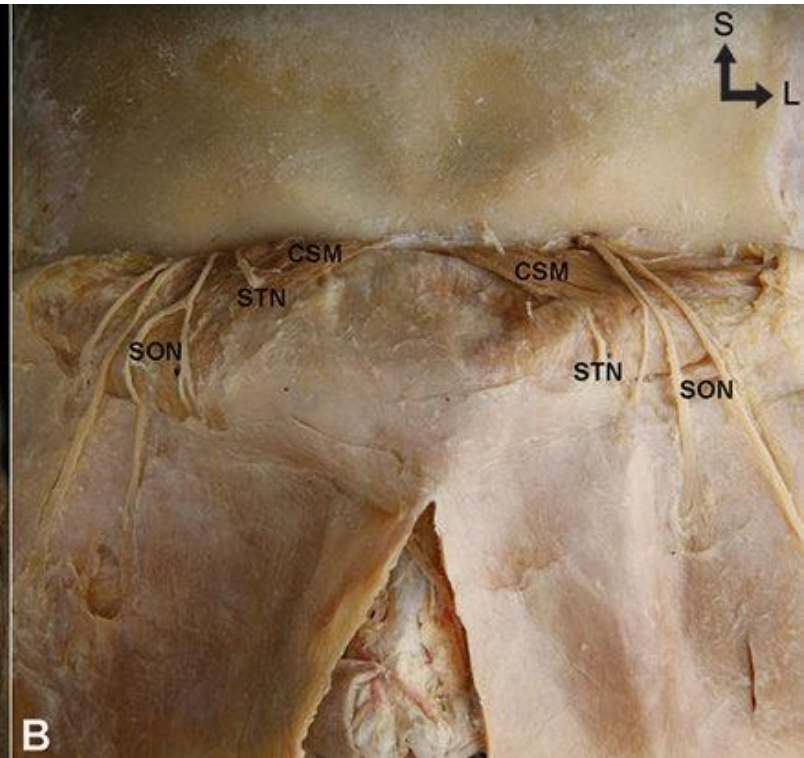
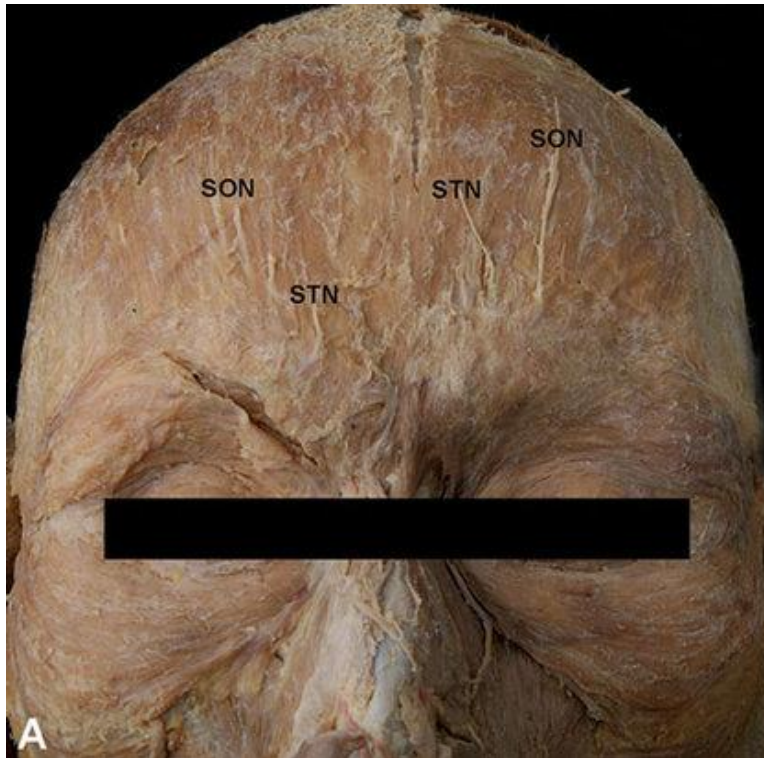
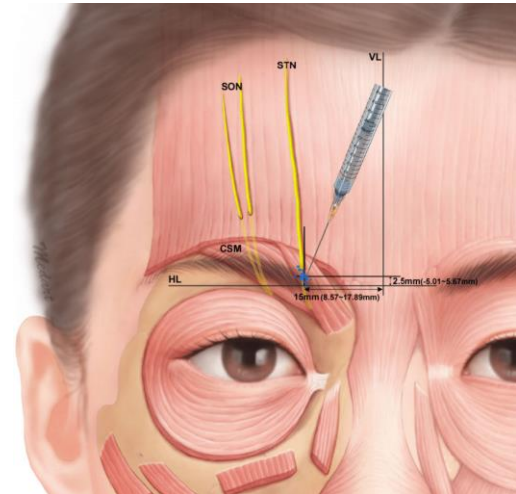
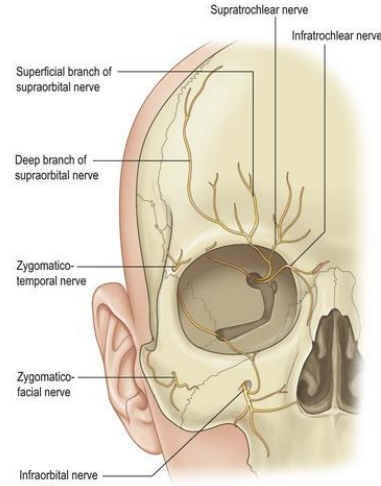
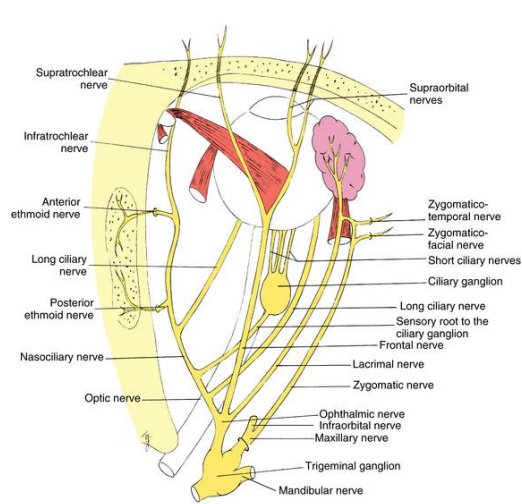
N. Olfactorius (Olfactory n.)



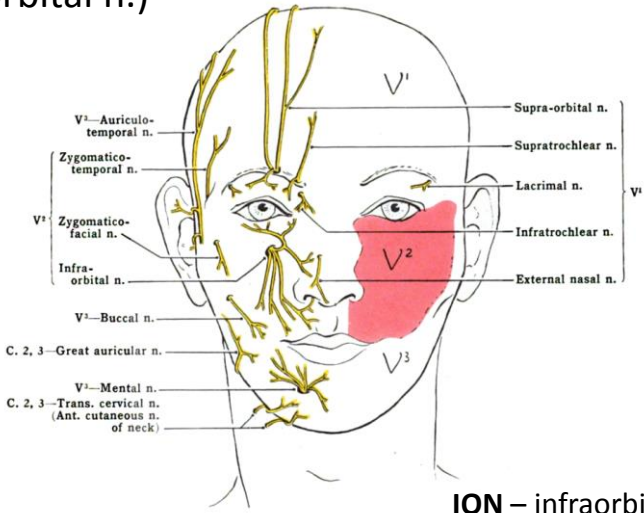
N. oculomotorius, n. trochlearis, n. abducens (Oculomotor n., trochlear n., abducens n.)



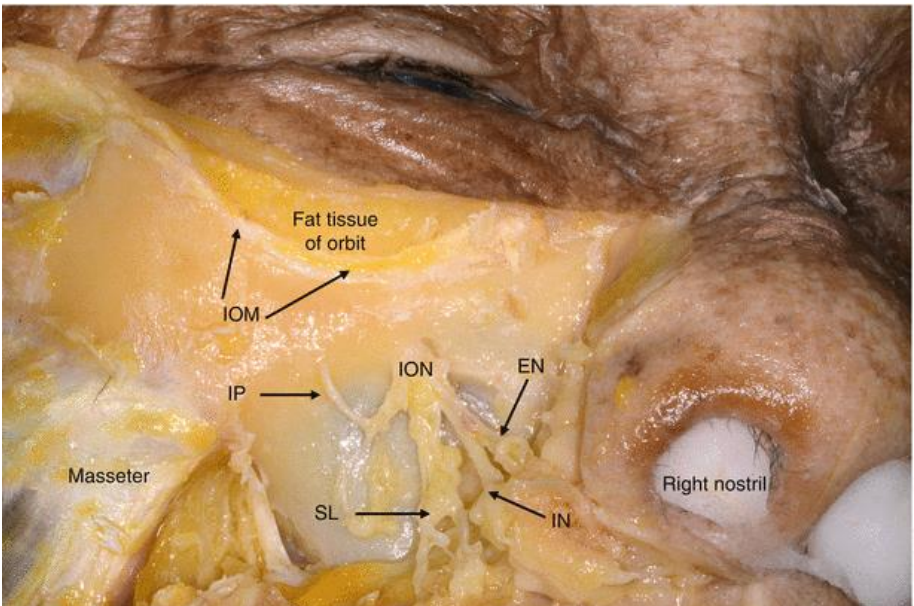
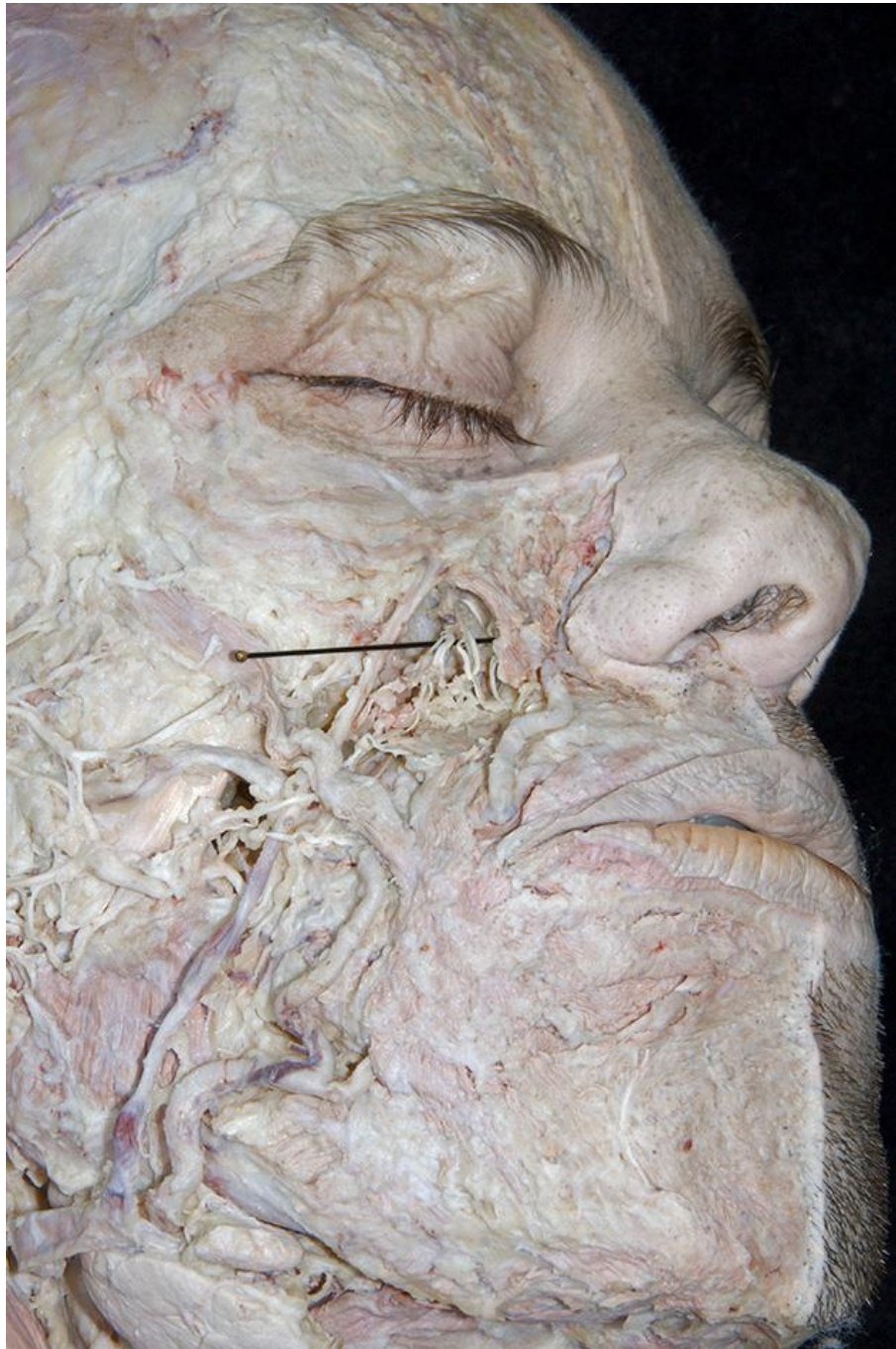N. supraorbitalis et supratrochlearis (Supraorbital and supratrochlear nn.)

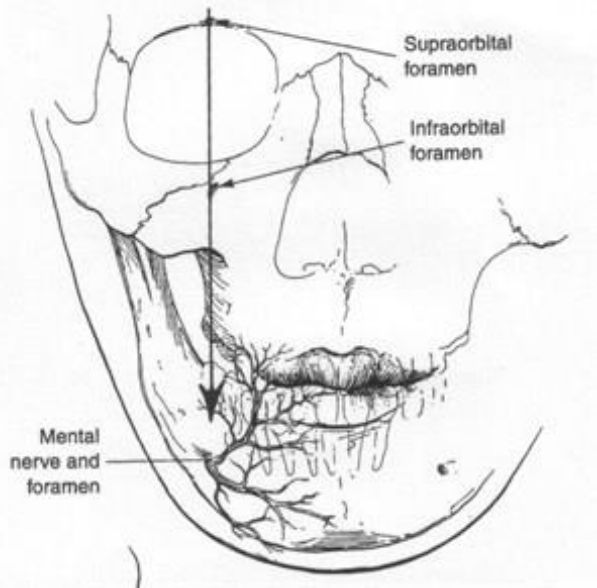


N. infraorbitalis (Infraorbital n.)

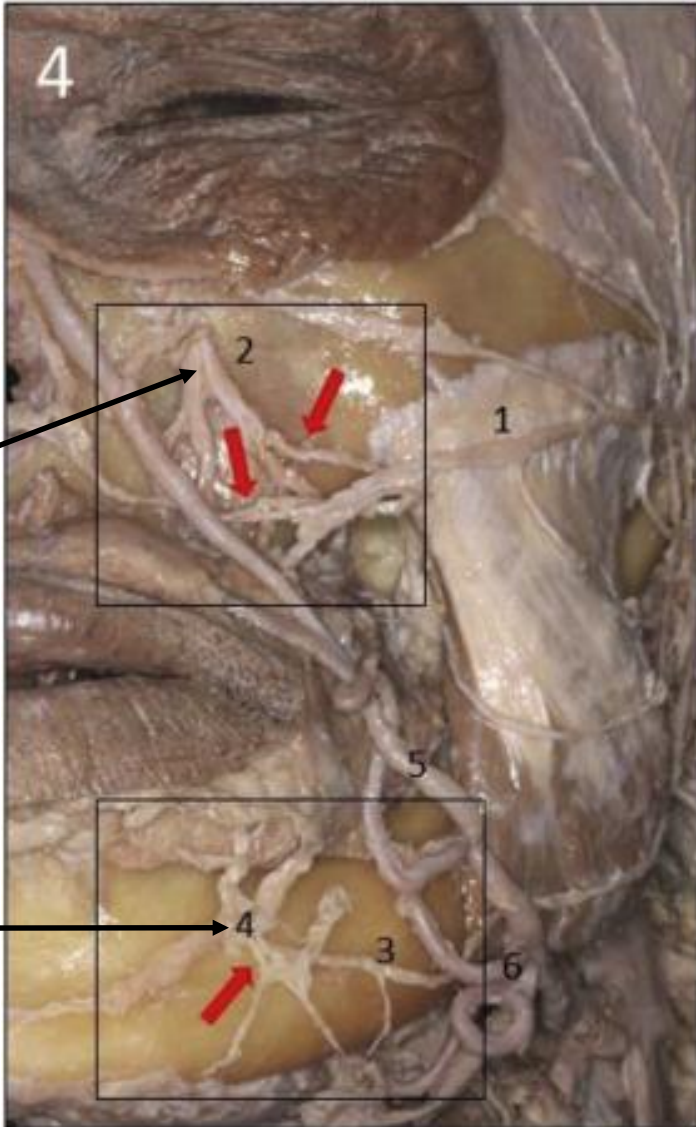


- ION** – infraorbital n.
- EN** – external nasal br.
- IN** – internal nasal br.
- SL** – superior labial br.
- IP** – inferior palpebral br.



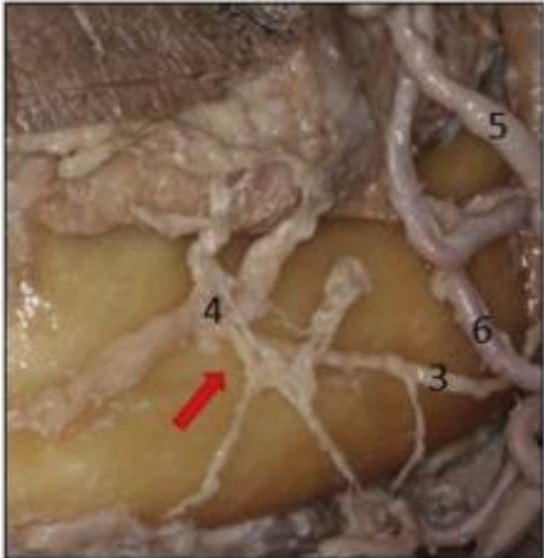
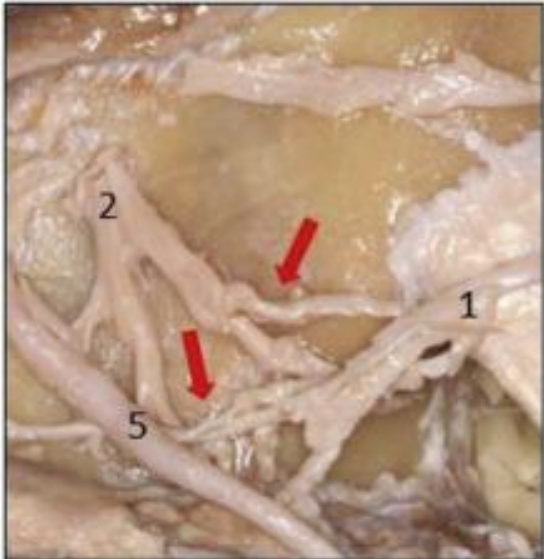


N. mentalis (Mental n.)

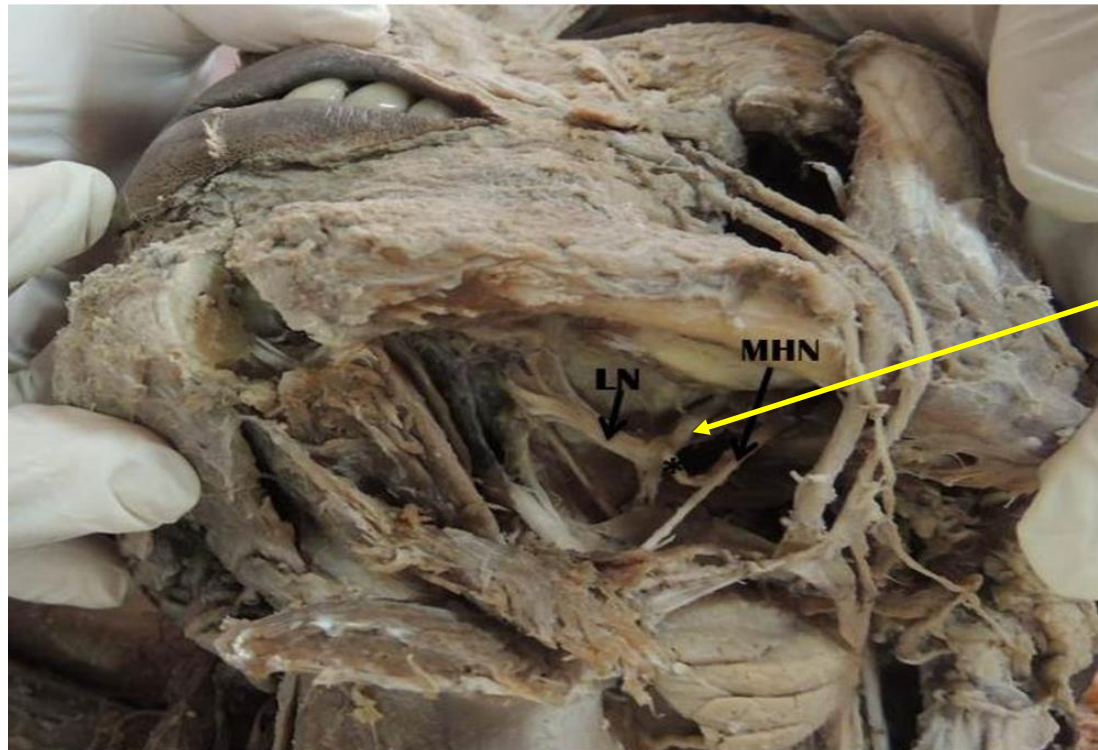
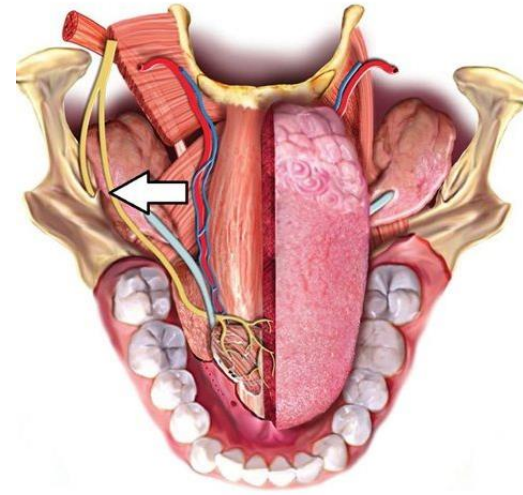
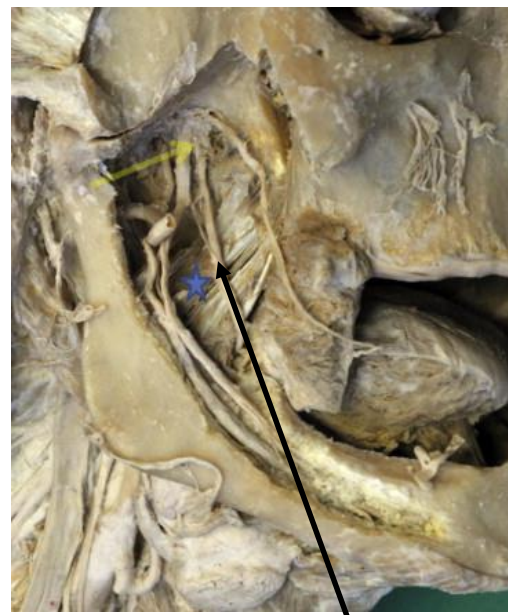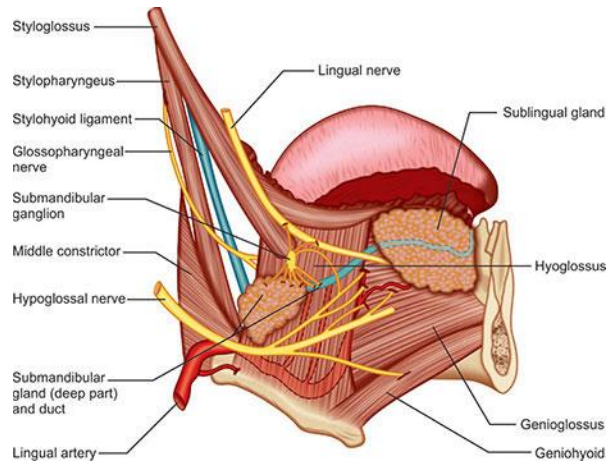


infraorbital n.

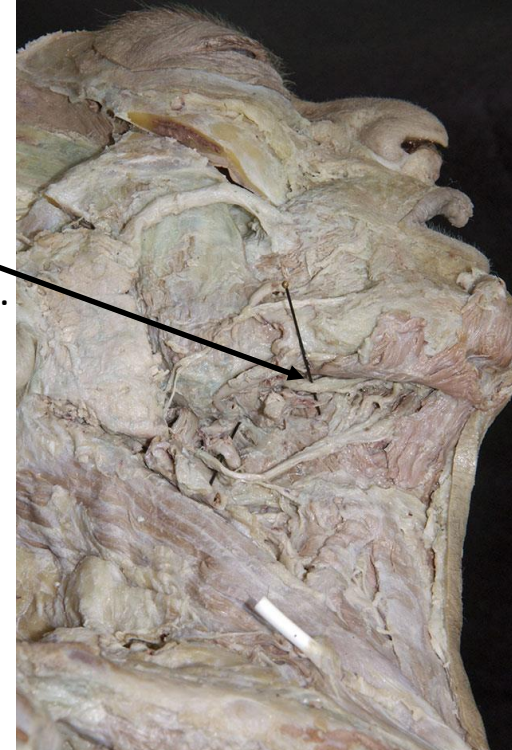
mental n.



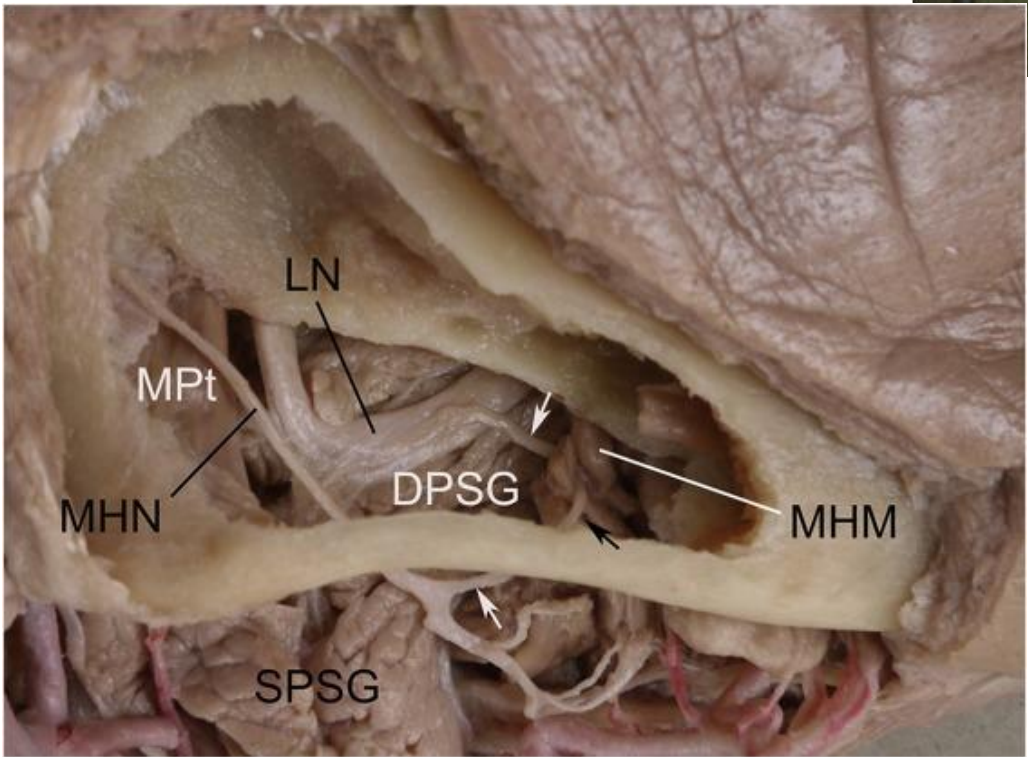
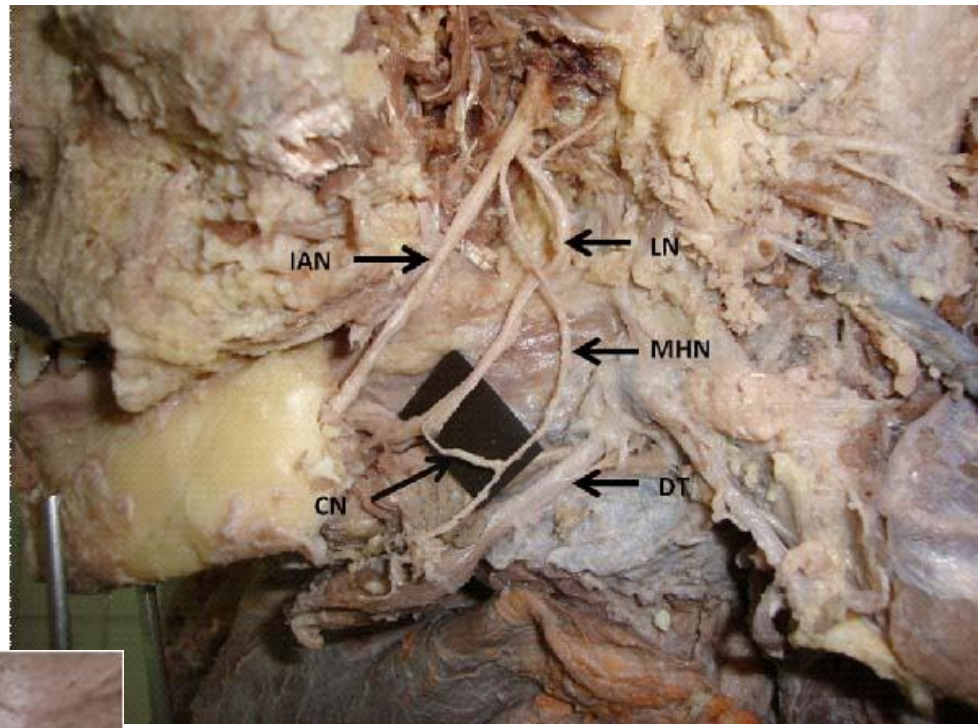
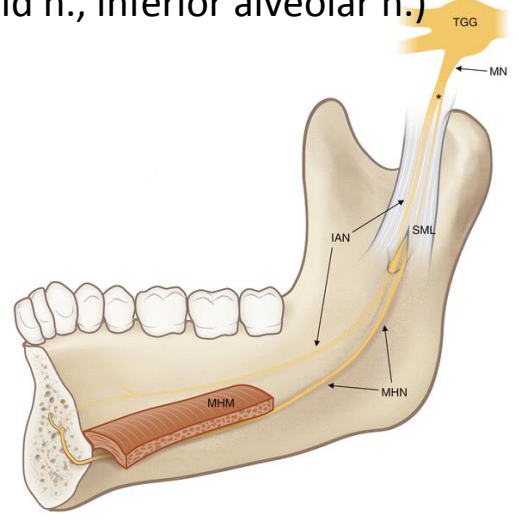
N. lingualis et mylohyoideus (Lingual and mylohyoid nn.)



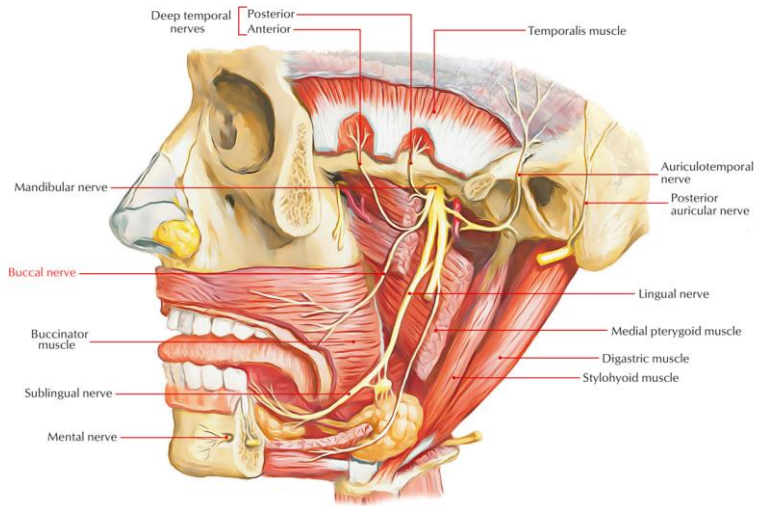
Lingual n.



N. lingualis, n. mylohyoideus, n. alveolaris inferior
 (Lingual n., mylohyoid n., inferior alveolar n.)

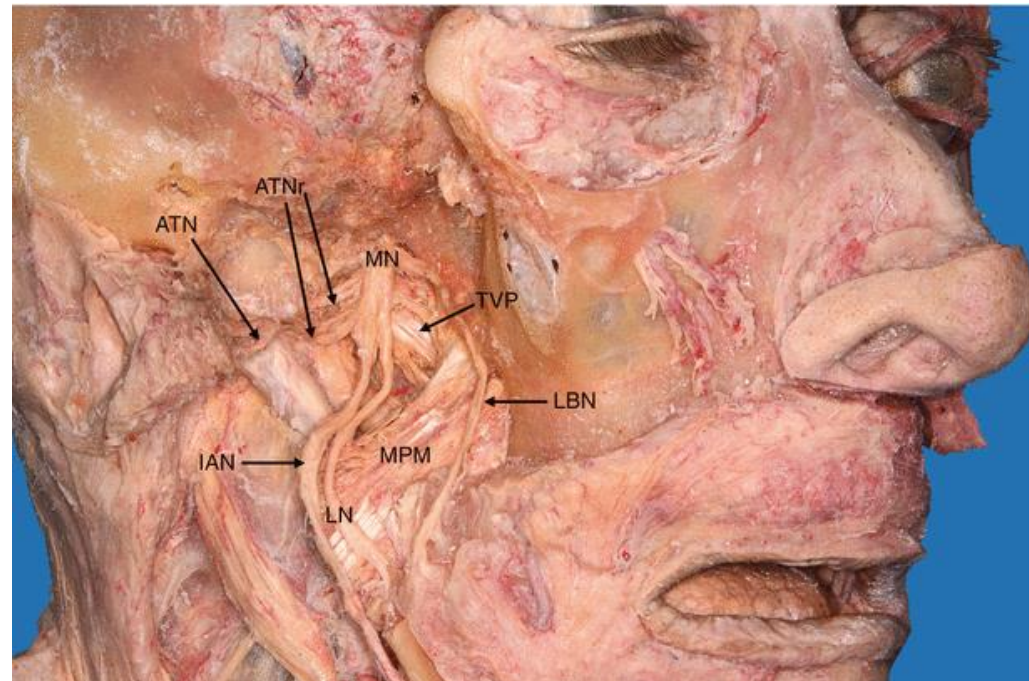
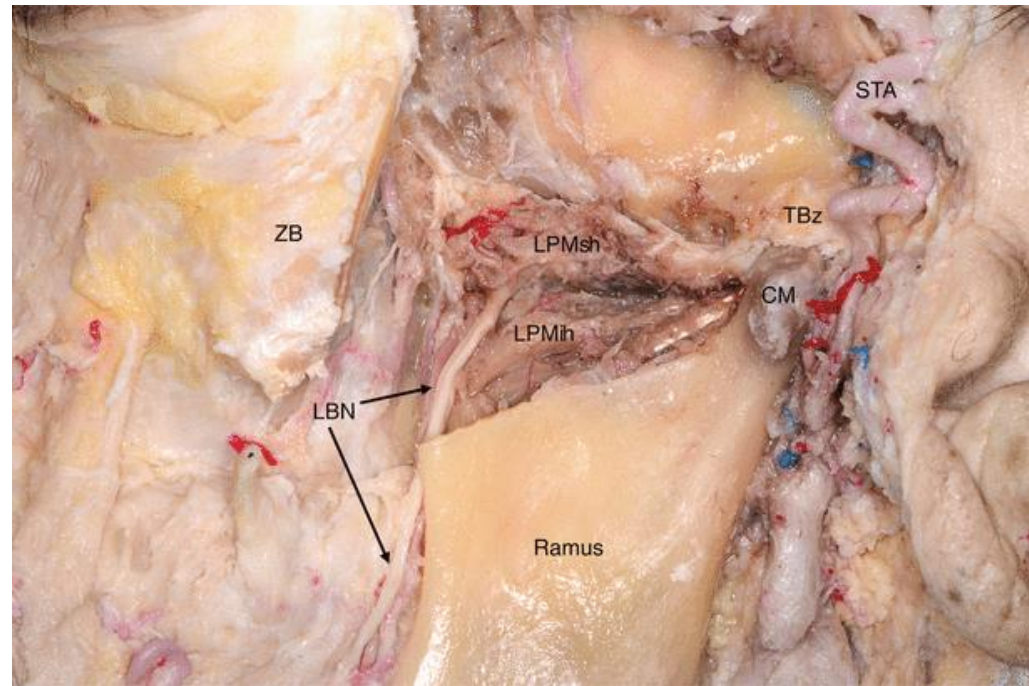


- LN** – lingual n.
- MHN** – mylohyoid n.
- IAN** – inferior alveolar n.
- MPT** – medial pterygoid m.
- MHM** – mylohyoid m.
- DPSG** – deep part of submandibular gland
- SPSG** – superficial part of submandibular gland

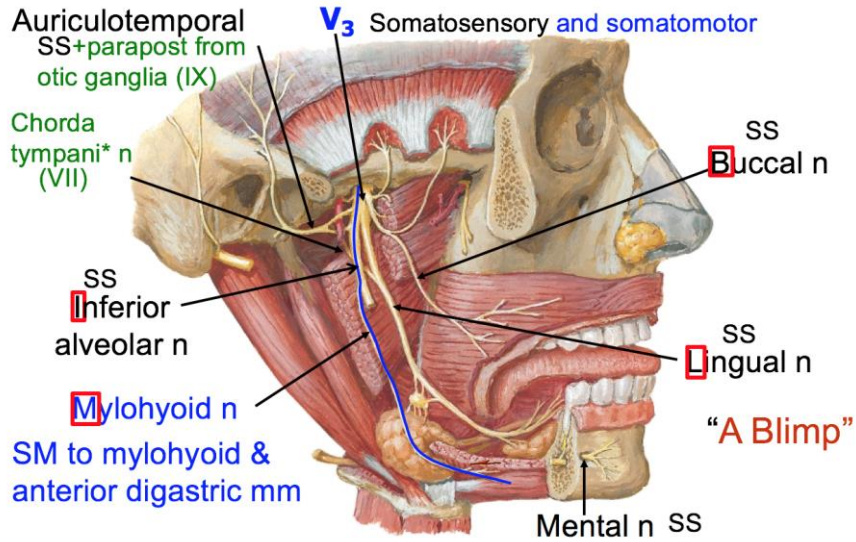


N. buccalis (Buccal n.)

- MN** – mandibular n.
- LBN** – buccal n.
- IAN** – inferior alveolar n.
- LN** – lingual n.
- ATN** – auriculotemporal n.
- MPM** – medial pterygoid m.
- LPM** – lateral pterygoid m.

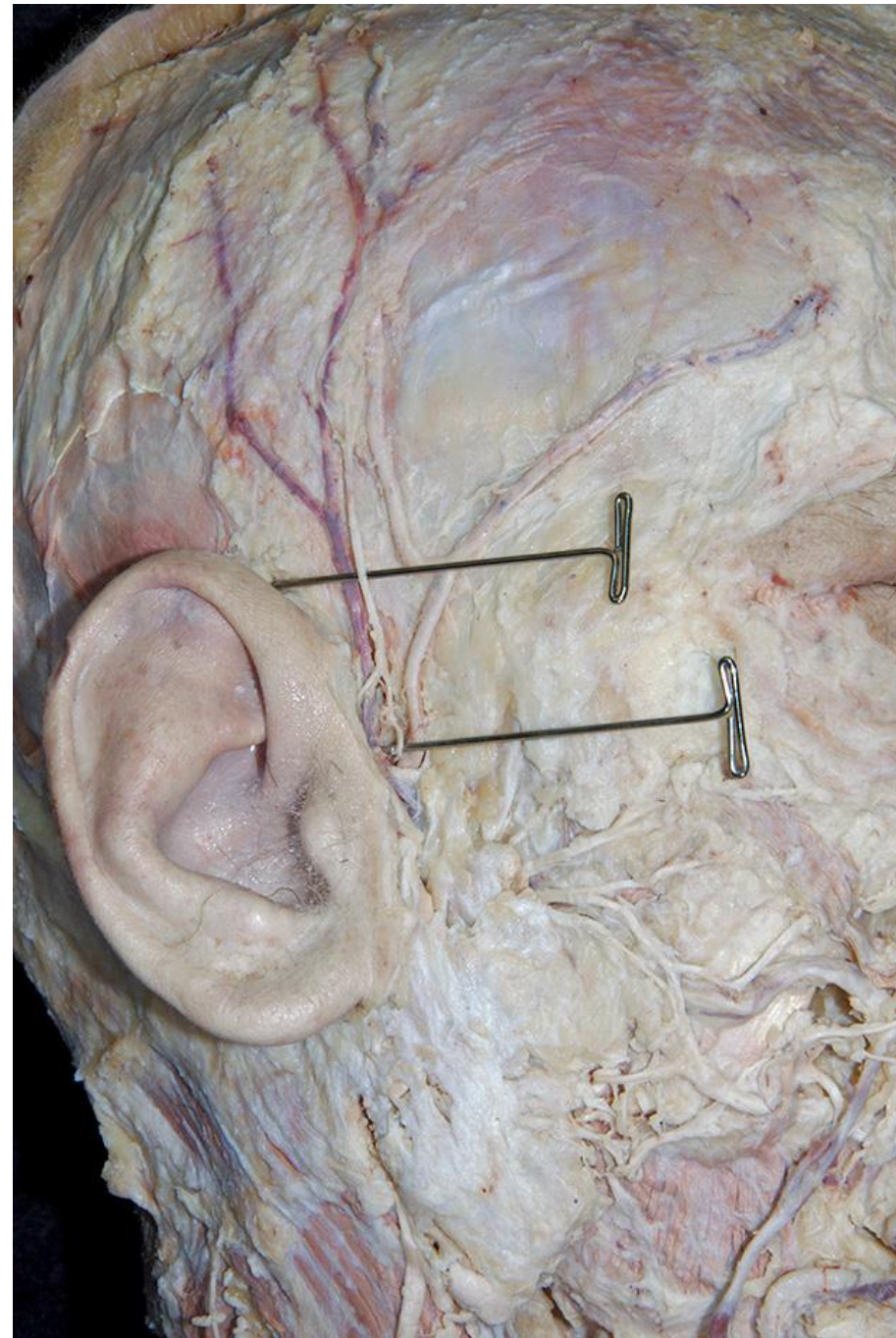
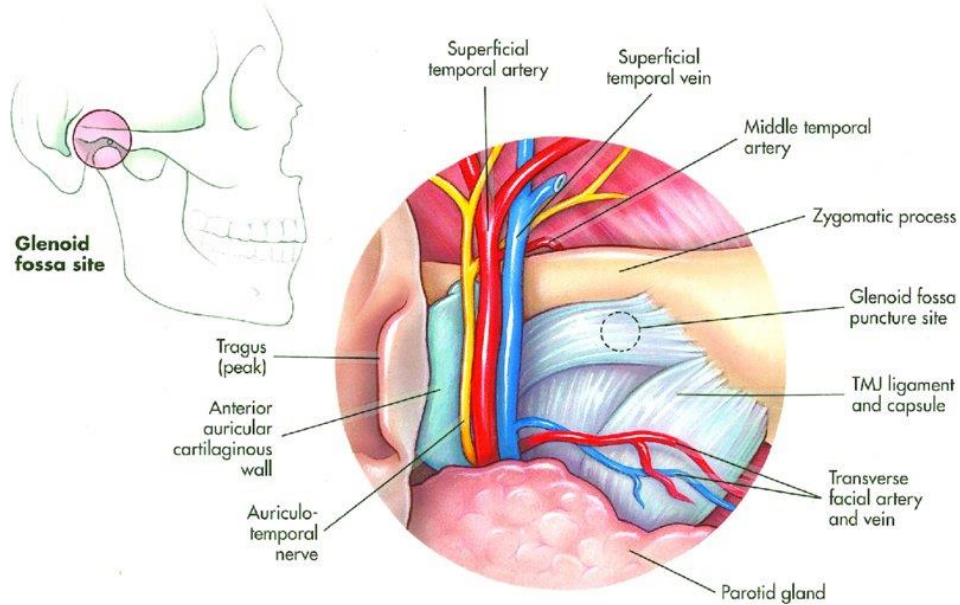


MANDIBULAR NERVE (V₃)



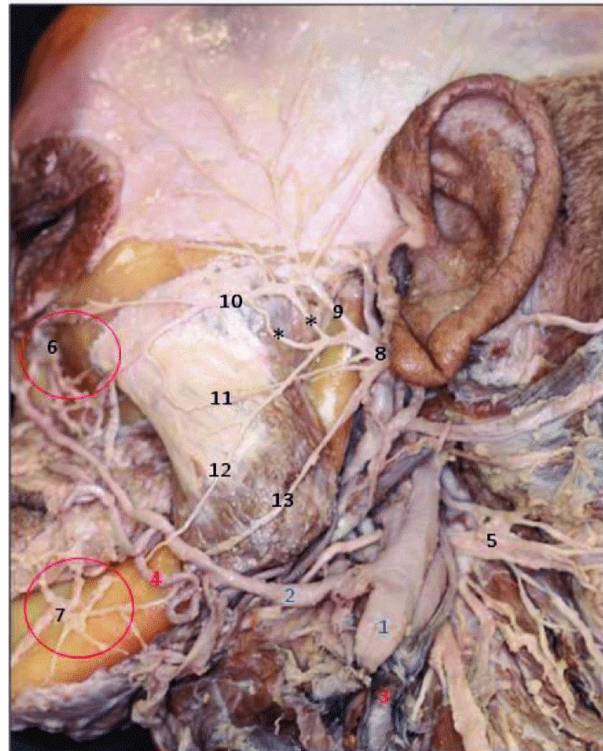
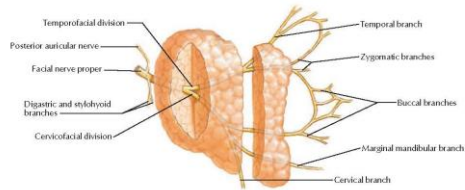
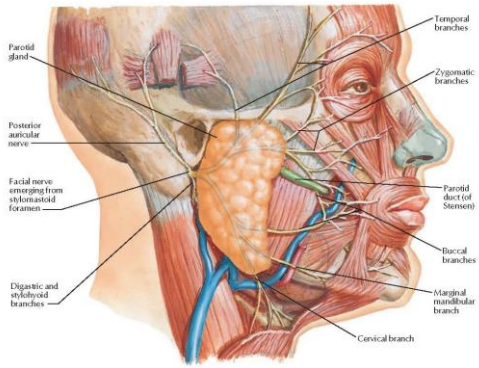
* Taste & parasympathetic pre-ganglionic

N. auriculotemporalis (Auriculotemporal n.)

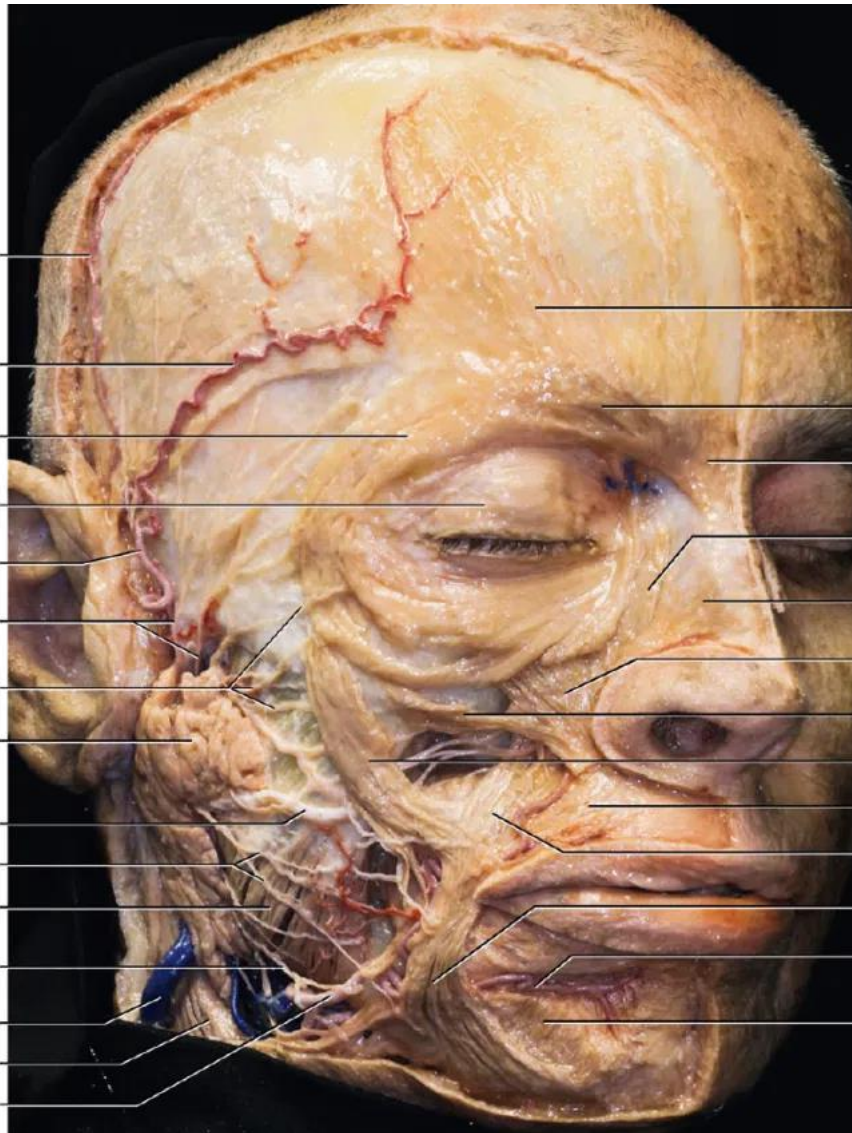


Pes anserinus major

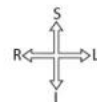
- 9 – tympanic br.
- 10 – zygomatic br.
- 11, 12 – buccal br.
- 13 – marginal mandibular br.

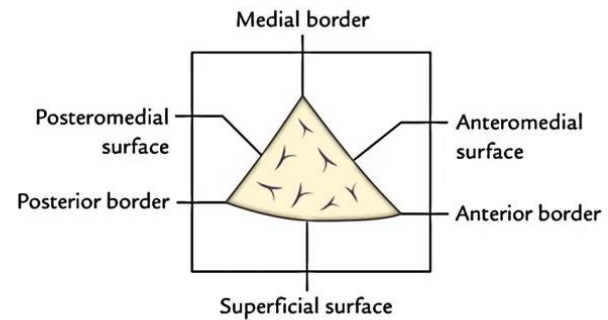
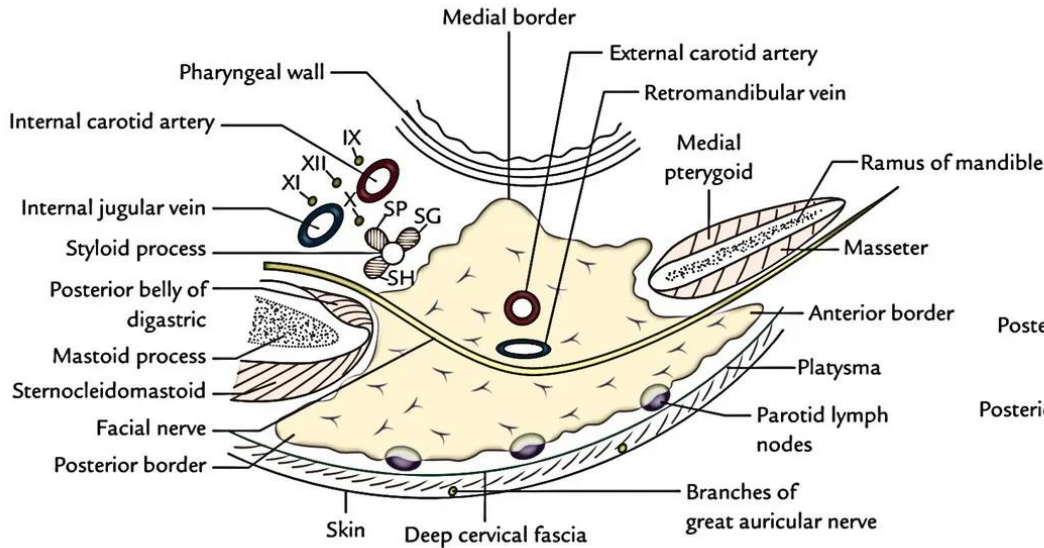
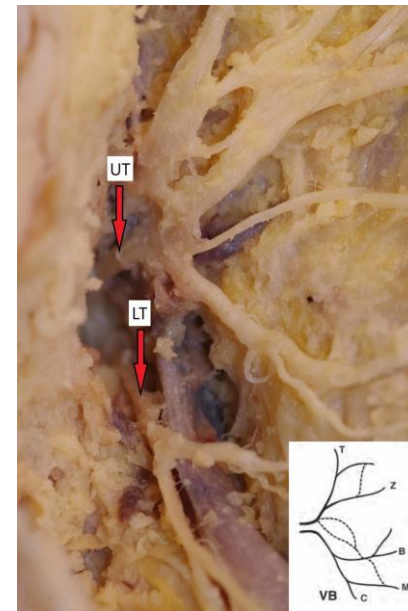
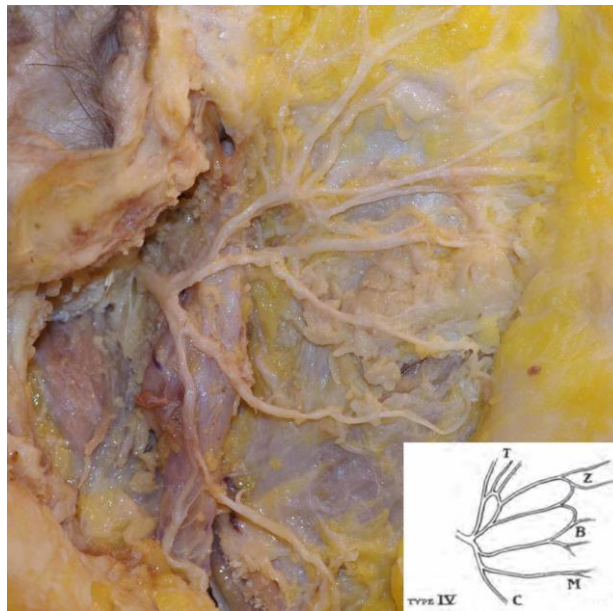
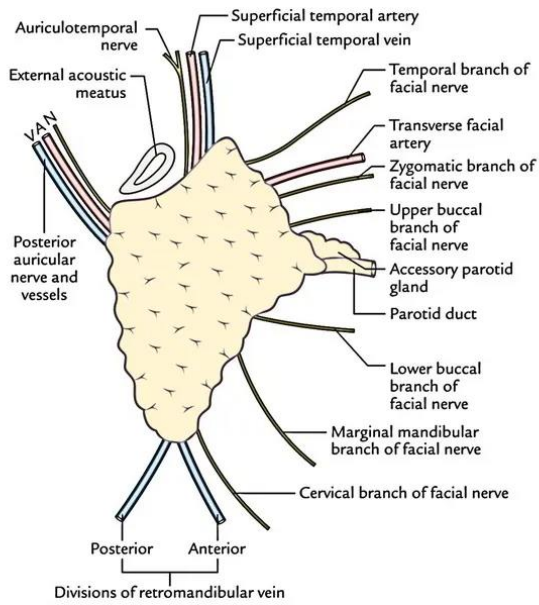


- Superficial temporal artery, parietal branch
Arteria temporalis superficialis, ramus parietalis
- Superficial temporal artery, frontal branch
Arteria temporalis superficialis, ramus frontalis
- Orbicularis oculi muscle, orbital part
Musculus orbicularis oculi, pars orbitalis
- Orbicularis oculi muscle, palpebral part
Musculus orbicularis oculi, pars palpebralis
- Superficial temporal artery
Arteria temporalis superficialis
- Facial nerve, temporal branches
Nervus facialis, rami temporales
- Facial nerve, zygomatic branches
Nervus facialis, rami zygomatici
- Parotid gland
Glandula parotidea
- Parotid duct
Ductus parotidicus
- Facial nerve, buccal branches
Nervus facialis, rami buccales
- Masseter muscle
Musculus masseter
- Facial nerve, marginal mandibular branch
Nervus facialis, ramus marginalis mandibularis
- External jugular vein
Vena jugularis externa
- Sternocleidomastoid muscle
Musculus sternocleidomastoideus
- Facial artery
Arteria facialis

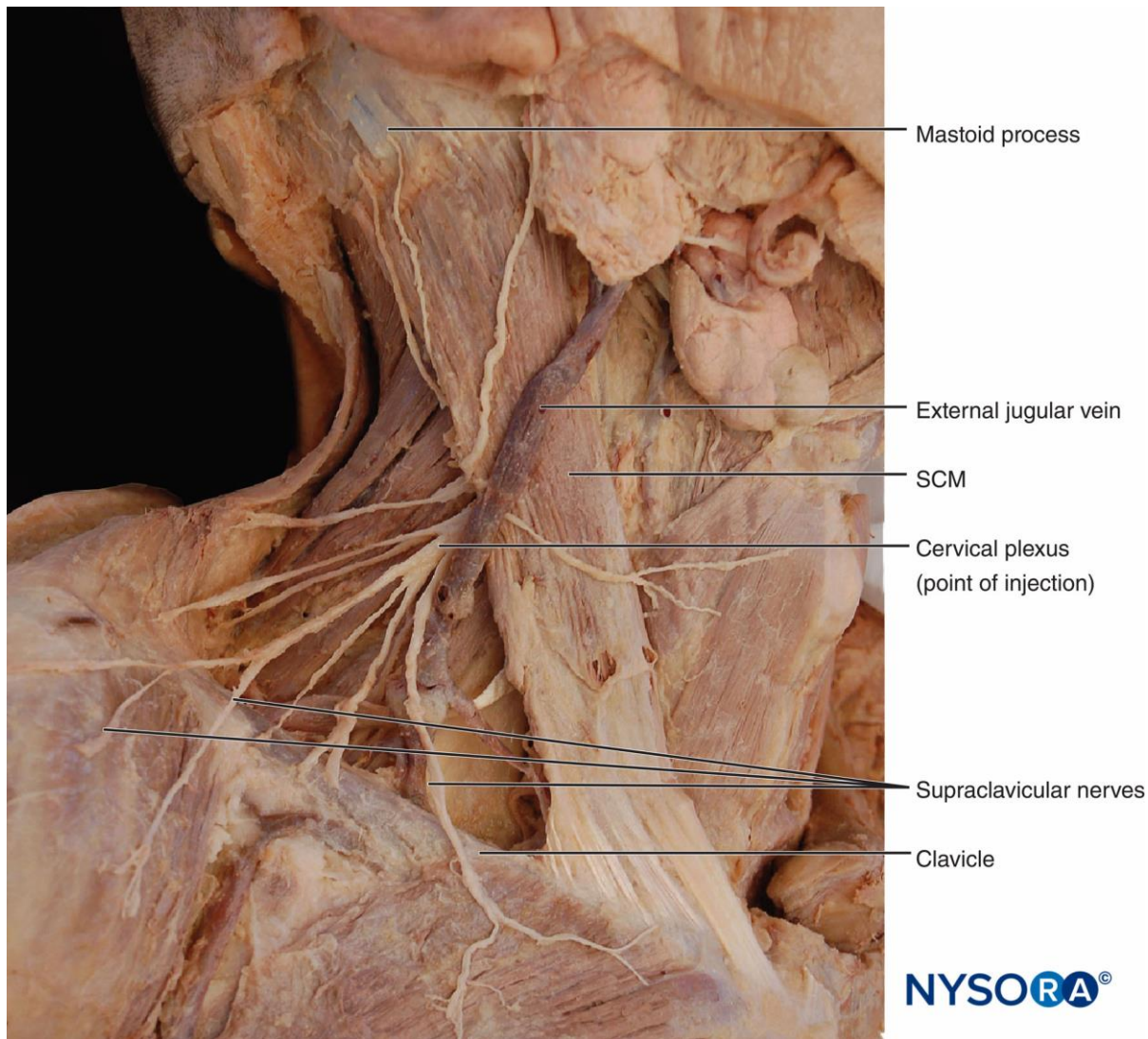
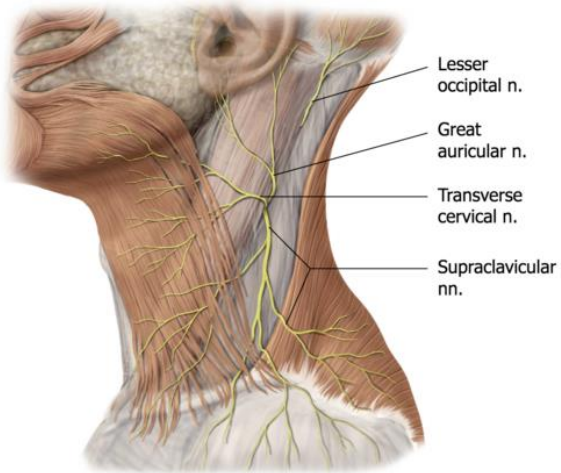
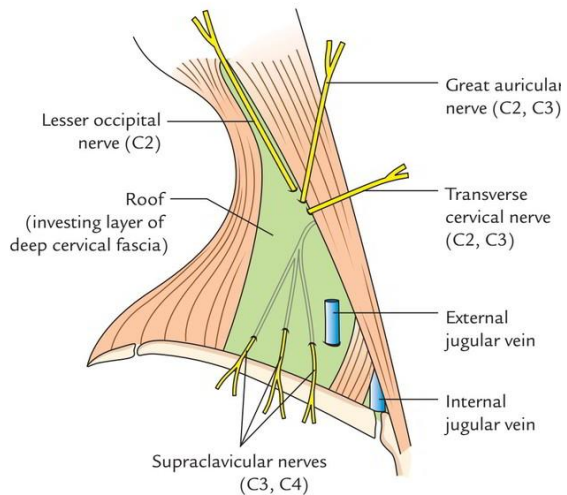


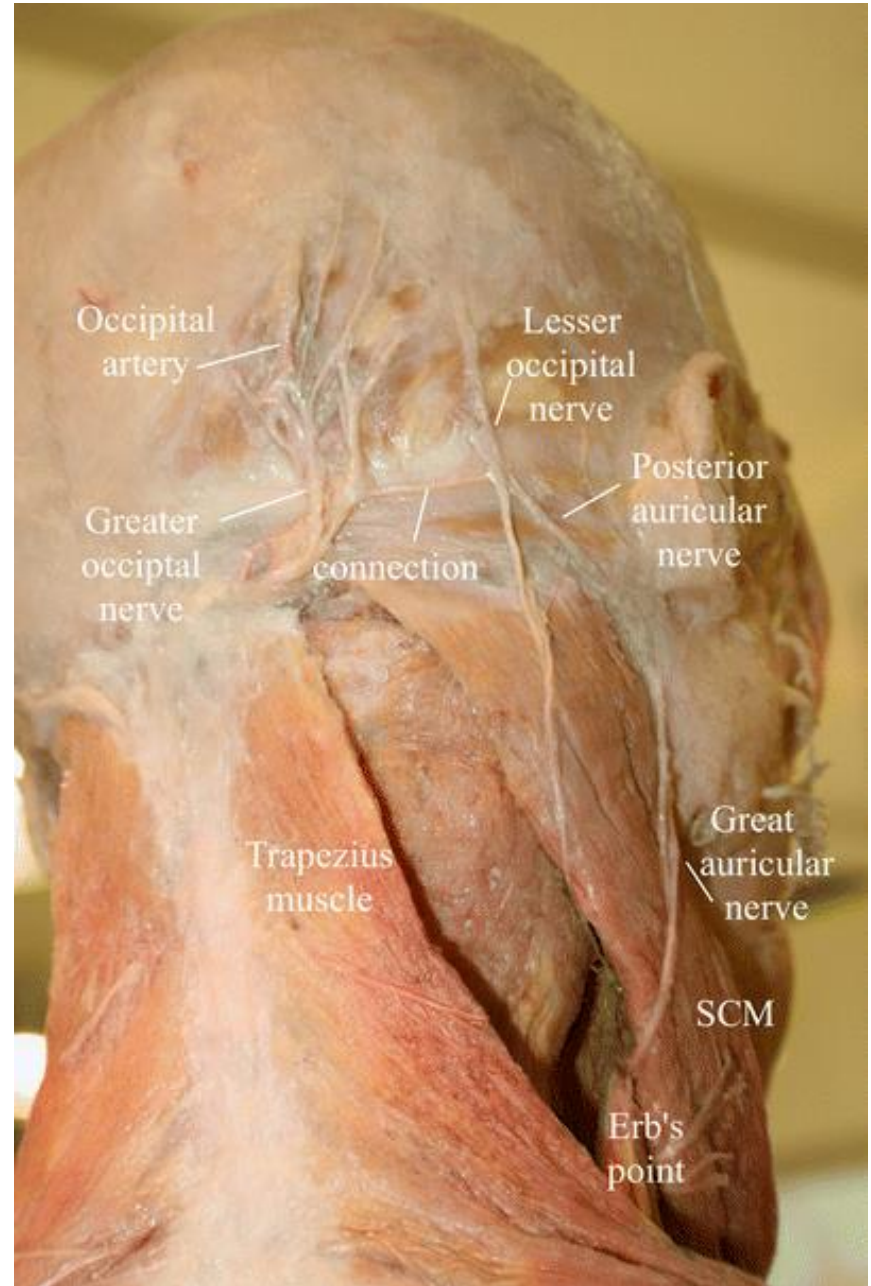
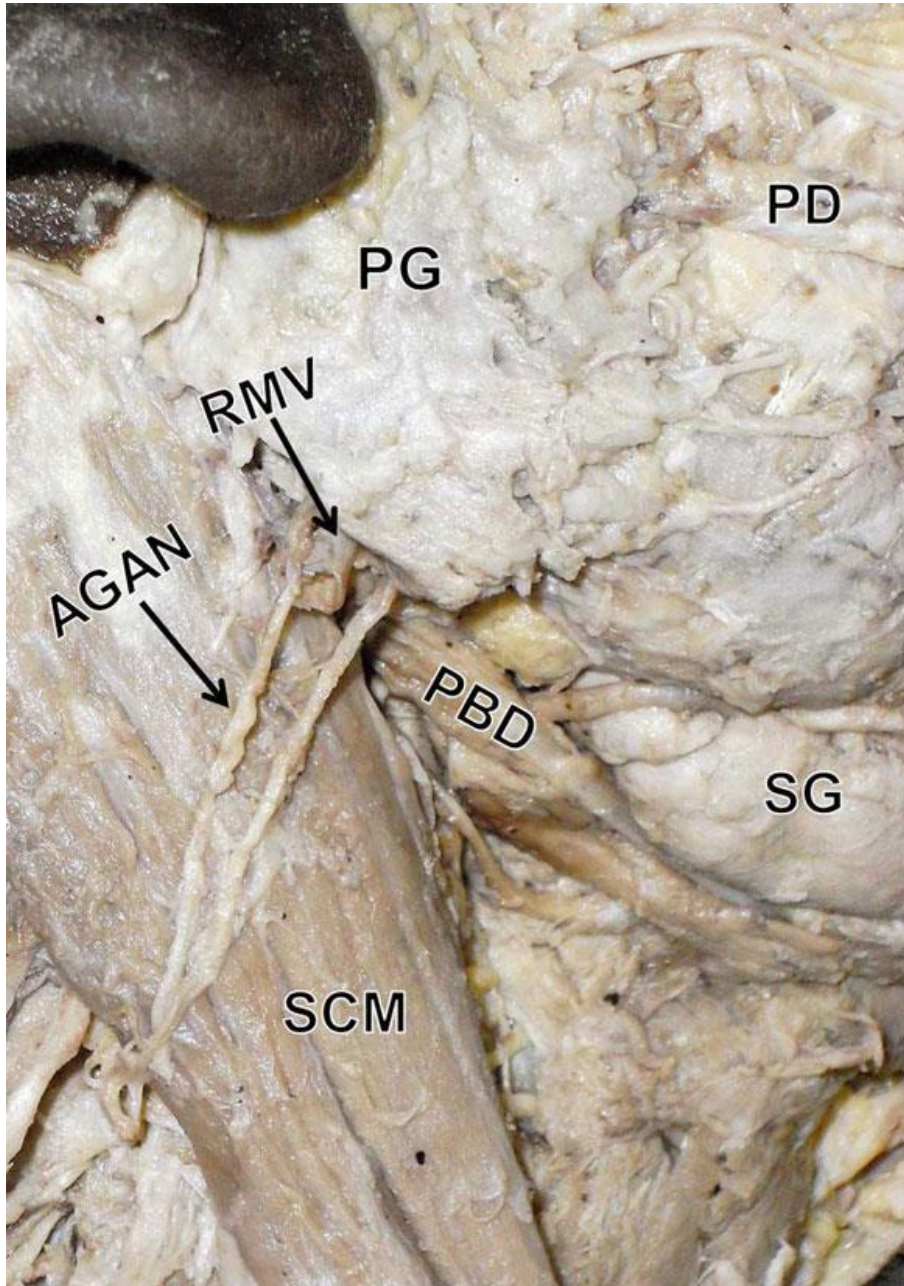
- Occipitofrontalis muscle, frontal belly
Musculus occipitofrontalis, venter frontalis
- Corrugator supercilii muscle
Musculus corrugator supercilii
- Procerus muscle
Musculus procerus
- Levator labii superioris alaeque nasi muscle
Musculus levator labii superioris alaeque nasi
- Nasalis muscle, transverse part
Musculus nasalis, pars transversa
- Levator labii superioris muscle
Musculus levator labii superioris
- Zygomaticus minor muscle
Musculus zygomaticus minor
- Zygomaticus major muscle
Musculus zygomaticus major
- Orbicularis oris muscle
Musculus orbicularis oris
- Levator anguli oris muscle
Musculus levator anguli oris
- Depressor anguli oris muscle
Musculus depressor anguli oris
- Inferior labial branch
Arteria labialis inferior
- Depressor labii inferioris muscle
Musculus depressor labii inferioris





Plexus cervicalis (Cervical plexus)





N. Phrenicus
(Phrenic n.)

