

The Day the Blue Bloater met the Pink Puffer

2013 Virginia EMS Conference

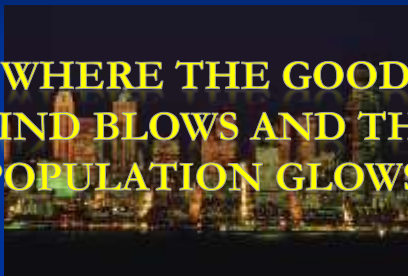
Chronic Obstructive Pulmonary Disease: COPD

A disease of airflow obstruction that is not totally reversible

- Chronic Bronchitis
- Emphysema

Welcome to the City of Carcinoma!

WHERE THE GOOD WIND BLOWS AND THE POPULATION GROWS!



Betty



Where she lives

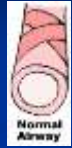

Chronic Bronchitis

Continuous sputum production on most days for three months of at least two consecutive years


Her Unique Qualities

- **Chronic inflammation**
 - Narrowing of the bronchial lumen
- ↑ airflow resistance
- ↑ work of breathing



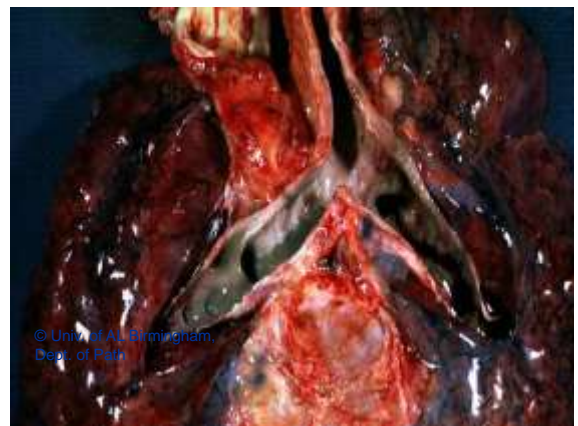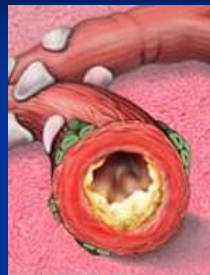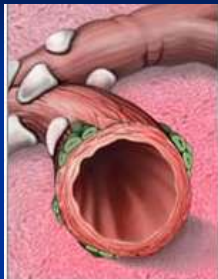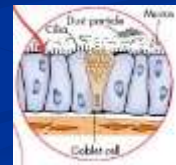Her Unique Qualities

- **Chronic Inflammation**
 - Permanent scarring
 - Cilia destroyed
 - Loss of effective escalator
 - Promotes further infections and inflammation



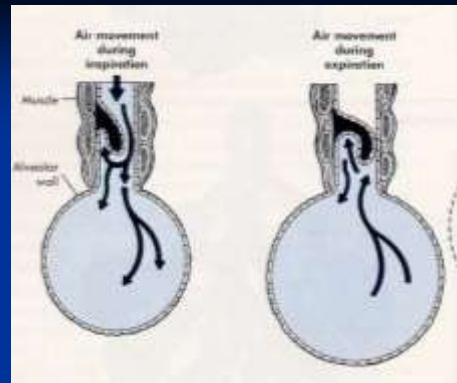
Her Unique Qualities

- **Increased mucus production**
 - Increased size and number of goblet cells
 - Constant thick mucus production
 - Formation of mucus plugs
- Chronic congestion
- Hypoventilation



Her Unique Qualities

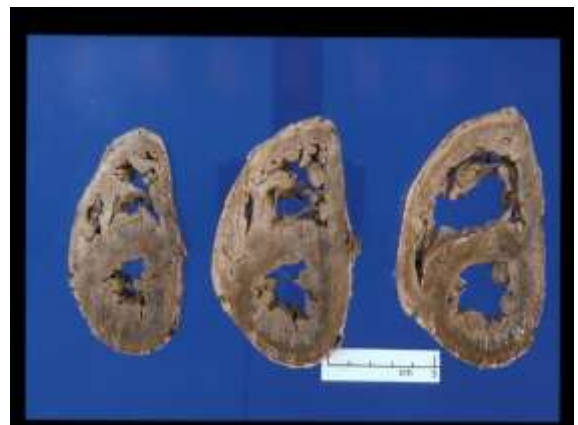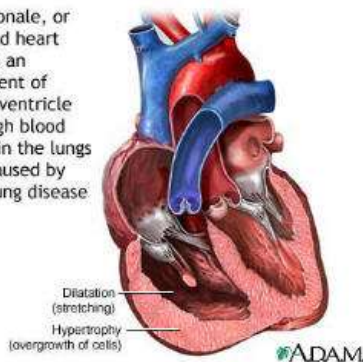
- **Increased mucus production**
 - Airways expand on inspiration/compress on expiration
 - Mucus causes excessive narrowing
- Stale (low O₂ /high CO₂) air becomes trapped in the distal airways and alveoli
 - hypoxia
 - acidosis

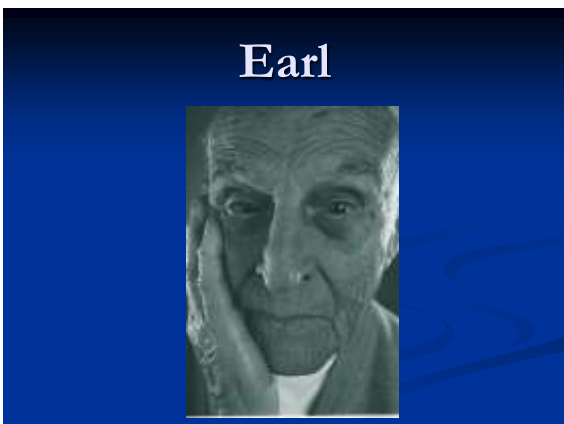
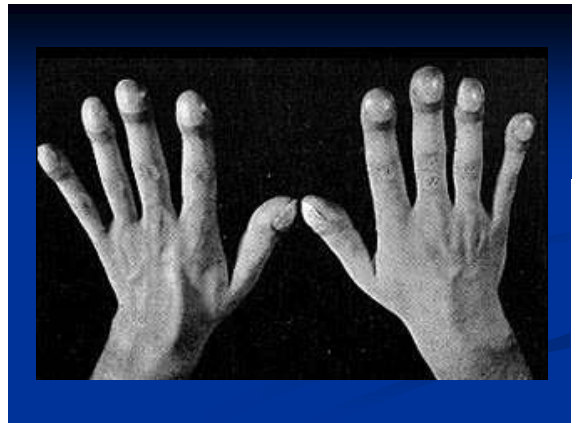
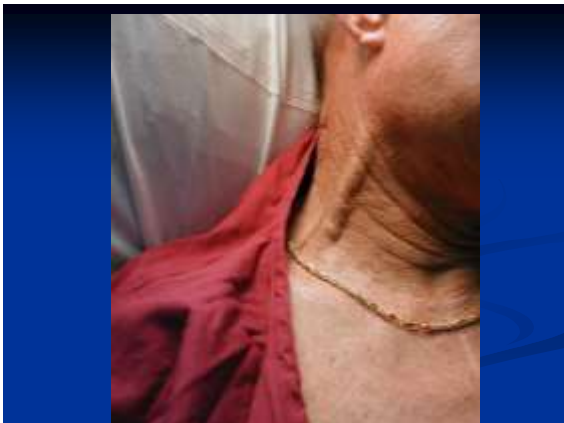
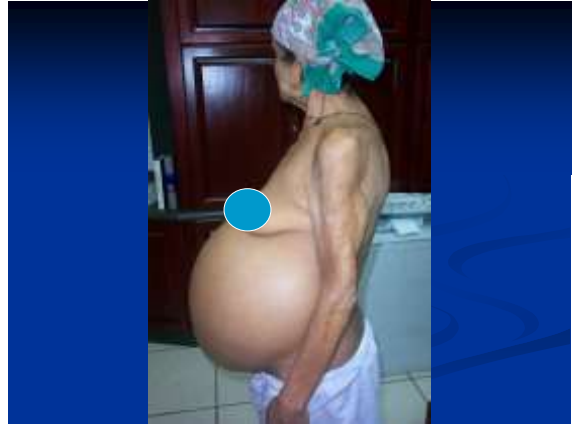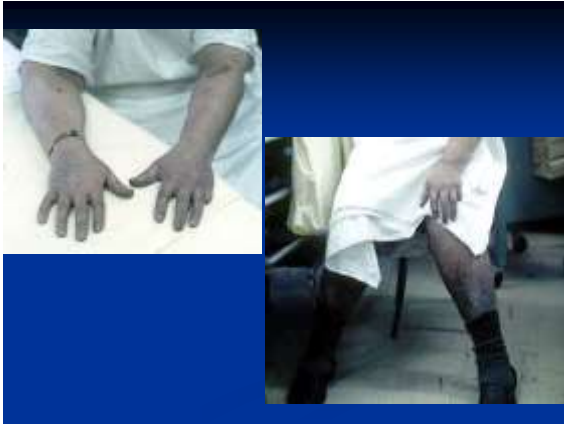The “Blue Bloater”

- Chronic low alveolar oxygen
 - Pulmonary vasoconstriction
- Limited exercise tolerance/D.O.E.
 - Predisposition to obesity
- Increased RBC production
 - Increases blood viscosity
 - Cor Pulmonale

Cor pulmonale, or right-sided heart failure, is an enlargement of the right ventricle due to high blood pressure in the lungs usually caused by chronic lung disease.



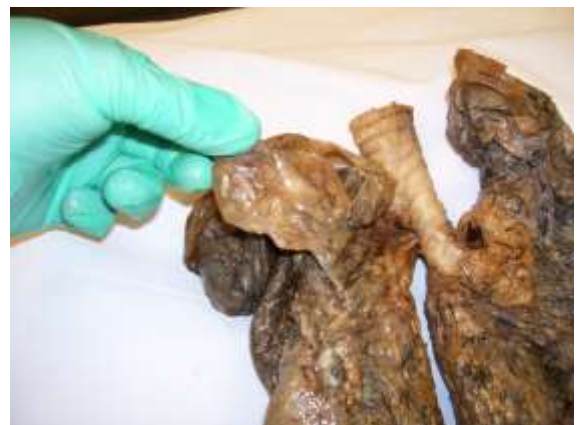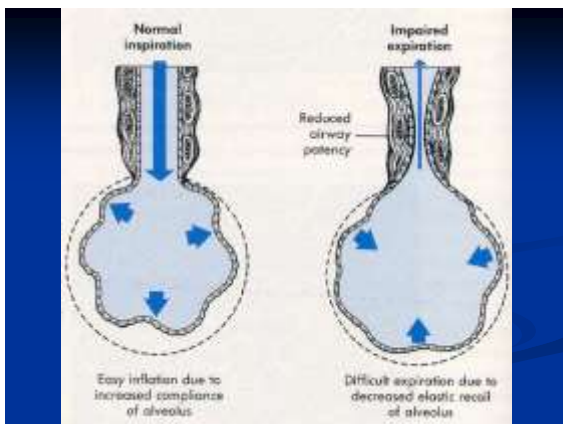


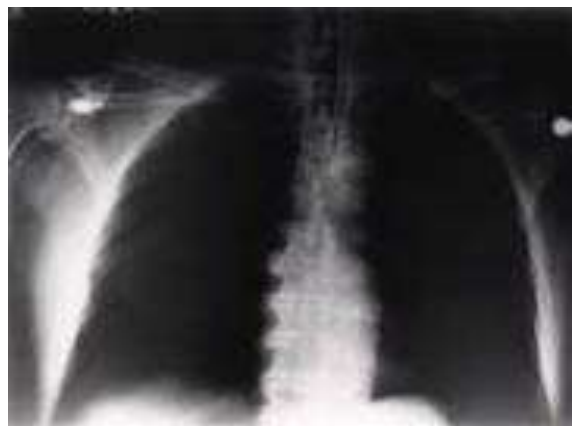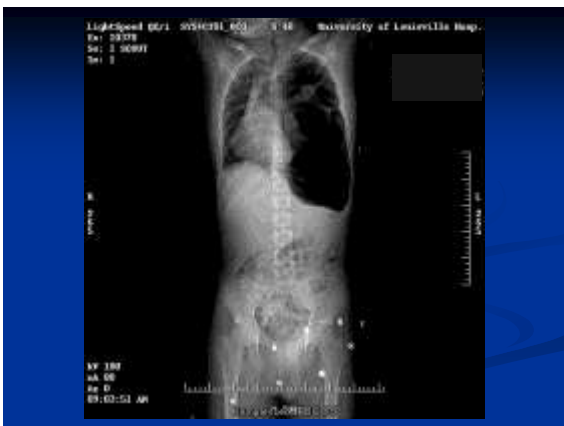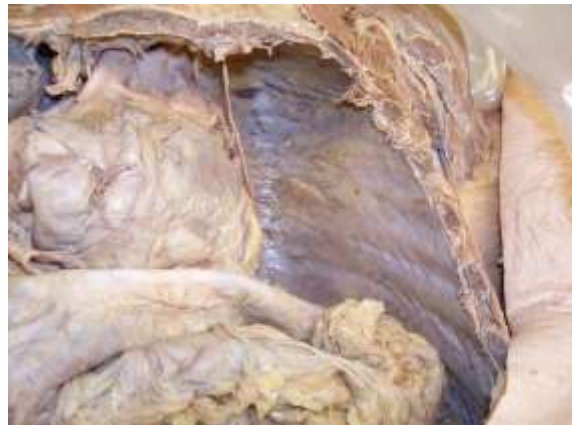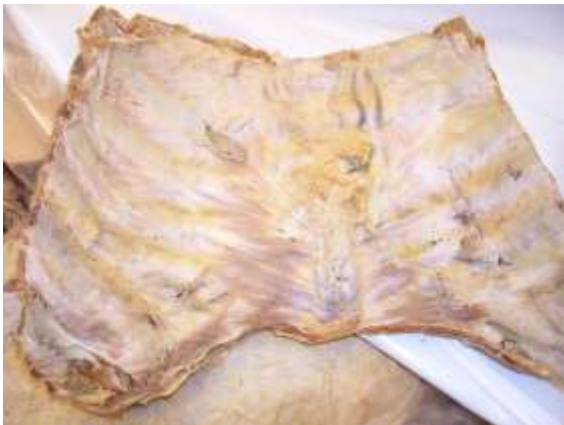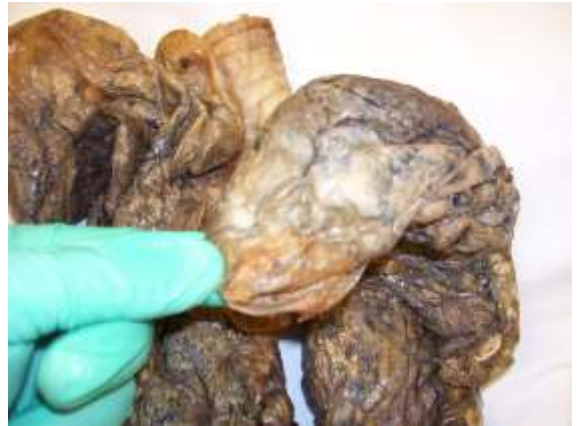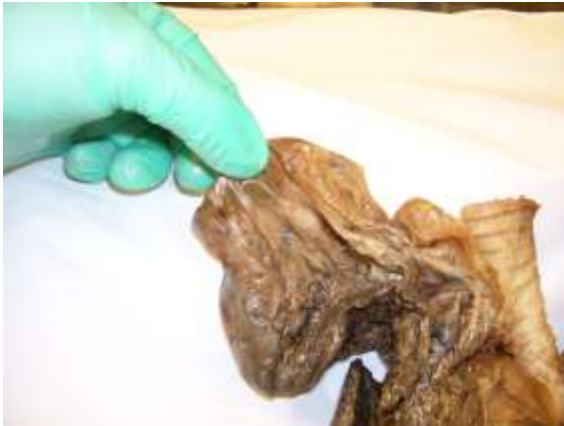Emphysema

A chronic, irreversible disease of the lungs characterized by abnormal enlargement of the alveoli and subsequent destruction of elastic lung tissue

His Unique Qualities

- Loss of bronchiole/alveolar elasticity
 - Cigarette smoke
 - Increases the local concentration of certain WBC's
 - Produce an enzyme called Elastase

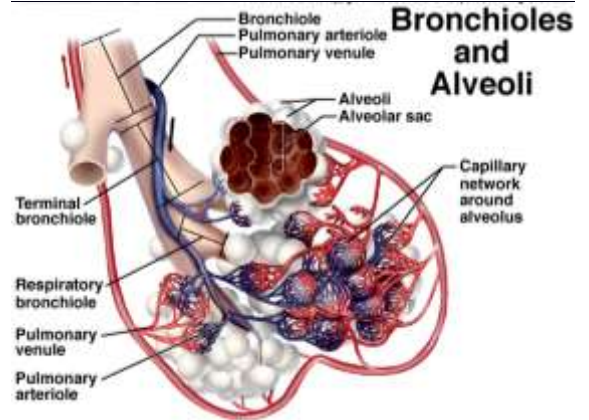




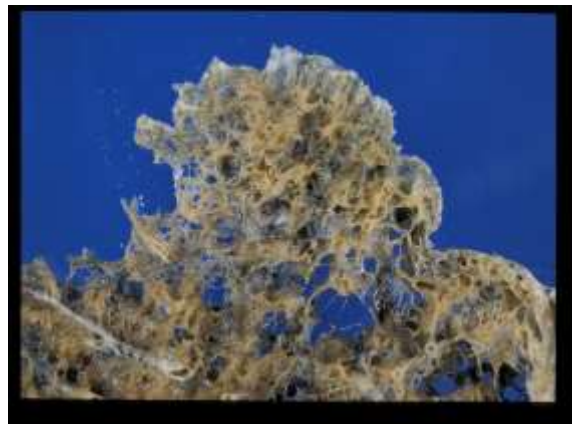
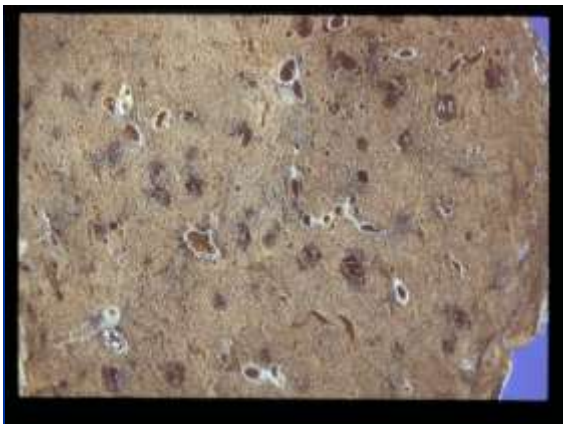
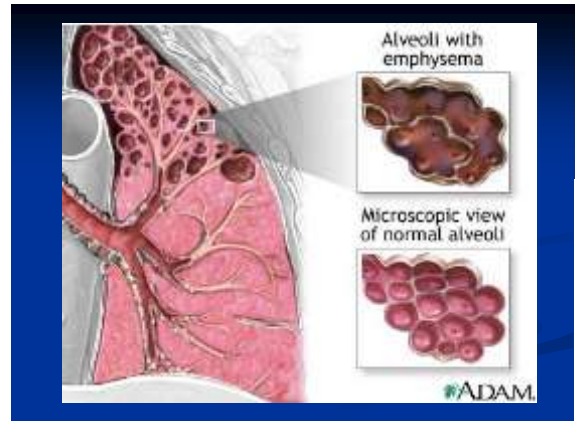
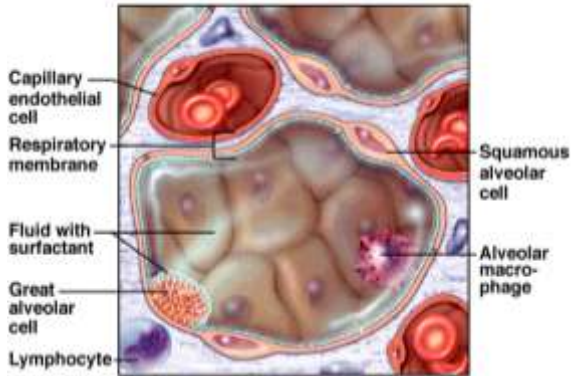
His Unique Qualities

■ Enlargement of alveoli

- Destruction of individual alveolar walls
 - Nicotine
 - Decreases surface area for respiration
- Hyperinflation of lung tissue
 - Flattens the diaphragm
 - Increases W.O.B.
 - Accessory muscle usage

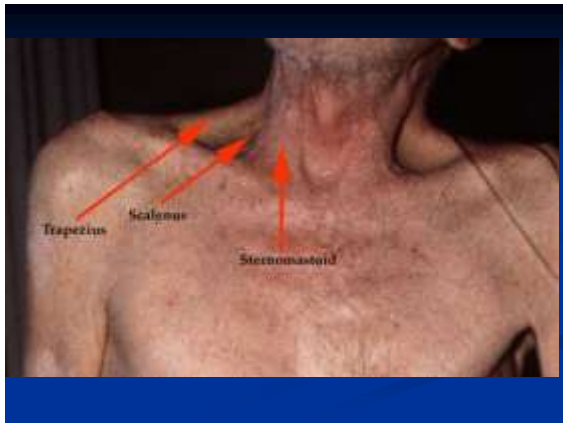
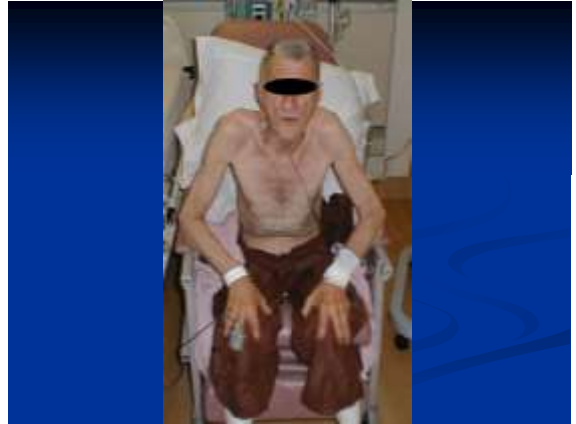
Structure of an Alveolus

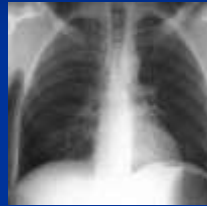

The "Pink Puffer"

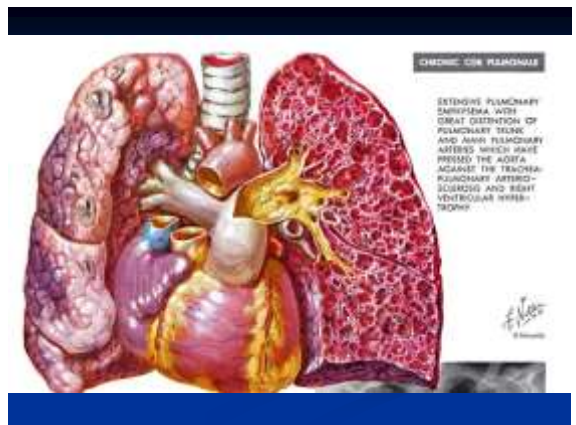
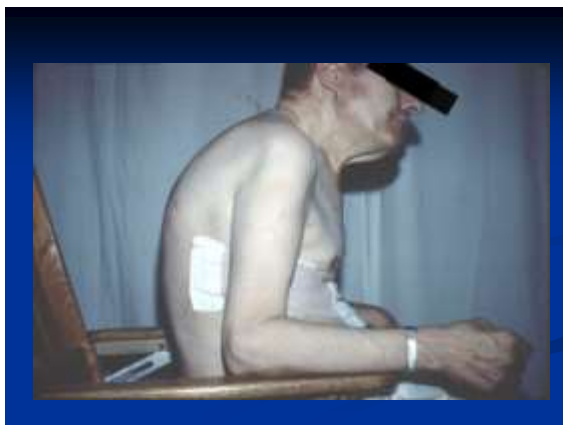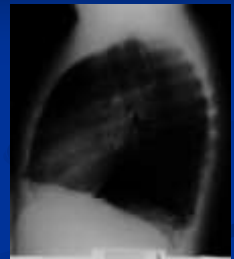
- Increased RBC production
 - Buffers high CO₂ levels
 - Picks up high O₂ concentration
- Expiration
 - Small airways collapse or narrow = air trapping
 - Loss of alveolar recoil
 - Adequate oxygen delivery
 - Inadequate CO₂ elimination



Normal



Emphysema





Let's Contrast

Earl

- Thin, barrel-chest appearance
- Nonproductive cough
- Pink complexion
- Prolonged expiration
 - Pursed-lip breathing
- Destroyed alveoli
- Decreased chest excursion

Betty

- Overweight/ascites
- Productive cough/mucus
- Cyanotic complexion
- Resistance upon inspiration and expiration
- Alveoli intact
- Chest excursion adequate





Let's Compare

- Both Earl and Betty have similar problems
 - Lower airway narrowing
 - Air trapping
 - Pulmonary hypertension
 - Possible cor pulmonale
- **HYPOXIC DRIVE**

Chronic Bronchitis/Emphysema

Management Goals

Relieve hypoxia

Reverse bronchoconstriction

Chronic Bronchitis/Emphysema Management

- Airway
 - Assure patency
 - Fowler's position
 - Encourage coughing
- Breathing
 - Assure adequate oxygenation and ventilation
 - NRB, BVM, CPAP, ET
 - Maintain pulse ox > 90%

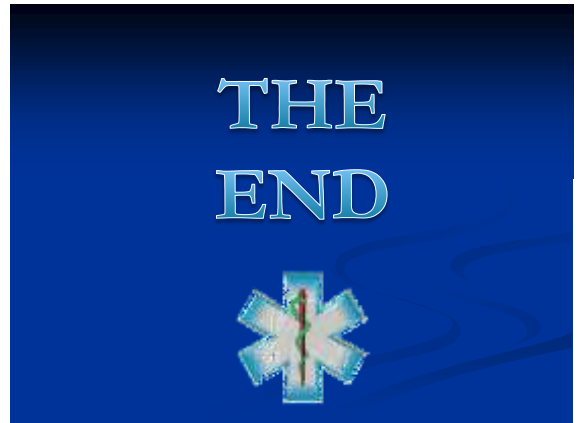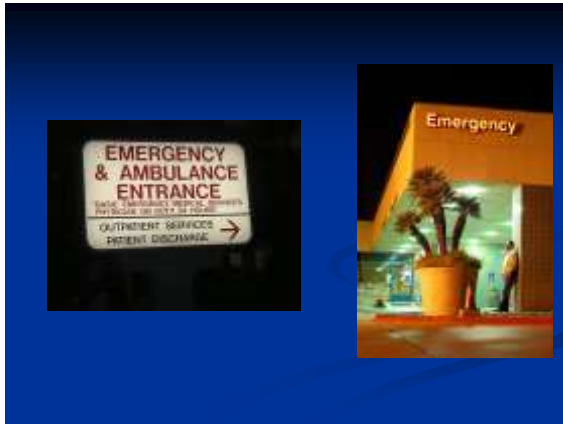Chronic Bronchitis/Emphysema Management

- Circulation
 - Vitals
 - I.V. access
 - Fluids for rehydration
 - Mucus thinning
 - Medication administration
 - ECG monitoring
 - Atrial fibrillation

Chronic Bronchitis/Emphysema Management

- Pharmacology
 - Bronchodilators
 - Albuterol, Proventil, Ventolin
 - Steroids
 - Solu-Medrol
 - sq Beta 2 agonists





QUESTIONS ???

Christopher Ebright

B.Ed., NREMT-P

EMS Education Coordinator
National EMS Academy
Covington, LA

cde61969@yahoo.com

References

- http://www.sanitarium.net/stuff/pics/city_night.jpg
- <http://www-cellbio.med.unc.edu/grad/cilia.jpg>
- http://www.lungusa.org/atf/cf/%7B7A8D42C2-FCCA-4604-8ADE-7E5D5E762256%7D/dirty_lung1_hr.jpg
- <http://www.murrasaca.com/ascitis1.jpg>
- http://www.tvacres.com/images/dancing_cigarettes.jpg
- http://img.alibaba.com/photo/10871452/Pure_Lights_Cigarettes.jpg

References

- http://www.jhsph.edu/bin/v/b/26old_man.jpg
- http://colourblind.ca/images/20051107184847_train%20tracks%20wide.jpg
- http://farm1.static.flickr.com/61/159766573_d4d39bfd6.jpg?v=0
- <http://www.grandprojectsinc.com/grocery%20store.png>
- <http://www.rascalscooters.com/images/Oxygen%20Tank%20Holder%20-Accessories-1.jpg>
- <http://www.browardmedicalsupply.com/catalog/images/E%20Tank%20Setup.JPG>

References

- <http://www.mhsk.org/assets/clientPhotos/EMS-ambulance%20on%20road.jpg>
- <http://cheerleadingsecrets.net/cheerleader.jpg>
- http://www.livingstonsportsphotos.com/images/football_image.jpg
- <http://www.harvard.hr/harvard.jpg>
- <http://portal.techhigh.us/SiteCollectionImages/New%20School%20Front.JPG>
- <http://www.flickr.com/photos/sgroi/254668516/>