

CT FINDINGS OF ACTINOBACILLOSIS IN A COW

Blanco B¹, Méndez A², Diz A², Méndez-Angulo JL¹, Morales A², Novales M¹

1. Hospital Clínico Veterinario. Universidad de Córdoba (Spain)

2. Departamento de Anatomía y A. Patológica Comparadas. Universidad de Córdoba (Spain)

E-mail address: pv1nodum@uco.es (M. Novales)

INTRODUCTION

Actinobacillosis is an infectious disease produced by *Actinobacillus lignerlesi*. In the literature, it is described to affect only soft tissues, producing piogranulomatous infections easy to misinterpret as actinomycosis, abscesses caused by piogenic bacteria or neoplasia.¹⁻³

MATERIALS AND METHODS

A cow head rejected from the slaughter house for lesions, with histopathological and microbiological diagnostic of actinobacillosis (Fig. 1-3), was digitally radiographed in laterolateral and dorsoventral views. Afterwards a CT study was performed with a dual scan. Helical slices of 1 mm width and a pitch of 0.75 were made from the incisive bone to the occipital condyles. Later an anatomical preparation of the head was made.

RESULTS

Lateral radiographs revealed an increased opacity with heterogeneous appearance from the caudal portion of the nasal cavity up to the frontal sinus. The dorsoventral view showed large areas of bone proliferation on the right side of the head, extending from the first premolar to the level of the temporomandibular joint (Fig. 4). The CT study revealed marked bony proliferation, large areas of lysis, and loss of bone cortex in the right incisive, maxillary, palatine, lacrimal, zygomatic, temporal, basisphenoid and ethmoid bones (Fig. 5). Additionally, the maxillary, palatine and sphenoid sinuses were deformed and contained a dense soft tissue mass. The large expansile lesion of poliostotic nature had caused displacement of the right maxilar premolars and molars and lysis of several of their roots.

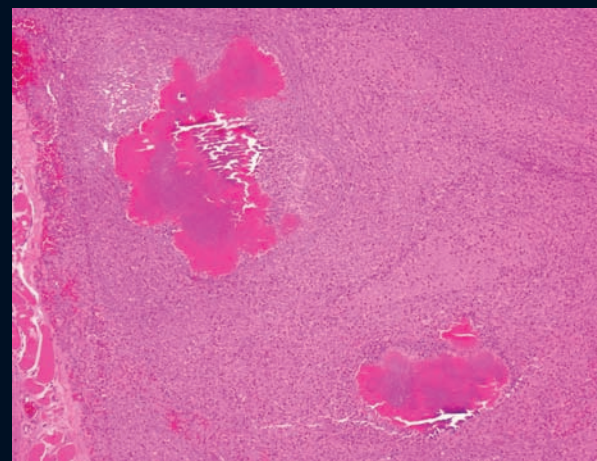
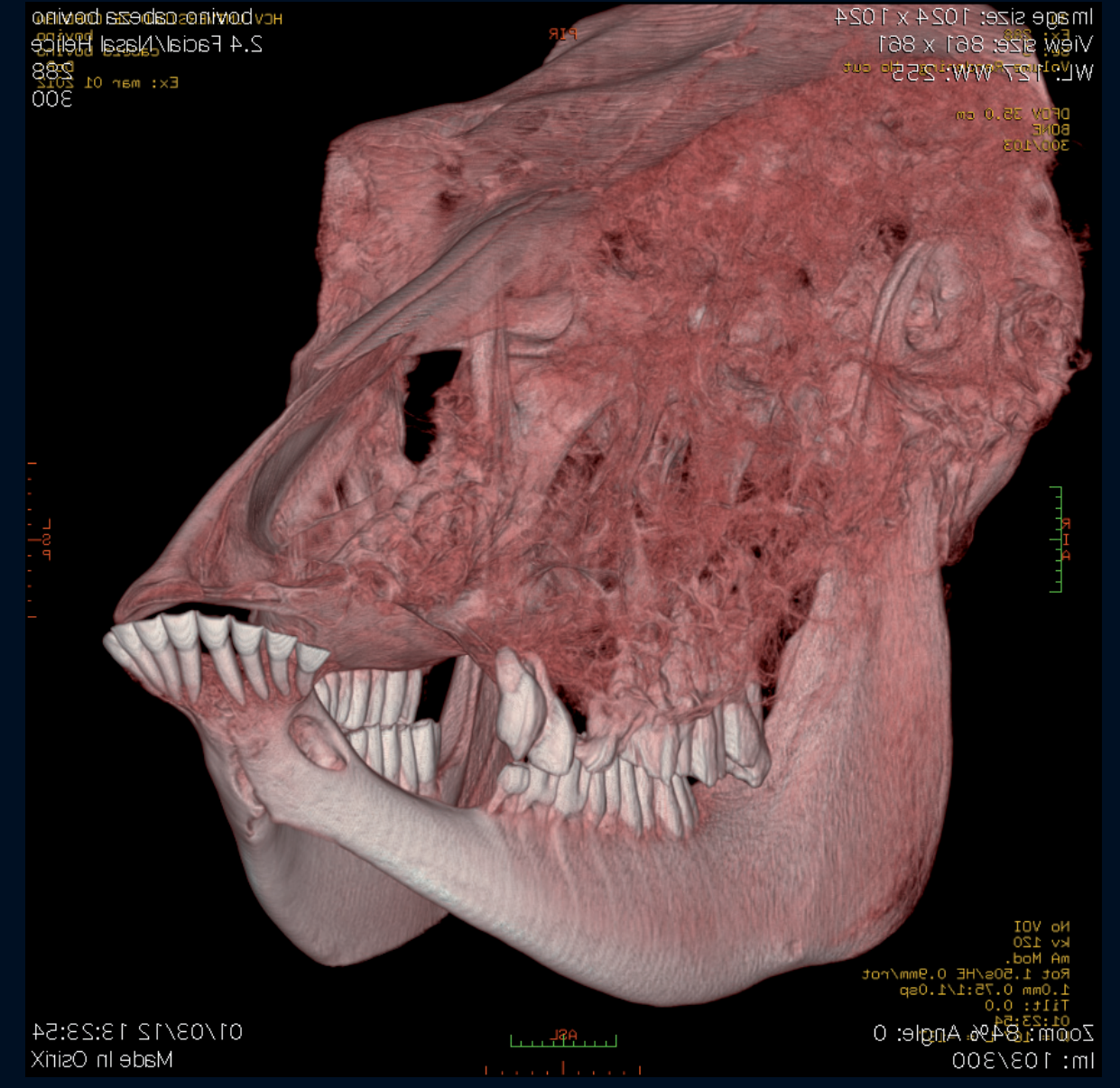


Fig. 1. Pyogranulomatous inflammation with presence of *Actinobacillus* spp. H-E 20x.

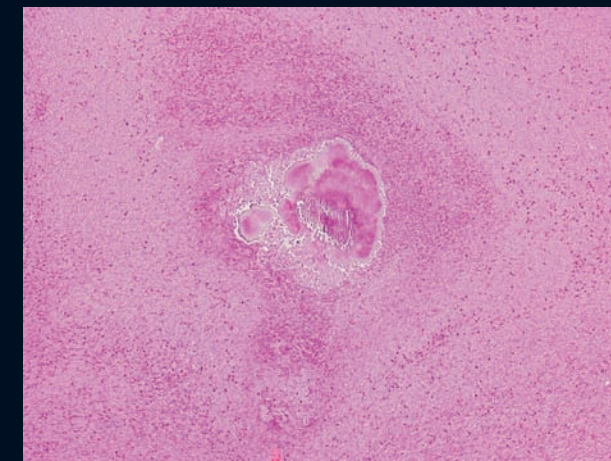


Fig. 2. Pyogranulomatous inflammation with presence of Gram negative microorganisms corresponding with *Actinobacillus* spp. Gram 20x.

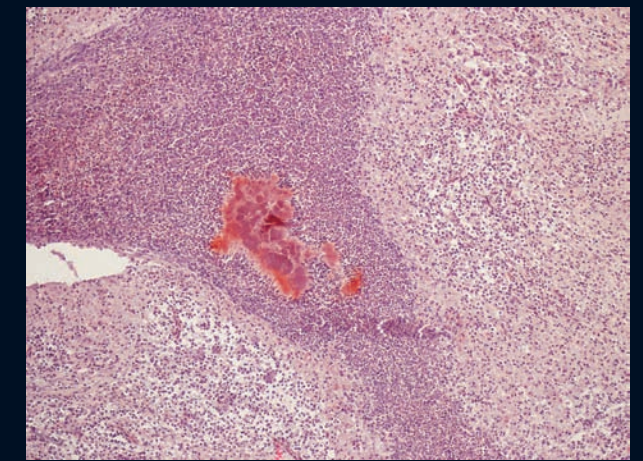


Fig. 3. Pyogranulomatous inflammation with positive Congo Red structures consistent with *Actinobacillus* spp. CR 20x.

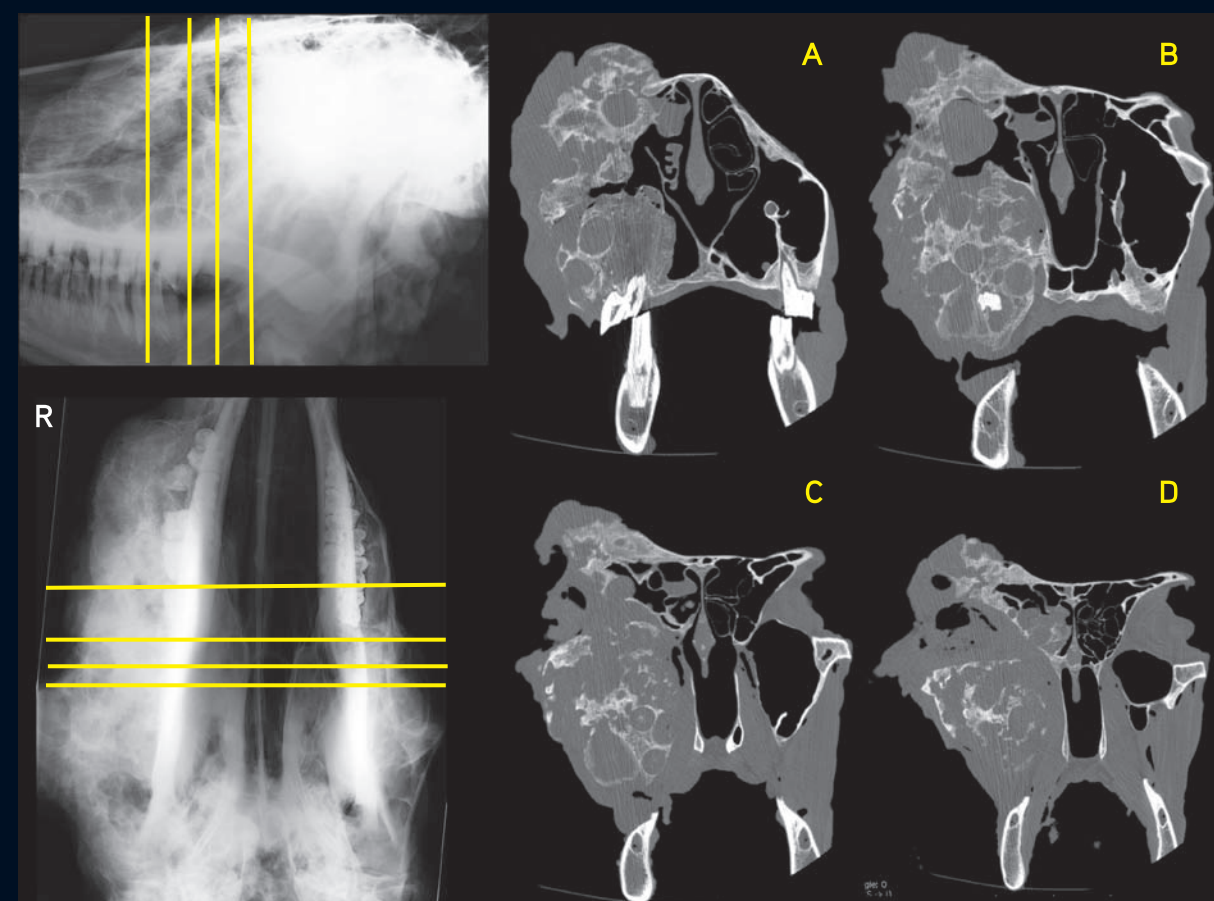


Fig. 4. Laterolateral and dorsoventral radiographs and transverse CT views taken at different levels of section showing the large expansile lesion of poliostotic nature. The yellow lines indicate the level of section.

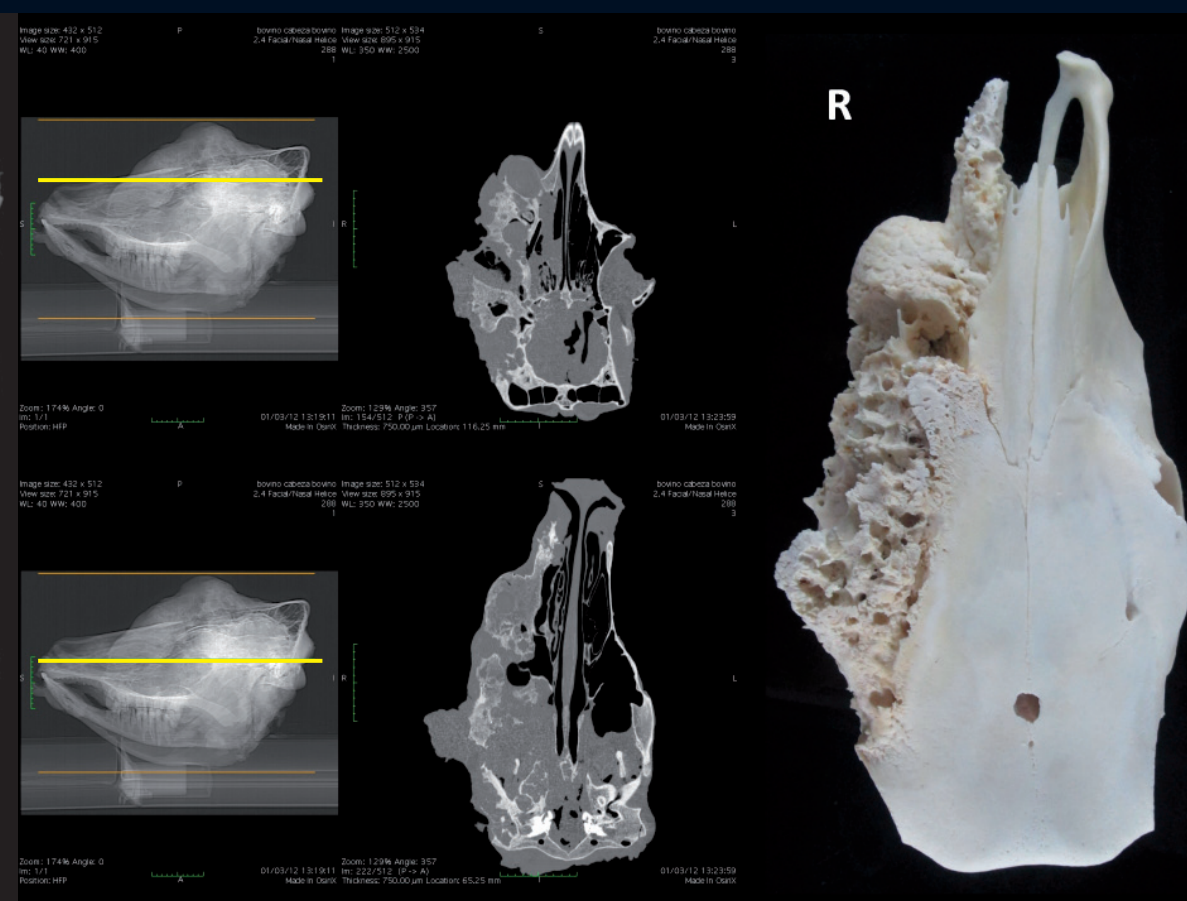


Fig. 5. Dorsal CT reconstruction taken at the level of the supraorbital rim (upper left images) and midpoint of zygomatic arch (lower left images) comparing with the head skeleton specimen (right image).

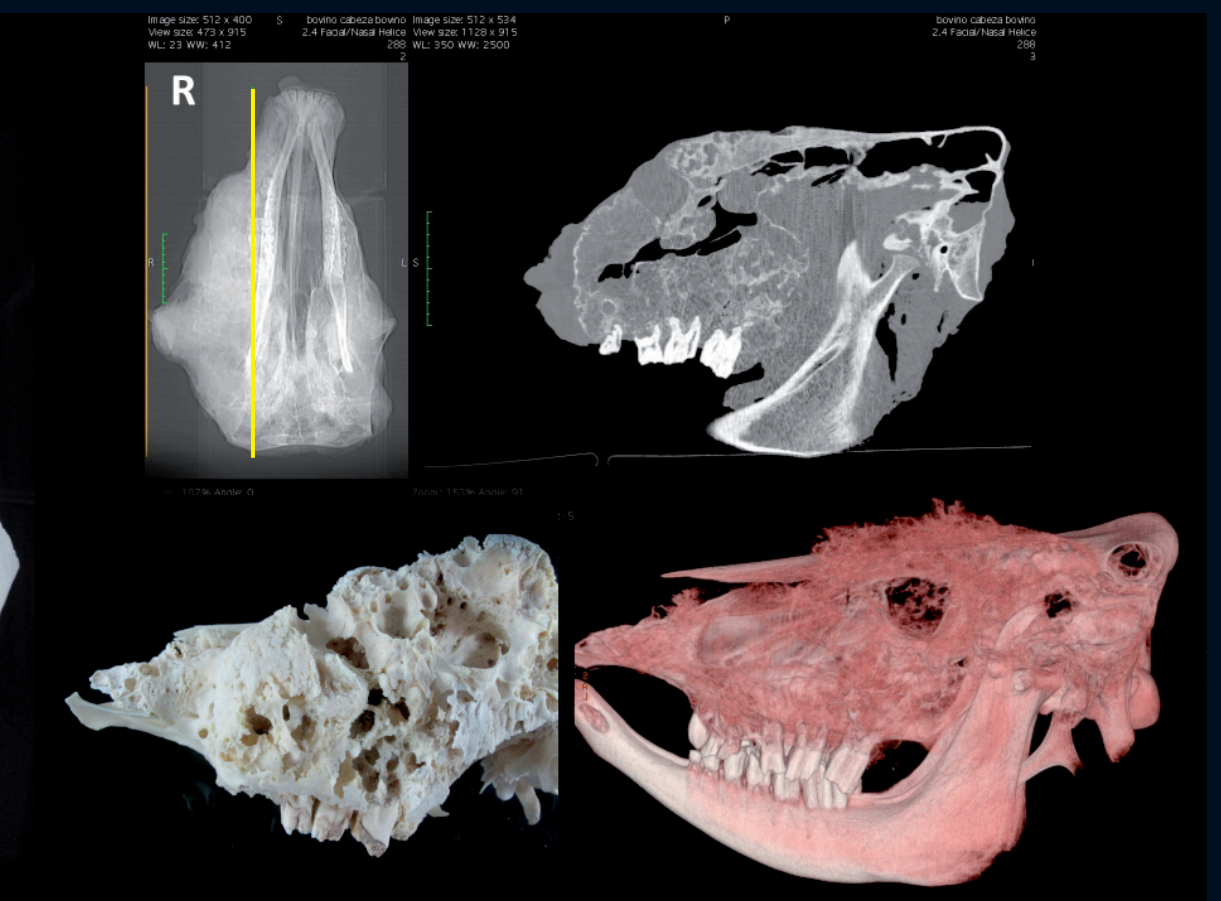


Fig. 6. Parasagittal CT reconstruction taken at the level of the right ramus of the mandible (upper images); the lower images include the anatomy specimen (left) and a VR view of the head (right).

DISCUSSION

Bovine actinobacillosis is typically characterized by piogranulomatous lesions in the soft tissues.¹ In this report, we describe a case of actinobacillosis with severe bone involvement of the right side of the head, providing a comparative anatomical, radiological and CT study (Fig. 4-6). There are very few imaging studies of actinobacillosis in the literature³ and, to our knowledge, there are no reports of CT studies of this disease. The information provided by radiography in our case was limited, due to extensive proliferation of lesions, and couldn't establish the extension and anatomical structures affected. Both the anatomopathological examination and the lesions detected on CT clearly showed the severe bone destruction that hasn't been formerly described in this pathology.

We conclude that bovine actinobacillosis may affect both soft tissues and bones of the head. Even in a very aggressive and chronic phase of the disease, it can still preserve its unilateral character. In highly proliferative lesions, CT allows their accurate delimitation.

REFERENCES

- 1.- Thompson K. Bone and joints. In Jubb KVF, Kennedy PC and Palmers N, eds. Pathology of Domestic Animal. 2007 . London (Elsevier Saunder): 1-158.
- 2.- Angelo P. et al. An atypical case of respiratory actinobacillosis in a cow J. Vet. Sci. 2009; 10 (3): 265-267.
- 3.- Wesseks M. et al. Rhinitis due to actinobacillosis in a UK suckler cow heard. Vet. Rec. 2012; 170; 599.

