

# Knuckle Pads

J. T. HUESTON AND W. F. WILSON  
Melbourne

*The condition of "knuckle pads" is discussed. These are due to no single cause, and the differential diagnosis, which has not previously been considered, is recorded in this paper.*

THE term "knuckle pad" is used to describe a visible and palpable thickening in the integument over the dorsum of any digital joint, but most frequently the proximal interphalangeal joint.

Confusion exists in the medical literature as to whether knuckle pads constitute a clinical sign or a disease entity. This confusion is most evident in dermatological literature, where knuckle pads are regarded as a disease, and inimitably dermatologists have even coined the polysyllabic Latin synonyms "heloderma" and "tylositas articuli" for this entity (Solomons, 1959). Dermatology texts also variously describe the pathology of the knuckle pad as a fibroma, a benign tumour of the corium (McKenna and Cohen, 1964), fibrochondroma (Percival and Dodds, 1955) and as a congenital hypoplasia (Leider, 1961).

We regard a knuckle pad merely as a clinical sign which reflects the end result of several different but literally underlying pathological processes. In 1893 Garrod pointed out that knuckle pads might be associated with Dupuytren's contracture, but in hand surgery practice we have found a number of other causes which have required differentiation. Although the following groups do not include all the possible conditions causing lumps over the knuckles,<sup>1</sup> a classification is offered of those conditions occurring commonly enough to require recognition.

<sup>1</sup>The derivation of this word is uncertain. It appears in Middle English as *knokil*, derived from a Teutonic base *knuk-*, regarded as perhaps allied to *knock*. Elsewhere it is suggested that it may ultimately be related to *knee*.

Address for reprints: 89 Royal Parade, Parkville, Victoria 3052.

## DUPUYTREN'S CONTRACTURE

By far the commonest aetiological factor producing knuckle pads is Dupuytren's contracture (Hueston, 1961). The subdermis and extensor tendon paratenon over the proximal interphalangeal joints is the commonest ectopic site of Dupuytren's tissue, and the knuckle pads, which such deposits produce, are seen frequently either associated with or preceding a palmar Dupuytren's contracture. Knuckle pads were found to be present in 20% of patients requiring surgery for Dupuytren's contracture. There is no uniform pattern of involvement of the fingers, and it is not unusual to find on the same hand some fingers with knuckle pads and some without. However, all eight fingers, and occasionally even the interphalangeal joint of the thumb, may be involved. Other ectopic sites of Dupuytren's tissue, such as the plantar fascia, are frequently associated with knuckle pads, and this is interpreted as reflecting the severity of a patient's inherited predisposition to the production of this multifocal hyperplastic fibrous tissue, now generally referred to as the Dupuytren's diathesis (Hueston, 1963).

McIndoe's aphorism epitomizes the relevance of knuckle pads to Dupuytren's contracture: "The clinician who observes a patient to have knuckle pads may be quite sure that the patient either has a Dupuytren's contracture or that one will develop in the future."

The management of the ectopic lesions in Dupuytren's contracture has recently been described (Hueston, 1972).

## OCCUPATIONAL KNUCKLE PADS

The most prominent parts of the clenched fist are the two rows of knuckles which repre-

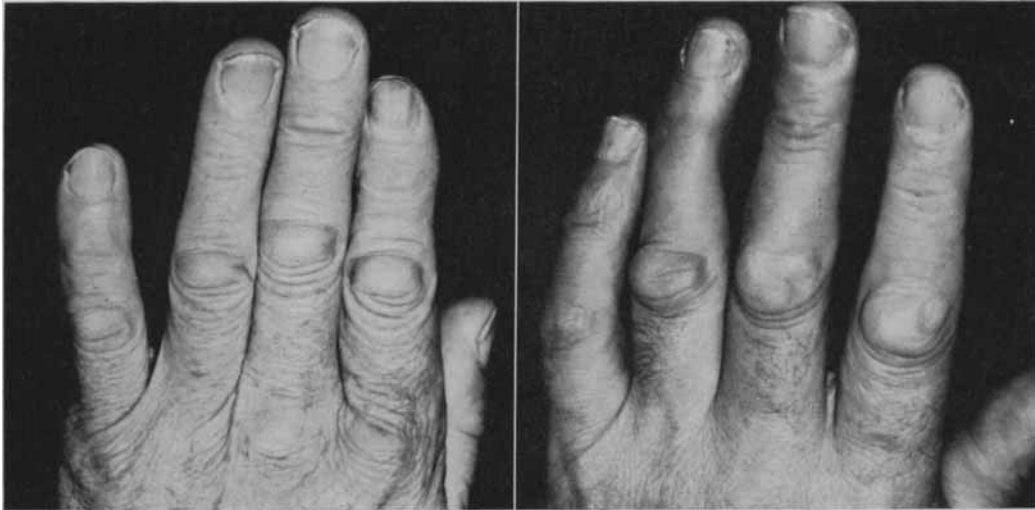


FIGURE 1: Shearer's left hand showing uniformly distributed knuckle pads (left), which closely resemble similarly distributed Dupuytren's knuckle pads (right).

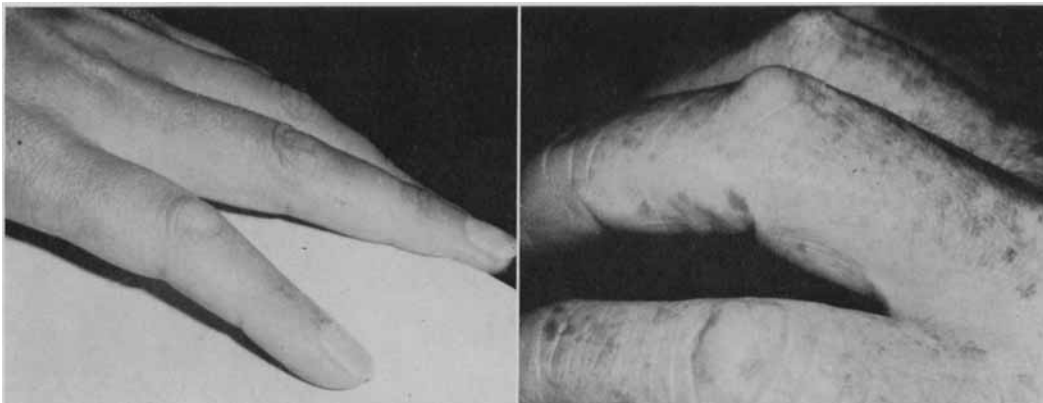


FIGURE 2: Reactive hyperplasia in the extensor tendon paratenon on the left index finger (left) appears as a lump which moves with the tendon, and thus can be distinguished from a similar-looking but immobile Dupuytren's knuckle pad (right).

sent the integument and extensor tendons attenuated over the heads of the metacarpals and the proximal phalanges. Thus it is not surprising that these exposed areas receive innumerable traumatic insults, many of which eventually may result in the formation of knuckle pads.

In a number of occupations frictional trauma to the skin over the knuckles results in the formation of knuckle pads which have the

histological appearances of callosities. Sheep shearers develop knuckle pads on the left hand over all the proximal interphalangeal joints as a result of two positions assumed by the left or non-dominant hand during shearing (Figure 1) (Wilson, 1972). Carpet layers subject the proximal interphalangeal joints of the right hand to frictional trauma in kneading the carpet on to holding tacks. Tailors develop pads over the proximal interphalangeal joints

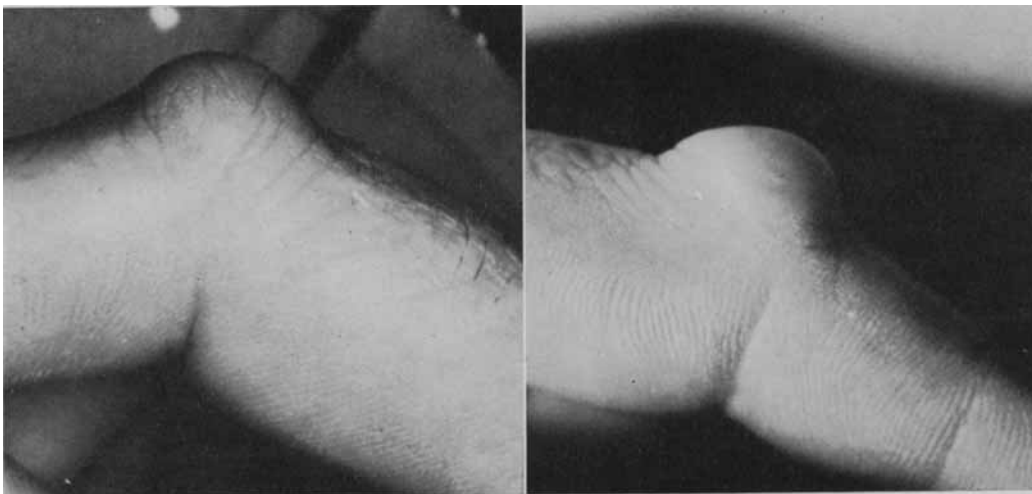


FIGURE 3: An inclusion cyst (left) in this area which is frequently subjected to trauma can resemble an isolated Dupuytren's knuckle pad (right).

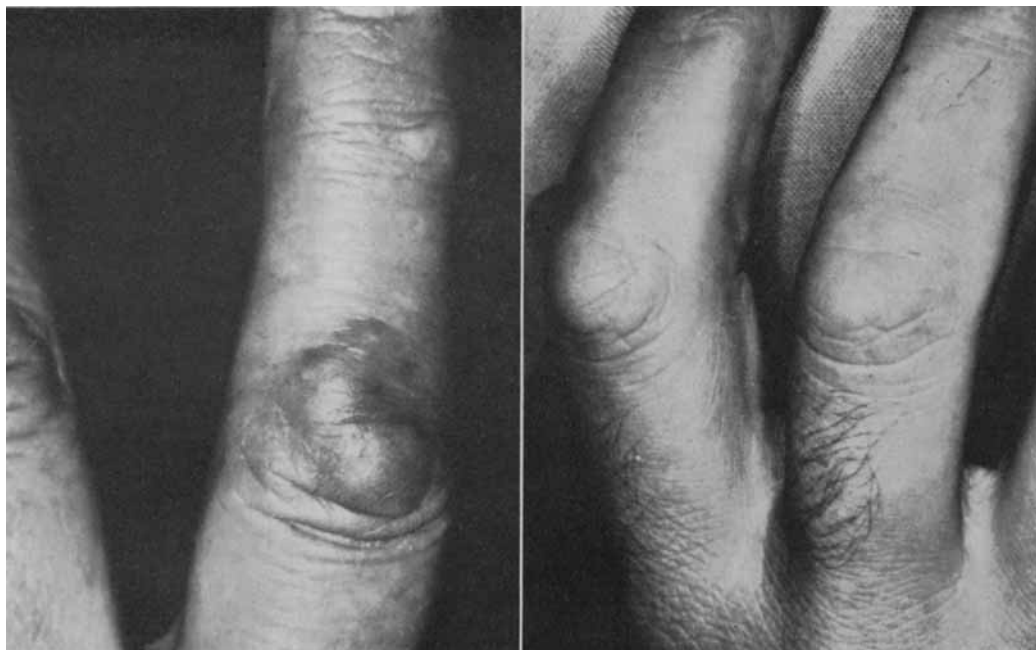

FIGURE 4: Granuloma annulare involving the skin over the interphalangeal joints (left) can superficially mimic an isolated Dupuytren's knuckle pad (right).

of the right hand for a similar reason. Occupational knuckle pads have also been recorded in plasterers and egg packers (Leffkowitz, 1964). All the occupational knuckle pads can be distinguished from Dupuytren's knuckle pads because they occur on one hand at a specific site as a result of a particular manoeuvre performed in the patient's work; they are dermal callosities and slowly subside over a few years when the occupation is discontinued.

#### REACTIVE HYPERPLASIA OF THE PARATENON

Lacerations of the knuckles are common, and frequently partially divide the vulnerable extensor tendons stretched over the underlying flexed digital joints. Whether they are repaired or not, a condition frequently occurs which is best described histologically as "reactive hyperplasia of the extensor tendon paratenon". This is essentially hypertrophic scar tissue which produces a visible and palpable lump in the injured extensor tendon covering the dorsum of the involved joint (Figure 2). This nodule is distinguished because it moves with the extensor tendon. Such hyperplastic scar tissue reflects the proliferative potential of the extensor paratenon, which in turn may be important in the pathogenesis of the similar but less mobile fibroblastic Dupuytren's nodules in this area.

Similarly, it is not surprising that true epithelial inclusion cysts are found over the knuckles (Figure 3) when one considers the vulnerability of these structures to trauma.

#### DERMATOLOGICAL CAUSES

Of course, any lumpy inflammatory skin conditions occurring coincidentally in the skin of the knuckles may simulate a knuckle pad. However, one common condition which has particularly caused confusion and warrants attention is granuloma annulare (Figure 4). This ringed eruption tends to occur over the extensor surface of any ginglymus joint, but

it is particularly common over the proximal interphalangeal joints. It is a chronic condition of unknown aetiology, in which aggregations of papules arise and enlarge to form a circinate pattern on the skin. Histologically the epidermis is normal, but the dermis is characterized by a lymphocytic and fibroblastic infiltration around areas of degenerating collagen with mucin between the collagen bundles.

#### SUMMARY

Knuckle pads are a frequent finding in patients with Dupuytren's contracture, particularly young patients with a strong Dupuytren's diathesis. Lesions in the same distribution over the dorsum of the proximal interphalangeal joints in particular have been observed in many other patients than those with Dupuytren's contracture, and these patients have been grouped here into those due to occupational frictional trauma, post-traumatic reaction of the extensor tendon paratenon or inclusion epithelial cysts, and those with coincidental dermatological lesions predisposed to occur on such traumatically exposed areas.

#### REFERENCES

- GARROD, A. E. (1893), *St Bart. Hosp. Rep.*, 29: 157.  
 HUESTON, J. T. (1961), *Plast. reconstr. surg.*, 27: 569.  
*Idem* (1963), "Dupuytren's Contracture", E. & S. Livingstone, Edinburgh & London: 54.  
*Idem* (1972), "Maladie de Dupuytren", *Expansion Scientifique Française*, Paris: 175.  
 LEIDER, M. (1961), "Practical Paediatric Dermatology", C. V. Mosby, St Louis.  
 LEFFKOWITZ, M. (1964), *Lancet*, 1: 172.  
 MCINDOE, A. H. and BEARE, R. L. B. (1958), *Amer. J. Surg.*, 95: 197.  
 MCKENNA, R. M. B. and COHEN, E. L. (1964), "Dermatology", Baillière, Tindall and Cox, London.  
 PERCIVAL, G. H., and DODDS, T. C. (1955), "An Atlas of Regional Dermatology", E. & S. Livingstone, Edinburgh.  
 SOLOMONS, B. (1959), "A Synopsis of Skin Diseases", John Wright and Sons, Bristol.  
 WILSON, W. F. (1972), *AUST. N.Z. J. SURG.*, 42: 192.