

APPROACH TO THE ENT PATIENT

HEAD & NECK EXAM

By: Christine B. Taylor, MD

LEARNING OBJECTIVES

After reviewing this module, the student will have the ability to:

- Develop a systematic approach to interviewing and examining the ENT patient
- Gain understanding of all components of the comprehensive head and neck physical exam
- Learn about what special tools are used in Otolaryngology to examine the patient

HISTORY

Chief complaint: Ear? Nose? Throat? Neck?

HPI:

- Onset, frequency, duration
- Associated symptoms
- What has the patient already tried?
- Pertinent positives & negatives
 - Always think: “Could this be related to underlying malignancy or something more serious?”
- Previous work-up, testing, imaging, or interventions
 - What has already been done or tried for this?

HISTORY

Past Medical History: Allergies? Asthma?
Neurologic or rheumatologic disorders?

Past Surgical History: Head and neck
procedures?

Allergies- Aspirin Sensitivity?

Meds- Is this problem medication-related?

Social History - Smoker? Alcohol use?

Family History- Does this run in the
patient's family?

Remember: The patient may not know their full medical history. Often, you will have to ask specific and directed questions to get the information you are looking for

Sampter Triad:

Allergies + Asthma
+ Aspirin sensitivity

Familial/genetic syndromes, such as MEN (which may have concurrent thyroid or parathyroid carcinoma, pheochromocytoma, or typical physical features

ENT REVIEW OF SYSTEMS

Gen: fever/chills/weight changes

Ear: tinnitus/ vertigo/ hearing loss/ otalgia/ otorrhea

Nose: congestion/ rhinorrhea/ epistaxis/ decreased smell

Throat: pain/ dysphagia/ odynophagia

Larynx: hoarseness/ voice changes/ noisy breathing/ difficulty breathing / pain with speaking (odynophonia)

Trachea: noisy or difficulty breathing

Neck: lymphadenopathy/ new lumps or bumps/ pain/ swelling

Face: sinus pain/ pressure/ swelling/ numbness

PHYSICAL EXAM

Tips:

- Remember that you will be approaching the patient very closely and are examining the head and face so be careful not to invade the patient's personal space. (Also, check your breath and monitor the volume of your voice accordingly!)
- Try to go in the same order each time you examine the patient

Tools:

- Pen light, tongue blades, nasal speculum (or otoscope for nasal exam if speculum not available), otoscope
- Your eyes and hands

INITIAL EXAM

First, start by looking at the skin of the face

- Look for scars, any concerning lesions
- Check for symmetry, is there muscle weakness?

Does the patient have tell-tale signs?

- Nasal crease in allergies
- Noisy nasal breathing?

Listen to the patient's voice as they give the history/answer questions

- Is it breathy? Nasal? Does the patient have stridor?

Be observant. Most of this can be done within the first few minutes in the exam room

You can also usually get a sense within a few moments if the patient is acutely ill or whether their problem is more chronic in nature

FACE/CRANIAL NERVES

CN VII

- Bilateral muscles of facial expression
- Asymmetry or weakness

CN V

- Bilateral sensation in all distributions (V1-V3)

Extraocular Muscles (CN III, IV, VI)

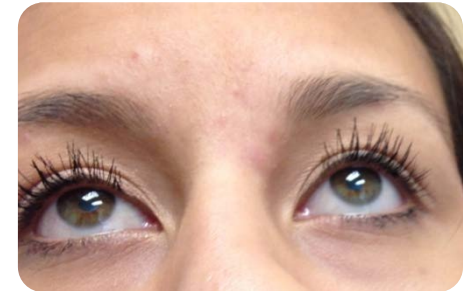CN VIII – hearing (see ear exam)

CN X - palate rise, voice

CN XI - shoulder shrug, head turn

CN XII- tongue protrusion

Facial muscle function is graded from 1-6 using the House-Brackmann classification. A score of 1 denotes full motion while 6 indicates no mobility. Each side is graded individually when there is asymmetry between sides.



EARS

External exam

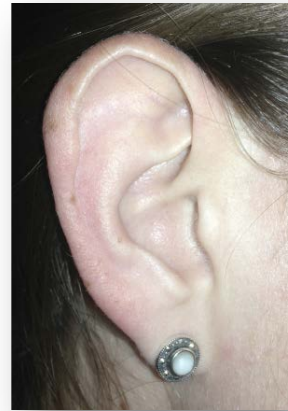- Deformities? Preauricular pits? Ulcers or lesions?

Otoscopy

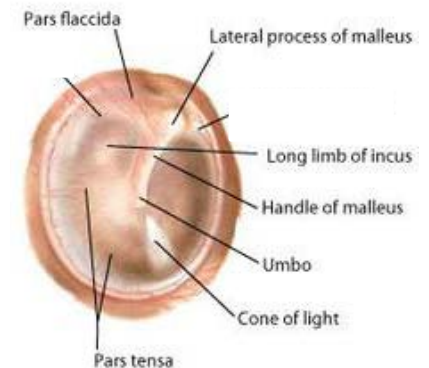
- External Auditory Canal
 - erythema, stenosis, debris or discharge
- Tympanic Membrane
 - Normal: Shiny, translucent, visible light reflex
 - Tympanosclerosis (white)
 - Erythema, bulging, dull, retractions
 - Perforations

Pneumatic otoscopy

- Mobility of TM



Otoscopic view of right tympanic membrane

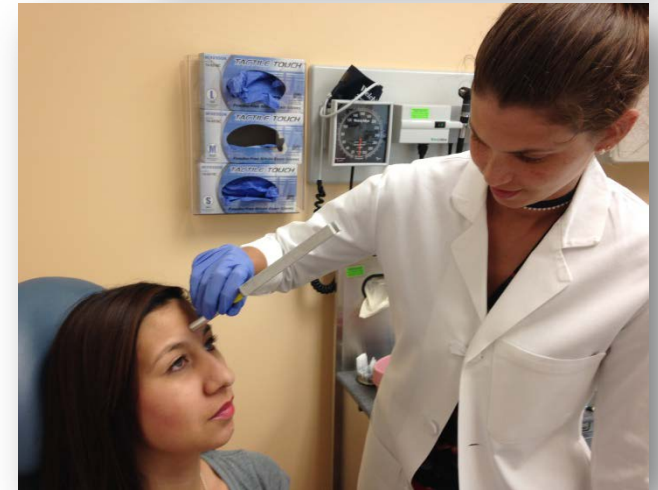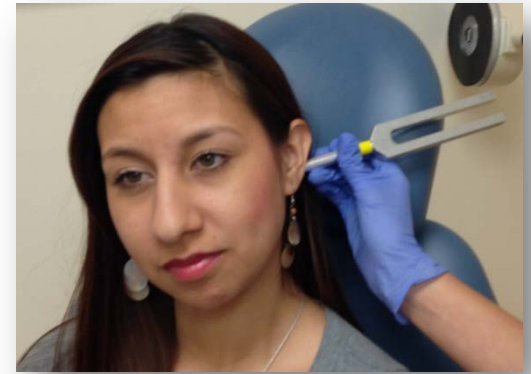


EARS

Microscopy: 3D image

Tuning fork exam

- Rinne: Air vs. bone conduction
 - Just outside to EAC vs. over mastoid
 - Normal: AC > BC
- Weber: Tuning fork on top/center of head
 - Normal: equal on both sides
 - Does the sound lateralize?



VIDEO- EAR EXAM

American Academy of Otolaryngology ENT EXAM videos

- Episode 1: The Ear Exam
- <http://www.entnet.org/EducationAndResearch/The-ENT-EXAM.cfm>

NOSE

Eternal exam

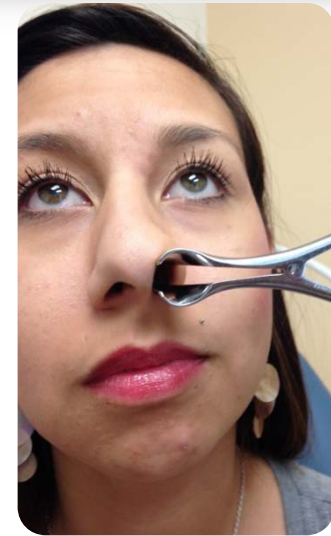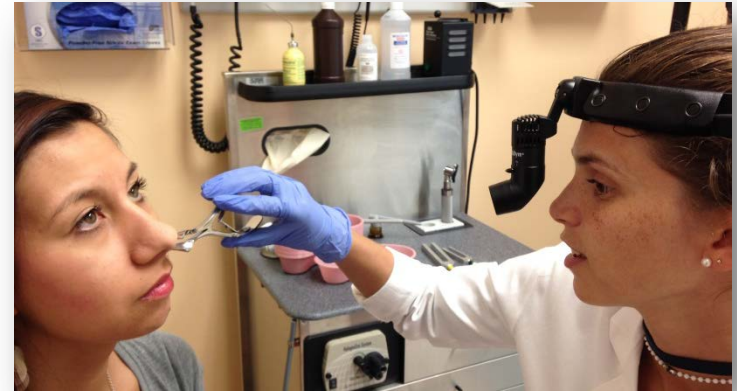- Deformities, symmetry, size/patency of nares

Nasal speculum (anterior rhinoscopy)

- Septum, inferior turbinates
- Septal deviation, boggy or pale turbinates/mucosa, hypertrophy of inferior turbinates, rhinorrhea, masses, prominent vessels

Rigid or flexible nasal endoscopy

- Vasoconstriction + decongest with Afrin (oxymetazone)
- Exam of sinus openings, mucosa, middle turbinates



VIDEO- FACE AND NOSE EXAM

American Academy of Otolaryngology ENT EXAM videos

- Episode 3: The Face and Nose Exam
- <http://www.entnet.org/EducationAndResearch/The-ENT-EXAM.cfm>

MOUTH

***Use your tongue blades!**

Teeth, gums, alveolar ridge

- Edentulous, dentures (remove), caries, bite

Mucosa

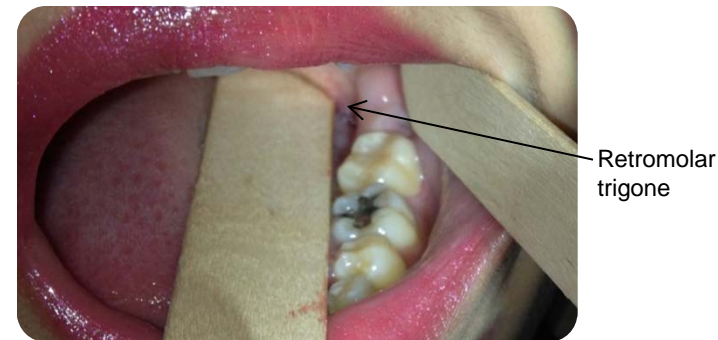
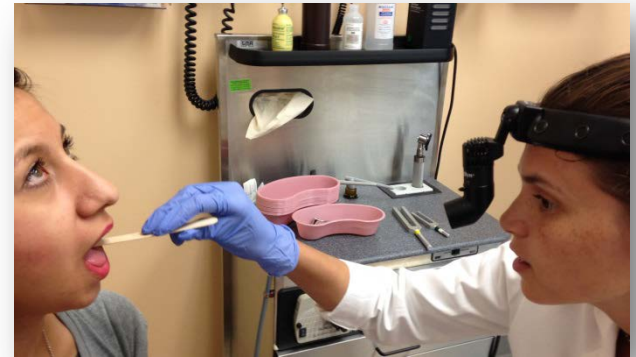- Buccal mucosa, palatal mucosa, lingual mucosa, vestibule (between teeth and lips)

Retromolar trigone

Tongue surfaces, including sides; examine bulk/atrophy, fasciculations, strength

Floor of mouth: look under the tongue!

Palpation: feel for masses on tongue/floor of mouth

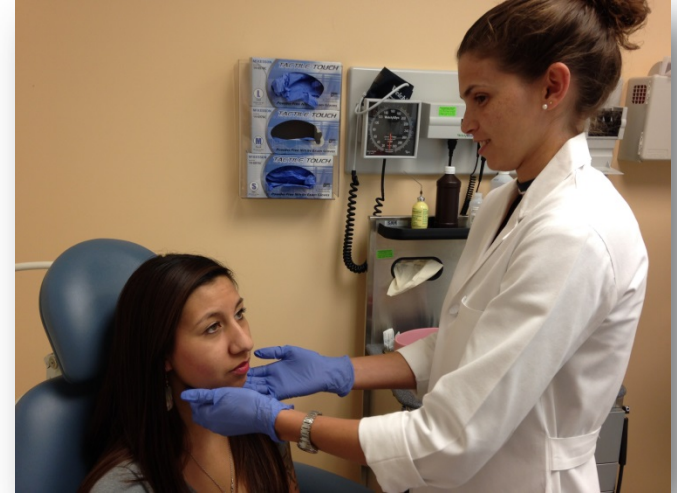

SALIVARY GLANDS

Palpate for masses, stones

Check for salivary duct patency

- Stenson's duct (parotid gland opening on buccal mucosa)
- Wharton's duct (submandibular and sublingual gland, located on floor of mouth)



ORAL CAVITY & OROPHARYNX

*Use your tongue blade here too!

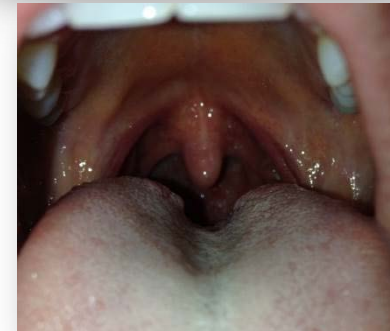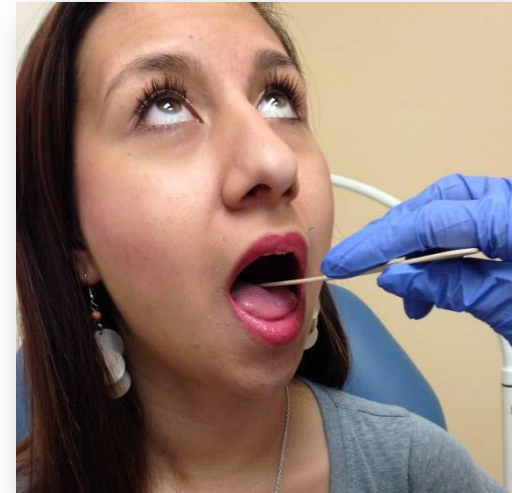
Palate and uvula

Tonsils

- Enlarged, symmetry, exudates, masses
- Grading tonsils
 - 1+ fills <25% of oropharynx between tonsillar pillars
 - 2+ 25-50%
 - 3+ 50-75%
 - 4+ >75%

Posterior pharyngeal wall

- Erythema, drainage, purulence, exudates



VIDEO- ORAL CAVITY AND NECK EXAM

American Academy of Otolaryngology ENT EXAM videos

- Episode 2: The Oral Cavity and Neck Exam
- <http://www.entnet.org/EducationAndResearch/The-ENT-EXAM.cfm>

NECK

External Exam

Lymphadenopathy

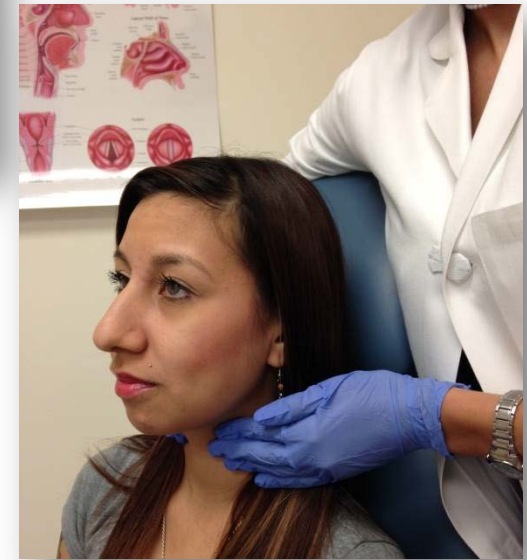
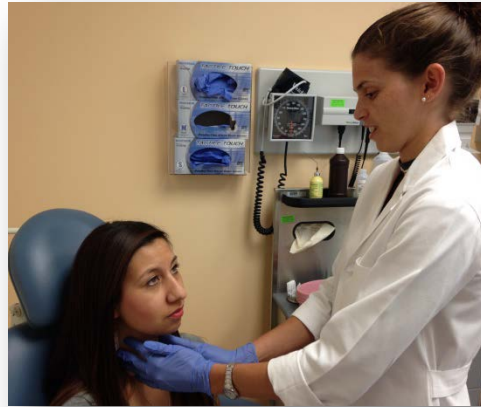Thyroid

Range of motion

Masses

- Exact location, size, mobility, depth, tenderness, texture, firmness, fluctuance

Larynx and trachea



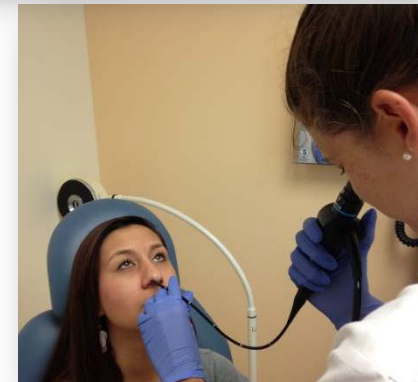
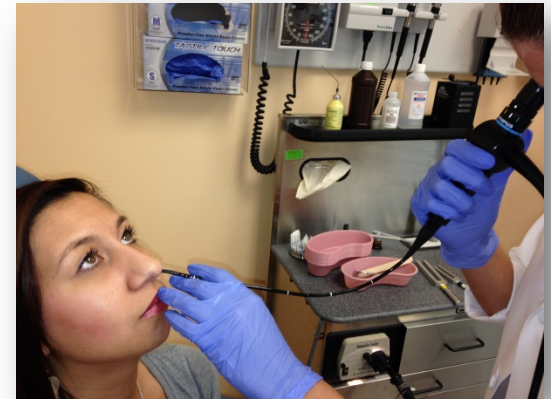
FIBEROPTIC NASOPHARYNGOSCOPY

What is it?

- Exam of nasal passages, nasopharynx, oropharynx, hypopharynx, larynx
- Use afrin/lidocaine before exam to decongest, vasoconstrict, and provide local anesthesia

Indications?

- Voice changes, neck masses, shortness of breath/noisy breathing, concern for mass anywhere along the aerodigestive tract (from nose down to larynx)



TAKE-HOME POINTS

All new patients should have full Head & Neck exam

Always be on the lookout for signs/symptoms of malignancy

Good lighting and the right tools are essential

Thorough exam is essential, especially when considering consultation/referral to a specialist

ACKNOWLEDGEMENTS/RESOURCES

Photo credits – Thank you to Megan M. Gaffey, MD and Lauren Thomas for participating in physical exam.

Primary Care Otolaryngology, 3rd edition. Edited by Mark K. Wax. (Available through the American Academy of Otolaryngology- Head and Neck Surgery Website- <http://www.entnet.org>)

American Academy of Otolaryngology Website (www.entnet.org); ENT EXAM videos: <http://www.entnet.org/EducationAndResearch/The-ENT-EXAM.cfm>

Thank you to Christian Stallworth, MD for overseeing this project and providing advisory support.

Editing and input: Jeanne Hatcher MD, John Morehead MD