

# Ichthyosis as a paraneoplastic syndrome and atypical variant of mycosis fungoides: two cases report

Małgorzata Sokółowska-Wojdyło<sup>1</sup>, Marta Malek<sup>1</sup>, Hanna Majewska<sup>2</sup>, Roman Nowicki<sup>1</sup>, Jadwiga Roszkiewicz<sup>1</sup>

<sup>1</sup>Department of Dermatology, Venereology and Allergology, Medical University of Gdansk, Poland  
Head: Prof. Roman Nowicki MD, PhD

<sup>2</sup>Department of Pathomorphology, Medical University of Gdansk, Poland  
Head: Prof. Wojciech Biernat MD, PhD

Postępy Derm Alergol 2012; XXIX, 6: 467-470

DOI: 10.5114/pdia.2012.32396

## Abstract

Acquired ichthyosis is a known paraneoplastic sign of lymphoproliferative malignancies, but ichthyosiform eruption can also constitute a rare atypical variant of mycosis fungoides. Ichthyosiform mycosis fungoides differs from acquired ichthyosis associated with mycosis fungoides in histopathology. Histological pictures of paraneoplastic ichthyosis usually do not show any aspect related to malignancy in the skin. In both cases thinning of the granular layer and decrease of filaggrin in that layer are observed. We describe here 2 patients with mycosis fungoides, who were treated in the Department of Dermatology, the first one with ichthyosiform mycosis fungoides and the other one with acquired ichthyosis with coexisting mycosis fungoides.

**Key words:** mycosis fungoides, ichthyosis, paraneoplastic syndrome.

## Introduction

Mycosis fungoides (MF) is the most common primary cutaneous lymphoma. The disease usually affects people in middle age (40-50 years), with a predominance for the male gender (M/F: 2 : 1) [1-4]. Apart from the classic Alibert-Bazen type of MF, with typical skin lesions: patches, plaques and tumors, many atypical variants have been reported (Table 1) [5].

The ichthyoses are a heterogeneous group of cutaneous keratinization disorders. The symptoms consist of pityroid and rhomboid scales on the skin with severe dryness [6, 7]. Acquired ichthyosis (AI) in contrast to the congenital type is not a syndrome but a clinical sign of many systemic diseases, including malignant, infectious, autoimmune and endocrine disorders, as well as metabolic conditions and medications (Table 2) [8].

Ichthyosiform skin lesions can coexist with MF or constitute a very rare atypical variant of this disease. Two patients with MF, who were treated in the Department of Dermatology, will be presented: one with an ichthyosiform type of MF (IMF), and the other with AI with coexisting MF.

## Case reports

### Case 1

A 71-year-old man, with hypertension, was admitted to the Department of Dermatology because of 20 years'

erythematosus scaling lesions. The ichthyosiform lesions were spread on the trunk, arms and legs (Figure 1). Clinical examination did not show enlarged lymph nodes and organomegaly. Histological features of biopsy from abdominal scaling skin lesions revealed orthokeratosis, thinning of the granular layer and infiltration of atypical cells into the epidermis and the superficial dermis (Figure 2). Immunohistochemical studies demonstrated that most infiltrated atypical lymphocytes were CD4, CD8 was positive focally. The results of the routine blood investigations were normal. Chest-X-ray examination and abdomen ultrasonography revealed no abnormalities. The diagnosis of MF, stage IB (T2N0M0), was established. The patient was treated with ultraviolet light B 311 therapy three times a week. After 5 months of treatment the ichthyosiform eruption regressed and pruritus decreased.

### Case 2

A 69-year-old male patient, with glaucoma, cataract and prostatic hypertrophy, was referred to the Department of Dermatology because of erythematosus lesions on the trunk and lower leg with pruritus lasting for 6 months (Figure 3). Additionally, the patient has suffered from severe dryness of the skin with scaling on the surface for 5 years, what was diagnosed as acquired ichthyosis without any known etiology (Figure 4). He did not take any medicaments

---

**Address for correspondence:** Marta Malek MD, PhD, Department of Dermatology, Venereology and Allergology, Medical University of Gdansk, 7 Dębinki St, 80-211 Gdansk, Poland, phone: +48 58 349 25 80, e-mail: mmalek@uck.gda.pl

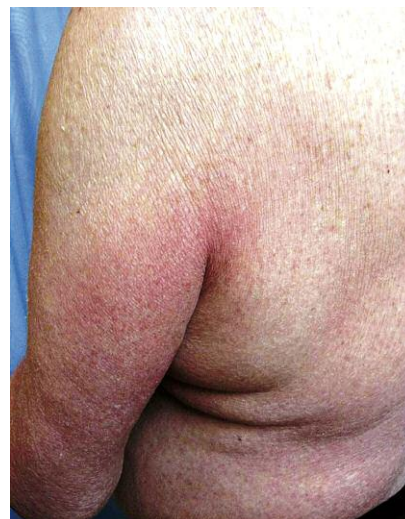**Table 1.** Clinicopathological variants of mycosis fungoides

Acanthosis nigricans-like mycosis fungoides
Angiocentric/angiodestructive mycosis fungoides
Bullous (vesiculobullous) mycosis fungoides
Dyshidrotic mycosis fungoides
Erythrodermic mycosis fungoides
Follicular (pilotropic) mycosis fungoides
Granulomatous mycosis fungoides
Granulomatous slack skin syndrome
Hyperpigmented mycosis fungoides
Hypopigmented mycosis fungoides
Ichthyosis-like mycosis fungoides
Interstitial mycosis fungoides
'Invisible' mycosis fungoides
Mucinous mycosis fungoides
Mycosis fungoides palmaris et plantaris
Mycosis fungoides with eruptive infundibular cysts
Mycosis fungoides with follicular mucinosis
Mycosis fungoides with large-cell transformation
Pagetoid reticulosis (Woringer-Kolopp type)
Papular mycosis fungoides
Papuloerythroderma of Ofuji
Perioral dermatitis-like mycosis fungoides
Pigmented purpura-like mycosis fungoides
Poikilodermatous mycosis fungoides (poikiloderma vasculare atrophicans)
Pustular mycosis fungoides
Small-plaque parapsoriasis
Syringotropic mycosis fungoides
Unilesional (solitary) mycosis fungoides
Verrucous/hyperkeratotic mycosis fungoides
Zosteriform mycosis fungoides

inducing ichthyosis. The diseases, including infections, solid tumors, kidney diseases, hypothyroidism, and nutritional deficiencies were ruled out. There were no peripheral lymphadenopathy or organomegaly. Histopathological examination of two skin biopsies from erythematous lesions revealed mycosis fungoides with infiltration of atypical lymphocytes CD 3+, CD 4+, CD 8+, CD 5+ and CD 20– (Figure 5). The biopsy from ichthyosiform eruptions disclosed hyperkeratosis and parakeratosis without infiltration of atypical cells typical of MF (Figure 6). Laboratory and imaging studies revealed no significant aberrations. The diagnosis

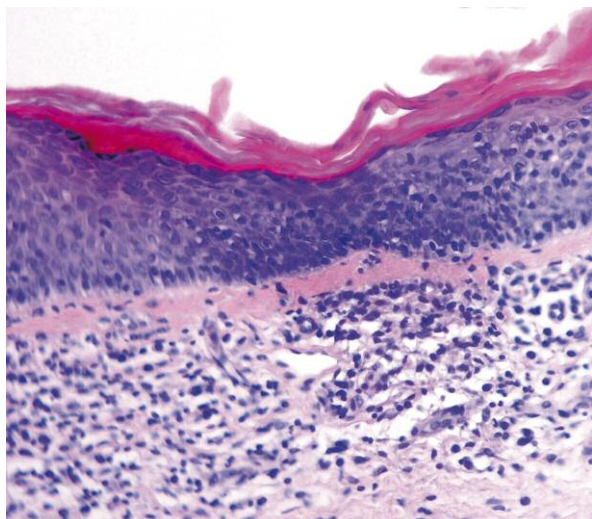
**Table 2.** Causes of acquired ichthyotic skin lesions

Category	Disorders
Paraneoplastic	Hodgkin lymphoma
	Other lymphomas
	Kaposi sarcoma
	Other malignancy
Infections	Leprosy
	Tuberculosis
	HIV/AIDS
Nutritional deficiencies	Pellagra
	Vitamin A deficiency
Medicaments	Statins
	Nicotinic acid
	Allopurinol
	Cimetidine
	Lithium
	Retinoids
Others	Crohn's disease
	Down's syndrome
	Hypothyroidism
	Kidney diseases

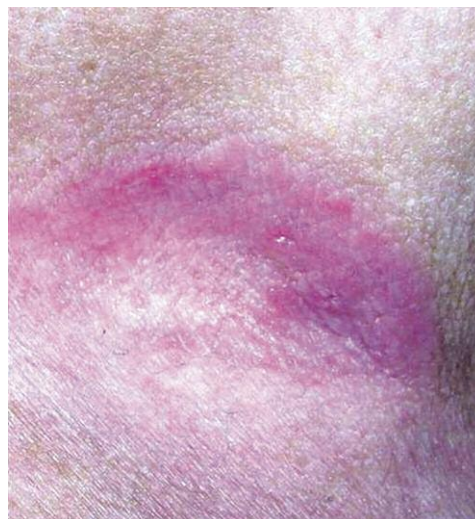

**Figure 1.** Case 1. Erythematous, scaling skin lesions on the trunk and left arm diagnosed as IMF

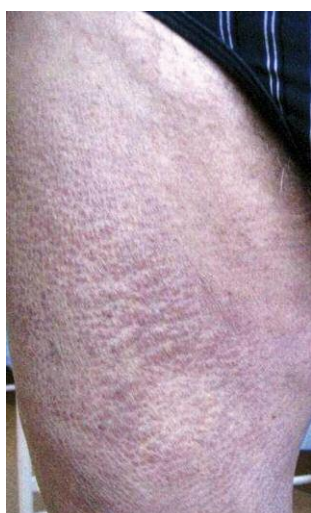of MF, stage IB (T2N0M0) and paraneoplastic ichthyosis was established. The patient was treated with ultraviolet light B 311 therapy three times a week. After 5 months of treatment the remission of erythematous lesions as well as ichthyosiform changes was observed.



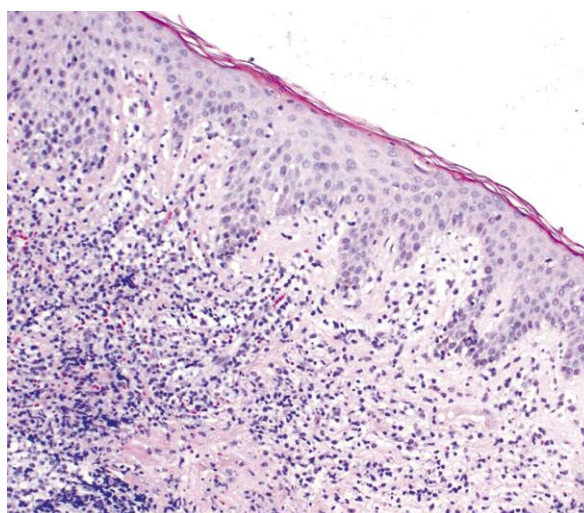
**Figure 2.** Case 1. Histopathologic findings of ichthyosiform eruption: orthokeratosis, thinning of the granular layer, mild acanthosis, abundant infiltration of mononuclear cells (lymphocytes, histiocytes, atypical cells) into the epidermis and the superficial dermis. H + E, 40×



**Figure 3.** Case 2. Erythematous skin lesion in the armpit area diagnosed as MF



**Figure 4.** Case 2. Scaling skin lesions on the right thigh diagnosed as AI



**Figure 5.** Case 2. Histopathologic findings of erythematous lesions: Abundant infiltration of atypical lymphocytes into the dermis. H + E, 10×

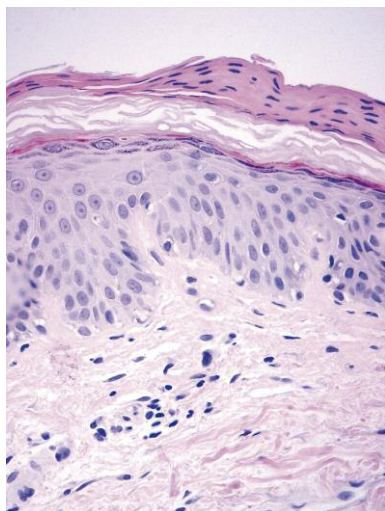
## Discussion

Among the malignant diseases known to be associated with ichthyosiform skin lesions, lymphoproliferative neoplasms are reported most often [6]. Morizane *et al.*, during 5 years' observation of 106 patients with malignant lymphoma found 9 with ichthyosiform skin lesions including 3 of 10 patients with anaplastic large cell lymphoma (ALCL) and 6 of 44 patients with MF. None of the 18 observed patients with cutaneous B-cell lymphoma had ichthyosiform eruptions [9]. Also the complication of ichthyosiform

eruptions in cutaneous B-cell lymphoma has not thus far been reported in the English literature.

Ichthyosiform type of MF differs from AI associated with MF in histopathology. We distinguish AI, IMF and the overlap of AI and IMF. Acquired ichthyosis demonstrated packed orthohyperkeratosis mimicking ichthyosis vulgaris, without lymphocytic infiltrates. Ichthyosiform type of MF showed epidermotropic infiltration of atypical lymphocytes without ichthyosis vulgaris-like packed hyperkeratosis. The overlap of AI and IMF discloses both packed hyperkeratosis and epidermotropic infiltration of atypical lymphocytes.





**Figure 6.** Case 2. Histopathologic findings of scaling lesions: packed hyperkeratosis with marked parakeratosis. No infiltration of atypical lymphocytes is present. H + E, 40x

In all three situations, thinning of the granular layer is observed. Also an expression of filaggrin, a key protein involved in the terminal differentiation of the epidermis and formation of the skin barrier, in the granular layers is markedly diminished in all three cases, what is typical of ichthyosis vulgaris [9].

Ichthyosiform type of MF is a very rare atypical variant of this disease, arising in 1.8-3.5% of MF patients [10, 11]. According to the clinical findings, IMF can be divided into 3 types: as the sole manifestation of the disease, in conjunction with additional atypical findings of MF and in combination with the classic types of MF [12]. Among cases presented by Morizane *et al.* [9], diagnosis of IMF should be only considered when it is the sole manifestation of MF, as in our first case.

Acquired ichthyosis, as a paraneoplastic syndrome, may precede by 2 weeks – 10 years the diagnosis of the malignancy. Prolonged intervals were especially documented in the lymphoproliferative diseases [6]. The interval between ichthyosis and MF was 5 years in our second patient.

Authors suggest that AI is a frequent complication of CD 30+ lymphoproliferative disorders, such as Hodgkin Lymphoma CD 30+, ALCL or lymphomatoid papulosis. Those observations confirm Morizane *et al.* in their series. Acquired ichthyosis was diagnosed in five of nine patients with ichthyotic eruptions. Three of these patients had ALCL and 2 had MF (stage IVa and IIb) with CD 30+ atypical lymphocytes in tumors [9].

Clinical remission in IMF is obtained with nonaggressive therapies such as topical treatments, PUVA therapy and Ultraviolet light B (UVB) [12, 13]. A significant remission was observed, after 5 months of UVB 311 therapy 3 times a week in the case of our first patient. In the situation when MF coexists with ichthyosis, 1-6 months' treat-

ment of the underlying malignant disease results in healing of ichthyosis in most cases [6], as occurred in our second case. It confirms ichthyosis as a paraneoplastic syndrome.

Ichthyotic skin lesions can indicate the presence of a severe underlying disease or reveals an atypical form of MF, and thus always requires careful diagnosis and follow-up.

#### References

1. Sokołowska-Wojdyło M, Maciejewska-Radomska A, Trzeciak M, et al. Results of the treatment primary cutaneous lymphomas in the Department of Dermatology Medical University in Gdansk performed in years 1997-2008. *Dermatol Klin* 2009; 11: 141-6.
2. Wojewoda K, Brenner J, Sokołowska-Wojdyło M, Barańska-Rybak M. Treatment of primary cutaneous lymphoma with reference to the latest therapeutic consensus of the Polish Lymphoma Research Group (PLRG). *Post Dermatol Alergol* 2012; 28: 63-8.
3. Sikorska M, Sokołowska-Wojdyło M, Kowalczyk A, Roszkiewicz J. Effectiveness of interferon alpha in mycosis fungoides therapy. *Post Dermatol Alergol* 2012; 28: 51-5.
4. Olek-Hrab K, Osmola Mańkowska A, Silny W, et al. Use of UVA1 in the treatment of mycosis fungoides. *Post Dermatol Alergol* 2011; 27: 158-64.
5. Requena L, González-Guerra E, Angulo J, et al. Anetodermic mycosis fungoides: a new clinicopathological variant of mycosis fungoides. *Br J Dermatol* 2008; 158: 157-62.
6. Levy O, Tishler M. Acquired ichthyosis as the primary manifestation of renal cell carcinoma. *Isr Med Assoc J* 2009; 11: 121-2.
7. Rabhi M, Ennibi K, Harket A, et al. Acquired ichthyosis disclosing non-Hodgkin's malignant lymphoma. *Intern Med* 2007; 46: 397-9.
8. Oji V. Keratinization disorders. In: Braun-Falco Dermatology. Burgdorf WHC, Plewig G, Wolff HH, Landthaler M (eds.). Czelej, Lublin 2011; 839-74.
9. Morizane S, Setsu N, Yamamoto T, et al. Ichthyosiform eruptions in association with primary cutaneous T-cell lymphomas. *Br J Dermatol* 2009; 161: 115-20.
10. Marzano AV, Borghi A, Facchetti M, Alessi E. Ichthyosiform mycosis fungoides. *Dermatology* 2002; 204: 124-9.
11. Hodak E, Amitay I, Feinmesser M, et al. Ichthyosiform mycosis fungoides: an atypical variant of cutaneous T-cell lymphoma. *J Am Acad Dermatol* 2004; 50: 368-74.
12. Nam KH, Park J, Hong JS, et al. Mycosis fungoides as an ichthyosiform eruption. *Ann Dermatol* 2009; 2: 182-4.
13. Badawy E, D'Incan M, El Majjaoui S, et al. Ichthyosiform mycosis fungoides. *Eur J Dermatol* 2002; 12: 594-6.