

Muscle tissue



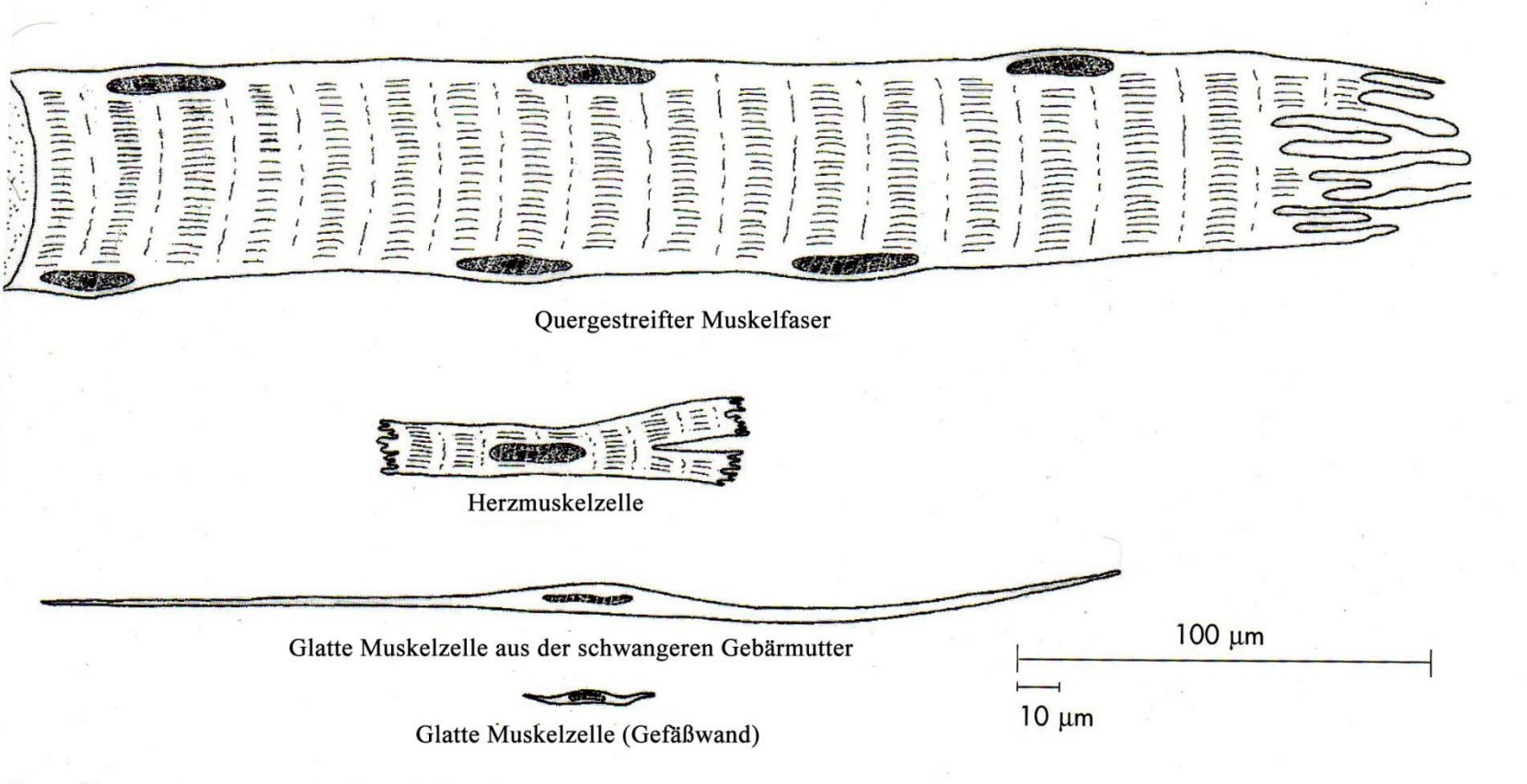
Ph.D., Dr. Dávid Lendvai

Anatomy, Histology and Embryology Institute
Semmelweis University

2018.

Picture: Myron – Diskobolos (copy, Vatikan)

Muscle tissue – in general



Muscle tissue

General to the movement (taxis):

- in all cells
- transformation of chemical energy into mechanical work
- advanced in muscle tissue
- cell skeletal component: actin
- contractile element: myosin

Striated muscle tissue

1. skeletal muscle
2. internal organs (oesophagus)
3. cardiac muscles

Smooth muscle

Without striation

Striated muscle

Striated muscle fiber

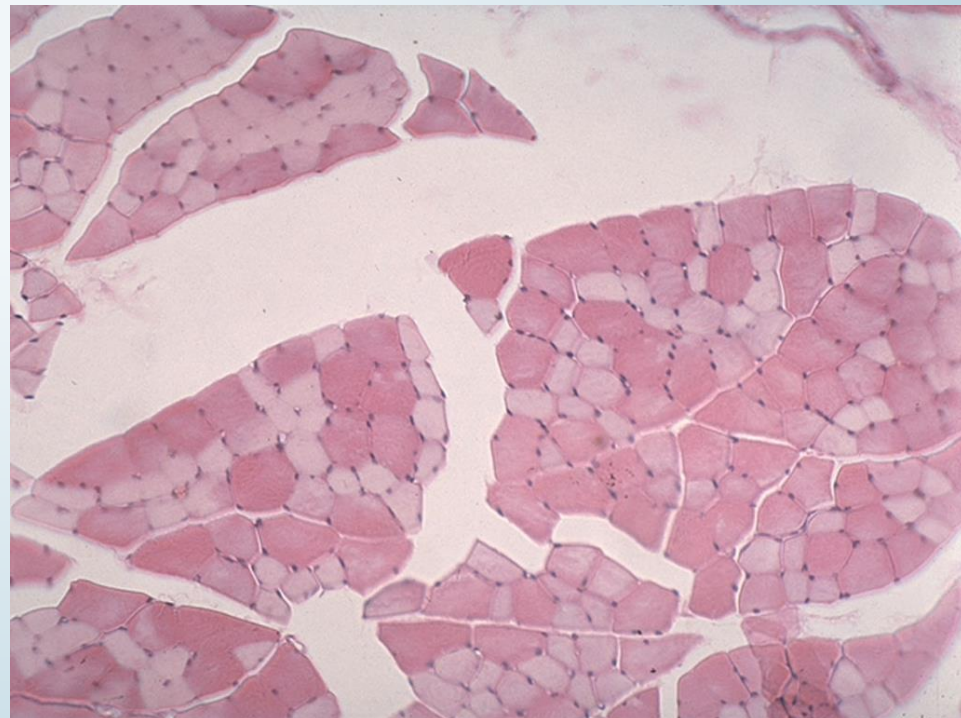
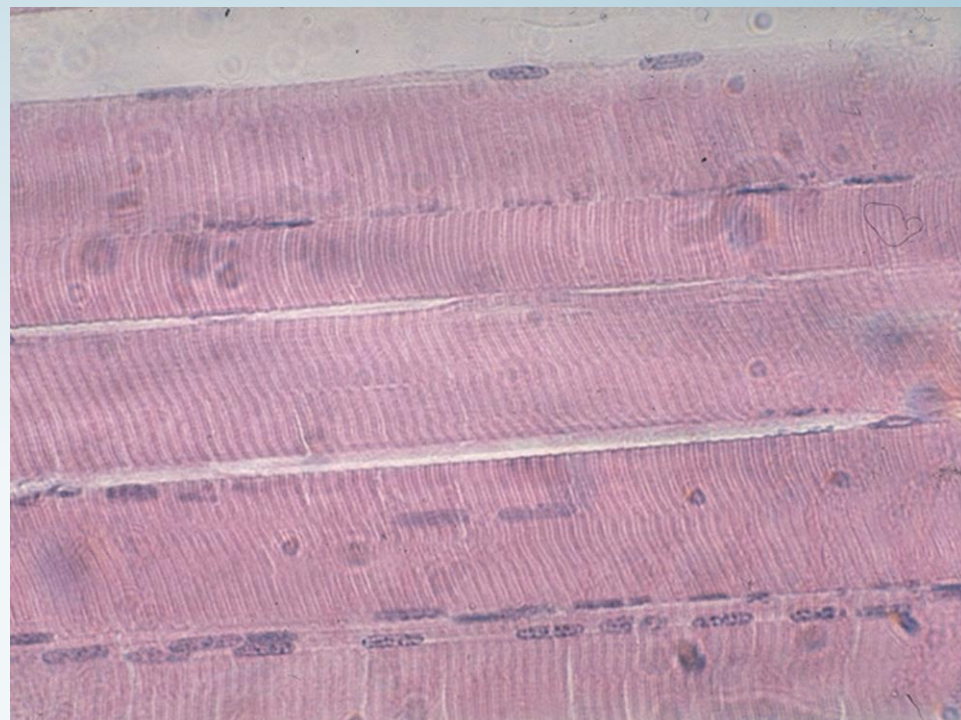
- Histological/functional unit
- giant cells
- syntitium
- multinucleolar, long (up to 40 cm)
- diameter 10-100 μm

Striation

- isotrope and anisotrope bands
(Polarisationsmikroskope)
- Z, H, M bands

Myofibrils

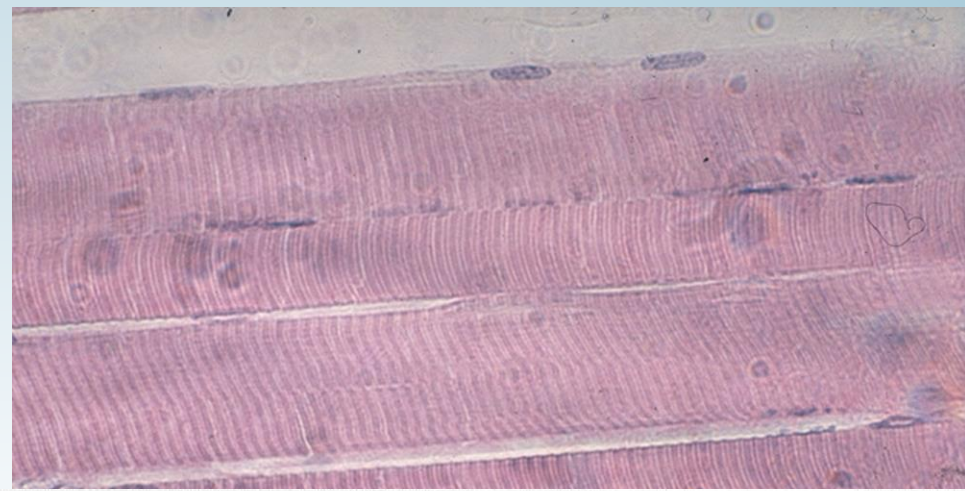
- thin units
- thick units
- sarcomer
- filaments



Striated muscle

Striated muscle fiber

- Histological/fuctional unit
- giant cells
- syntitium
- multinucleolar, long (up to 40 cm)
- diameter 10-100 μm

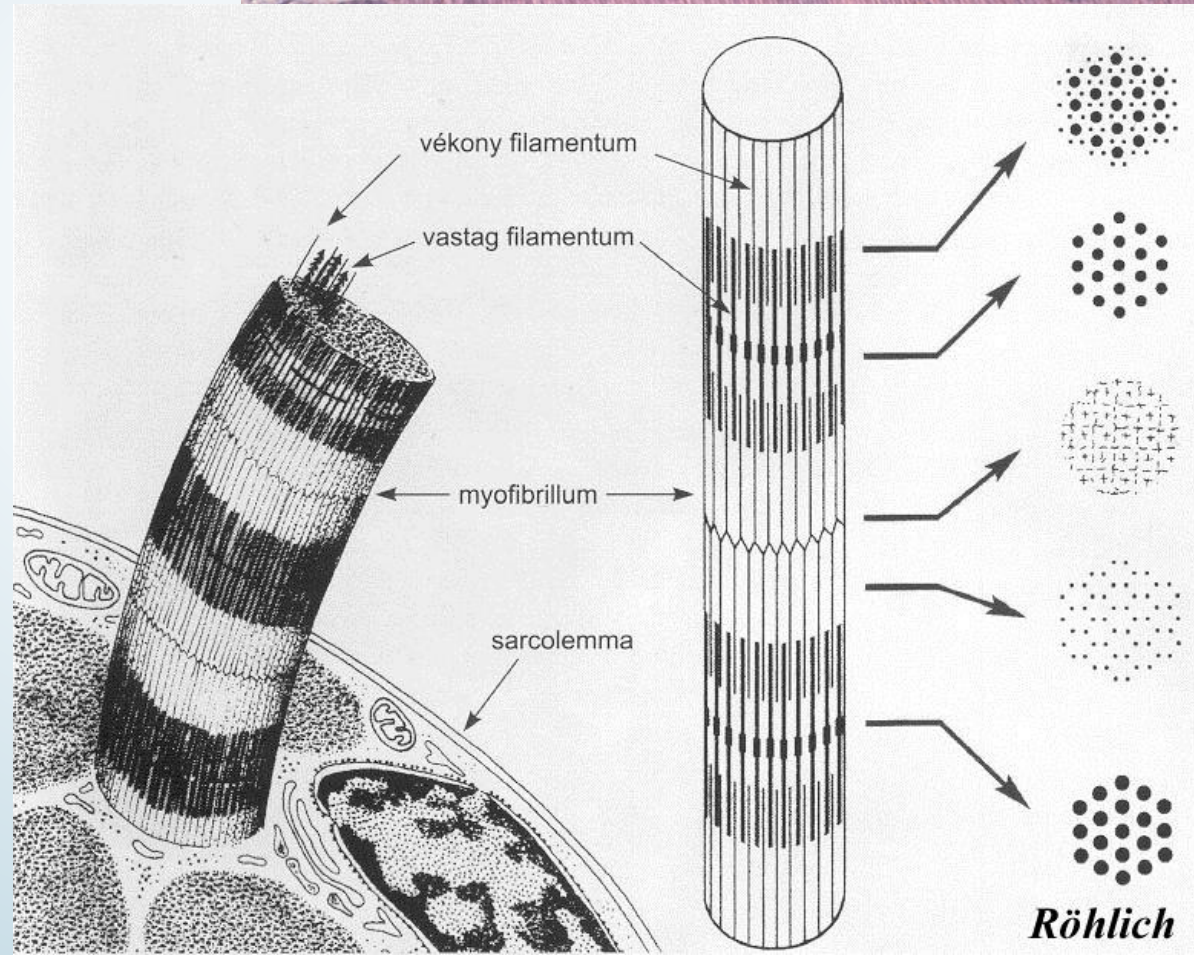


Striation

- isotrope and anisotrope bands
(Polarisationsmikroskope)
- Z, H, M bands

Myofibrils

- thin units
- thick units
- sarcomer
- filaments



Striated muscle

Myofilaments

Myosin


- main ingredient of the A-strip
- about 300 myosin molecules
- head and rod shared bipolarity
- cross-connection M strips

Actin

- main component of the I-strip
- at the ends: Z-disc and tropomodulin
- twisted double chained tropomyosin and troponin (I, C, T)

skeletal proteins

- Z-filamentum, myomesin, nebulin, Titin (for longitudinal stabilization)



Striated muscle

Myofilaments

Myosin

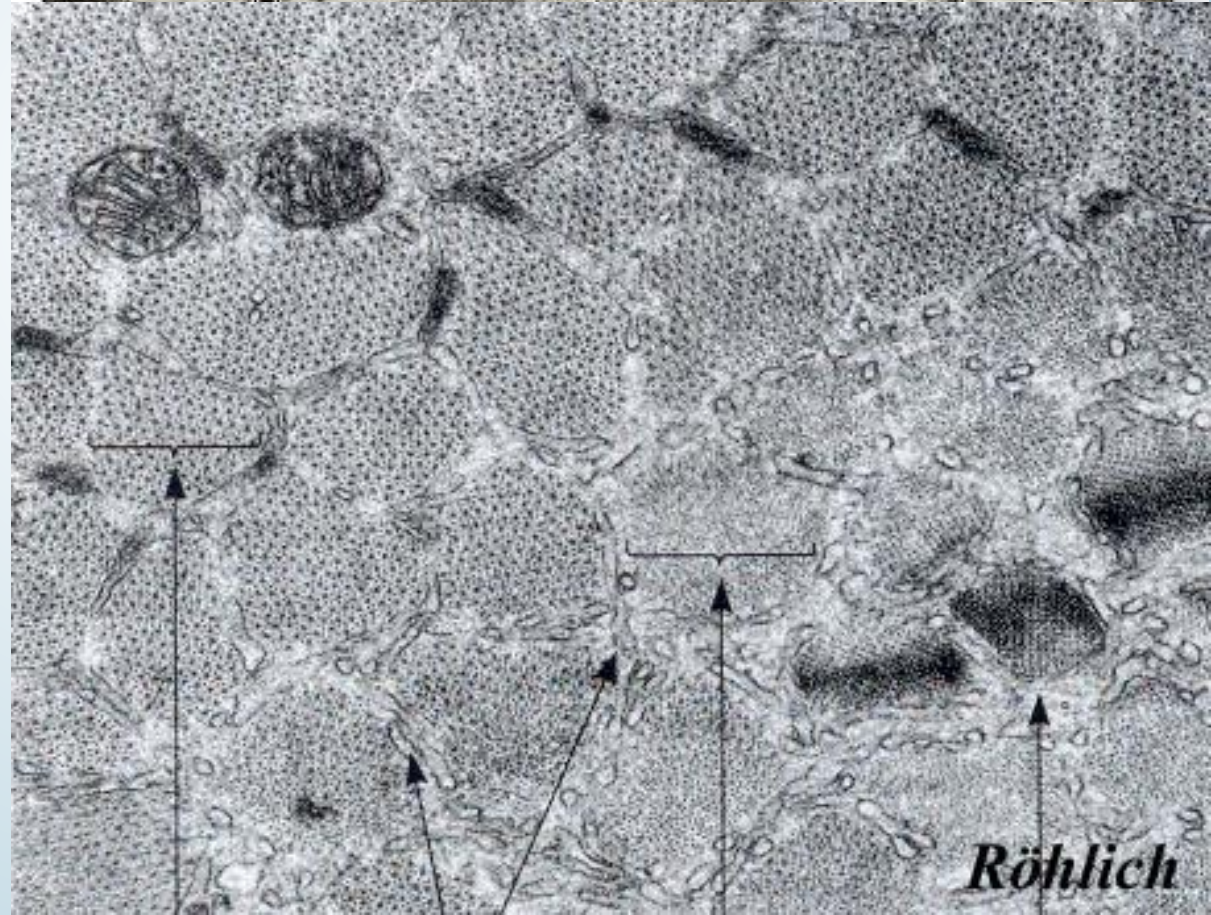
- main ingredient of the A-strip
- about 300 myosin molecules
- head and rod shared bipolarity
- cross-connection M strips

Actin

- main component of the I-strip
- at the ends: Z-disc and tropomodulin
- twisted double chained tropomyosin and troponin (I, C, T)

skeletal proteins

- Z-filamentum, myomesin, nebulin, Titin (for longitudinal stabilization)



Striated muscle

Myofilaments

Myosin

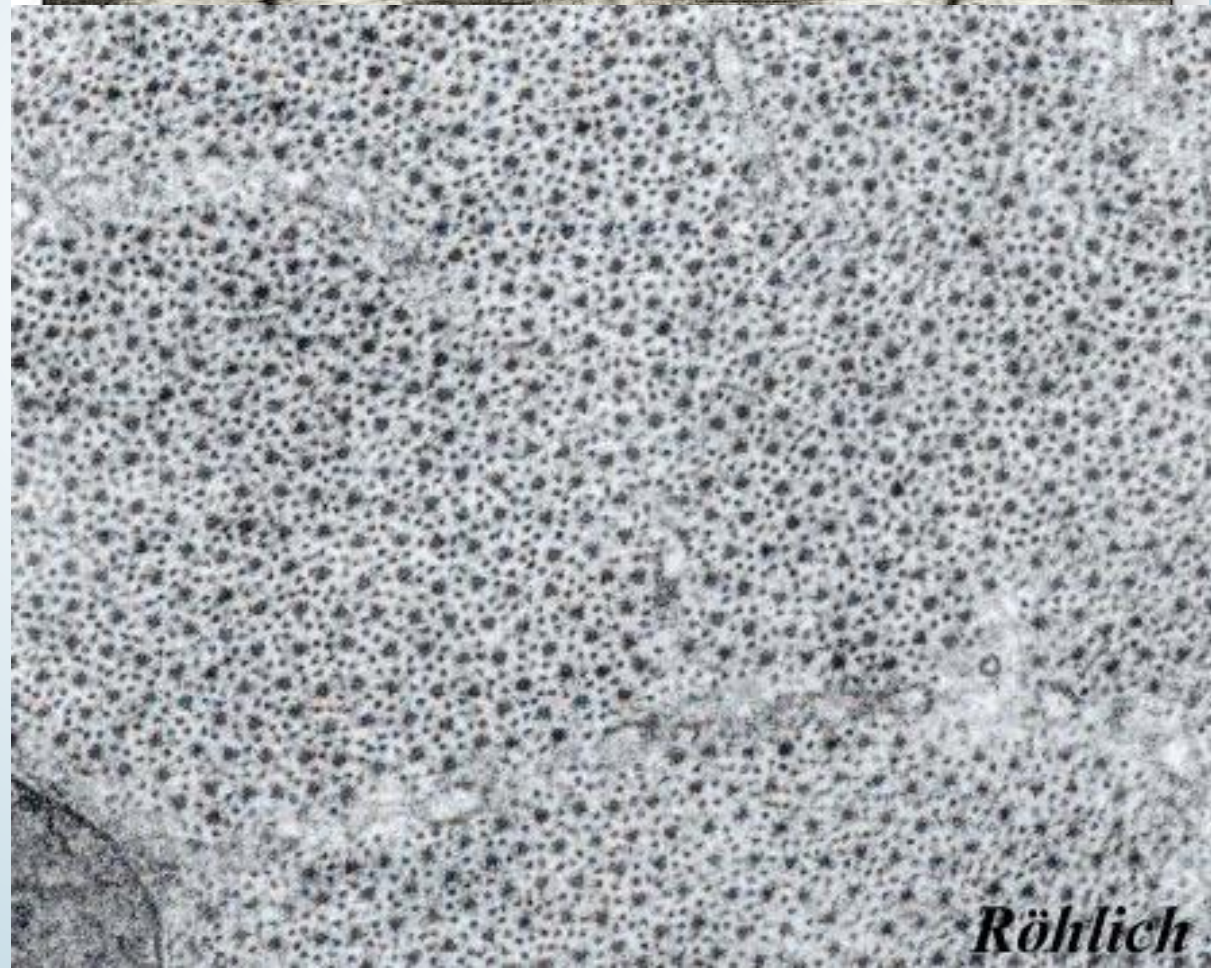
- main ingredient of the A-strip
- about 300 myosin molecules
- head and rod shared bipolarity
- cross-connection M strips

Actin

- main component of the I-strip
- at the ends: Z-disc and tropomodulin
- twisted double chained tropomyosin and troponin (I, C, T)

skeletal proteins

- Z-filamentum, myomesin, nebulin, Titin (for longitudinal stabilization)

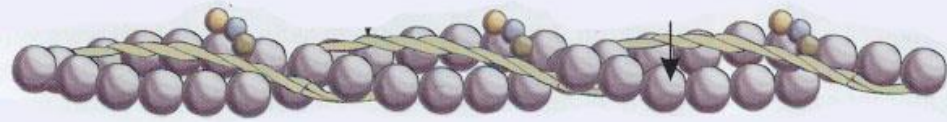
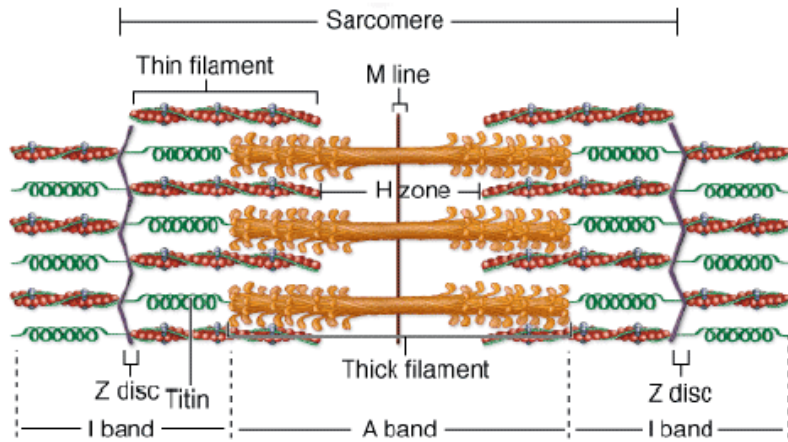


Striated muscle

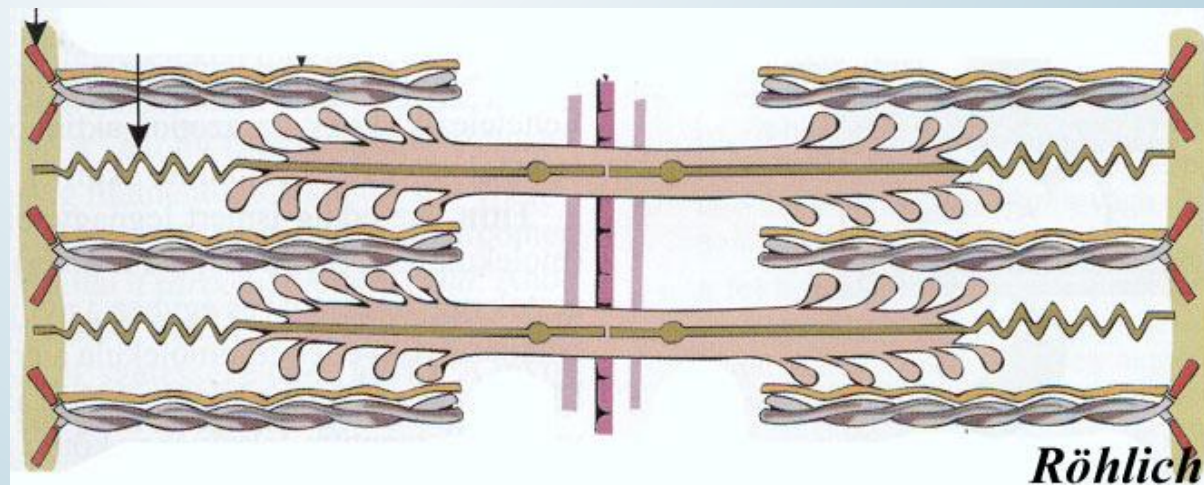
Sarcomer

Sarcomer

- change in the length
- Sliding-Filament-Theory
(several times 5nm jumps)



Röhlich



Röhlich

Striated muscle - Sarcolemma, Sarcoplasma

Sarcolemma

- cell membrane and lamina basalis
- membrane skeleton (dystrophin and actin)
- satellite cells (regeneration, outside)

Sarcoplasma

- Nucleus (Function↓)
- Mitochondria
- Lipid drops, glycogen

T-tubules

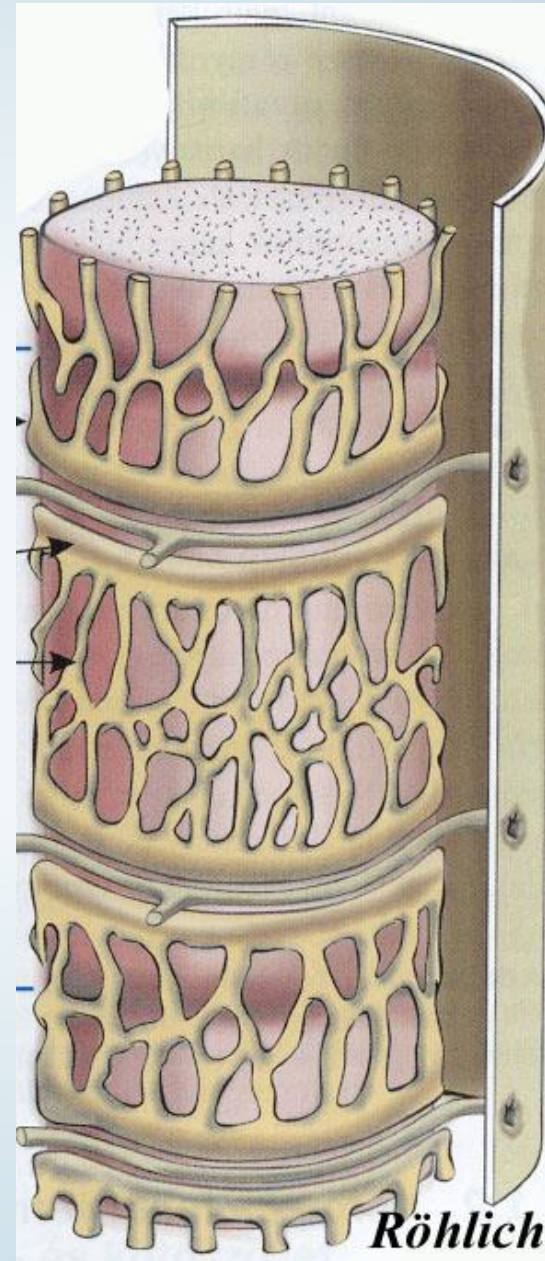
- passing the potential
- along A-strips, across

Sarcoplasmic reticulum (SR)

- Ca delivery- adapted ER- long tubes and cystersns

Triad

- triple structure in terminal cystersns, regulation



Striated Muscles - Intermediate Filaments

Connection of myofibrils

Desmin

- in the Z-line all around
- longitudinal (shell) Skelemin
- in the M line, between the neighboring molecules
- Paranemin, Sinemin, Ankizin
- At the peripheral filaments, to the sarcolemma at Z-line (Costamers)

Muscle fibres - Types

Type-I fibres

- slow red fibres
- oxydative methabolism
- rich in mithochondria
- lots of capillaries
- lots of lipids
- less of glycogen

long lasting

m. masseter, diaphragma

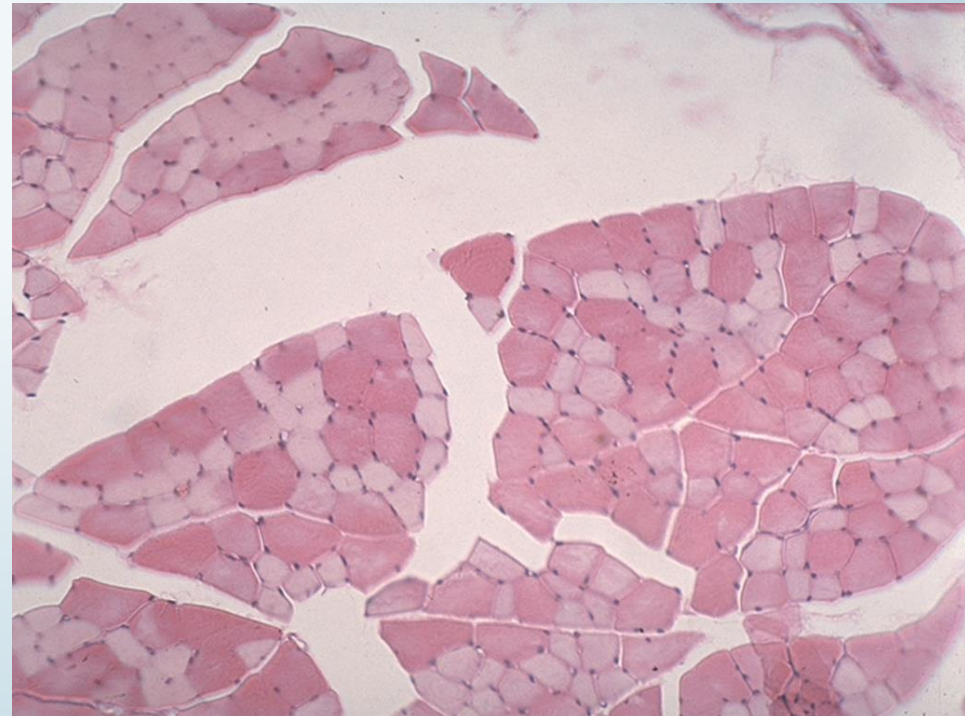
Type-II twitch fibres

- fast
- glycolic methabolism
- smal mitochondria
- less of capillaries
- less of lipids
- lots of glycogen

Strong, not long lasting

external muscles of the eye

Transitional fibres



Connection between muscle and connective tissue

Epimysium

- Nerves and blood vessels

Perimysium

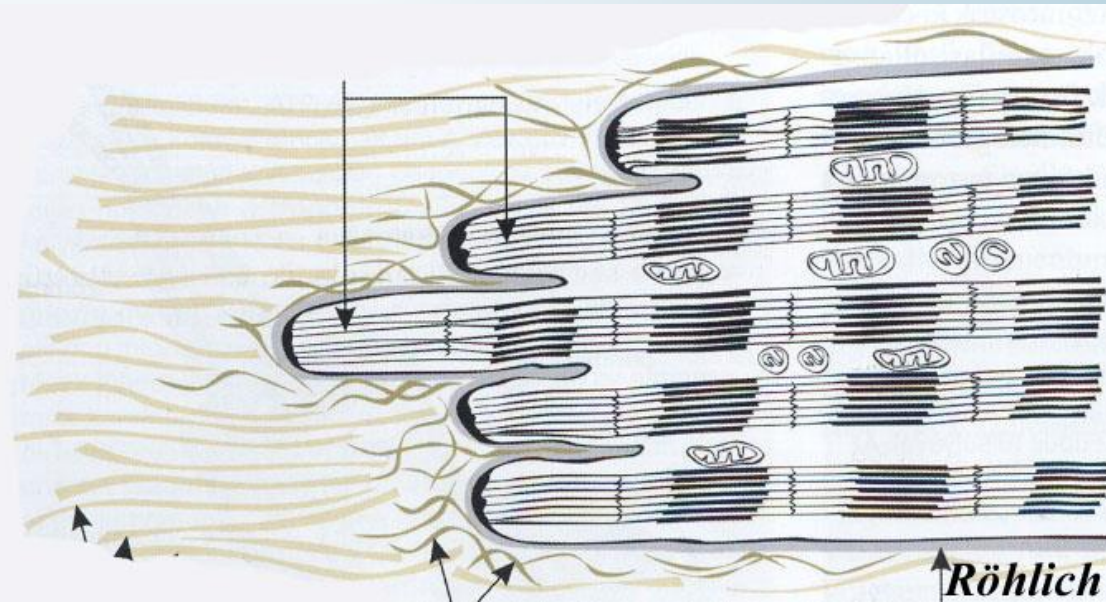
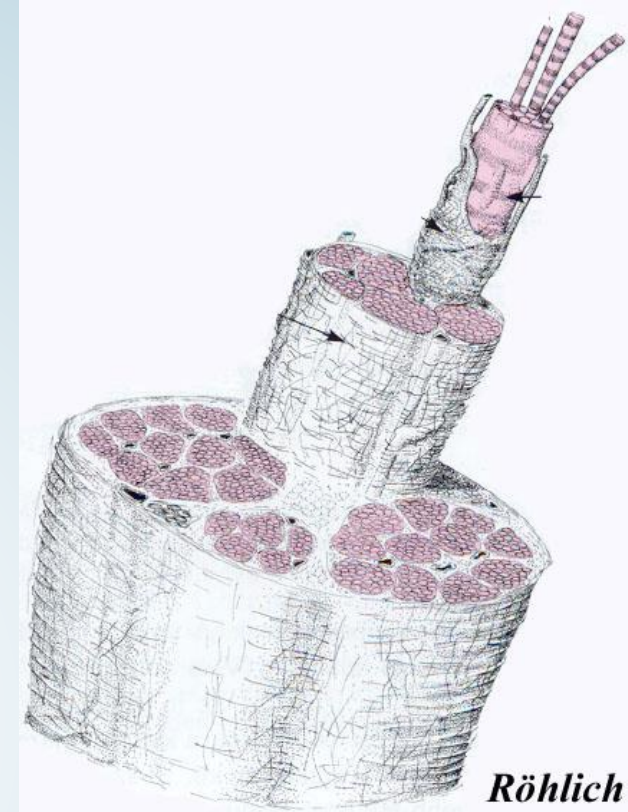
- Septa
- Nerves, blood vessels, muscle spindle (receptor)

Endomysium

- fine CT. around the muscle fibres
- wavy blood vessels

Muscle-tendon transition

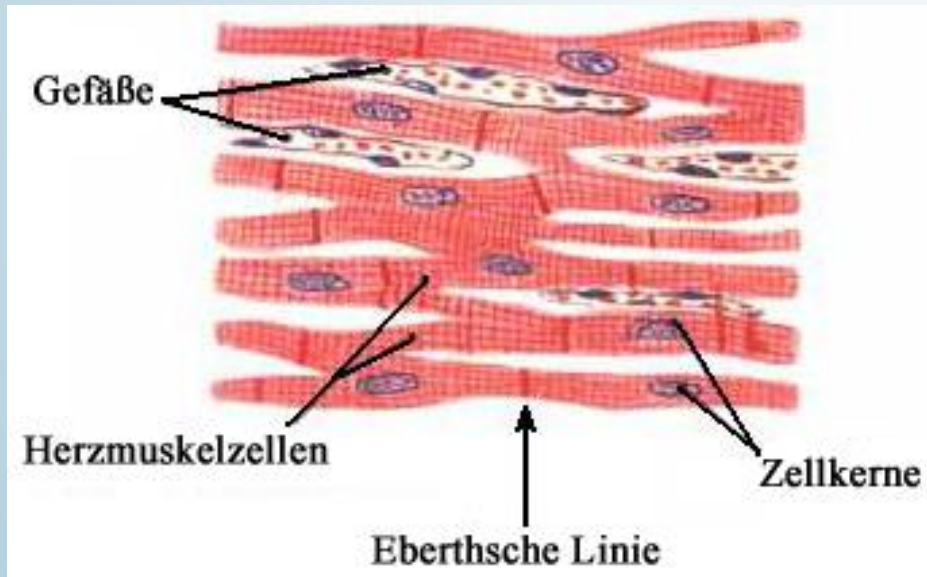
- complete sarcomers



Cardiac muscle

- histological/functional unit: cardiac muscle cell
- working muscles
- specialized cells: conducting system
- in the atria: hormone production
- does not tire, works lifelong
- aerobic metabolism!! (O_2)
- receptors for parasympathetic (M_2, M_3) and sympathetic nervous system (β_1)

Röhlich

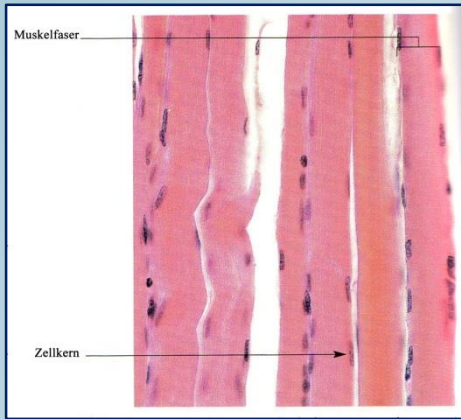


cardiac muscle cell - light microscope:

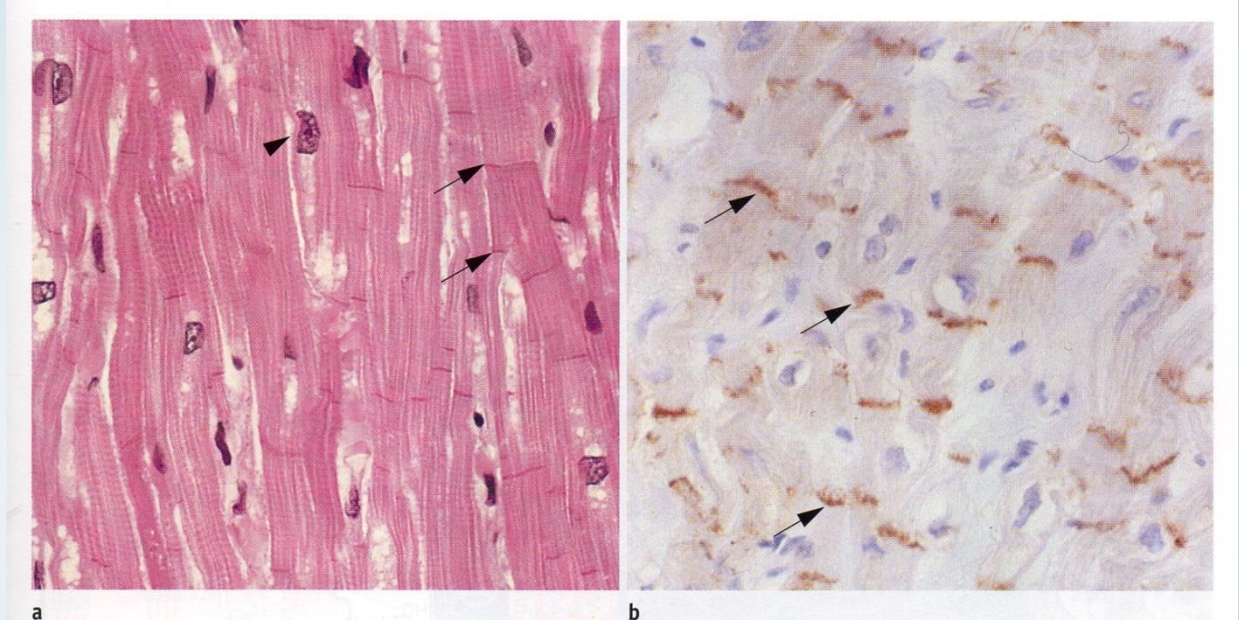
- Y-shaped
- 50-120 μm long and 15-20 μm thick
- interdigitating cell processes
- 1 nucleus, central
- 1-2 nucleoli
- eosinophilic cytoplasm
- striation
- connection: lines of Eberth

Cardiac muscle – Long section

Welsch



Röhlich



↗ lines of Eberth

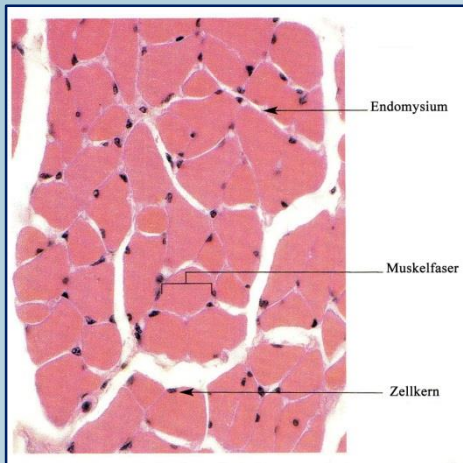
- a. HE-staining
- b. Connexin 43
(Immunohistochemistry)

Connection between the cardiac muscle cells: lines of Eberth
also called **intercalated discs** or glossy stripe

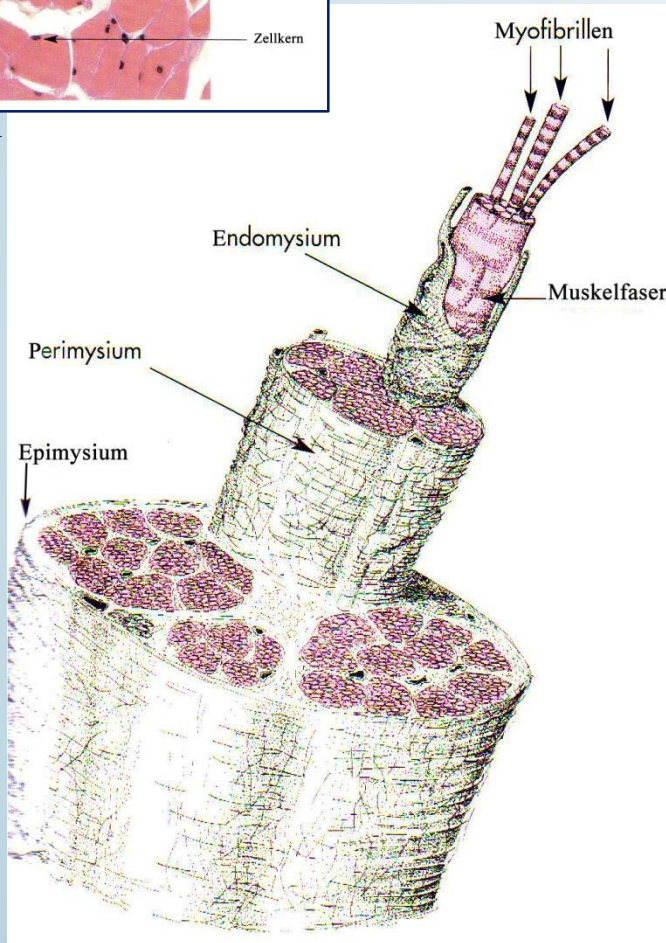
light microscopic: a transverse line

electron microscopic: stepped (transverse and longitudinal portions)

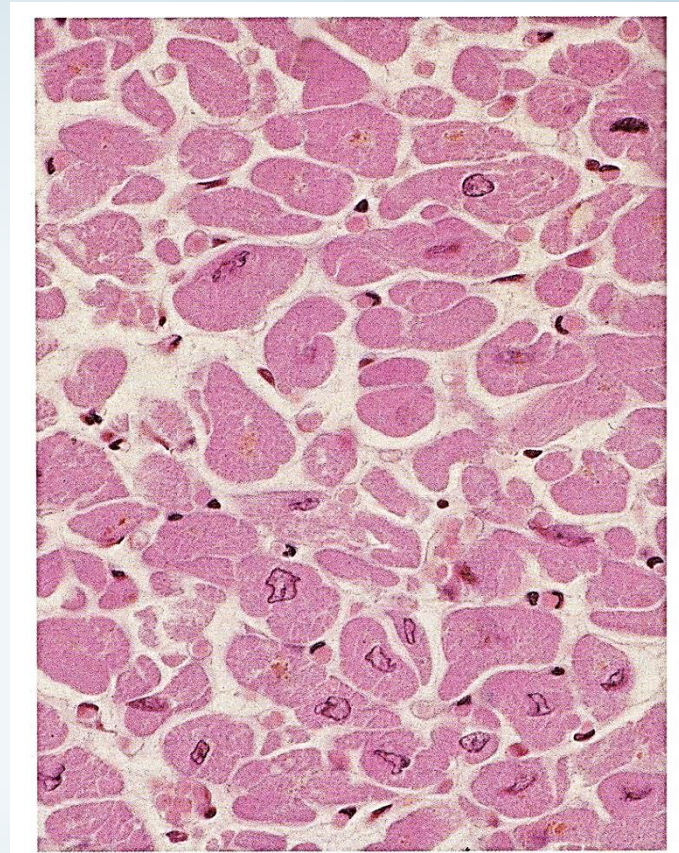
Cardiac muscle – cross section



Röhlich



Striated muscle

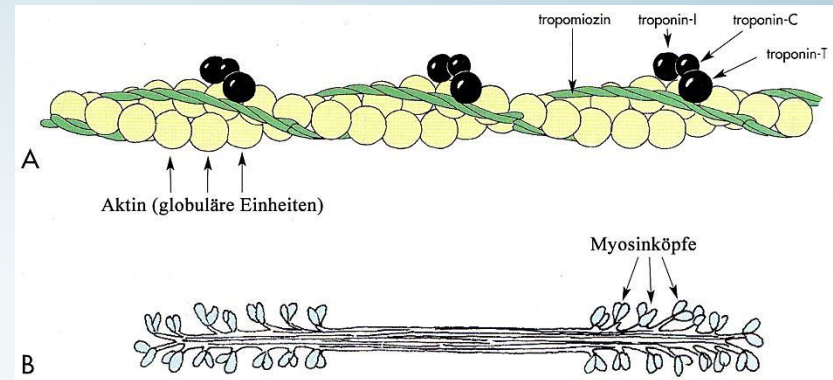
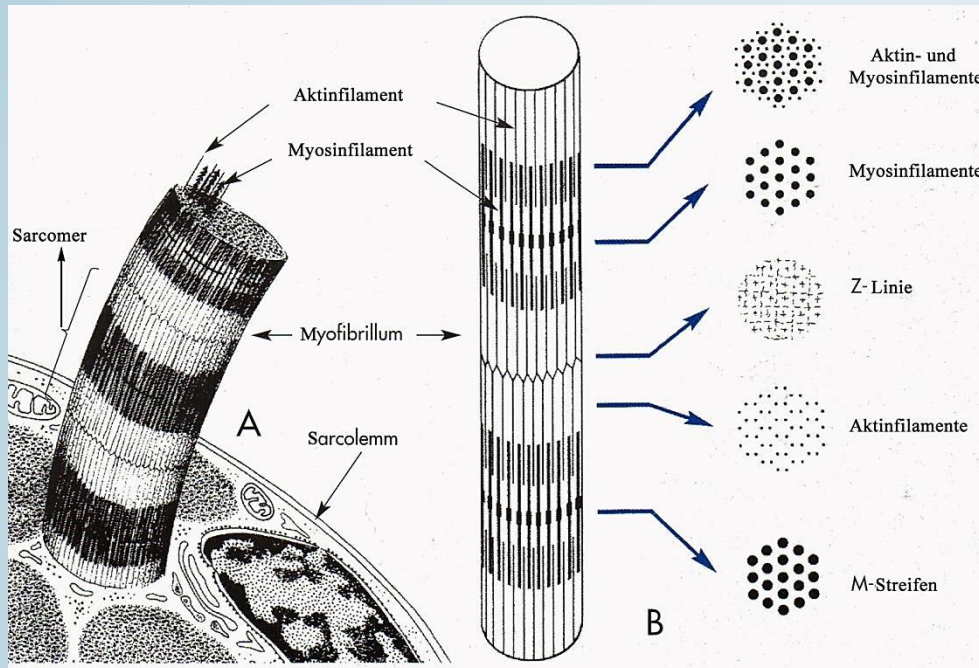


Röhlich

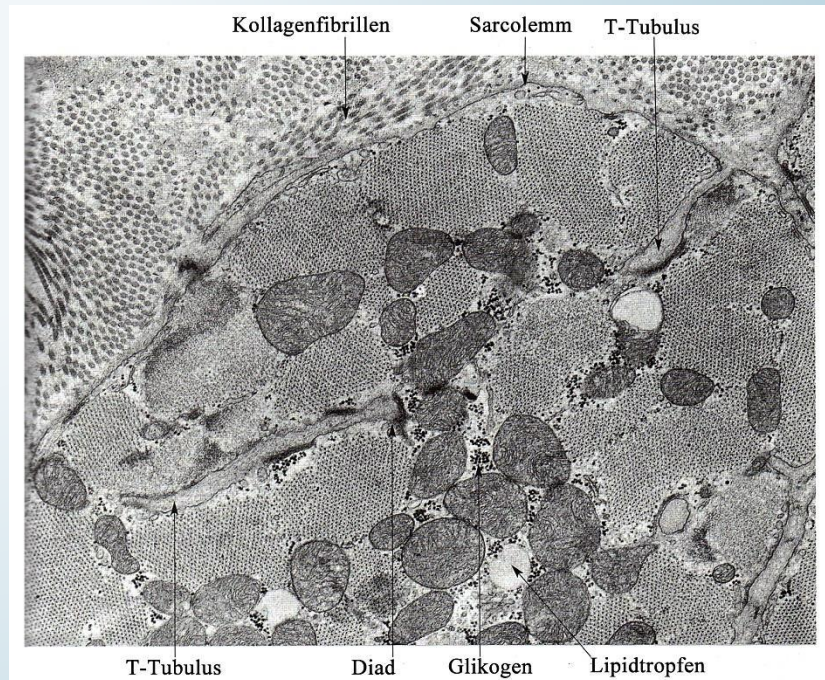
Cardiac muscle

- Here is no regular arrangement in bundles
- no proper fielding (no correct myofibrils)
 - central, oval nuclei
 - lot of connective tissue (nerves, vessels, fibrocytes)

Ultrastructure



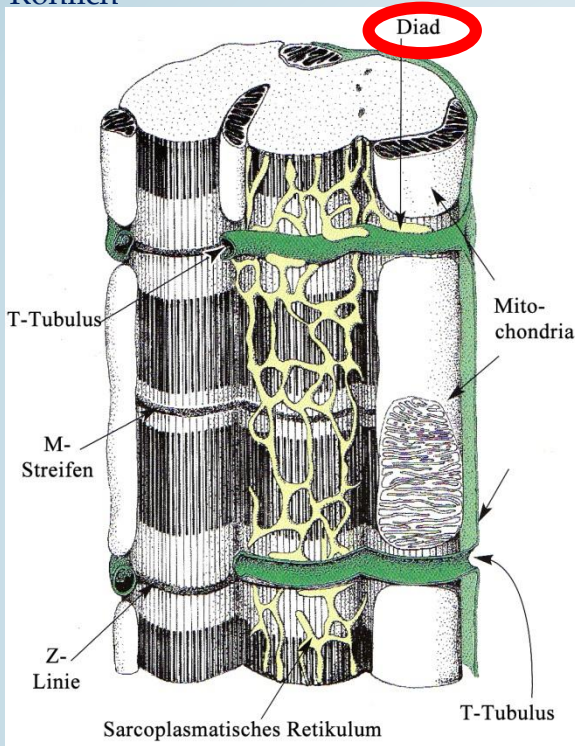
Röhlich



Part actin and myosin filaments form the contractile apparatus, where no proper myofibrils are present. The filaments build approx. 2.5 μm long sarcomeres. No regular fields in cross section.

Ultrastructure and Function

Röhlich



The contraction:

Calcium concentration of the cytosol is increased from two sources:

1, Extracellular calcium enters (Excitement on sarcolemm opens the calcium channel linked to dihydropyridine receptor)

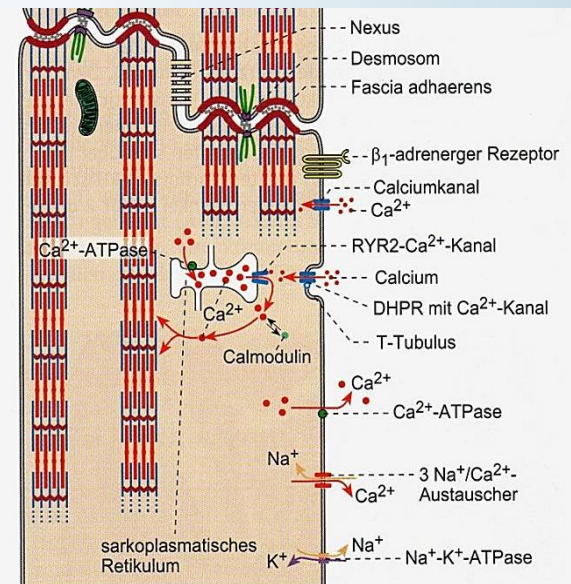
2, Intracellular calcium from the SR (Increased calcium level in the cytosol opens the Rianodin receptors of the SR)

The relaxation:

Calcium is stored in SR * (to calsequestrin bound) - Ca-ATPase

Ca-ATPase, Na/Ca exchanger, Na/K ATPase transport additional calcium into the extracellular space

*SR = TATS (Transversales-Axiales Tubulussystem)



Ultrastructure and Function

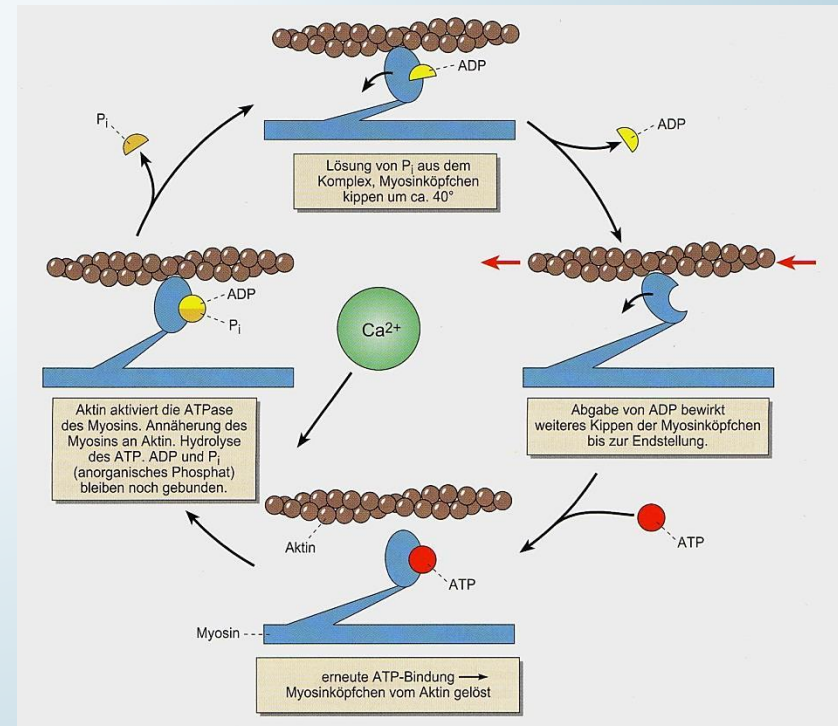
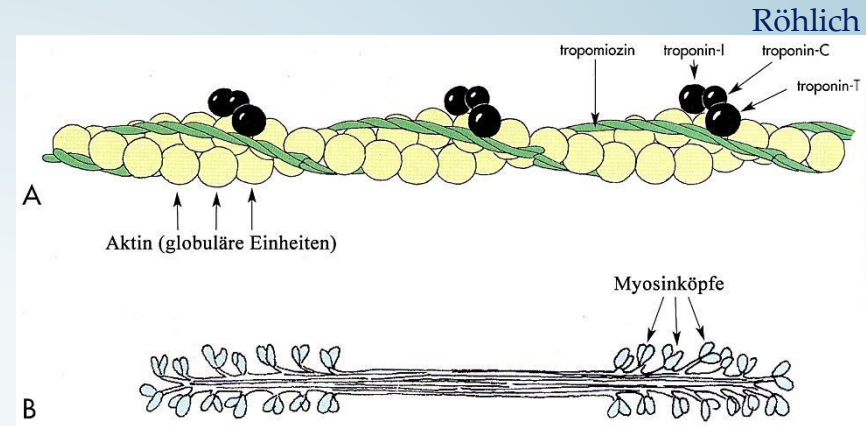
In resting phase, the myosin head is not or weakly bound to the actin filament.

Increases of the calcium level:

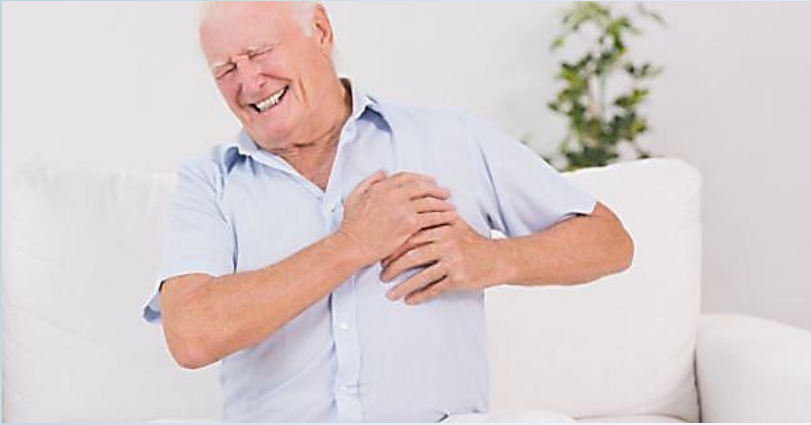- troponin C binds calcium
- changes to the conformation of troponin complex
- tropomyosin decreases much deeper between the actin-filaments
- ATPase from myosin is also activated
- Aktin – Myosin heads are connected
- ATPase activity increases on myosin
- Myosin droplet tilts in 2 steps

Troponin T: Binding to tropomyosin
Troponin I: Inhibitor of complex formation

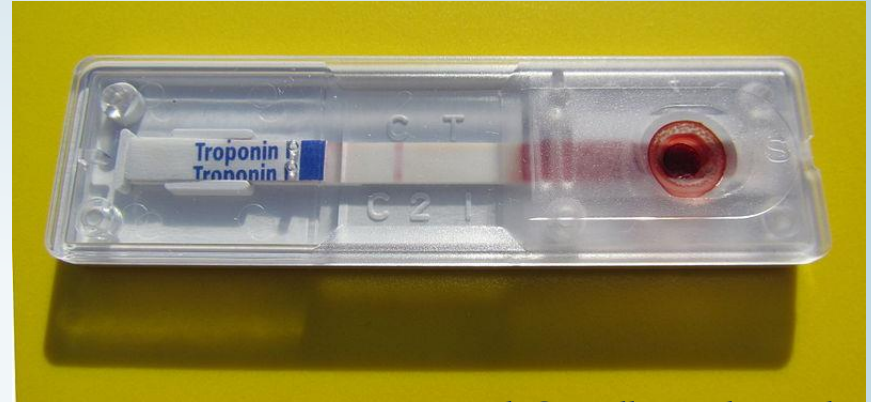Kreatinkinase (CK-MB): Phosphorilation of ADP



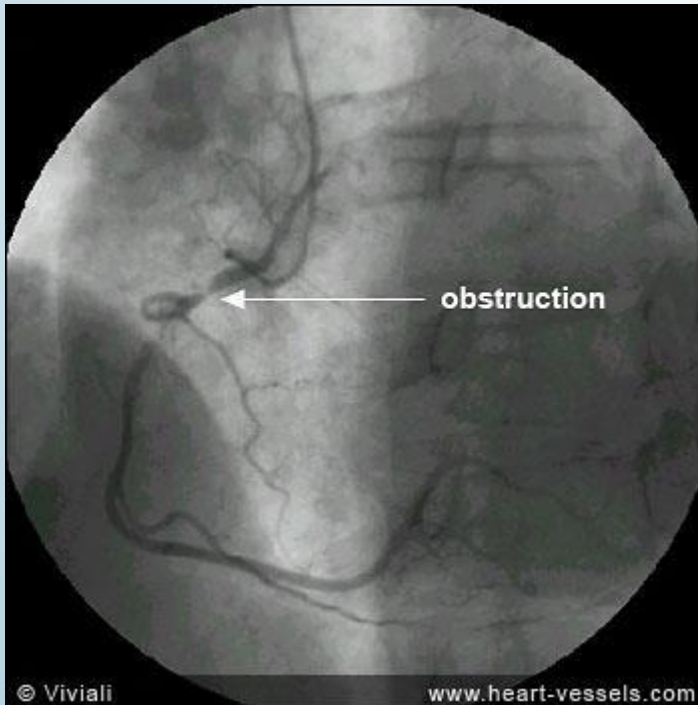
Where can these things be important later?



egeszsegtukor.hu

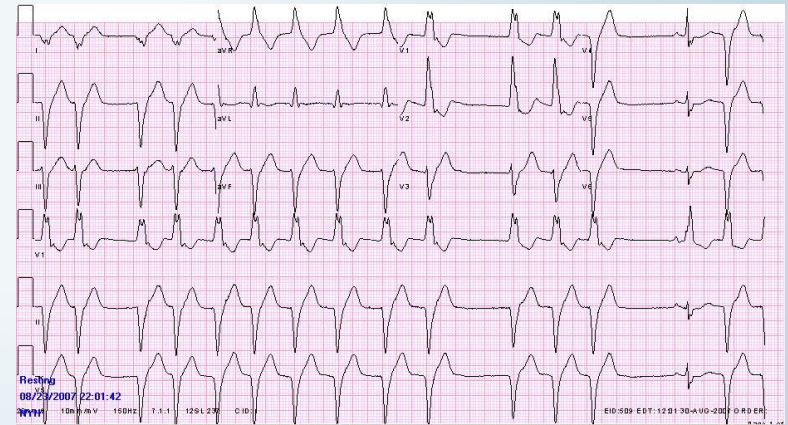


Frank C. Müller, Baden-Baden



© Viviali

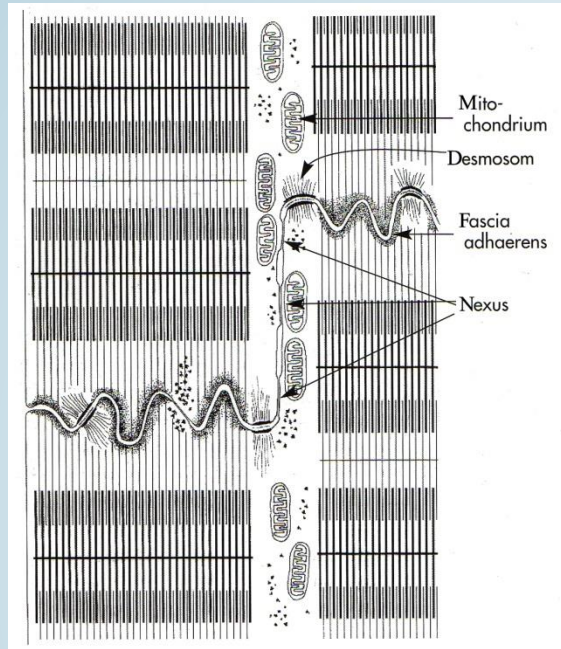
www.heart-vessels.com




clinicalcorrelations.org

Blood levels of
Troponin T !!!
CK - MB!

Lines of Eberth = glossy stripes = intercalated discs



Röhlich



Röhlich

Transvers parts:

Adherens fascias, desmosomes anchoring the I-strip "Z-line"; Cell adhesion with cadherins

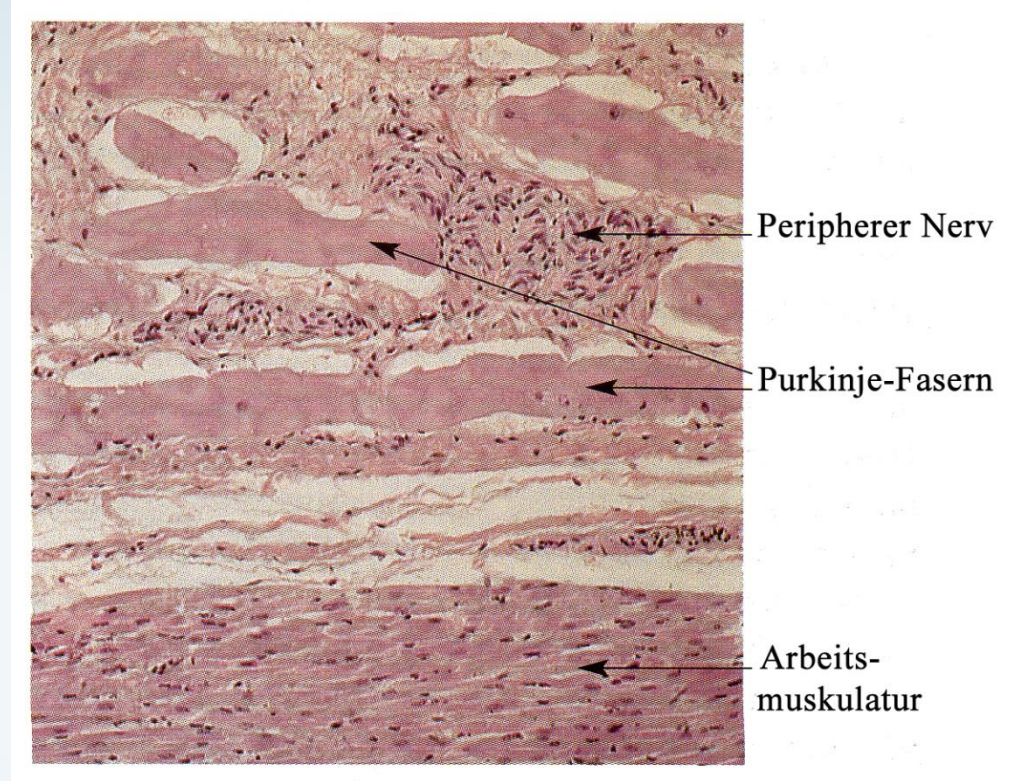
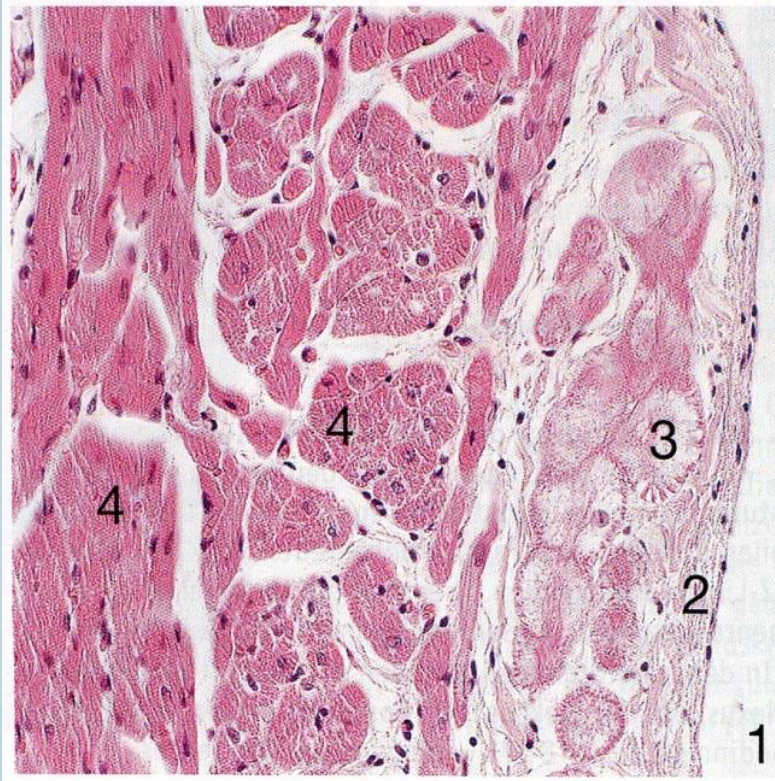
Longitudinal parts:

Nexus or Gap junctions (Connexin 43)
fast excitation conduction from cell to cell (functional Syncytium)

Cardiac conduction – Purkinje-fibres

Welsch

Röhlich

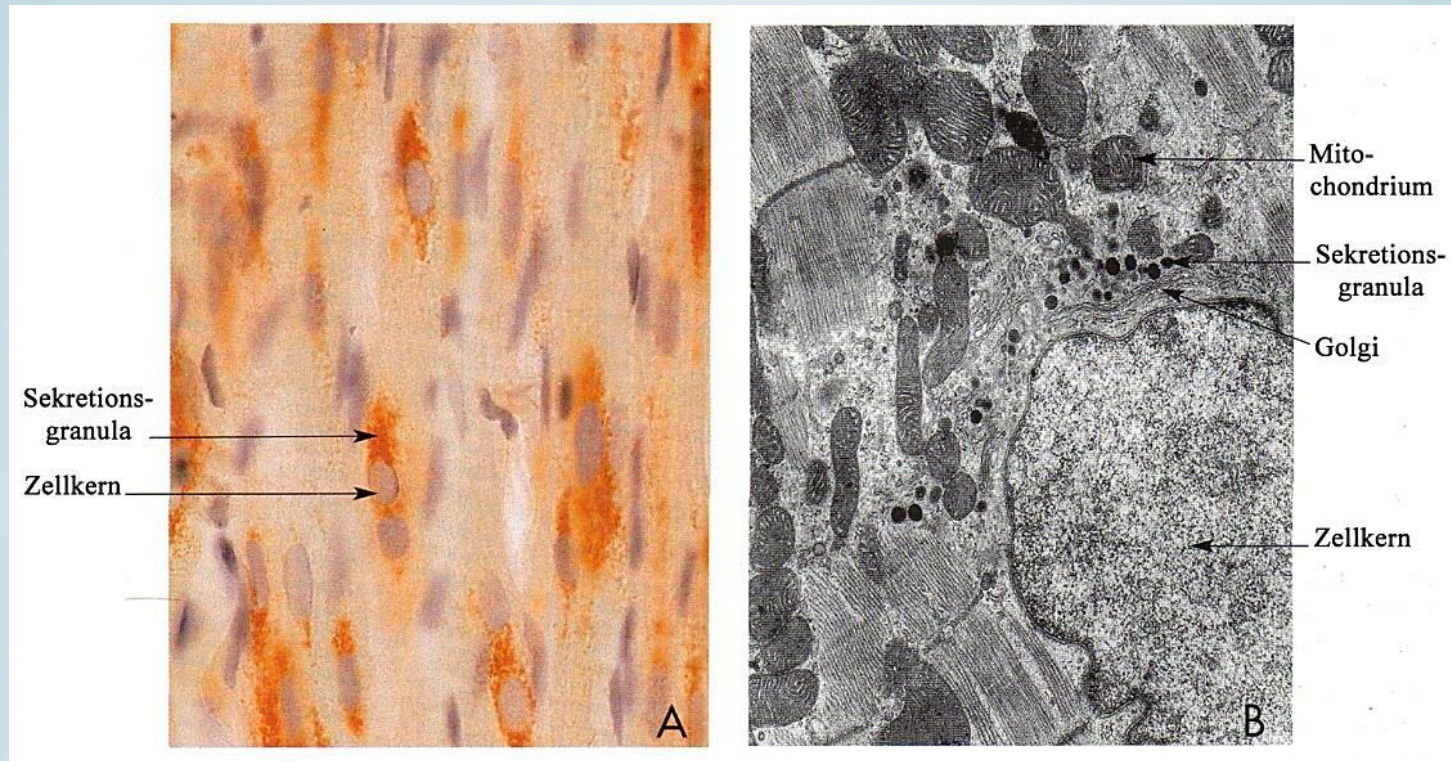


- 4 working muscles
- 3 Purkinje-fibres
- 2 endocardium
- 1 chamber

Purkinje-fibres: distal parts of the conducting system

- large (short but thick) cells
- polynuclear
- rich in glycogen
- no T-Tubuli
- lots of Gap junctions (Nexus)
- high Acetilcholine activity

Atrial Natriuretic Peptid (ANP)




Röhlich

Elongation of the atrial musculature (increased blood pressure) causes the production of ANP

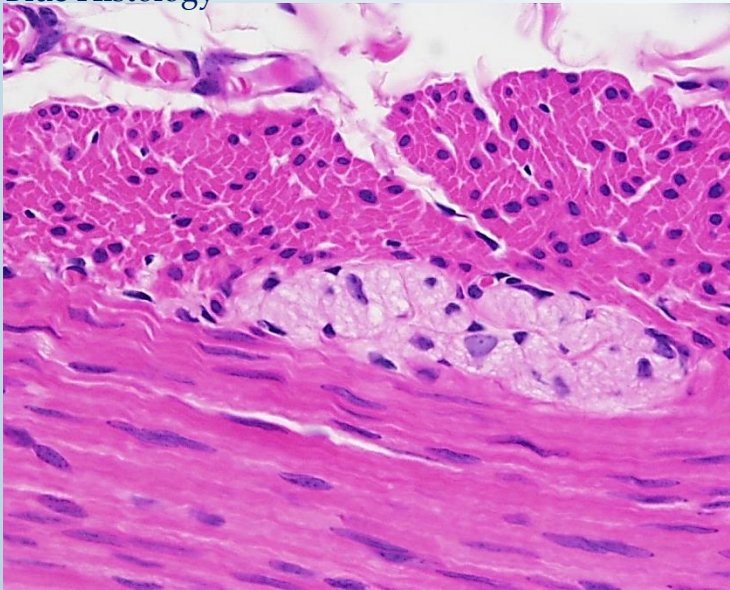
- Constriction of efferent kidney arterioles
- Increase of the filtration fraction
- Inhibition of sodium absorption (collecting tubules)
- Vasodilatation in the ventricles: BNP

Smooth muscle tissue



Röhlich

Blue Histology



functional unit: smooth muscle cell

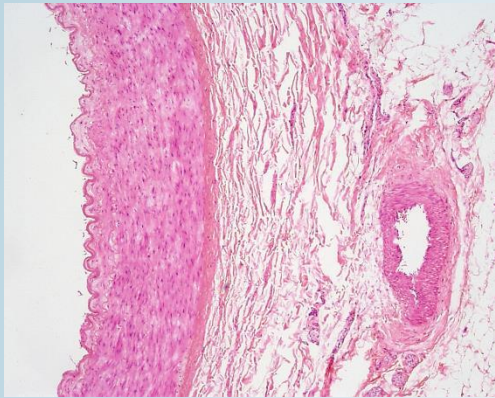
- Basal lamina
- Mononuclear, nucleus rod shaped, central
- Cell in the middle approx. 8 μm thick and about 15 - 500 μm long
- Cytoplasm: intensive eosinophilic
- No striation: smooth!
- low energy requirement
- slow but permanent contraction
- great power effect
- matrix production (Myofibroblasts)

Receptors also here for PSY (M_{1-4}) and SY ($\alpha_1, \alpha_2, \beta_1, \beta_2$) ...see pharmacology!
vessel wall: NO-Synthase

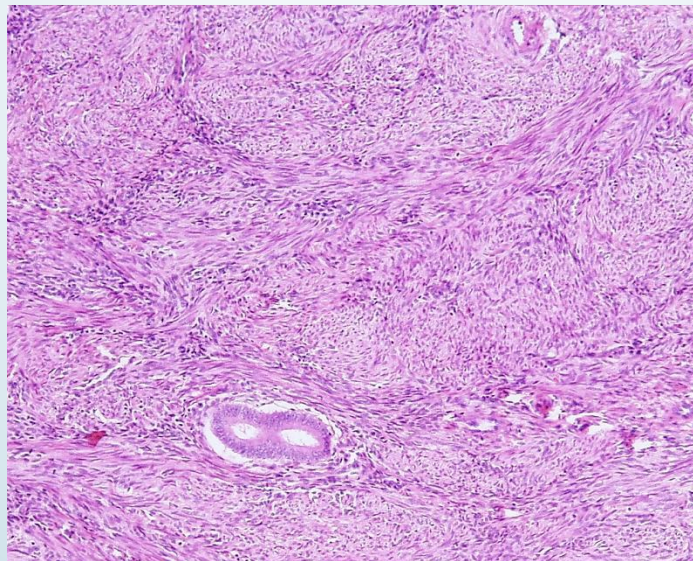
Occurrence

Mostly in hollow organs (gastrointestinal, respiratory, genitals, vessels) but also in the eyeball and in the skin.

Can be in lamina (crossing each other) or in bundles or layers organized.

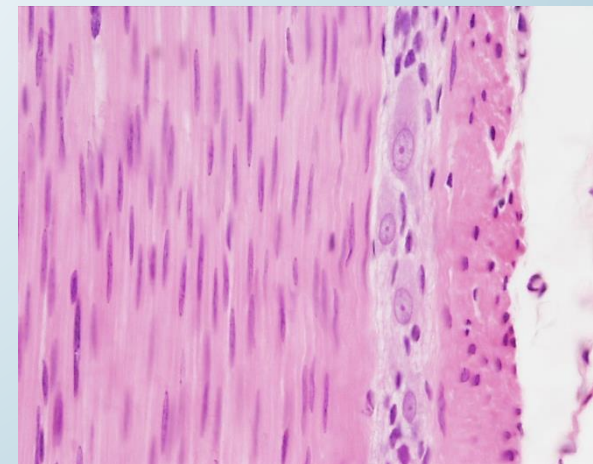


vessel wall

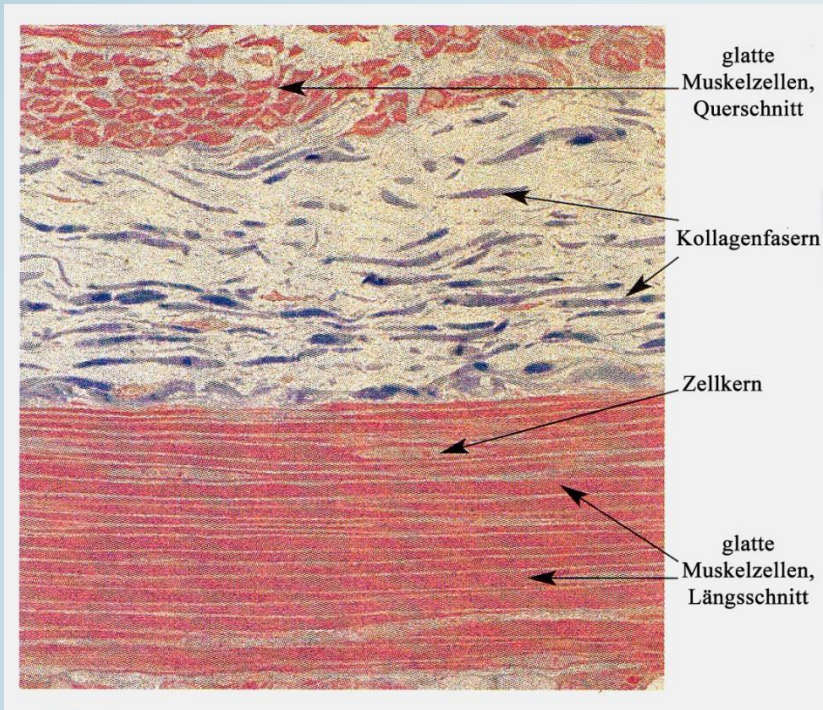


uterus

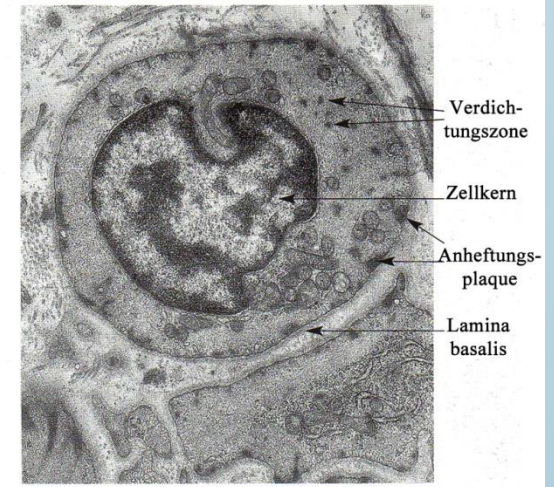
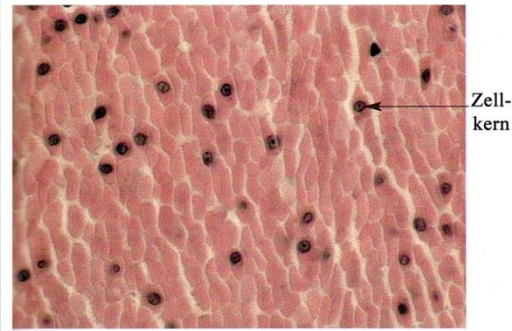
intestinal wall



Longitudinal and cross section

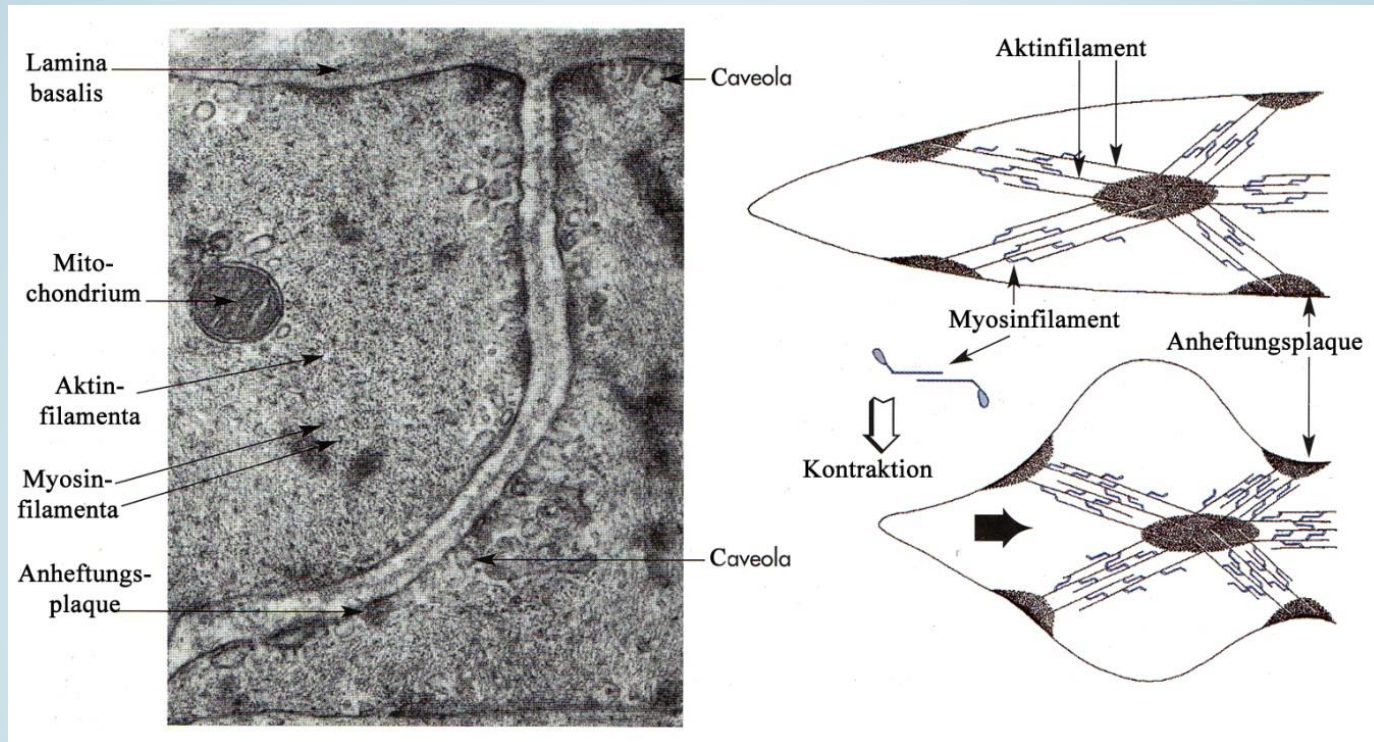


Röhlich



Ultrastructure - contractile apparatus

Röhlich



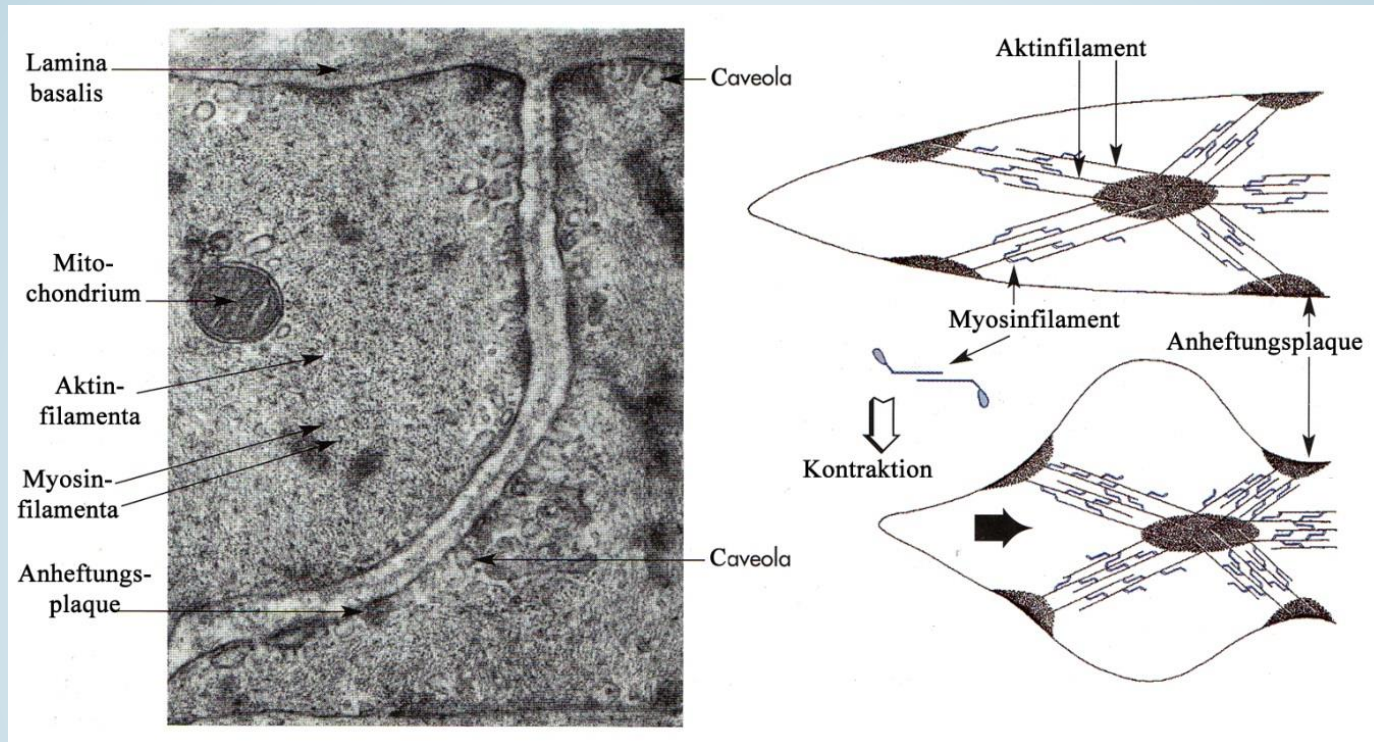
Myosin and actin filaments do not form myofibrils.

To a myosinfilament there are 12-14 actinfilamenta. Actinfilamenta are on the so-called attachment plaques of sarcolemma (subsarcolemmal plaque) or at the compression zones ("dense bodies" anchored). Both contain α -actinin.

The course of the filament is neither parallel with nor perpendicular to the longitudinal axis of the cells.

Ultrastructure - contractile apparatus

Röhlich



The attachment plaques or the compression zones actually correspond to the Z-discs.

SR is present as calcium storage, but missing the T-tubules. Instead of, you have learned the caveolae of the sarcolemma.

Contraction - relaxation

The contraction:

calcium-related (extracellular and SR)

- Elektromech.: Action potentials act on **voltage-dependent Ca-channels**
- Pharmakomech.: Transmitter, drugs, etc. ∴ **receptor-controlled Ca-channels**
- Mechanical strain: **strain-dependent Ca-channels**

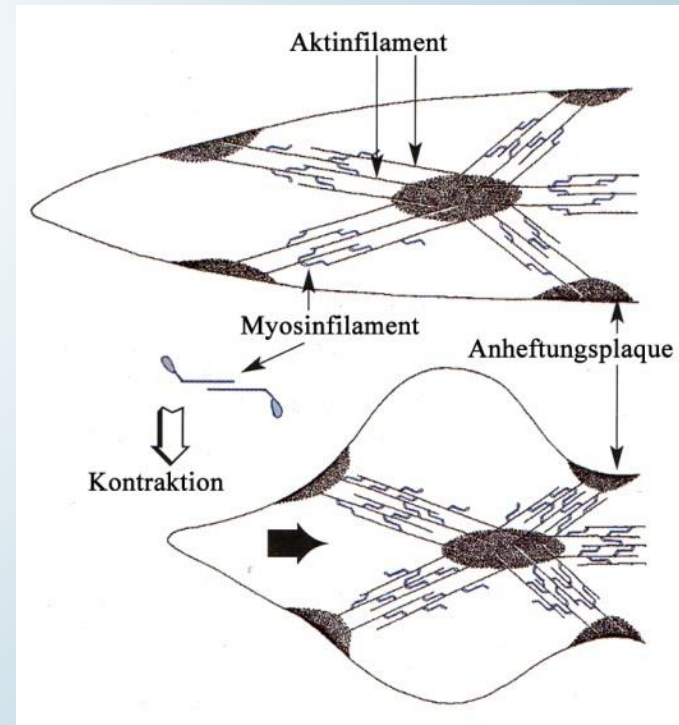
There is no troponin-tropomyosin complex:

- Calcium binding in calcium calmodulin complex
- Activation of „myosin light chain kinase (MLCK)
- ATP is cleaved and myosin light chain phosphorylated
- so-called transverse bridge between myosin and actin arises

The relaxation: Calcium is pumped out of the cell or into SR withdrawn (Ca-ATPase, Ca/Na exchanger)

Activation of myosin light chain phosphatase (MLCP) and dissociation of the calcium-calmodulin complex

Röhlich



Contraction - relaxation

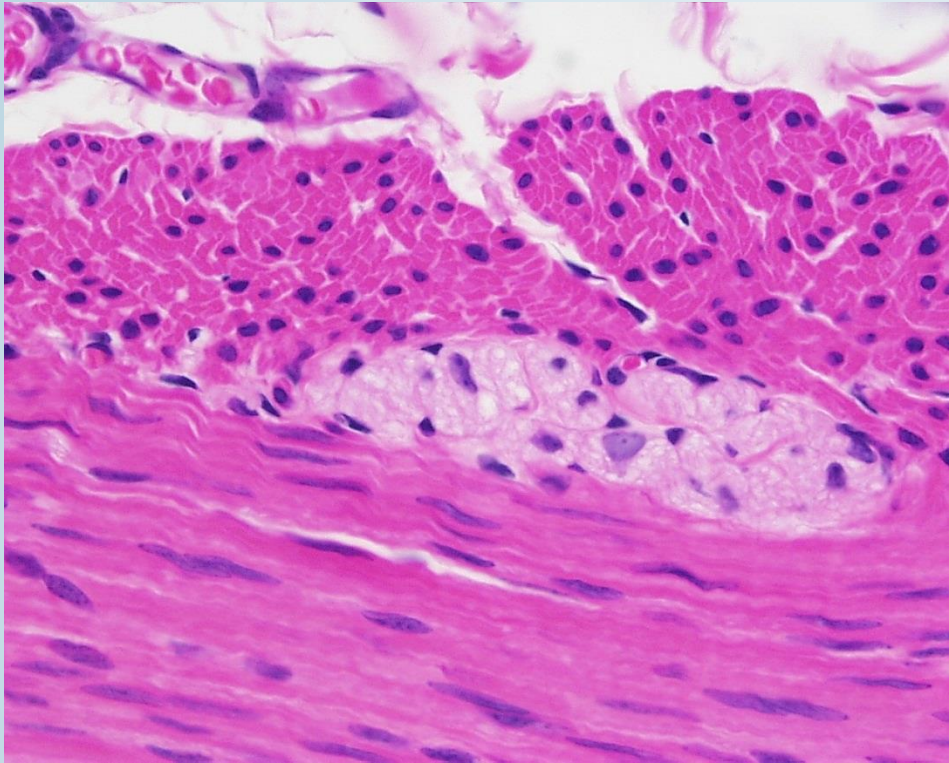
Single-unit type: so-called pacemaker cells are depolarized excitement spreads through Gap junctions (Nexus) the cells thus form a functional syncytium. "Myogenic tone"

e.g. Vessels, GI tract, urogenital system

Multi-unit type: vegetative nerve fibers innervate with the help of passing varicosities ("en passant") "Neurogenic tone"

e.g. Eye, skin, urogenital system, respiratory system, vessels

Innervation

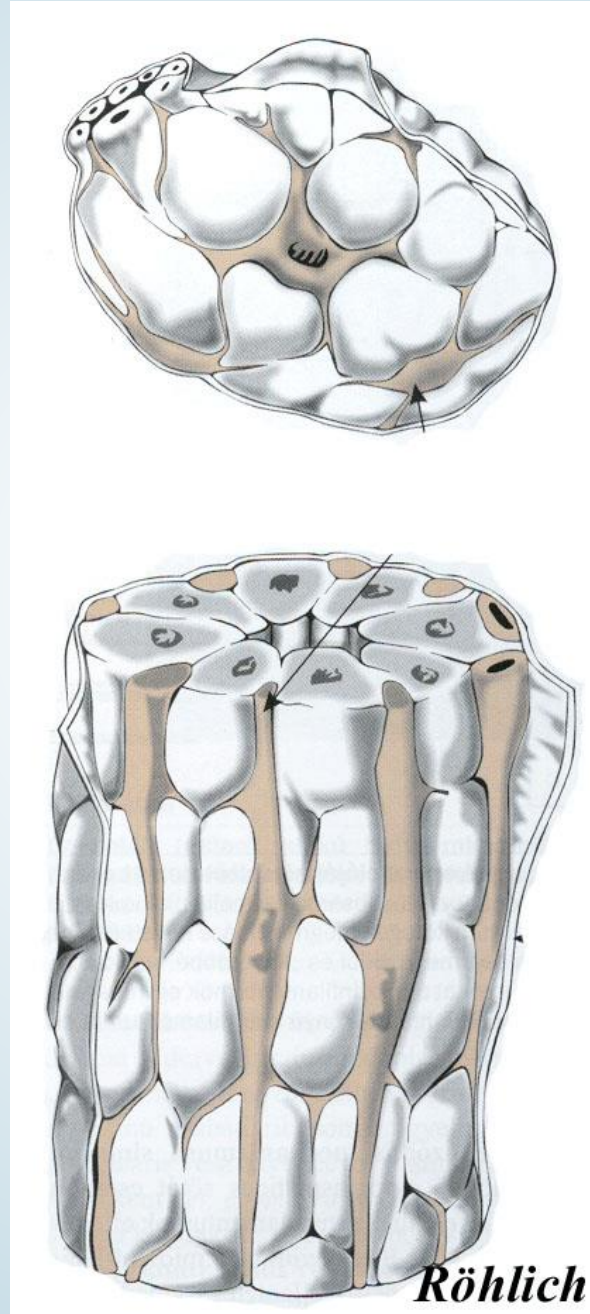


a ganglion intramural in the colon
myentericus Plexus of Auerbachii

Blue Histology

No voluntary innervation: autonomous (PSY un SY)
Influence: other substances, medicines, mechanical stretching

Cells with similar function

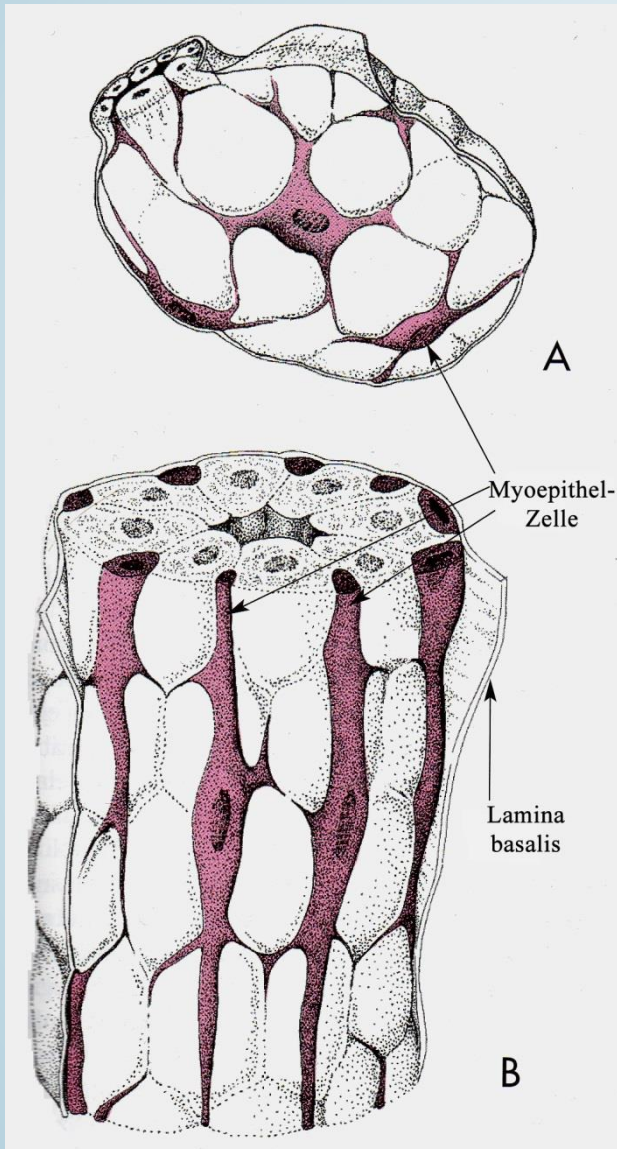


Fibrocytes, Myofibrocytes

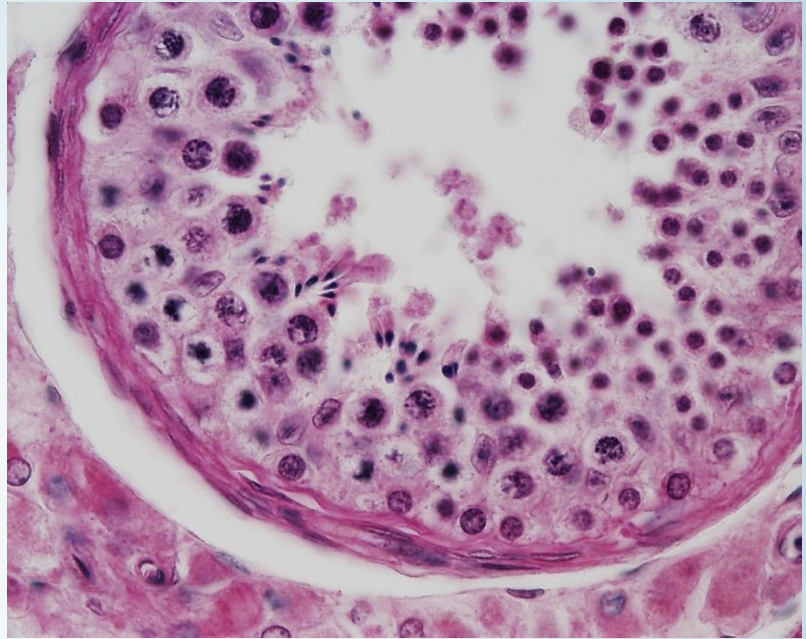Myoepithelial cells

- Around Acini
- Iris

Myoepithelcells

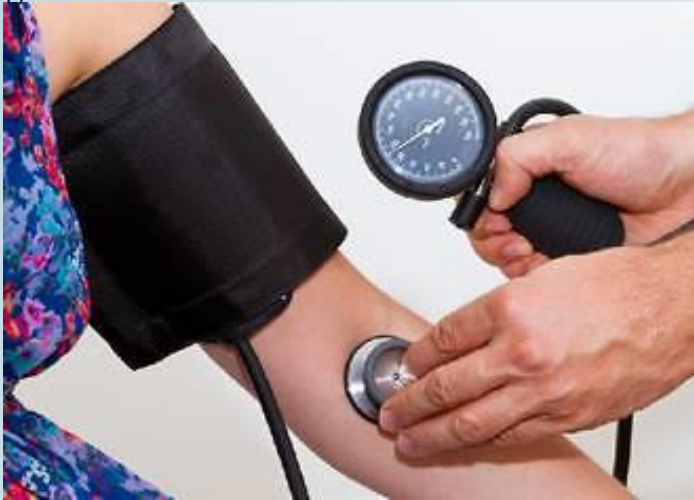

Röhlich



Blue Histology

gesundheitsstadt-berlin.de



makeup.at



topnews.in



medicamon.de

Literatur

after: Dr. Alpár and Dr. Baksa

Röhlich: Szövettan (SOTE Képzéskutató 1999.)

Welsch: Lehrbuch Histologie (Urban & Fischer 2010.)

www.anatomia.uw.hu

www.clinicalcorrelations.org

www.de.wikipedia.org

www.egeszsegtukor.hu

www.gesundheitsstadt-berlin.de

www.google.hu

www.heart-vessels.com

www.lab.anhb.uwa.edu.au (Blue Histology)

www.makeup.at

www.medicamon.de

www.topnews.in

Frank C. Müller (www.de.wikipedia.org)