

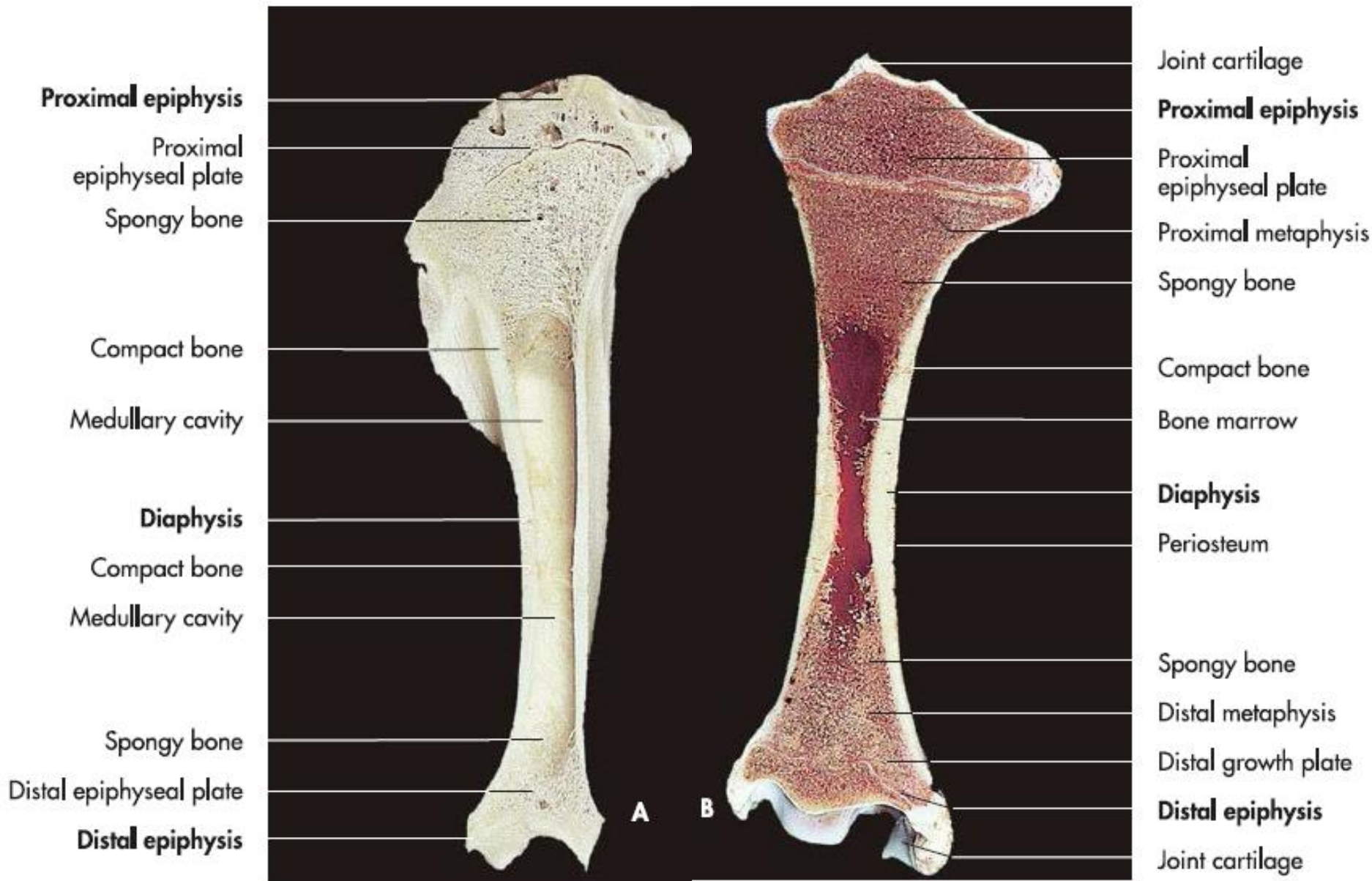## **Forms of bony tissues**

- Bones differ greatly in form, size and strength, not only between species but also within the same individual
- They can be grouped according to common structural characteristics. These are as follows:
  1. Long bones
  2. Short bones
  3. Flat bones
  4. Irregular bones
  5. Pneumatic bones: Some bones of the skull are flat bones surrounding cavities of air

\*Bones of the organs are not related to the locomotor system such bones are found in the penis of male cats and dogs or in the bovine heart.

# Long bones

- They are characterized by:
  1. **A shaft or diaphysis**, formed from
    - A. A thick, outer layer of **compact bone**
    - B. An inner **medullary cavity**
  2. Long bones have two ends
    - A. **Proximal epiphysis**
    - B. **Distal epiphysis**
  3. Both extremities contain **spongy bone contain** delicate pores
  4. Example upper arm (humerus, femor, tibia), or the metacarpal bones
  5. Bone surface is constructed of compact lamellae which form the basis of the compact substance of bone.
  6. Bones are sheathed on the inside and outside surfaces by
    - A. **Endosteum**
    - B. **Periosteum**
  7. The vascularisation of bone: Nutrient arteries branch off from the larger limb arteries and enter the long bones through openings (foramina nutritia) in the diaphysis.



**Proximal epiphysis**

- Proximal epiphyseal plate
- Spongy bone

**Compact bone**

- Medullary cavity

**Diaphysis**

- Compact bone
- Medullary cavity

**Spongy bone**

- Distal epiphyseal plate
- Distal epiphysis**

Joint cartilage

**Proximal epiphysis**

- Proximal epiphyseal plate
- Proximal metaphysis
- Spongy bone

**Compact bone**

- Bone marrow

**Diaphysis**

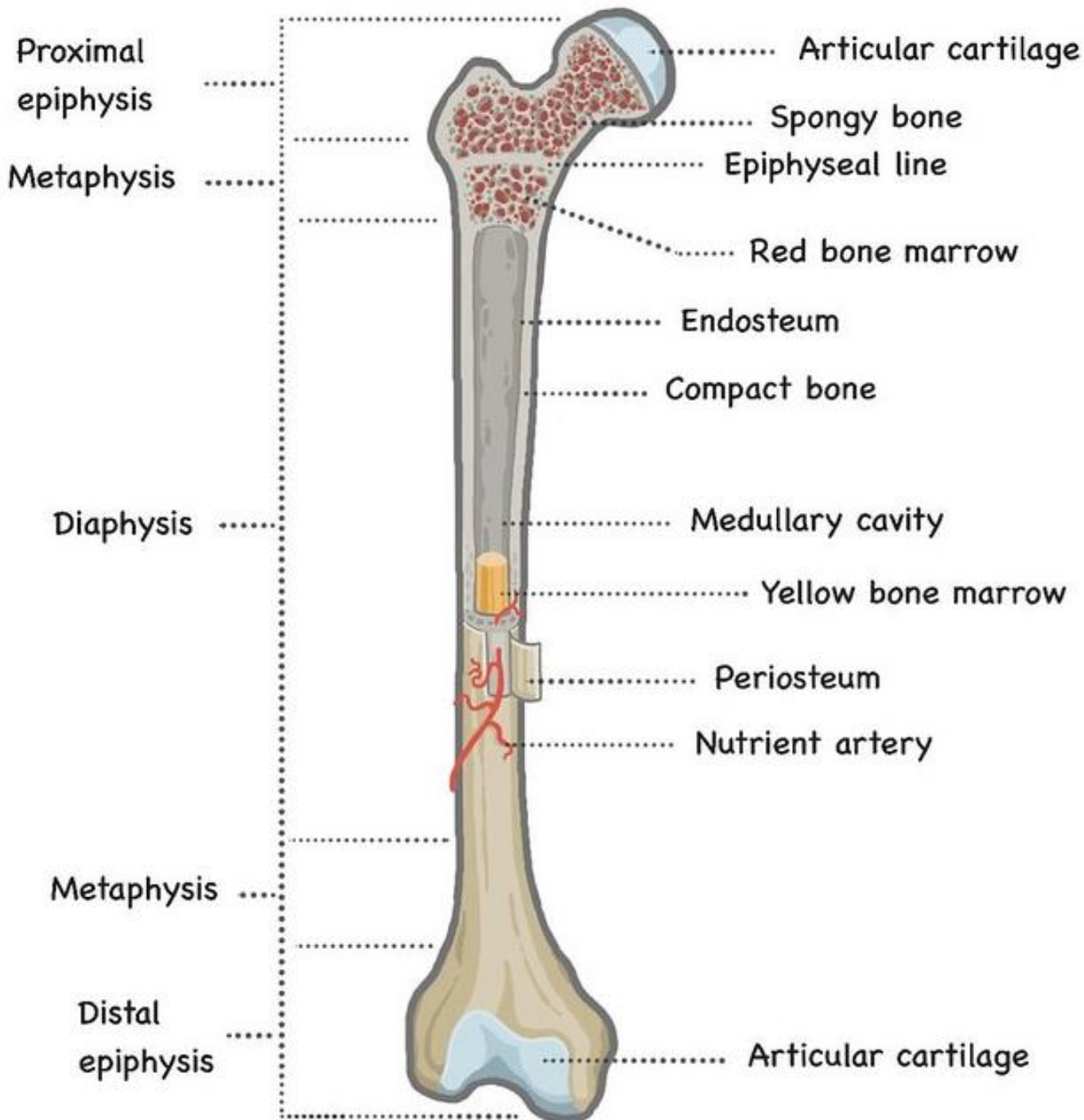
- Periosteum

**Spongy bone**

- Distal metaphysis
- Distal growth plate

**Distal epiphysis**

- Joint cartilage



**Schematic showing the structure of the long bone**

## **The endosteum:**

1. Lines the medullary cavity and covers the spongiosa.
2. Creating a border between bone or spongiosa and bone marrow.
3. It consists of a single layer of flattened, inactive osteoprogenitor.
4. It can differentiate into either bone-forming cells (osteoblasts) or (osteoclasts).

## **The periosteum:**

1. It covers the external surface of bone, but it is absent from the articular surfaces and where tendons and ligaments attach.
2. It is necessary for the blood supply, growth, regeneration, and fracture repair of bones,
3. It is also transfer of muscle power to the bone.
4. It is composed of two layers:
  - A. inner cellular, osteogenic layer (stratum osteogenicum).
  - B. outer protective fibrous layer (stratum fibrosum).

\*The stratum osteogenicum lies directly on the bone and produces bone tissue.

\*A great number of sensory nerve fibers as well as a network of blood and lymphatic vessels supplying the bone are enclosed in this layer.

\*This layer also contains progenitor cells.

# Chondrogenesis (cartilage formation)

- Is the process by which cartilage is formed from condensed mesenchyme tissue, which differentiates into chondrocytes and begins secreting the molecules that form the extracellular matrix

# Osteogenesis (bone formation)

- During foetal development, a precursor skeleton of cartilage is formed, providing support and shape (primordial skeleton) for the growing foetus.
- Until ossification, this primordial skeleton undergoes quick progressions of mitotic division.
- Eventually determining the growth and form of the entire organism
- The cartilage is slowly resorbed and eventually replaced by bone. This process is **chondral or indirect ossification**.
- The replacement of cartilage through bone begins during the middle foetal period at sites referred to as **primary ossification centers**.
- In some bones this process is completed only when the animal has reached physical maturation.

# Ossification

- Bone can form directly from mesenchymal tissue without a cartilage precursor; this process is referred to as **intramembranous or direct ossification**. There are two forms:

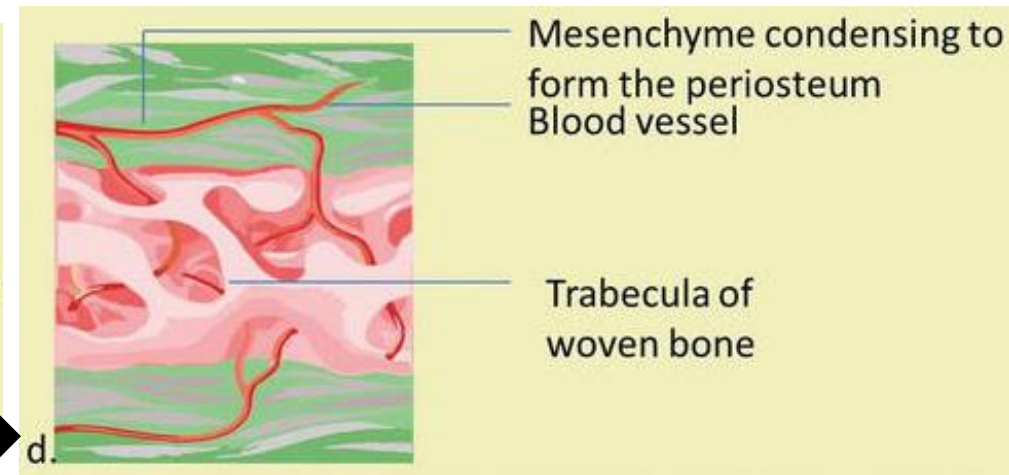
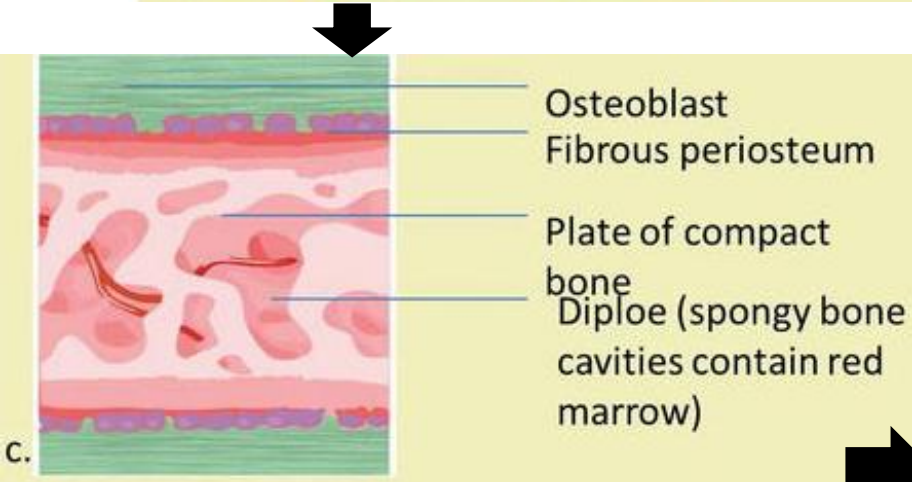
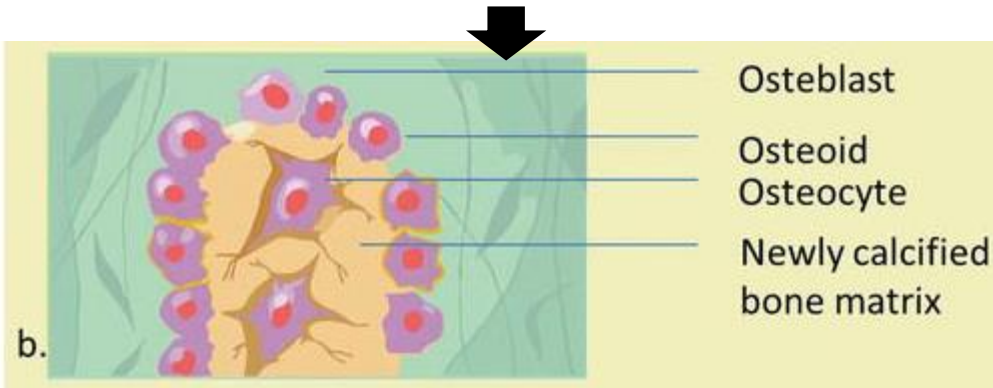
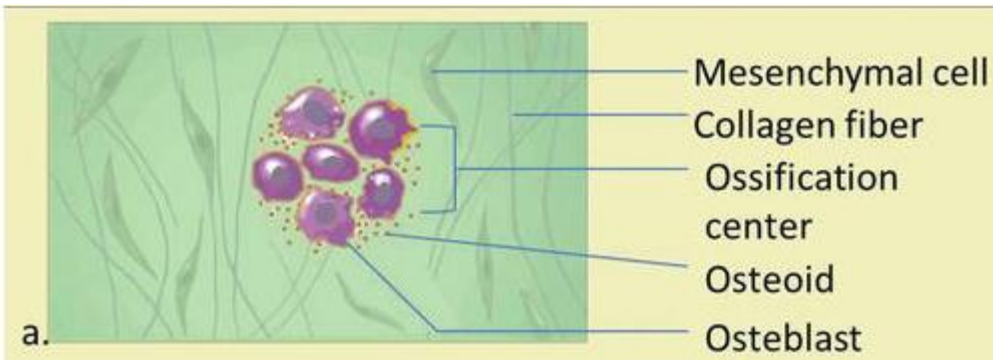
- 1. Intramembranous or direct ossification**

- 2. Chondral or indirect ossification**, divided into:
  - A. Perichondral ossification
  - B. Endochondral ossification

- 1. Intramembranous ossification**

- Developing through intramembranous ossification are referred to as “membrane bones”.
- Dermal bones are membrane bones arising directly from the mesenchyme tissues of the skin (i.e. most of the skull bones).
- Intramembranous bone development occurs when mesenchyme cells differentiate directly into cells responsible for producing bone. These cells are various and appear in many different forms
- Non differentiated mesenchyme cells differentiate into osteoblast precursor cells, which develop into osteoblasts, cells that build bone
- During ossification, the osteoblasts produce an organic, mineral-free matrix called the osteoid, which completely encloses the cells.
- The osteoid is mainly composed of type-I collagen fibers (95%).
- The collagen fibers act as scaffolding for the successive appositional deposition of inorganic calcium and phosphate compounds.
- As the mineralization continues, the osteoblasts become isolated in a growing field of calcified bone tissue and differentiate into osteocytes

## The stage of intramembranous ossification





## 2. Chondral or indirect ossification

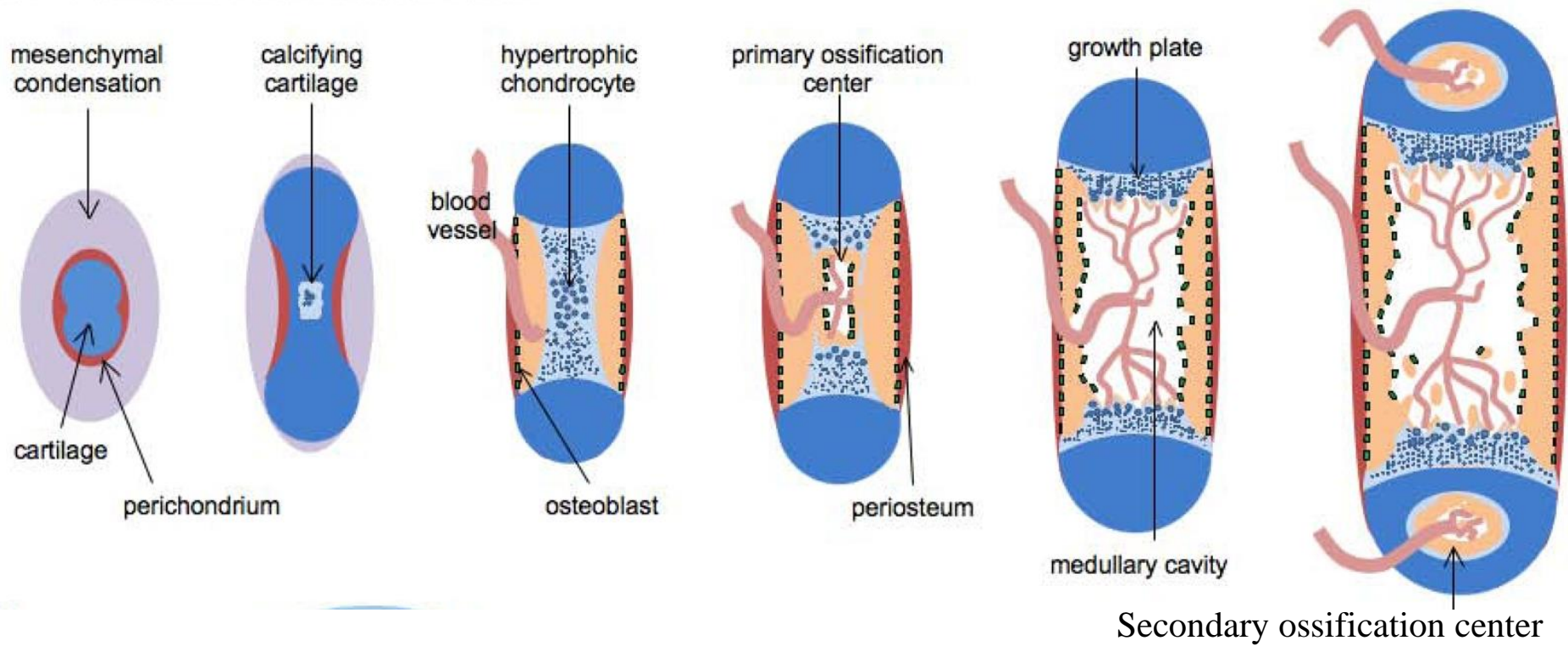
- It involves hyaline cartilage, provides the basis for the longitudinal growth of bone.
- The primordial skeleton consists of hyaline cartilage, until chondral ossification begins through the gradual resorption of the cartilage and its replacement with permanent bone.
- Example: vertebrae, the ribs, the sternum, the limbs and the base of the skull are formed. This process of building new bone from a hyaline cartilage precursor is the chondral osteogenesis.
- Based on the location of mineralization, it can be divided into: **Perichondral ossification** and **Endochondral ossification**. Both types of ossification play an essential role in the formation of long bones where only endochondral ossification takes place in short bones.

### A. Perichondral ossification

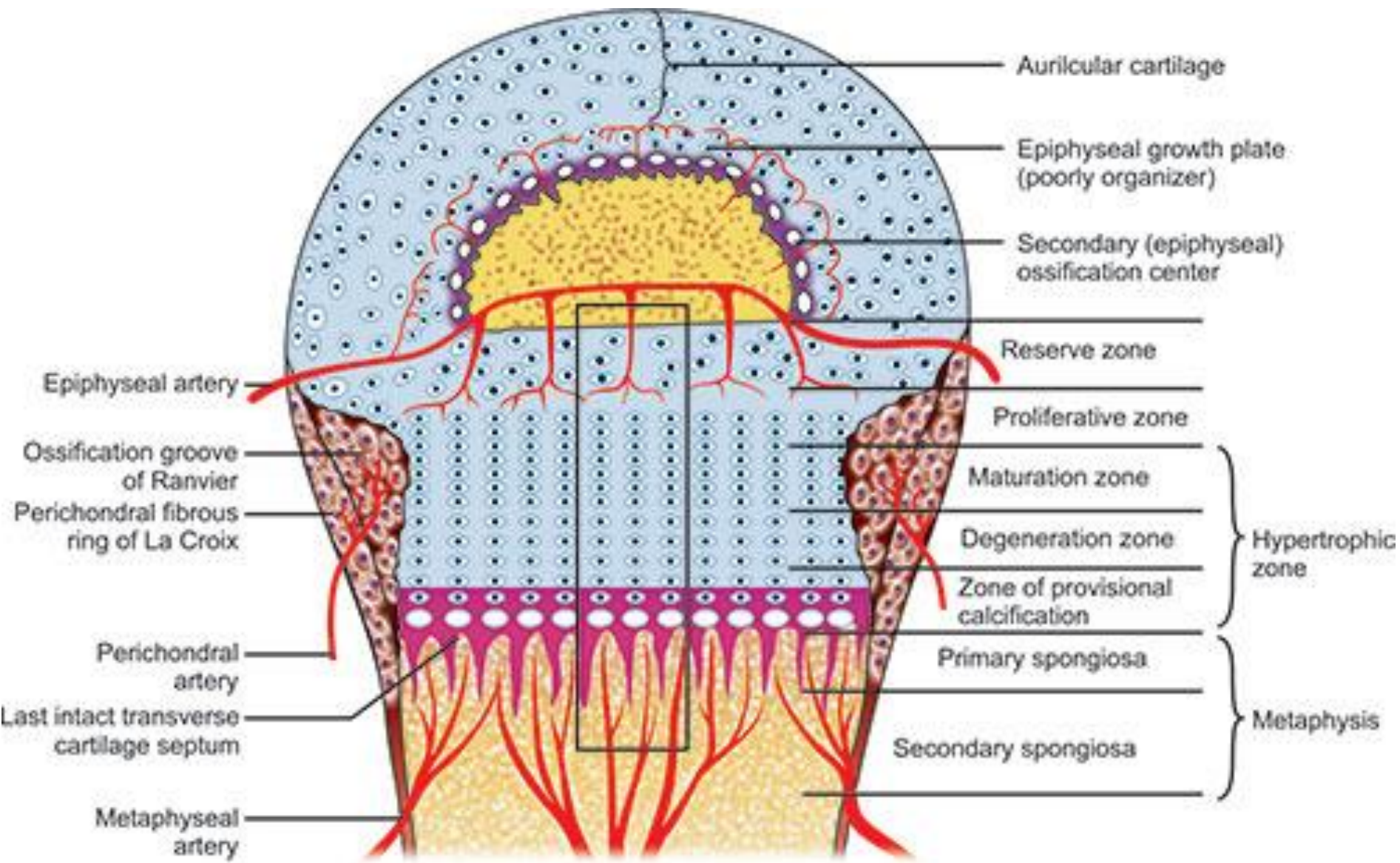
- It is similar to intramembranous ossification
- Osteoid is formed and slowly mineralised.
- Osteoprogenitor cells are located in the perichondrium and differentiate into osteoblasts (primary ossification).
- This transformation of soft tissue into bony tissue begins in the middle of the diaphysis and results in the formation of a bony sheath, the periosteal collar.
- The ossification of the perichondrium progresses towards each bone extremity.
- The perichondrium becomes the periosteum.
- Perichondral ossification leads to the development of the periosteum of the long bones.
- The continuous process of bone resorption and replacement of the matrix results in the development of the primary medullary cavity
- The bone marrow located in the medullar cavities of both epiphyses and between the spongiosa trabeculae remains lifelong a hemopoietic organ
- In adults the red bone marrow of the diaphysis is gradually replaced by fat.

## **B. Endochondral ossification**

- The two metaphyses border on each end of the bone an area of distinct endochondral ossification called the epiphyseal growth plates
- The epiphyseal plates are responsible for the longitudinal growth of a bone.
- In the area of the metaphysis, inhibits radial growth of the cartilage.
- The chondrocytes proliferate through mitotic division and hypertrophy.
- It is basis for the longitudinal growth of cartilage, it is necessary for bone growth.
- The endochondral ossification of the metaphyseal cartilage occurs in several zones
- The chondrocytes place alongside to the epiphyseal plates are diffusely located throughout the hyaline cartilage and do not divide (zone of resting chondrocytes).
- In the direction of the medullary cavity, is the wide zone of proliferation, where the chondrocytes actively divide.
- Mechanical influence of the periosteal collar forces the maturing chondrocytes in the following zone.
- The chondrocytes begin to degenerate. This is a process characterized by an increase in volume due to water uptake and the calcification of the intercellular substance (zone of hypertrophied chondrocytes).
- In the final zone, the intercellular matrix becomes saturated with minerals and ossification is complete (zone of calcification).
- Eventually, the young woven bone is replaced by mature lamellar bone



**Schematic showing endochondral ossification**



## Bone cells, their function, and locations

Cell type	Function	Location
Osteogenic cells	Develop in osteoblast	Deep layers of the periosteum and the marrow
Osteoblast	Bone formation	Growing portions of bone, including periosteum and endosteum
Osteocytes	Maintain mineral concentration of matrix	Entrapped in matrix
Osteoclasts	Bone resorption	Bone surfaces and at sites of old, injured, or unneeded bone

# Types of bone tissues

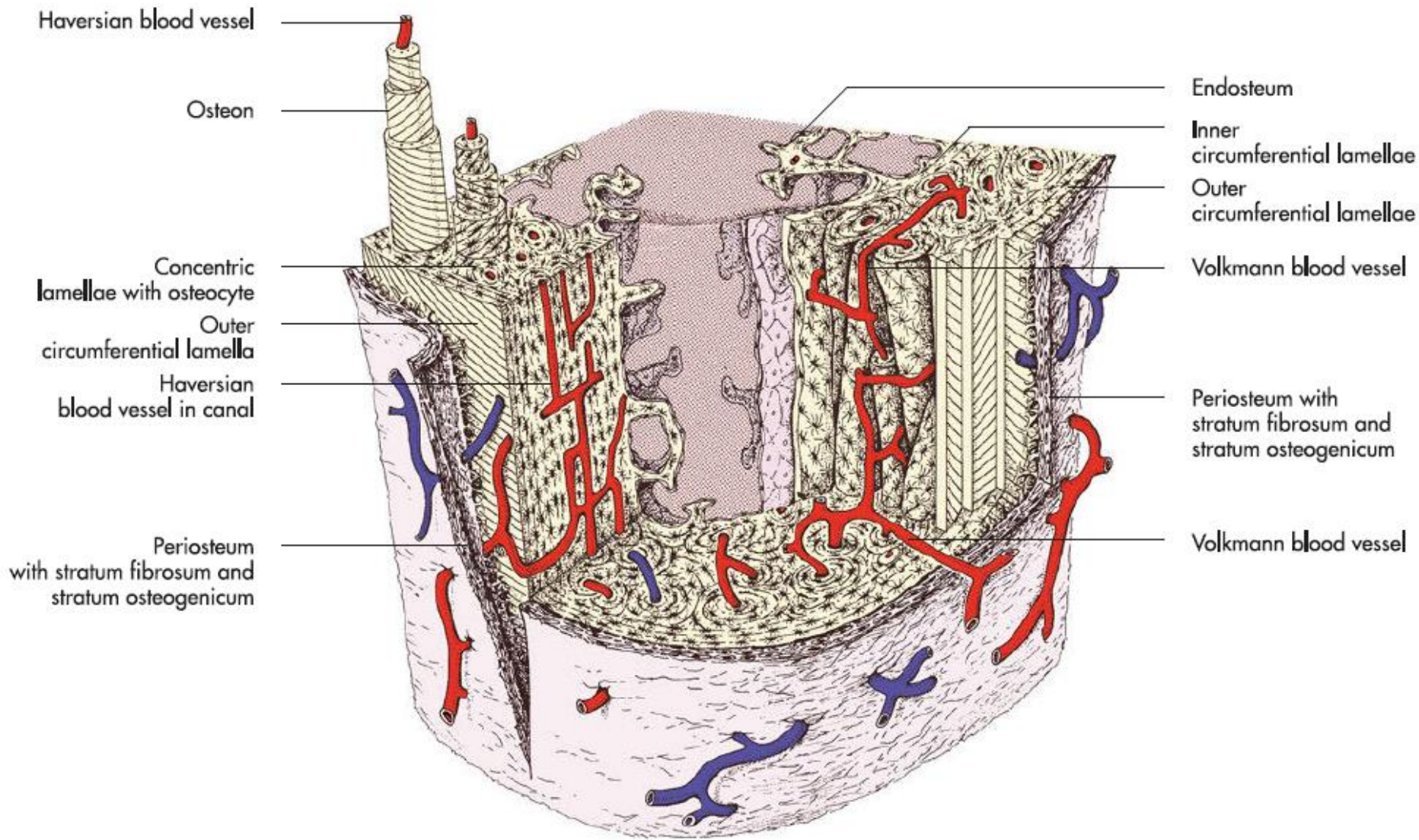
- There are two types of bone tissue: woven bone and lamellar bone

## 1. **Woven (fibrous, immature) bone:**

- Is regarded as the first and oldest form of bone, often being classified as ossified connective tissue.
- During foetal development, each bone initially consists of woven bone, and only after birth this is bone slowly replaced by the more complex lamellar bone.
- However, some woven bone persists throughout life. For example the osseous labyrinth of the ear, the external acoustic meatus, and muscle attachment sites on long bones remain as woven bone

## 2. **Lamellar (mature) bone**

- It is arrangement of strictly parallel or concentric layers of collagen fibres, called lamellae.
- Most bones of the adult animal consist of lamellar bone, which forms the long bones as well as the short and flat bones.
- The structural unit of lamellar bone is the osteon (Haversian system).
- Each osteon is a series of concentric rings made up of layers of bone matrix around a central canal (Haversian canal) through which a blood vessel travel.
- The central blood vessels in the osteons communicate with the periosteum, the endosteum and the medullary cavity through transverse Volkmann vessels
- Layers of lamellae form the outer circumference of the bone directly
- beneath the periosteum (outer circumferential lamellae)



Haversian blood vessel

Osteon

Concentric lamellae with osteocyte

Outer circumferential lamella

Haversian blood vessel in canal

Periosteum with stratum fibrosum and stratum osteogenicum

Endosteum

Inner circumferential lamellae

Outer circumferential lamellae

Volkmann blood vessel

Periosteum with stratum fibrosum and stratum osteogenicum

Volkmann blood vessel