



Sciatic nerve structure and nomenclature: epineurium to paraneurium is this a new paradigm?

Xavier Sala-Blanch, MD*

* Department of Anesthesiology. Orthopedic Anesthesia Section. Hospital Clinic, University of Barcelona. Barcelona, Spain.

We read with interest the study by Perlas et al.,⁽¹⁾ about the sciatic nerve block at the level of its division in the popliteal fossa. We have been developing this technique in our routine practice during the past 7 years and have no doubt about the efficacy and safety of this approach^(2,3).

However, we do not agree with the author's definition of the structure and limits of the nerve. Given the impact of publications from the principal author's research group on the regional anesthesia community, we are compelled to comment on proposed terminology that we feel may create confusion and contribute to the creation of a new paradigm in peripheral nerve blockade. The peripheral nerve is a well-defined anatomical entity with an unequivocal histological structure (Figure 1). The fascicle is the noble and functional unit of the nerves. Fascicles are constituted by a group of axons covered individually by the endoneurium and tightly packed within the perineurium.

The epineurium comprises all the tissues that hold and surround the fascicles and defines the macroscopic external limit of the nerve. Epineurium includes loose connective and adipose tissue and epineurial vessels. Fascicles can be found as isolated units or in groups of fascicles supported and held together into a mixed collagen and fat tissue in different proportions (within the epineurial cover). The epineurium cover is the thin layer of connective tissue that encloses the whole structure and constitutes the anatomical limit of the nerve. It acts as a mechanical barrier (limiting the spread of injected local anesthetic), but not as a physical barrier (allowing the passive diffusion of local anesthetic along the concentration gradient). The paraneurium is the connective tissue that supports and connects the nerve with the surrounding structures (eg, muscles, bone, joints, tendons, and vessels) and acts as a gliding layer. We agree that the limits of the epineurium of

the sciatic nerve, like those of the brachial plexus, are more complex than in single nerves. Therefore, the sciatic nerve block deserves special consideration.

If we accept that the sciatic nerve is an anatomical unit, the epineurium should include the groups of fascicles that will constitute the tibial and the common peroneal nerves. Similarly, the epineurium of the common peroneal nerve contains the fascicles that will be part of the lateral cutaneous, the deep peroneal, and the superficial peroneal nerves. However, if we accept that the connective tissue enveloping the sciatic nerve is not part of it, the same argument could be applied to more distal nerves. Therefore, an injection inside the common peroneal nerve could be considered as a block in the paraneurium of its terminal branches. By modifying the concept of epineurium of the sciatic nerve and adopting a different terminology (eg, paraneurium and mesoneurium), we risk promoting deliberate and unrestricted intraneural injections, which may lead to an increase in neurological complications associated with peripheral nerve blocks. In our opinion, it would be more appropriate to maintain the nomenclature of epineurium and accept that wherever a nerve divides into distinct branches, as in the case of sciatic nerve in popliteal fossa, the epineurium can be accessed to produce an effective block while minimizing the risk of fascicle damage. Perlas et al. demonstrate that a single injection results in a more efficient and fast block than a double injection targeting 2 smaller nerves^(1,4), which is at odds with our current understanding^(5,6). The authors did not explain these uncommon results. We needed more than a decade, after the introduction of ultrasound in regional anesthesia, to reject the erroneous paradigm generated in the 1970's about the safety of nerve stimulation to avoid needle-nerve contact. Now, ultrasound is generating

Este artículo puede ser consultado en versión completa en <http://www.medigraphic.com/rma>

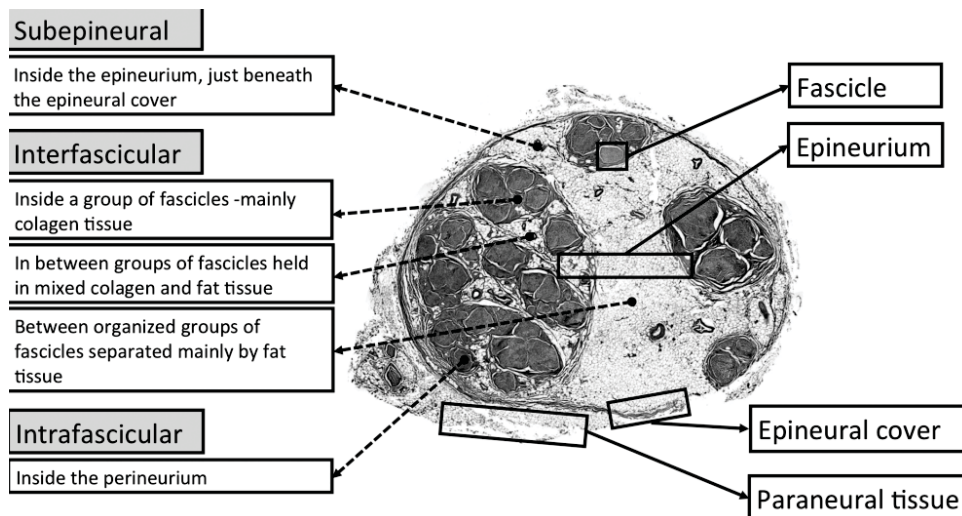


Figure 1.

Modificado de: Reina MA. Originalmente publicado en *Reg Anesth Pain Med.* 2012;37:363-365.

an intense debate on the classical anatomic and histological concepts of nerve structure. We believe that, if the community of regional anesthesiologists finally accepts that the epineurium of the sciatic nerve is the «paraneurium», a new paradigm arises. We would not be surprised if this new paradigm is debated and rejected by the next generation of regional anesthesiologists.

Miguel A. Reina, MD, PhD
 Department of Anesthesiology
 Madrid-Montepíncipe University Hospital
 Madrid, Spain
 Department of Clinical Medical Sciences

and Applied Molecular Medicine Institute
 CEU San Pablo University School of Medicine
 Madrid, Spain
 Teresa Ribalta, MD, PhD
 Department of Pathology, Hospital Clinic
 University of Barcelona
 Barcelona, Spain
 Alberto Prats-Galino, MD, PhD
 Laboratory of Surgical Neuroanatomy
 Faculty of Medicine
 University of Barcelona
 Barcelona, Spain
 The authors declare no conflict of interest.

REFERENCES

1. Perlas A, Wong P, Abdallah F, Hazrati LN, Tse C, Chan V. Ultrasound-guided popliteal block through a common paraneural sheath versus conventional injection: a prospective, randomized, double-blind study. *Reg Anesth Pain Med.* 2013;38:218-225.
2. Sala-Blanch X, de Riva N, Carrera A, Lopez AM, Prats A, Hadzic A. Ultrasound-guided popliteal sciatic block with a single injection at the sciatic division results in faster block onset than the classical nerve stimulator technique. *Anesth Analg.* 2012;114:1121-1127.
3. Sala-Blanch X, Lopez AM, Pomes J, Valls-Sole J, Garcia AI, Hadzic A. No clinical or electrophysiologic evidence of nerve injury after intraneural injection during sciatic popliteal block. *Anesthesiology.* 2011;115:589-595.
4. Tran de QH, Dugani S, Pham K, Al-Shaafi A, Finlayson RJ. A randomized comparison between subepineural and conventional ultrasound-guided popliteal sciatic nerve block. *Reg Anesth Pain Med.* 2011;36:548-552.
5. Prasad A, Perlas A, Ramlogan R, Brull R, Chan V. Ultrasound-guided popliteal block distal to sciatic nerve bifurcation shortens onset time: a prospective randomized double-blind study. *Reg Anesth Pain Med.* 2010;35:267-271.
6. Buys MJ, Arndt CD, Vagh F, Hoard A, Gerstein N. Ultrasound-guided sciatic nerve block in the popliteal fossa using a lateral approach: onset time comparing separate tibial and common peroneal nerve injections versus injecting proximal to the bifurcation. *Anesth Analg.* 2010;110:635-637.

www.medigraphic.org.mx