


Monaco



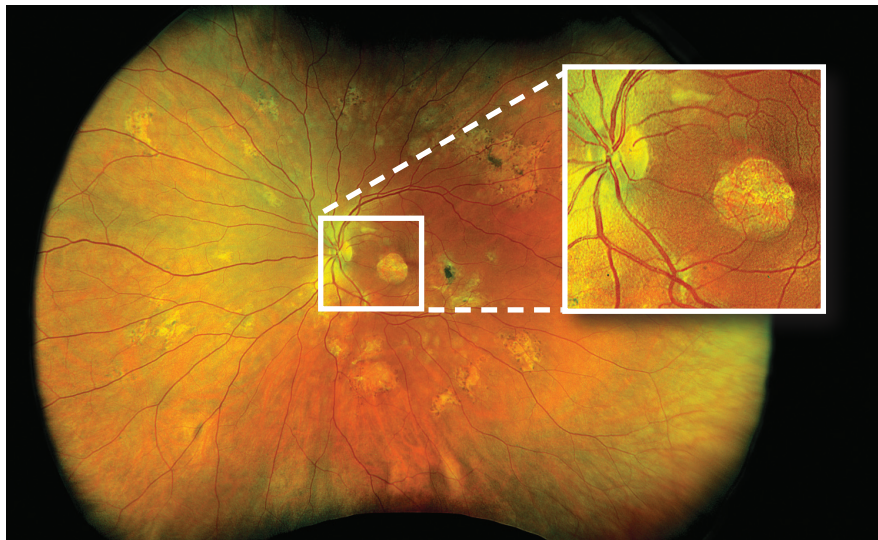
Optos Ultra-widefield Retinal Imaging with **optomap**[®]-guided SD-OCT

Monaco

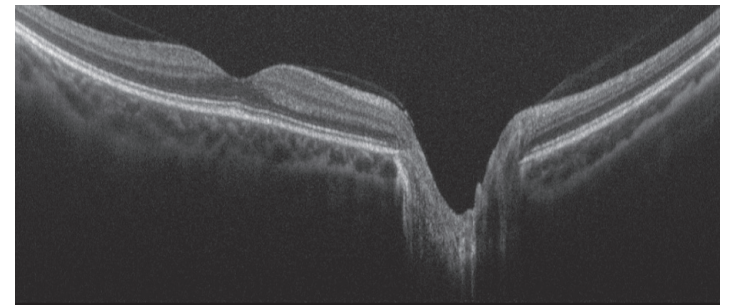
Monaco combines **optomap ultra-widefield (UWF™)** technology with **SD-OCT** creating a **fast, convenient, multi-modal imaging tool**. *Monaco* can produce a 200°, single-capture retinal image of unrivaled clarity and can display a six-image overview including color, FAF, and OCT of both eyes in as little as 90 seconds.

optomap has been shown to enhance pathology detection and disease management, and to improve clinic flow.² The integrated OCT further contributes to this capability.

OCT scans are precisely registered to corresponding **optomap** images facilitating detailed examinations, follow up scanning, and visit to visit comparisons.



1-click **optomap** imaging provides image resolution equivalent to ETDRS³ and eliminates the need for multiple image sweeps or montaging

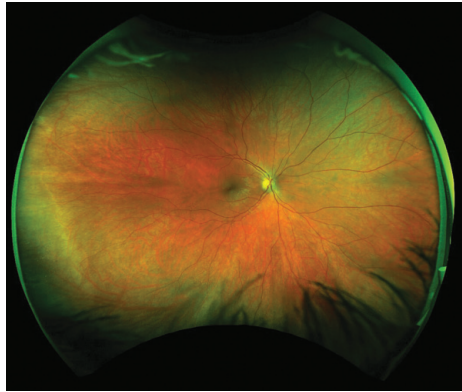

12mm OCT scan across macula and ONH

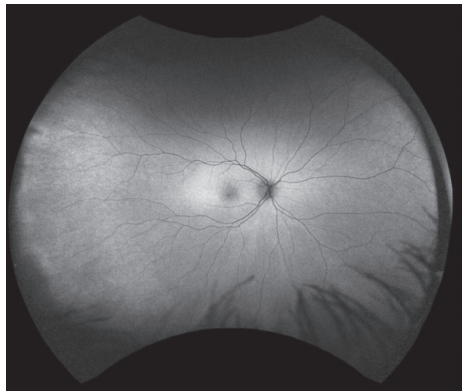
Fast, Comprehensive Imaging

Monaco can capture a 6-image, multimodal overview of both eyes in as little as 90 seconds. Visualizing multiple image modalities at the same time enables a practitioner to detect pathology in the various views.

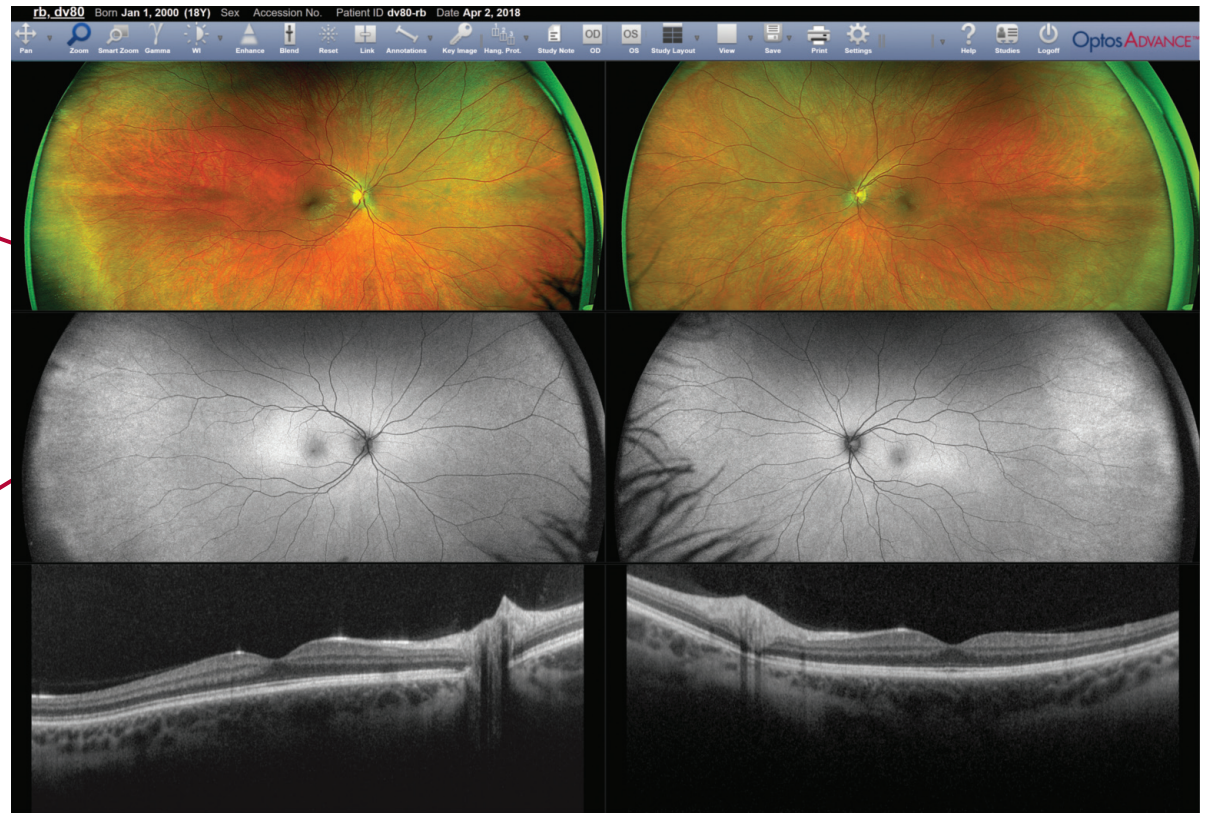
View the entire, 200° optomap® image with a click



optomap *color*

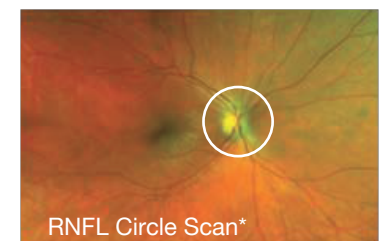
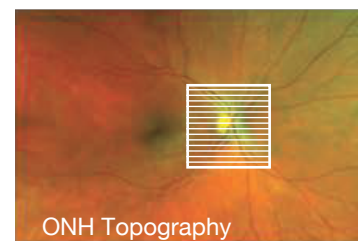
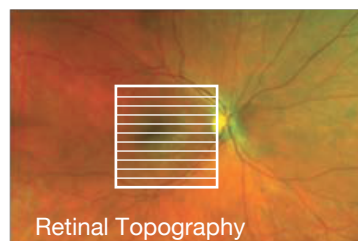

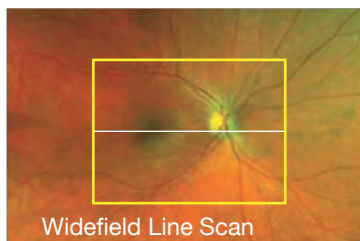


optomap *af*



Scroll through OCT raster scans to look for fluid or pathology

OCT SCAN TYPES



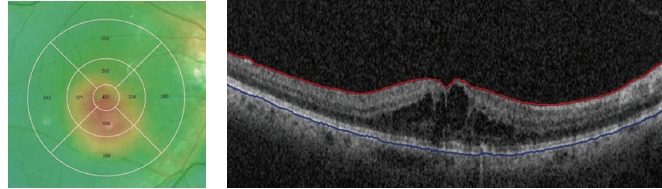
*The RNFL peripapillary scan is automatically extracted from the ONH Topography

Fast, Comprehensive Imaging

The Monaco analysis tools automatically segment, measure, and display key parameters.

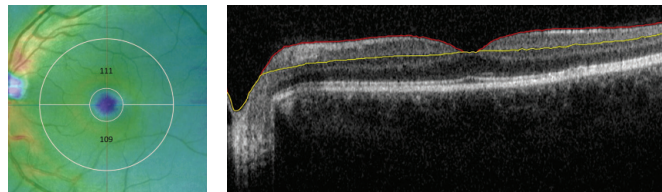
RETINAL THICKNESS

ILM and RPE are automatically detected and marked. Retinal thickness is measured and displayed in a color map, and numeric values are provided in an ETDRS grid overlay.



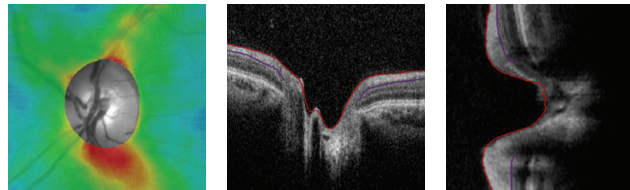
GANGLION CELL COMPLEX

GCC is automatically segmented and measured from the ILM to the IPL. Thickness measurements are displayed in a color map and grid overlay.



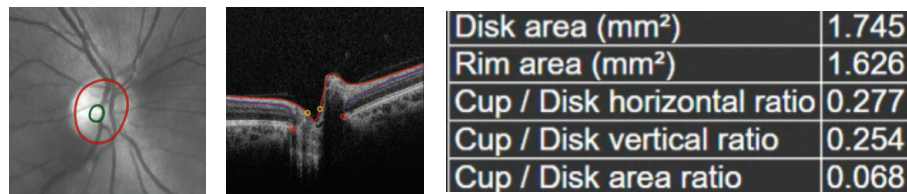
ONH RNFL THICKNESS

Retina nerve fibre layer (RNFL) is automatically segmented from the ONH topography cube scan and is displayed in a color map.



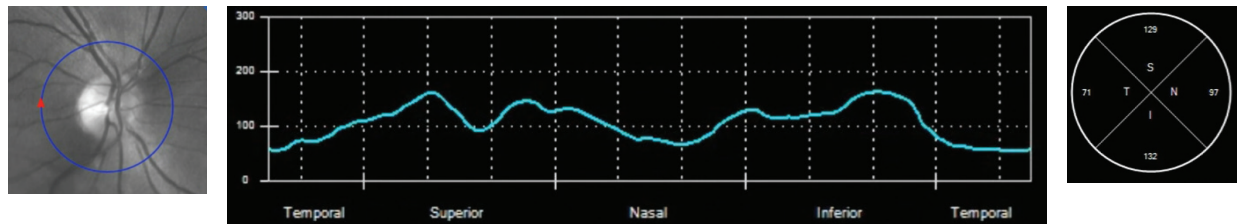
ONH CUP & DISC ANALYSIS

Bruch's Membrane Opening (BMO) and ILM are automatically detected and used to calculate optic nerve head parameters. Disk and Cup outlines and calculated ONH parameters are displayed.



RNFL THICKNESS

Peripapillary RNFL is automatically segmented from the ONH topography scan data. Thickness measurements are displayed graphically and in TSNIT charts.



Monaco

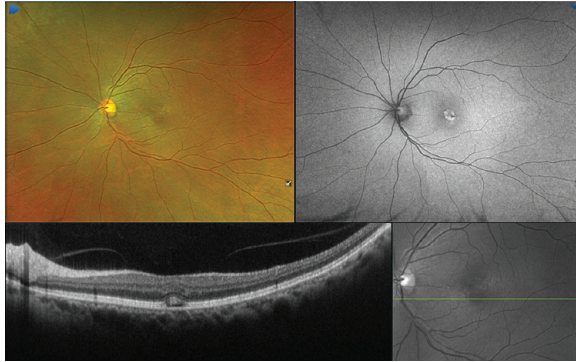


Multimodal Imaging

Multimodal imaging with ultra-widefield (UWF™) technology + OCT can provide additional insights especially in cases of peripheral pathology.

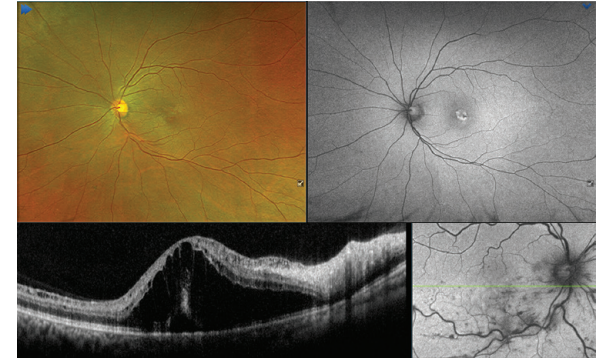
WET AMD

In this AMD case, a choroidal neovascular lesion directly below the fovea is visible in the color image. The lesion is unmistakable in the AF image which shows an area of hyper-fluorescence with spots of dark hypo-fluorescence. The OCT scan clearly shows RPE disruption within the lesion and a PVD in the vitreous.



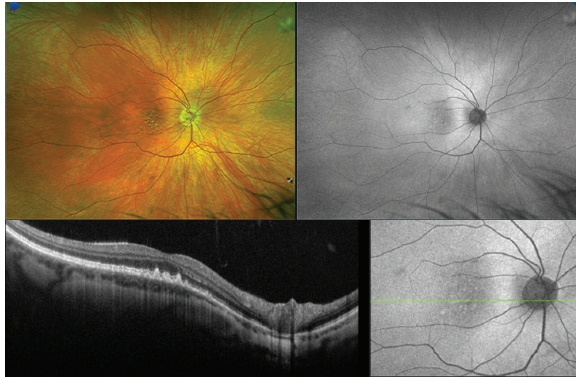
RVO

The color image of this hemi-retinal vein occlusion shows haemorrhages and exudates in the inferior retina extending into the far peripheral retina. The OCT scan through the fovea shows significant edema.



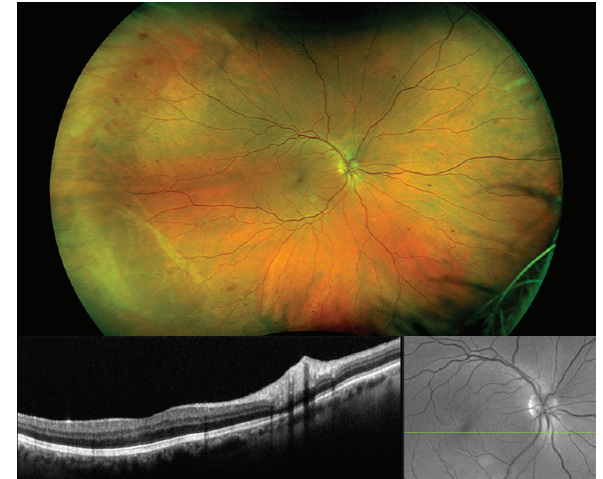DRY AMD

This AMD patient has large drusen in the macula region. The drusen appear as pale white spots in the color **optomap** and as hyper-fluorescent spots on the AF image. The OCT scan across the macula reveals structural detail of the drusen under the fovea.



NPDR

At first glance, the eye of this diabetic patient might be seen as normal. The OCT through the fovea is unremarkable. However, the **optomap** shows haemorrhages in the mid and far periphery both nasally and temporally. Recent studies suggest this patient is at greater risk of progression to proliferative disease.¹



Unique Features

- Distance (mm) and area (mm²) measurements provide objective assessment of change over time
- optomap** with integrated OCT saves time, space and minimizes patient movement
- High resolution 200° single-capture **optomap** images improve pathology detection and management from macula through the far periphery
- Non-mydratric, cSLO imaging through most cataracts⁴ and small pupils (2 mm)⁵
- 3-in-1 Color Depth Imaging™ provides important clinical data from the retinal surface through the choroid
- Green laser autofluorescence shows macula and optic nerve head detail
- Central pole OCT provides structural detail of pathology seen in fundus images
- Fast, comfortable image acquisition is easier on patients and improves clinic flow
- Optos*Advance*™ Image Management software streamlines image review and consultations
- Color, AF, and OCT images are shown in a single, comprehensive view
- DICOM compatible software supports compliance with the Code of Federal Regulations⁶



Technical specifications

TRADE NAME	Monaco
MODEL NAME	P200TE
MODEL NUMBER	A10700
optomap UWF Imaging	
IMAGING MODALITIES	Color Red-free (Sensory) Choroidal Autofluorescence (AF)
RESOLUTION	optomap <i>plus</i> : 14 µm optomap: 20 µm,
LASER WAVELENGTHS	Red laser: 635 nm Green laser: 532 nm (for AF)
EXPOSURE TIME	Less than 0.4 seconds
OCT Imaging	
SIGNAL TYPE	Optical scattering from tissue
SIGNAL SOURCE	Spectral domain OCT, Wavelength 840 nm
AXIAL RESOLUTION*	< 7 micron (in tissue) < 5 micron (digital)
TRANSVERSE RESOLUTION*	< 20 micron (in tissue) < 15 micron (digital)
SCANNERS	Galvanometric X, Y mirrors
SCAN DEPTH	2.3 mm (in tissue)
A-SCAN RATE	Up to 70k cycles/sec
SCAN TYPES	Line Scans Width: 12 mm Raster Scan Retina Topography Scan Optic Nerve Head (ONH) Topography Scan Retinal Nerve Fiber Layer (RNFL) Scan
System	
OPTICAL POWER	Laser safety Class-1 following IEC/EN60825-1
FOOT PRINT	Width: 550 mm / 22 in, Depth: 570 mm / 23 in Height: 608 - 632 mm / 24 - 25 in
WEIGHT	Max 40 kg
TABLE SPACE REQUIREMENTS	Width: 887 mm / 35 in, Depth: 600 mm / 24 in Height: 725 to 1205 mm / 29 - 48 in
SYSTEM VOLTAGE	100-240V, 50/60Hz
POWER CONSUMPTION	300 VA

NOTE: Specifications are subject to change without notice.

- Silva. Peripheral Lesions Identified on Ultrawide Field Imaging Predict Increased Risk of Diabetic Retinopathy Progression over 4 Years. Ophthalmology 2015.
- Tornambe, The Impact of Ultra-widefield Retinal Imaging on Practice Efficiency, US Ophthalmic Review 2017.
- Silva et al, Nonmydratric Ultrawide Field Retinal Imaging Compared with Dilated Standard 7-Field 35-mm Photography and Retinal Specialist Examination for Evaluation of Diabetic Retinopathy, AJO 2012.
- Friberg. Advances in retinal imaging of eyes with hazy media: Further Studies. ARVO 2011.
- Legarreta. Imaging of Peripheral Retina with Optos Ultra-Widefield Imaging: Evaluation of Aperture Size on Image Quality. ARVO 2012.
- All Covered Entities must securely backup 'retrievable exact copies of ePHI' (CFR 164.308 (7)(ii)(A)).



Optos UK/Europe
+44 (0)1383 843350
ics@optos.com

Optos North America
800 854 3039
usinfo@optos.com

Optos DACH
DE: 0800 72 36 805
AT: 0800 24 48 86
CH: 0800 55 87 39
ics@optos.com

Optos Australia
+61 8 8444 6500
auinfo@optos.com

Contact us:

