

Viral Rashes in Children

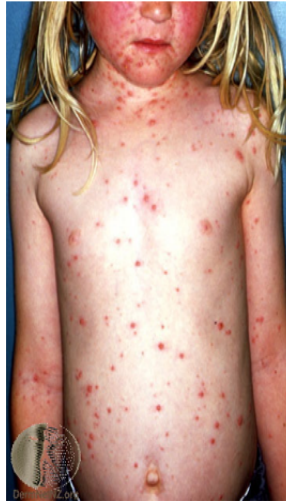

Hello, my name is Carly Rumley and I am a medical student at the University of Alberta. This podcast was developed with Dr. Melanie Lewis, a paediatrician at the University of Alberta. In this PedsCases Podcast, we will discuss viral rashes that can present in a child under the age of 2, or in school age children.

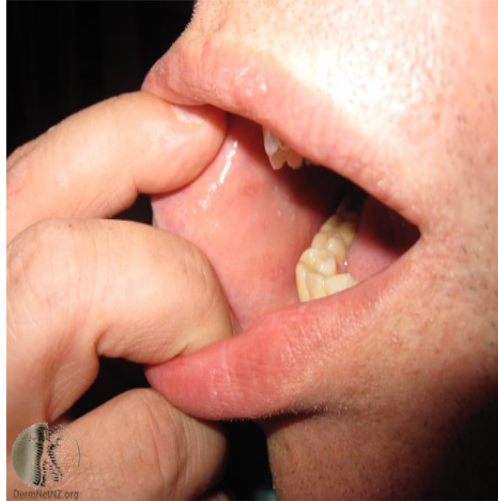Learning Objectives

1. Describe classic presentations of common viral exanthems and enanthems in infants and children.
2. List specific features of some viral rashes to help differentiate between them.

Exanthem
(Ex. Varicella)



Enanthem
(Ex. Measles – Koplik spots day 1)



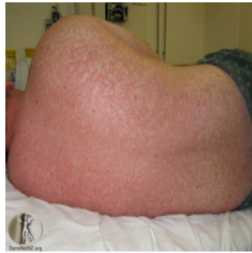We will start by defining some terms that are important to use when describing rashes. An exanthem is a rash involving the skin, whereas an enanthem is a rash involving mucous membranes.

<http://www.dermnetnz.org/doctors/viral-infections/specific-exanthems.html#vari>

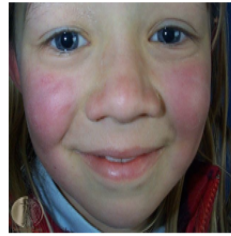<http://www.dermnetnz.org/viral/morbilli.html>

Macular Rash

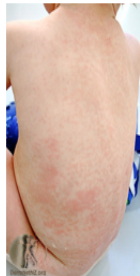Measles



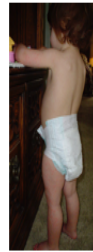Parvovirus B19



Rubella



Roseola- HHV6, HHV7



Some viruses will cause a macular rash, whereas others will cause a vesicular rash. A macule is a circumscribed flat lesion that has a different color than the surrounding skin. You cannot feel it when you run your finger over it. A papule is a small, solid, elevated lesion that is usually <1 cm in size. A vesicle is an elevated, circumscribed lesion that contains fluid, usually <1 cm in size.

It is important to know which viruses can cause which type of rash. Some viruses that cause

red macular rashes are measles, rubella, Parvovirus B19, and human herpes virus 6 and 7.

<http://www.dermnetnz.org/viral/morbilli.html>

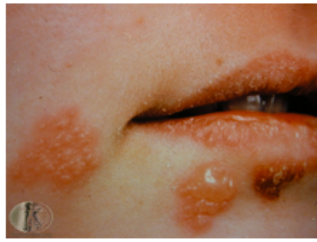
<http://www.dermnetnz.org/viral/rubella.html>

<https://en.wikipedia.org/wiki/Roseola>

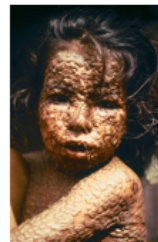<http://www.dermnetnz.org/viral/fifth-imgs.html>

Vesicular Rash

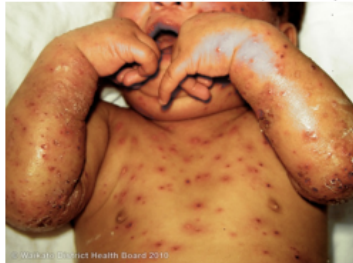HSV 1, 2



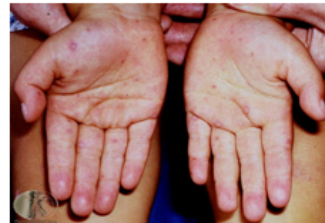Smallpox



Varicella Zoster Virus (HHV3)



Coxsackie Virus (picture- Hand Foot Mouth Disease)



Viruses that can cause vesicular rashes include Herpes Simplex 1 and 2, Varicella zoster virus, smallpox and monkeypox, and Coxsackie virus.

<http://www.dermnetnz.org/viral/herpes-simplex.html>

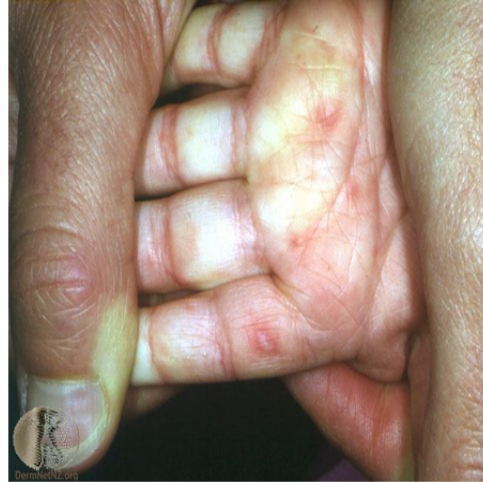<http://www.dermnetnz.org/viral/varicella.html>

<https://en.wikipedia.org/wiki/Smallpox>

<http://dermnetnz.org/viral/hand-foot-mouth.html>

History and Physical Exam

- ID: Age, gender
- History:
 - HPI
 - Fever
 - Rash description
 - Systemic symptoms
 - Animal contact
 - Travel history
 - Food
 - Past Medical History
 - Medications
 - Immunizations
- Physical Exam
 - Vitals
 - Scalp, ears, neck
 - Mucous membranes
 - Skin folds
 - Digits, palms, soles



Let's think of our approach to a 1 year old baby girl presenting with a rash in a family doctor's office. Some initial questions to ask on History should be: is there a fever, are there systemic symptoms, are her immunizations up to date, has she had any animal contacts or stings, where has she traveled to recently, is she on any medications, has she tried new foods? Where did the rash start, what did it look like, and what is the time frame of development?

On physical exam, you would want to get vital signs, and examine the scalp, ears, neck, mucous membranes, skin folds, digits, palms, and soles. Depending on where the rash originated, you would of course start there, and then make sure to examine the rest of the body as location of rashes can guide the differential.

<http://dermnetnz.org/viral/hand-foot-mouth.html>

Common Viral Rashes for a Child <2 years old:

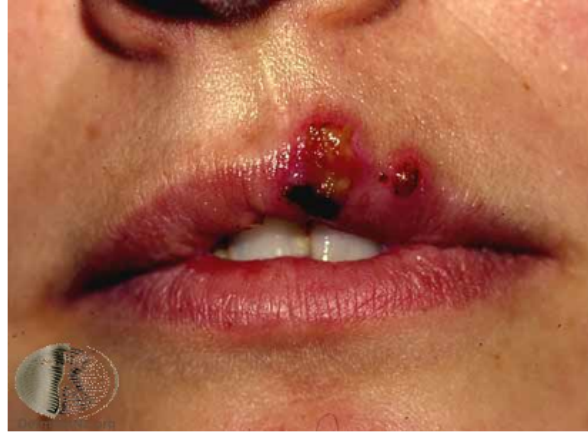- Roseola (HHV6, 7)
- HSV1 Herpes Simplex Virus 1
- HFMD (hand foot mouth disease)
 - Coxsackie A16
 - Enterovirus 71



For this 1 year old patient (or any child under 2 years old), the most common viral rashes are Roseola, herpes simplex virus 1, and HFMD/ hand foot and mouth disease.

HSV1

- Transmission - Respiratory droplet, direct contact
- Presentation - Oral vesicles, Gingivostomatitis
- Management - Symptomatic treatment
 - Severe Infection - Can treat with antiviral (Acyclovir)



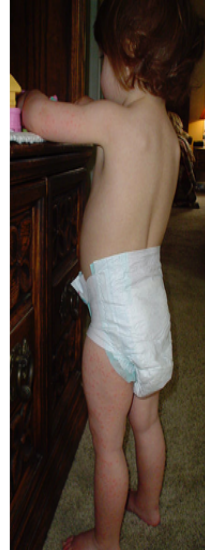Herpes simplex virus 1 is a common cause of oral lesions or gingivostomatitis (versus herpes simplex virus 2, which more commonly causes genital lesions). HSV1 is spread by respiratory droplet and direct contact. The incubation period is 2-14 days after exposure. These oral vesicles are extremely painful, and will eventually crust over. HSV1 can be detected via PCR from the fluid of an unroofed vesicle. Also, this virus can show trigeminal nerve latency- meaning, the viral DNA can stay in the

nerve, latent for years, where it can be reactivated and affect the same dermatome as before. The treatment of a viral cause of these oral lesions is symptomatic- so lidocaine can be used.

<http://www.dermnetnz.org/viral/herpes-simplex.html>

Roseola- HHV6, 7

- Presentation
 - Abrupt high fever 3-5 days, then rash 1-2 days
 - Rash – Erythematous, blanching maculopapular eruption
- Management – Acetaminophen for fever



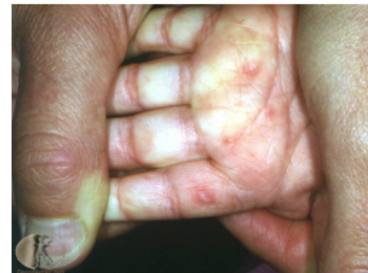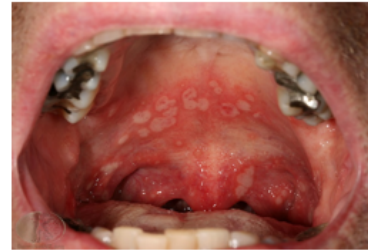Next virus to consider is human herpes virus 6, which causes Roseola Infantum (also called exanthem subitum or Sixth disease). It is a common febrile childhood illness that is characterized by an abrupt high fever for 3-5 days, then defervescence, then a rash that lasts for 1-2 days. Specifically, the rash is described as an erythematous maculopapular eruption that is discrete, pale pink lesions that are 2-5 mm in diameter on the neck, trunk, buttocks, and maybe face and proximal extremities. The

lesions blanch with pressure. This illness can also present with a mild cough, coryza, anorexia, abdominal discomfort, and lymphadenopathy. The fever can be treated with acetaminophen.

<https://en.wikipedia.org/wiki/Roseola>

Hand, Foot, and Mouth Disease (HFMD)

- Coxsackie Virus A16
 - Transmission - Direct contact
 - Rash – Maculopapular on palms, soles, buccal mucosa, or tongue
 - Herpangina - Gray/white vesicles on posterior palate and tonsils
- Enterovirus A71
 - Red papules that change to grey vesicles



The last common viral rash that will be discussed for an infant is hand, foot, and mouth disease or HFMD. The most common viruses that cause HFMD are Coxsackie virus A (A16), or Enterovirus 71. The incubation period is 4-6 days, then the patient will present with fever, anorexia, malaise, sore throat, and a rash. Coxsackie is transmitted via direct contact and causes a maculopapular rash that starts on the face and neck, extends to the trunk and feet, and is sometimes on the palms

and soles, buccal mucosa, and tongue. Coxsackie A causing fever, sore throat, and gray/white vesicles on the posterior palate and tonsils is termed Herpangina. These vesicles can form bullae and ulcerate.

Enterovirus A19 can also cause HFMD, which also presents with fever, anorexia, malaise, sore mouth, and oral lesions 1-2 days later. These oral lesions are vesicles on an erythematous base which ulcerate and are painful. The cutaneous lesions caused by Enterovirus A19 are red papules that change to grey vesicles 3-7 mm in size and can affect the palms and soles. Most cases of HFMD are self-limiting in 1 week. The treatment is symptomatic therapy with hydration and antipyretics.

<http://www.dermnetnz.org/viral/herpangina.html>

<http://dermnetnz.org/viral/hand-foot-mouth.html>

Diagnosis and Treatment of Viral Rashes

Things to Consider:

- Exposure history
- Rash location
- Duration of Symptoms
- Presence/Absence of Fever

Overall, we have discussed that exposure history, location of rash, duration of symptoms, and presence or absence of a fever are important clinical signs that can guide the diagnosis and treatment plan.

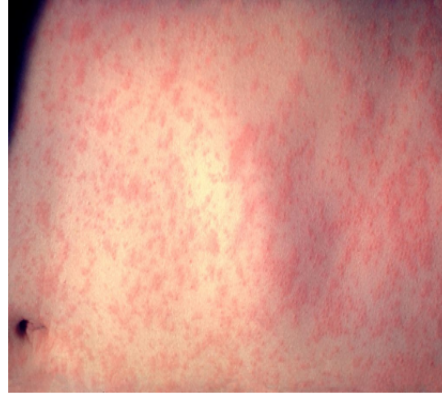Common Viral Rashes for a School-Age Child:

- Chicken Pox (Varicella Zoster Virus/HHV3)
- Measles
- Rubella (German measles)
- Parvovirus B19 (Slapped cheek syndrome)
- Mumps

Now, we will change demographic slightly to consider a school age male or female presenting with a rash. Some common viral rashes to consider are chicken pox, measles, rubella, parvovirus B19, and mumps.

Case

- Female, 8 years old
 - Fever
 - Sore throat
 - Maculopapular rash on neck, trunk, arms
 - Negative throat culture



Consider this situation: while working at a family medicine clinic, one of your patients is an 8 year old girl, and her parents say she has a fever and sore throat. She presents with a red rash on her neck, and upon further physical examination, has a maculopapular rash over her trunk and arms. You take a throat culture, which is negative. It is possible to obtain a blood sample to perform viral serology (which could indicate measles, rubella, or B19 if positive), but realistically this would only be

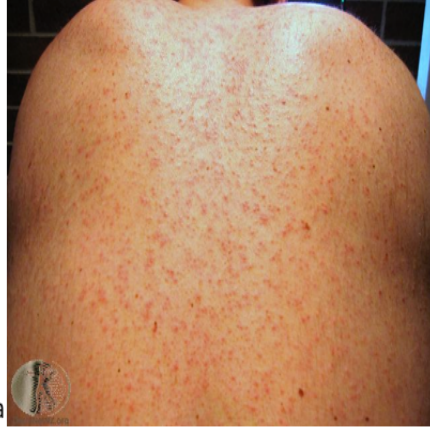done if the child was quite unwell.

Lets go through 5 common viral causes of a rash in this age group and consider some defining characteristics.

<https://en.wikipedia.org/wiki/Measles>

Measles

- Paramyxoviridae Virus
- Transmission – Airborne
- Presentation – Upper respiratory symptoms, malaise, fever, conjunctivitis, photophobia, cough
- Rash – Spreads centrifugally, blanches on pressure, ~7 days
 - Koplik spots – Pathognomonic enanthem
- Self limited
- Management – Isolation, symptomatic
- Complications – Subacute sclerosing panencephalitis (SSPE), a progressive neurologic disease
- Vaccination – MMRV measles, mumps, rubella, varicella (12-15 mo, 4-6 yrs)



Measles is caused by a Paramyxoviridae virus with airborne transmission, hence is one of the most contagious of all infectious diseases. There is a 10 day incubation period followed by a 3 day prodrome which can include upper respiratory symptoms, malaise, fever, conjunctivitis, photophobia, and cough. The rash first forms behind the ears and forehead hairline. It then spreads in a centrifugal pattern, which is central to peripheral, and from head to feet. The rash initially is red,

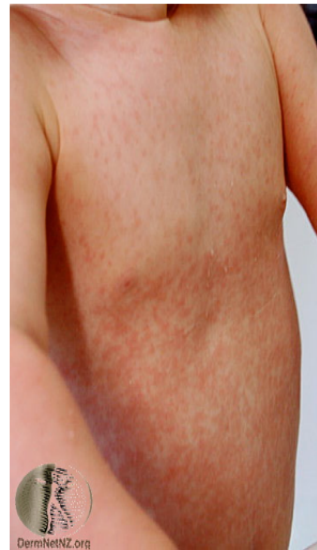blanches on pressure, and lasts about 7 days. The patient can also have Koplik spots, which is a pathognomonic enanthem for measles- this rash is white or blueish 1 mm discrete spots with a red base on the buccal mucosa. The measles rash is a self limiting infection (unless the patient is immunocompromised). Complications of measles can include otitis media, diarrhea, secondary bacterial infections, or acute postinfectious encephalitis. Treatment is isolation because measles is airborne spread. After that, treatment is symptomatic as there is no effective anti viral for measles. There is also the complication of subacute sclerosing panencephalitis (SSPE). This complication is rare, but can develop 2-10 years after a measles infection. SSPE is a progressive neurologic disease, characterized by personality change, intellectual deterioration, development of myoclonic jerks and motor dysfunctions, and possibly blindness. Children can eventually become bedridden and stuporous. Progressive superinfection and metabolic imbalances

eventually lead to death. The pathology of SSPE is due to measles virus infection in the CNS and retina. The incidence of SSPE is about 1/100 000 measles cases and there is no effective therapy at present. Importantly, vaccination is key for prevention of measles! There is a combined MMRV vaccine which covers measles, mumps, rubella, and varicella. Children can receive the first dose at age 12-15 months, and then a second dose at age 4-6 years.

<http://www.dermnetnz.org/viral/morbilli.html>

Rubella Virus

- AKA German measles
- Togaviridae family of viruses
- Transmission – Droplet, vertical
- Presentation – Fever, malaise, headache, nausea, runny nose, sore throat
- Rash – Pink macules and papules on face, spreading to neck, arms, trunk, Forchheimer spots (petechiae on soft palate), lymphadenopathy
- Treatment – Symptomatic
- Congenital Rubella Syndrome – Microcephaly, cataracts, heart disease, osteitis, hepatosplenomegaly, anemia, deafness, developmental delay



Secondly, the Rubella virus, which is sometimes called German measles or third disease, is from the Togaviridae family of viruses. Transmission is droplet or vertical from mom to baby, and there is an incubation period of 12-25 days after exposure. There is a 1-5 day prodrome which can include fever, malaise, headache, nausea, runny nose, and a sore throat. When the exanthem appears afterwards, it starts as irregular pink macules and papules on the face, which spreads to the

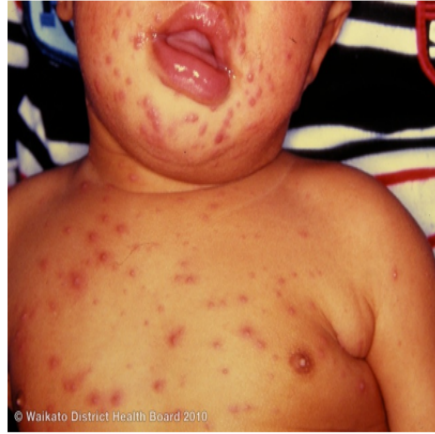neck, arms, and trunk. The rash usually lasts 3 days. Pinpoint petechiae involving the soft palate can also occur, called Forchheimer spots.

Lymphadenopathy involving the sub occipital and posterior auricular nodes can occur with a Rubella infection as well. The treatment is also symptomatic. Pregnant women will be screened for Rubella at their first prenatal visit. If they are not vaccinated or the results are indeterminate, the mom will need postpartum vaccination since Rubella is a live virus vaccination and cannot be given during pregnancy. There is a risk of Congenital rubella syndrome in the newborn, which can present with all or any of microcephaly, cataracts, heart disease, osteitis, hepatosplenomegaly, anemia, deafness, and/ or developmental delay.

<http://www.dermnetnz.org/viral/rubella.html>

Varicella Zoster Virus (HHV3)

- AKA Chicken pox
- Transmission – Airborne
- Presentation – Low grade fever, malaise, headache
- Rash – Pruritic vesicular exanthem. Teardrop vesicles on erythematous base, sparing palms and soles. Vesicles present in different stages of lesion formation
- Self limited
- Treatment – Acetaminophen for fever
- Complication – Can reoccur later in life as Shingles/ Herpes Zoster



Third on the list is chicken pox, from the varicella zoster virus which is human herpes virus 3. Transmission is airborne. Chicken pox presents as a pruritic vesicular exanthem with mild systemic manifestations such as low grade fever, malaise, or headache. The exanthem starts as faint red macules on the trunk or scalp, and then 24 hours later will show the typical vesicular varicella appearance which is described as teardrop vesicles on an erythematous base, spreading centrifugally

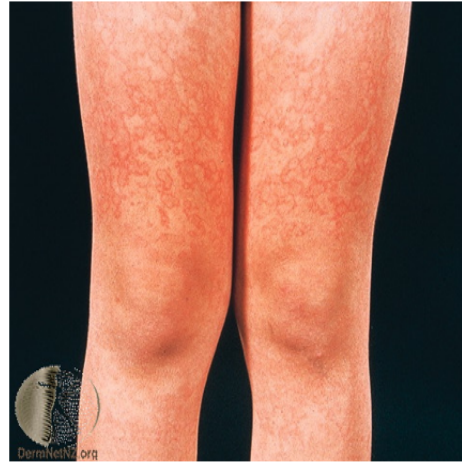and sparing the palms and soles. Most infected children can have 250-500 vesicular skin lesions, and an important factor to note is that the skin vesicles will present in different stages of lesion formation. Diagnosis can be made by clinical presentation, PCR, but serology is not very useful in an acute infection; serology can be used to assess immunity after vaccination. HHV3 is usually a self limited infection. The treatment for chicken pox is acetaminophen for fever (not aspirin, because it can predispose the patient to Reye syndrome, which is a rapidly progressing encephalopathy). If the patient is immunocompromised, then the antiviral therapy acyclovir can be used- it is not recommended for uncomplicated varicella infections in immunocompetent children. Complications of a varicella infection can be encephalitis, meningitis, myelitis, pneumonia, hepatitis, or a secondary bacterial super infection of ruptured vesicles with Staph or Strep. Since chicken pox is caused by a herpes virus, remember the virus can remain latent

in dorsal root ganglia or the trigeminal nerve, and can reoccur later in life as shingles or Herpes zoster.

<http://www.dermnetnz.org/viral/varicella-imgs.html>

Parvovirus B19

- AKA Fifth Disease or Slapped Cheek Syndrome
- Transmission – Vertical, respiratory droplet
- Presentation – Fever (days 5-7), headache, sore throat, cough, vomiting, diarrhea, myalgia
- Rash (day 15-17) – Red rash on cheeks, non-pruritic lacy maculopapular rash on trunk and limbs, palms and soles spared
- Self limiting
- Treatment – Symptomatic



Fourth on our list is Human Parvovirus B19, also called fifth disease, erythema infectiosum, or slapped cheek syndrome. Transmission is vertical or via respiratory routes. A B19 infection presents with a unique exanthem that is a red rash on the cheeks that gives a “slapped cheek” appearance lasting for 4-5 days. 1-2 days after this facial rash, the child can have a non pruritic maculopapular rash on the trunk and limbs- this rash has a lacy or reticulated appearance with the palms and

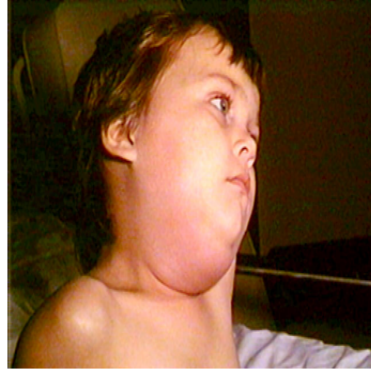soles usually spared. Children infected with Parvovirus B19 can also present with fever, headache, sore throat, cough, vomiting, diarrhea, and myalgia. B19 has a biphasic incubation period where the child presents with a fever for days 5-7 and then a rash at days 15-17 for the second phase. However, an asymptomatic infection is possible with B19. This virus has a tropism for erythrocytic precursor cells which can cause a lack of release of RBCs from the bone marrow, thus causing anemia and puts the patient at risk of transient aplastic crisis. However, a B19 infection is self limiting, so the treatment is symptomatic.

There is no antiviral or vaccine for a B19 infection.

<http://www.dermnetnz.org/viral/fifth-imgs.html>

Mumps

- Transmission – Respiratory route
- Presentation – Low-grade fever, myalgia, headache, anorexia, salivary gland swelling lasting >2 days, epididymoorchitis or oophoritis
- Self limiting
- Parotitis DDX – HIV, Coxsackie Virus, Parainfluenza Virus type 3, influenza A virus, EBV, Adenovirus, Parvovirus B19, HHV6, Gram pos bacteria, atypical mycobacteria, Bartonella species, Sjogren's syndrome, uremia, diabetes, malnutrition, cirrhosis, tumors, medications



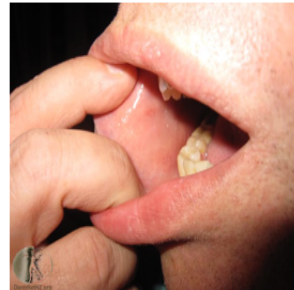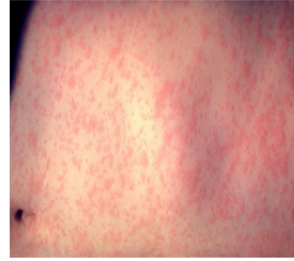
The last viral infection we will discuss is the mumps virus. Mumps is characterized by an acute onset unilateral or bilateral tender swelling of the parotid or other salivary glands that lasts at least 2 days. Before that, the incubation period after exposure is 7-23 days. There is a prodrome that can be characterized by low grade fever, myalgia, headache, and anorexia. The mumps virus is transmitted via the respiratory route in the form of droplets, saliva, or fomites. The virus can replicate

commonly in the salivary glands, testes, pancreas, ovaries, mammary glands, and CNS. In 15-30% of mumps in post pubertal males, epididymo orchitis can occur. This can develop up to 6 weeks after parotitis. 5% of women with a mumps infection can develop oophoritis, which can present as lower abdominal pain and vomiting. Other complications of mumps infection include pancreatitis, thyroiditis, or abnormal renal function. It is important to remember a differential for parotitis which includes the viruses of HIV, coxsackie virus, parainfluenza virus type 3, influenza A virus, Epstein-Barr virus, adenovirus, parvovirus B19, and HHV6. Some non viral causes of parotitis are gram positive bacteria, atypical mycobacteria, and Bartonella species. Parotitis can also occur in the setting of Sjogren's syndrome, uremia, diabetes mellitus, malnutrition, cirrhosis, tumors, or some medications. Generally, mumps is self limiting.

<https://en.wikipedia.org/wiki/Mumps>

Case

- Female, 8 years old
 - Fever
 - Sore throat
 - Maculopapular rash- neck, trunk, arms
 - Negative throat culture
- Koplik spots – Pathognomonic for measles!
- Measles Treatment - Isolation, and symptomatic relief



Lets return to consider the 8 year old girl who presented with a fever and red rash. Upon further inspection, she has blue/ whiteish spots on a red base inside her mouth. In this case, you decide to do viral serology because measles is a reportable disease. It is important to remember that the viral serology test must have 2 weeks between the 2 blood samples. There must be IgM present, or a 4 fold increase in IgG levels from sample 1 to 2 for a positive test. Her viral serology is positive for

measles. As with many viral infections, you tell her parents that her fever can be treated with acetaminophen. A positive measles case would lead public health to isolate the affected individual for 4 days after the rash appeared, which would be the contagious period. Public health would consider post exposure prophylaxis for all possible contacts of this girl.

<http://www.dermnetnz.org/viral/morbilli.html>

Take-Home Points

When considering the etiology for an infectious rash in an infant or child, consider:

- 1. Morphology of rash
- 2. Distribution and progression of the rash. Don't forget to check oral mucosa!
- 3. Presence of systemic features - Ex. Arthritis, fever, lymphadenopathy, parotid swelling



Overall, when considering the etiology for an infectious rash in an infant or child, consider: 1. The morphology of the rash, 2. The distribution and progression of the rash (remember to check oral mucosa) , and 3. Presence of systemic features such as arthritis, fever, lymphadenopathy or parotid swelling. We have discussed the clinical diagnoses commonly made for viral rashes and have reviewed that viral rash treatment is symptomatic in the majority of cases. This concludes our pedscases podcast on viral rashes.

References

- References

- Dennis Dennis Kasper, Anthony Fauci, Stephen Hauser, Dan Longo, J. Larry Jameson, Joseph Loscalzo. 2015. Harrison's Principles of Internal Medicine, 19e. Section 15: Infections Due to RNA Viruses. Chapter 228, 231e
- Judith E. Tintinalli, J. Stephan Stapczynski, O. John Ma, David M. Cline, Rita K. Cydulka, Garth D. Meckler. 2010. Tintinalli's Emergency Medicine: A Comprehensive Study Guide, 7e. Chapter 134. Rashes in Infants and Children.

- Images

- <http://www.dermnetnz.org>
- <http://www.dermnetnz.org/doctors/viral-infections/specific-exanthems.html#vari>
- <http://www.dermnetnz.org/viral/morbilli.html>
- <http://www.dermnetnz.org/viral/rubella.html>
- <https://en.wikipedia.org/wiki/Roseola>
- <http://www.dermnetnz.org/viral/fifth-imgs.html>
- <http://www.dermnetnz.org/viral/herpes-simplex.html>
- <http://www.dermnetnz.org/viral/varicella.html>
- <https://en.wikipedia.org/wiki/Smallpox>
- <http://dermnetnz.org/viral/hand-foot-mouth.html>
- <https://en.wikipedia.org/wiki/Roseola>
- <http://www.dermnetnz.org/viral/herpangina.html>
- <https://en.wikipedia.org/wiki/Measles>
- <http://www.dermnetnz.org/viral/varicella-imgs.html>
- <http://www.dermnetnz.org/viral/fifth-imgs.html>
- <https://en.wikipedia.org/wiki/Mumps>



Pediatrics
for Medical
Students
