



Available online at  
**ScienceDirect**  
www.sciencedirect.com

Elsevier Masson France  
**EM|consulte**  
www.em-consulte.com/en



Original article

## Hyper extension-internal rotation (HERI): A new test for anterior gleno-humeral instability

T. Lafosse<sup>a,\*</sup>, S. Fogerty<sup>b</sup>, J. Idoine<sup>b</sup>, R. Gobezie<sup>b</sup>, L. Lafosse<sup>b</sup>

<sup>a</sup> European Georges Pompidou Hospital, 20, rue Leblanc, 75015 Paris, France

<sup>b</sup> Alps Surgery Institute, clinique générale, 4, chemin de la Tour-la-Reine, 74000 Annecy, France

### ARTICLE INFO

#### Article history:

Received 6 October 2014

Accepted 19 October 2015

#### Keywords:

Shoulder  
Instability  
Clinical test  
Hyperextension  
Internal rotation  
Cadaver study  
Clinical study

### ABSTRACT

**Background:** Anterior shoulder dislocation causes injury to the inferior gleno-humeral ligament (IGHL) and capsule. Clinical manoeuvres currently used to evaluate the IGHL test for, and may induce, apprehension. We developed the hyper extension-internal rotation (HERI) test to assess the IGHL and inferior capsule without causing apprehension or inducing a risk of gleno-humeral dislocation.

**Hypothesis:** The HERI test is easy to perform and reproducible, induces no risk of gleno-humeral dislocation during the manoeuvre, and causes no apprehension in the patients.

**Material and methods:** We studied 14 fresh cadaver shoulders. Each specimen was positioned supine with the lateral edge of the scapula on the table and the upper limb hanging down beside the table under the effect of gravity. This position produced hyperextension and internal rotation of the gleno-humeral joint. For each shoulder, the range of extension ( $^{\circ}$ ) was measured before and after isolated IGHL section. Then, we performed the HEIR test in 50 patients with chronic unilateral anterior gleno-humeral instability and we compared the range of extension between the normal and abnormal sides.

**Results:** In the cadaver study, isolated IGHL section increased the angle of extension by a mean of  $14.5^{\circ}$  ( $11^{\circ}$ – $18^{\circ}$ ) compared to the pre-injury values. In the clinical study, the mean difference in extension angles between the normal and abnormal sides was  $14.5^{\circ}$ . The patients reported no apprehension during the HERI test.

**Conclusion:** The angle of extension increases after section or injury of the IGHL in cadaver specimens and patients, respectively. When the inferior capsule and IGHL are damaged, the angle of extension increases compared to the normal side. Lesions to these structures can be evaluated clinically by performing the HERI test.

**Level of evidence:** III.

© 2015 Elsevier Masson SAS. All rights reserved.

### 1. Introduction

During antero-medial gleno-humeral dislocation, the forward, downward, and medial displacement of the humeral head causes damage to the inferior gleno-humeral ligament (IGHL) and capsule. The IGHL is a capsular and ligamentous complex that has three main components, namely, the anterior band, posterior band, and axillary pouch (Fig. 1).

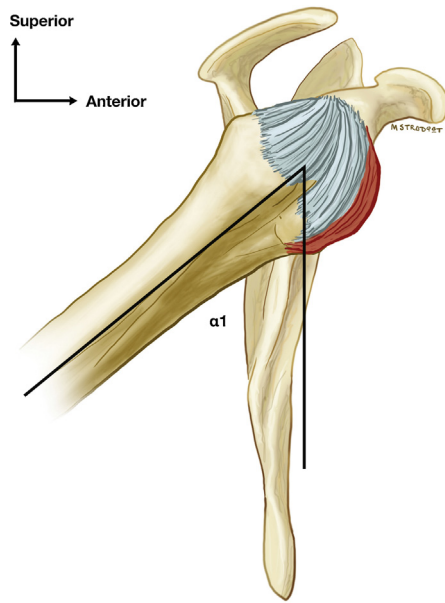
The hyper abduction test developed by Gagey [1] also evaluates the IGHL but has the major disadvantage of inducing a sensation of imminent dislocation that causes apprehension in patients with chronic anterior shoulder instability. To allow evaluation of the IGHL without inducing apprehension, we developed a new clinical

test, the hyper extension-internal rotation ([HERI] for the *hyper extension rotation interne* in French) test. Fig. 1 shows the range of extension in degrees ( $\alpha$  angle) of a normal shoulder and Fig. 2 an injury to the anterior band and axillary pouch during shoulder dislocation. This injury can cause chronic anterior instability with a potential increase in the range of gleno-humeral extension, represented by the  $\alpha_2$  angle. The HERI test puts the IGHL and inferior capsule under tension while allowing the examiner to evaluate the range of gleno-humeral extension with no risk of dislocation. During the HERI test, the side-to-side difference in gleno-humeral extension range is due to gleno-humeral joint laxity and to injuries affecting the antero-inferior capsule and ligament complex.

Hyperextension of the shoulder places strain on the capsule and ligaments and displaces the humerus upwards. Internal rotation applies the humeral head to the glenoid cavity, thereby preventing alignment of post-traumatic bony defects (Fig. 3). Thus, combining hyperextension and internal rotation demonstrates anterior

\* Corresponding author.

E-mail address: [lafosse.thibault@gmail.com](mailto:lafosse.thibault@gmail.com) (T. Lafosse).

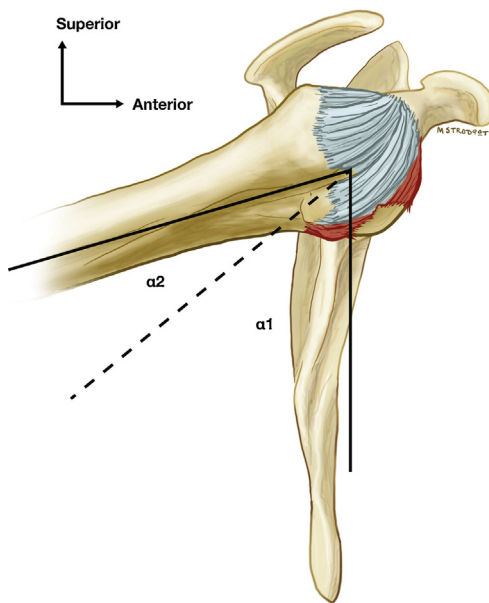


**Fig. 1.** Gleno-humeral joint in extension and internal rotation, with the inferior capsule and inferior gleno-humeral ligament intact. The  $\alpha_1$  angle is the normal extension angle during the HERI test.

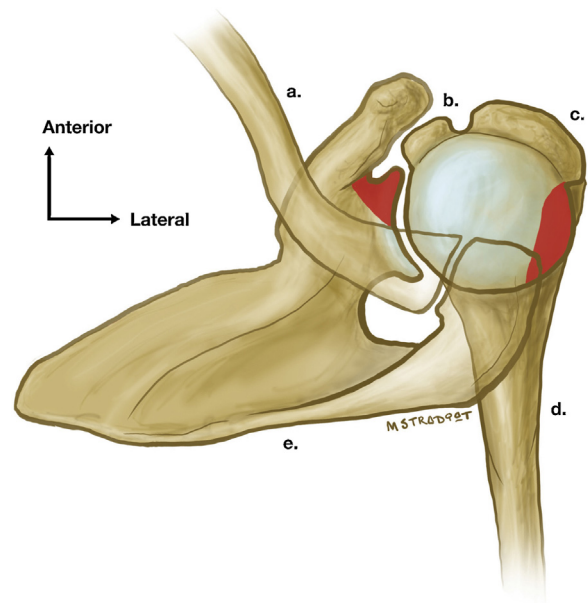
gleno-humeral laxity but induces neither apprehension nor a risk of dislocation.

To validate the principle underlying the HERI test, we conducted both a cadaver study and a clinical study of potential associations linking an increase in the range of gleno-humeral extension and damage to the antero-inferior capsule and ligament complex [2].

The objective of this study was to describe a new clinical manoeuvre designed to complement existing tests for anterior gleno-humeral instability. The study hypothesis was that the HERI test is easy to perform and reproducible, induces no risk of gleno-humeral dislocation during the manoeuvre, and causes no apprehension in the patients.



**Fig. 2.** Gleno-humeral joint in extension and internal rotation, with a traumatic injury to the inferior capsule and inferior gleno-humeral ligament. This injury results in a larger extension angle ( $\alpha_2$ ) during the HERI test.



**Fig. 3.** Gleno-humeral joint viewed from above: illustration of the combined internal rotation and extension, which ensures stability of the gleno-humeral joint by placing the bony defects in the humerus and glenoid opposite each other: a: clavicle; b: lesser tuberosity; c: greater tuberosity; d: humeral shaft; e: spine of the scapula.

## 2. Material and method

### 2.1. Cadaver study

Fresh cadaver shoulders were supplied by the pathology laboratory of the Paris Hospital School of Surgery. Shoulders with evidence of surgery or disease were not eligible. The same operator dissected all the specimens.

#### 2.1.1. Photographs

Photographs of each dissection were taken using a digital reflex camera mounted on a tripod. Focus, zoom, and distance were standardised. For each specimen, the gleno-humeral joint was at the centre of the photograph. We used software designed to process photographic images to analyse the photographs and to confirm the accuracy of the measurements performed on each specimen during dissection.

#### 2.1.2. Conduct of the dissection

Each specimen was positioned with the back of the shoulder on the table. The scapula was placed at the edge of the table to eliminate movements of the scapulo-thoracic joint. The upper limb was placed away from the edge of the table and allowed to hang freely under the effect of gravity. Under these conditions, the gleno-humeral joint was in hyperextension and internal rotation.

We developed a simple method for directly measuring the angle of gleno-humeral extension (Fig. 4). One long pin was inserted at the centre of rotation of the humerus and another along the intercondylar line at the distal humerus to create two points of reference. A plumb line hanging from the proximal pin visualised the vertical axis and a line connecting the two pins visualised the axis of the arm. The angle between these two lines was the angle of gleno-humeral joint extension, which was measured using a goniometer (Fig. 4). Photographs were taken and used to check the accuracy of the direct measurements, as explained above.

For each specimen, the extension angle was measured before starting the dissection. The integrity of the native IGHL was checked. The delto-pectoral approach was used and the lower and

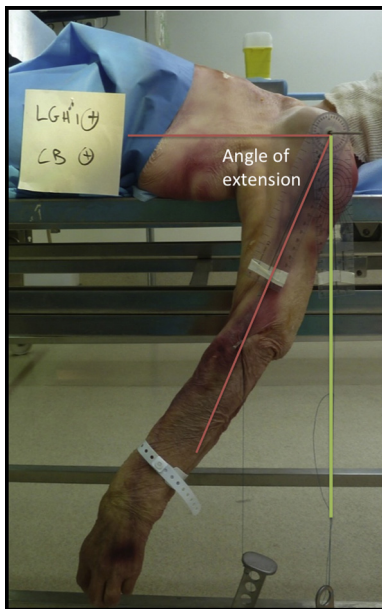


Fig. 4. Cadaver study: the extension angle was measured using a goniometer.

upper edges of the subscapularis (SSc) muscle were exposed (Fig. 5). The interval between the anterior capsule and posterior edge of the SSc was dissected (Fig. 6), taking care to spare the attachment of the SSc, which is not usually injured by gleno-humeral dislocation. Then, the inferior capsule and IGHL were cut at the level of the joint line, from 4 o'clock to 7 o'clock for a right shoulder (Fig. 7). All other structures of the shoulder were left intact. We then performed a second measurement of the gleno-humeral extension angle, and we took a new photograph to check the accuracy of the direct measurement. Fig. 8 shows the extension angles before and after section of the inferior capsule and IGHL.

### 2.1.3. Description of the clinical hyper extension-internal rotation (HERI) test (Fig. 9)

The patient stands in front of the examiner. To perform the HERI test and to measure the gleno-humeral extension angle of

the right shoulder, the examiner places his left elbow against the patient's left scapula and maximally elevates the patient's left upper limb to lock the thoracic spine and prevent the patient from bending forwards while also locking both scapulo-thoracic joints. The examiner then grasps the patient's right forearm, pulling it backwards and in pronation with the elbow extended, thereby inducing hyperextension and internal rotation of the patient's right gleno-humeral joint. Gleno-humeral dislocation is due to alignment followed by engagement of lesions in the glenoid and humerus. Internal rotation of the gleno-humeral joint prevents the alignment of any such lesions. The examiner increases the degree of hyperextension until a hard resistance is felt, indicating maximal gleno-humeral extension. This sensation should be felt in the absence of thoracic-spine flexion or motion in the scapulo-thoracic joint, which are both normally prevented by the elbow of the examiner placed against the left scapula and the elevation of the patient's left upper limb. When the right gleno-humeral joint is maximally extended, the extension angle is measured and any pain or apprehension reported by the patient is recorded. The HERI test should be performed on both sides and the results of the two tests compared.

### 2.2. Clinical study

Our cadaver study showed a significant difference between the gleno-humeral extension angles measured before versus after isolated section of the inferior capsule and IGHL. This result prompted us to conduct a prospective clinical study aimed at validating the HERI test in our patients seen for chronic anterior shoulder instability. In each of these patients, the HERI test was performed on both sides and the extension angle values were compared between the normal and abnormal sides.

Inclusion criteria were unilateral chronic anterior shoulder instability with a normal contralateral shoulder and no history of surgery on either side. Apprehension or pain during the HERI test was not an exclusion criterion.

The surgeon in charge tested both shoulders, starting with the normal side. During this first test, another surgeon took a side-view photograph centred on the gleno-humeral joint. The patient then made a 180° turn around an imaginary vertical axis, whereas the surgeon taking the photographs remained in the same place.

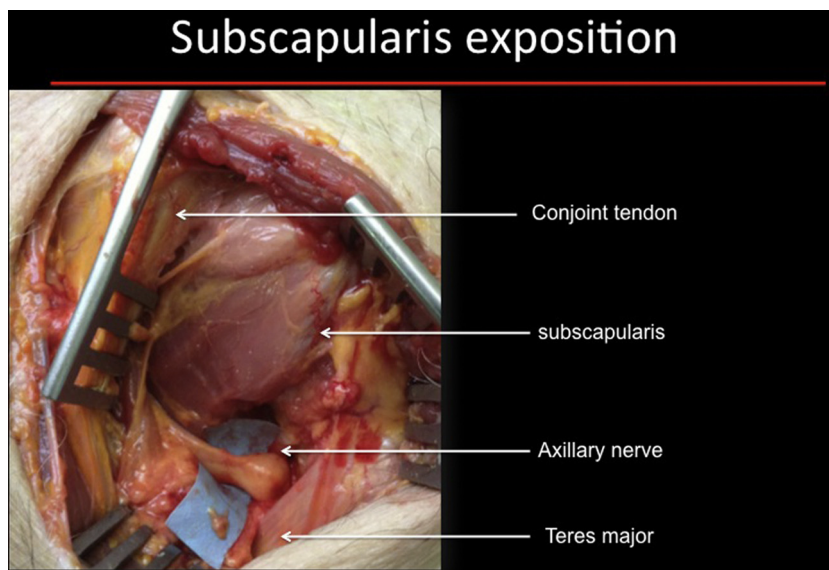


Fig. 5. Delto-pectoral approach and exposure of the upper and lower edges of the subscapularis.



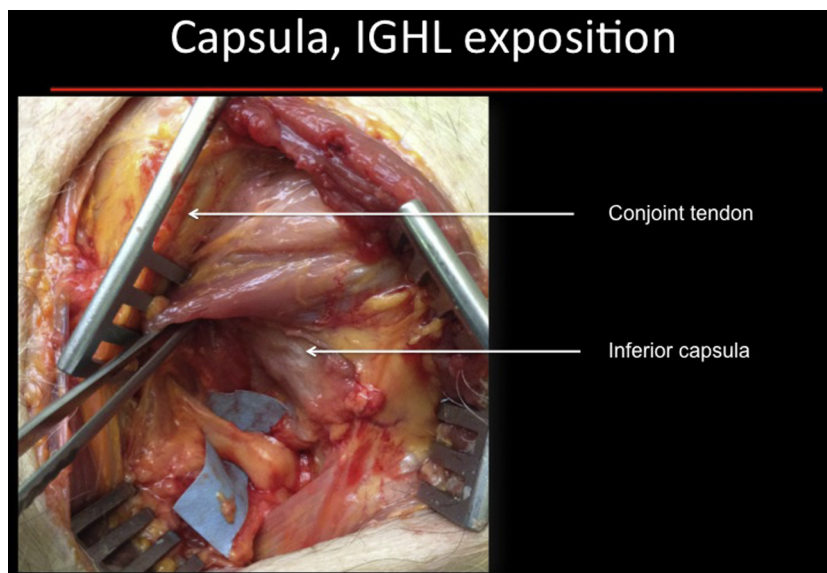


Fig. 6. Exposure of the interval between the anterior capsule and the posterior edge of the subscapularis muscle. IGHL: inferior gleno-humeral ligament.

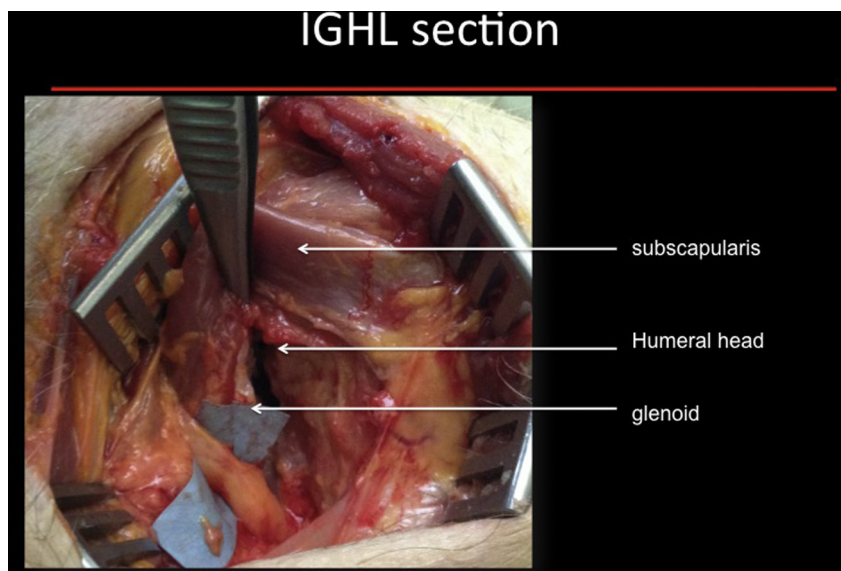


Fig. 7. Section of the IGHL and inferior capsule to simulate the capsulo-ligamentous injury caused by anterior shoulder dislocation. IGHL: inferior gleno-humeral ligament.

The HERI test was done on the abnormal shoulder, and a second photograph was taken. Fig. 10 describes this protocol.

An alternative method for measuring the difference in gleno-humeral extension angles between the normal and abnormal sides in everyday practice is to record the height of the examiner's hand holding the patient's wrist, when it is pulling the patient's upper limb backwards to achieve maximal gleno-humeral extension. The hand is higher on the abnormal than on the normal side (Fig. 11).

For each patient, the gleno-humeral extension angle was measured directly during testing, using a goniometer, and the value obtained was compared to that on the corresponding photograph (Fig. 12). The remainder of the physical examination was then performed.

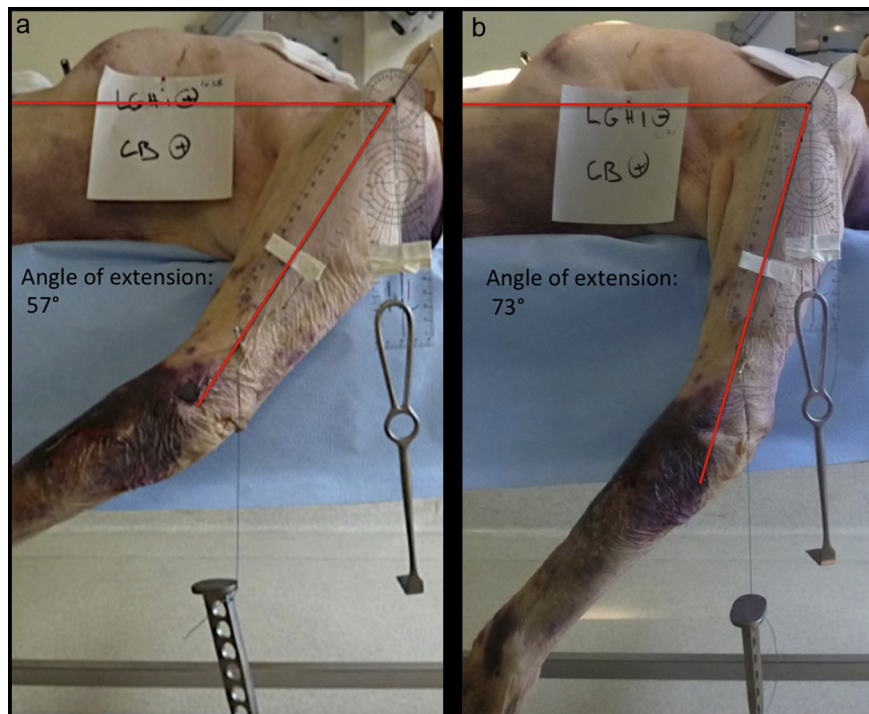
We sought to identify factors associated with the extension angle measured during the HERI test. To this end, we separated the patients into eight groups based on whether the side-to-side difference was  $-5^\circ$ ,  $0^\circ$ ,  $5^\circ$ ,  $15^\circ$ ,  $20^\circ$ ,  $30^\circ$ , or  $40^\circ$ . We then

performed within-group and between-group comparisons to evaluate whether the radiological bony lesions and the occurrence of pain or apprehension during the HERI test were associated with the side-to-side difference [3]. We used plain radiographs and computed tomography images to classify the radiological lesions according to Bigliani et al. [4].

### 3. Results

#### 3.1. Cadaver study

We dissected 14 cadaver shoulders, 8 from males and 6 from females. Table 1 reports the extension angle values. The mean extension angle was  $59^\circ$  ( $54^\circ$ – $60^\circ$ ) before isolated section of the IGHL and inferior capsule. After section, the mean value increased to  $73.5^\circ$  ( $65^\circ$ – $76^\circ$ ), yielding a mean absolute difference of  $14.5^\circ$  (95%CI, 13.4–15.6; range,  $11^\circ$ – $18^\circ$ ) ( $P < 0.001$  [ $1.25749^E-13$ ],



**Fig. 8.** Extension angles measured before (a) and after (b) section of the inferior capsule and inferior gleno-humeral ligament. Note the marked increase in the angle value after the experimental injury.

paired Student's *t* test). The mean relative difference was a 24% (20%–27%) increase after isolated section of the inferior capsule and IGHL.

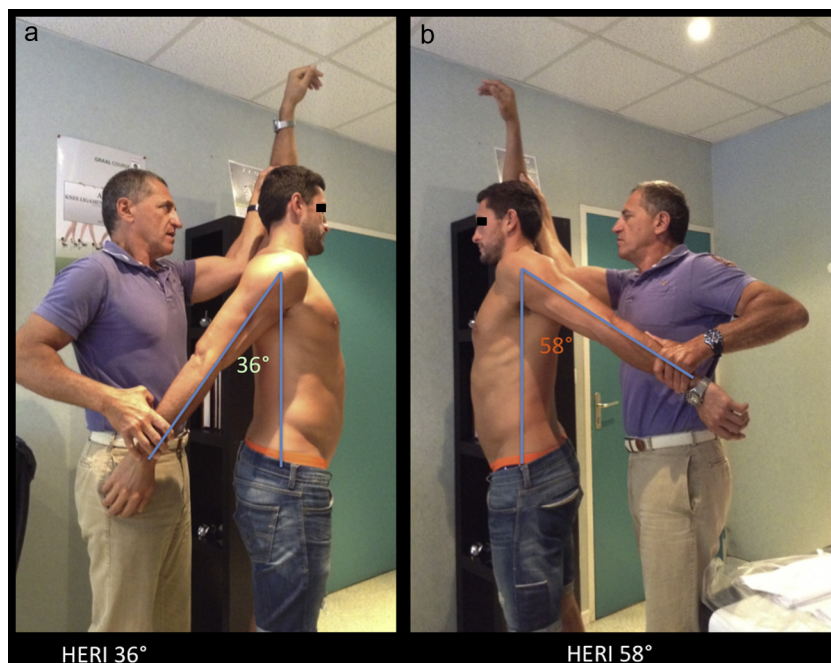
### 3.2. Clinical study

The prospective clinical study included 50 patients, 41 males and 9 females, with unilateral chronic anterior instability of the shoulder and no history of shoulder surgery before the study.

**Table 2** reports their level of sports: 16 patients participated in competitive and 32 in recreational sports, whereas 2 had no sports activities.

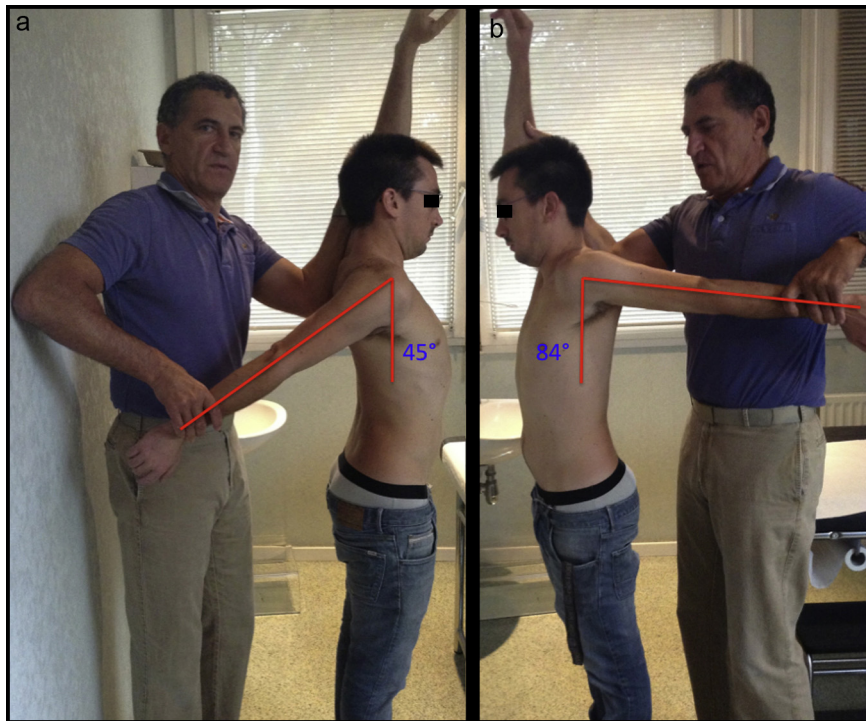**Table 3** shows the type of shoulder instability events: 9 patients had subluxation episodes without dislocation, 21 had dislocation episodes without subluxation, and 20 had both subluxation and dislocation episodes.

Of the 29 patients with a history of subluxation (with or without dislocation), 14 reported fewer than five episodes, 4 five to ten



**Fig. 9.** HERI test on the normal side (a) and on the abnormal side (b).






**Fig. 10.** HEIR test performed on the normal side (a) then on the abnormal side (b). Comparison of the two values then showed that the extension angle is larger by 39° on the abnormal side.

episodes, and 11 more than 10 episodes. Of the 41 patients with a history of dislocation, 37 reported fewer than five episodes, 3 five to ten episodes, and 1 more than ten episodes. These data are shown in Table 4.

During the HEIR test, the mean extension angle on the normal side was 65° (30°–90°), compared to 79° (40°–100°) on the abnormal side. The mean absolute difference was 14.5° (95%CI, 11.8–17.2; range, –5° to 45°) ( $P < 0.001$  [1.29245<sup>E</sup>–14], paired Student's *t* test) (Table 5).

When we analysed individual values, we found that 2 (4%) patients had smaller extension angle values on the abnormal side (80°) than on the normal side (85°) during the HEIR test. In 5 (9.8%) other patients, the two values were identical. The remaining 43 (86%) patients had a larger extension angle value on the abnormal than on the normal side. Among these 43 patients, the differences were distributed as follows: 5°, 1 (1/43, 2.32%) patient; 10° to 15°, 21 (48.8%) patients; 15° to 25°, 16 (37.2%) patients; and >25°, 5 (11.62%) patients (Table 6).



**Fig. 11.** The HEIR test and corresponding extension angle values: (a) normal side; (b) abnormal side. The side-to-side difference can be estimated by comparing the height of the hand of the hyperextended limb relative to the body of the examiner.

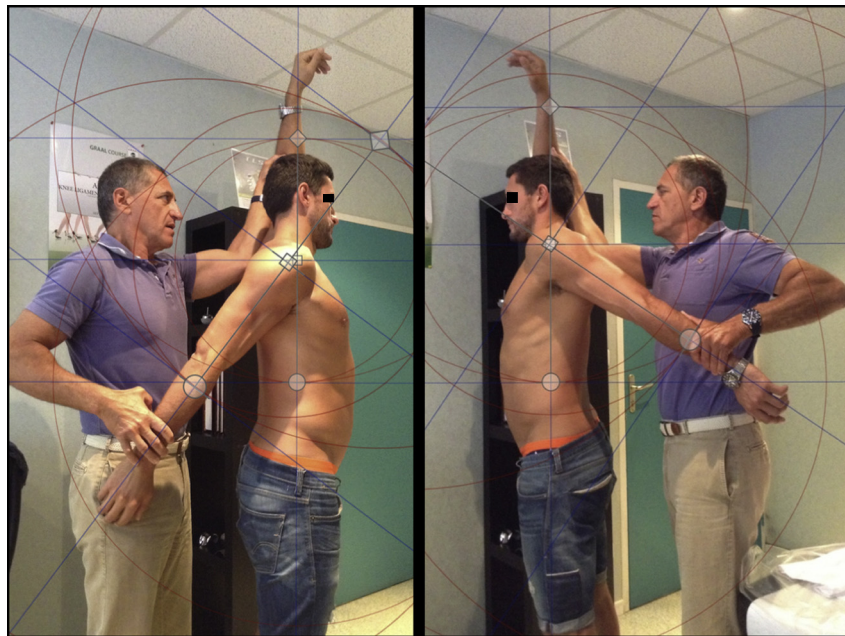


Fig. 12. Illustration of the method used to measure the extension angles on a photograph using specialised software: a: normal side; b: abnormal side.

**Table 1**  
 Extension angle values (°) during the HEIR test performed on cadaver shoulders before and after section of the inferior gleno-humeral ligament (IGHL).

Specimen #	IGHL+	IGHL-	Difference between extension angle values (°)
1	60	75	15
2	60	76	16
3	59	73	14
4	54	65	11
5	61	74	13
6	60	76	16
7	61	74	13
8	60	73	13
9	58	72	14
10	57	73	16
11	59	74	15
12	60	76	16
13	59	77	18
14	58	71	13
Mean	59.00	73.50	14.50

**Table 2**  
 Level of sports.

Level of sport	Number of patients
Competitive	16
Recreational	32
None	2

**Table 3**  
 Number and type of shoulder instability events.

Events	Number of patients
Subluxation and dislocation	20
Subluxation without dislocation	9
Dislocation without subluxation	21

**Table 4**  
 Distribution of the numbers of episodes of shoulder subluxation and dislocation.

Number of episodes	Number of subluxations	Number of dislocations
<5	14	37
5 to ≤10	4	3
>10	11	1

We found no association between the type of instability event (subluxation and/or dislocation) and the extension angle increase on the abnormal side compared to the normal side during the HEIR test. Thus, there was no evidence that the type of instability event might predict the extension angle increase on the abnormal side during the HEIR test. Similarly, the extension angle difference did not seem to provide information on the type of instability event [5]. The two parameters seem independent from each other.

#### 4. Discussion

When evaluating patients with chronic anterior shoulder instability, the physical examination is crucial. In the vast majority of patients, the physical findings provide a detailed diagnosis, and further investigations are needed only for confirmation. In patients with shoulder instability, the goal of clinical tests is to detect weakness of the capsule and ligaments responsible for laxity of the gleno-humeral joint [6]. These soft-tissue lesions are independent from the bony lesions to the humerus or glenoid, which are readily identified by imaging studies. The role for the inferior capsule and IGHL in stabilising the gleno-humeral joint is crucial and probably more significant than that of the capsulo-labral complex. Lesions to these two structures therefore have a severe impact, causing a greater degree of antero-inferior instability than does an isolated Bankart lesion [7,8]. Availability of a clinical tool for evaluating the integrity of the inferior capsule and IGHL is clearly a necessity. The abnormalities detected by testing are subtle, and care should therefore be taken to ensure that the patient is at ease, relaxed, and free of pain and apprehension. Because patient comfort is unaffected by the HERI test despite the shoulder instability, this test is a powerful, valuable, and accurate diagnostic tool. The test causes no feelings of apprehension and leaves the patient calm and relaxed, allowing accurate measurements of the extension angles and assessments of gleno-humeral laxity. Objective physical findings can thus be collected, with no influence of subjective factors such as pain, apprehension, or defensive contractions, which often bias the results of the current tests for shoulder instability.

We used two main investigative approaches to evaluate the efficacy of the HERI test. Both the cadaver study and the clinical study showed a mean 14.5° increase in the extension angle during the

**Table 5**  
Value of the extension angles measured in 50 patients on the normal and abnormal sides.

Patient #	Extension angle values (°) during the HERI test		
	Abnormal side	Normal side	Difference
1	80	50	30
2	80	70	10
3	60	50	10
4	90	80	10
5	100	90	10
6	100	90	10
7	90	90	0
8	85	70	15
9	65	50	15
10	60	60	0
11	70	50	20
12	80	60	20
13	90	60	30
14	80	60	20
15	80	60	20
16	60	50	10
17	40	30	10
18	60	45	15
19	90	80	10
20	80	80	0
21	80	60	20
22	70	55	15
23	80	80	0
24	80	65	15
25	90	80	10
26	50	40	10
27	100	80	20
28	80	60	20
29	90	90	0
30	90	70	20
31	90	70	20
32	80	70	10
33	90	60	30
34	80	60	20
35	90	80	10
36	90	85	5
37	55	45	10
38	100	90	10
39	90	75	15
40	60	30	30
41	100	80	20
42	80	60	20
43	80	60	20
44	80	85	-5
45	60	45	15
46	70	50	20
47	60	40	20
48	90	45	45
49	80	60	20
50	80	85	-5
MEAN	79	65	14.5

HERI test on abnormal shoulders. Whereas the mean difference was the same in the two parts of our study, the maximal extension angle values differed. One possible explanation is that gleno-humeral extension was obtained by gravity pulling down on the upper limb in the cadaver study and by a force applied by the examiner in the clinical study. One would expect this force to be greater than the gravitational pull.

In the clinical study, the extension angle on the abnormal side was at least 10° greater than on the normal side in 82.3% of patients. These values are consistent with those reported by Gagey and Gagey in their 2001 report about the hyper abduction test: 85% of patients with anterior shoulder instability had 105° of passive motion on the abnormal side compared to 90° on the normal side [1].

In 5 (9.8%) of our patients, the extension angles were the same on the abnormal and normal sides: 60°, 80°, 80°, 90° and 90°, respectively. Although we have no clear explanation to this finding,

**Table 6**  
Radiological abnormalities according to the extension angle difference between the normal and abnormal sides. Radiological lesions were classified according to Bigliani et al. [4].

Difference in extension angles	Humeral defect	Glenoid defect
-5°	n	1
-5°	s	0
0°	<b>n</b>	<b>3a</b>
0°	l	1
0°	l	3b
0°	s	3a
0°	n	0
5°	l	1
10°	<b>l</b>	<b>3a</b>
10°	<b>n</b>	<b>0</b>
10°	<b>m</b>	<b>3a</b>
10°	<b>s</b>	<b>3b</b>
10°	<b>s</b>	<b>3a</b>
10°	s	2
10°	s	3b
10°	s	3a
10°	s	1
10°	m	2
10°	n	1
10°	s	0
10°	m	2
10°	m	3a
15°	<b>s</b>	<b>3a</b>
15°	m	2
15°	s	3a
15°	s	2
15°	s	1
15°	s	3a
15°	n	1
20°	s	3a
20°	s	1
20°	m	0
20°	n	0
20°	l	2
20°	s	n
20°	l	1
20°	l	2
20°	m	2
20°	s	3a
20°	n	3a
20°	l	1
20°	s	2
20°	s	1
20°	s	1
20°	s	2
30°	<b>s</b>	<b>3a</b>
30°	s	1
30°	m	2
30°	n	0
45°	m	3a

Humeral defects: 0, none; s, small; m, medium-sized; l, large.  
Glenoid fossa defects: 0, none; 1, displaced avulsion fracture with capsule attachment; 2, non-union of the glenoid fragment, which is displaced medially; 3a, erosion of the inferior edge of the glenoid cavity, with a defect <25%; 3b, erosion of the inferior edge of the glenoid cavity, with a defect ≥ 25%.

several hypotheses can be put forward. The most likely in our opinion is that these patients had minimal capsule and ligament injuries with a small extension angle increase that was below the detection threshold of the test. Alternatively, the test may have been performed improperly in these patients, although this seems highly unlikely given the considerable experience of the examiner with the HERI test. A third hypothesis is that these patients had hyperlaxity responsible for an extension angle increase on the normal side similar in magnitude to that caused by an IGH injury in a patient without hyperlaxity. Assessing this hypothesis would require determining the extension angle during the HERI that defines hyperlaxity, as done by Gagey and Gagey with a group of normal controls. The absence of a control group is a limitation of our study.



Two patients reported apprehension during the HERI test. Normally, this test does not induce apprehension. Both patients had an extension angle difference of only 5° between the two shoulders during the HERI test. Both had experienced an instability event within 10 days before testing. In this specific situation, the HERI might induce pain, a defensive contraction, and apprehension. Thus, the results of the HERI test may be challenging to interpret in patients with a recent instability event.

Regarding our protocol for performing the HERI test, we believe that maximal elevation of the contralateral upper limb is crucial. This manoeuvre prevents movement in the thoracic spine and scapulo-thoracic joint. Without it, flexion of the thoracic spine or movement in the scapulo-thoracic joint might spuriously increase the extension angle. Patient apprehension also deserves discussion. None of our patients reported apprehension when the affected limb was maximally elevated during the HERI test on the normal shoulder. In this position, rotation was neutral and the upper limb was in strictly forward elevation, with no abduction. Consequently, there was no risk of dislocation, which explains the absence of apprehension.

We have not yet investigated the normal extension angle values during the HERI test. In the present study, we compared the extension angles between the normal and abnormal sides. As mentioned above, there is a need for further evaluation of extension angle values in a study including a group of healthy controls, to determine the normal mean extension angle during the HERI test, as performed by Gagey and Gagey for the hyper abduction test [1].

However, we believe the focus of attention should be the difference between the extension angles on the two sides. Similar to Gagey and Gagey, we found a mean difference of about 15° in patients with damage to the IGHL. Rather than a normal value, the difference is the clinically relevant variable, and the HERI test must therefore be performed on both sides for purposes of comparison.

Given our radiological data, it is reasonable to conclude that bony defects in the humeral or glenoid articular surfaces have no significant impact on HERI test results. During this test, the maximal internal rotation of the arm places the humeral and glenoid lesions (Hill-Sachs lesion and glenoid notch) opposite each other, preventing their engagement. This concept has been illustrated clearly by Yamamoto et al. [9], who described the zone of contact, or glenoid track, in patients with both humeral and glenoid bony defects. When the arm is externally rotated and abducted, a Hill-Sachs lesion cannot engage with the glenoid rim as long as it remains within the glenoid track. If the Hill-Sachs lesion is outside the glenoid track, in contrast, it may engage with the anterior glenoid rim, resulting in anterior shoulder dislocation. The HERI places the gleno-humeral joint in a position of stability, thereby ensuring that any Hill-Sachs lesion remains within the glenoid track: the internal rotation shifts the Hill-Sachs lesion away from the glenoid fossa and applies the intact anterior humeral surface to the glenoid cavity, thus ensuring continuous joint contact during the passive extension of the arm. The risk of gleno-humeral subluxation or dislocation is therefore minimal [10].

The SSc muscle also makes a major contribution to gleno-humeral stability during the HERI test. The combination of extension and internal rotation puts strain on the SSc muscle, particularly its inferior fibres. The SSc muscle thus forms a sling anterior and inferior to the gleno-humeral joint, precluding anterior translation of the humeral head and therefore preventing dislocation. During the hyper abduction test [1], the SSc muscle is pulled upwards, in the opposite direction to that responsible for the protective antero-inferior sling effect seen during the HERI test. The apprehension triggered by the hyper abduction test is easy to understand, since the SSc muscle is one of the few intact structures still capable of preventing dislocation. In the study by Gagey and Gagey [1], passive abduction caused apprehension in 15% of the

patients. This effect has led many physicians to discard this test in everyday practice. The study [1] also establishes that an isolated antero-inferior capsulo-labral lesion is probably not sufficient to result in gleno-humeral dislocation during the Hyper Abduction test. Pouliart et al. reported that the usual antero-inferior labral lesion (typical Bankart lesion) does not allow antero-inferior gleno-humeral dislocation. The lesion must show considerable superior and posterior extension before the ability of the capsule to prevent dislocation is overwhelmed and dislocation occurs [8]. Drury et al. identified many factors associated with the risk of recurrent gleno-humeral dislocation but found that shoulder stability was chiefly ensured by the inferior capsulo-ligamentous complex (inferior capsule and IGHL) [11].

Our understanding of the biomechanics of shoulder movements and stability has benefited from knowledge about the organisation of the ligaments in the gleno-humeral joint, which exert both static and dynamic effects [12]. The gleno-humeral joint has no true ligaments, i.e., ligaments that exist as separate entities. Instead, the gleno-humeral ligaments are reinforcements of the joint capsule [13]. The degree of tension applied to these ligaments varies with joint position, so that no ligament is continuously under tension and all ligaments are slack in the resting position. This point explains the complexity of shoulder physiology and the absence of a simple clinical test comparable to the Lachman test and valgus/varus stress tests at the knee. A simple basic analysis of shoulder kinetics is difficult to perform. Consequently, developing a test for shoulder stability that is simple, easy to replicate, and both sensitive and specific for ligament damage is a challenging task.

In this study, the contralateral normal shoulders served as the control group. We therefore excluded patients with abnormalities of the contralateral shoulder detected either by our physical examination or by the medical history interview. Although we took great care to obtain accurate measurements during both the cadaver and the clinical parts of our study, intra-observer variability may have occurred. All measurements and data collection were performed by the same observer to limit variability [14].

Our study has several limitations. As indicated above we did not recruit controls free of shoulder abnormalities on both sides. Useful additional information could be obtained by studying a population of controls with no apparent shoulder abnormalities. Assessment of HERI test results in this population would provide normal extension values and determine whether side-to-side differences exist in healthy individuals. Such a study would determine the normal extension angle value and may allow a definition of laxity based on the extension angle values, as reported by Gagey and Gagey [1]. We simply compared the two shoulders, one believed to be normal and the other abnormal by both the examiner and the patient.

In everyday practice, a single examiner cannot easily measure the extension angle. To perform the test, the examiner stands behind the patient, whereas the extension angle during the HERI test is best measured when the patient is viewed from the side. Furthermore, the examiner needs both hands for the manoeuvre and, consequently, cannot use a goniometer [15]. To circumvent this difficulty, the extension angle can be assessed indirectly by determining the height of the patient's hand on the side the examiner is maintaining in extension, as shown in Fig. 8. To improve measurement accuracy and scientific validity, a second person performed the measurements in our study.

Nevertheless, we believe the HERI test is as accurate as the other clinical tests used in everyday practice to assess shoulder instability and for which a goniometer is rarely needed.

## 5. Conclusion

The HERI test is an innovative clinical tool capable of demonstrating lesions of the inferior capsule and IGHL in patients with

chronic anterior shoulder instability. Our dual cadaver and clinical approach showed that lesions of the inferior capsule and IGHL are associated with a 14.5° increase in the gleno-humeral extension angle during the HERI test, compared to the contralateral normal side. This test does not induce apprehension in the patient because it carries no risk of shoulder dislocation, even in the presence of major bony defects in the humerus or glenoid fossa. Thus, the HERI test provides an evaluation of the inferior capsule and IGHL independently from any influence of bony lesions.

We believe the HERI test is a powerful tool that constitutes a valuable addition to the diagnostic armamentarium used by surgeons to evaluate anterior and inferior capsulo-ligamentous lesions of the gleno-humeral joint in patients with chronic anterior shoulder instability. The reproducibility of the HERI test needs to be evaluated by measuring intra-observer and inter-observer variability in the measurements obtained during the HERI test. Furthermore, a study should be performed to compare the HERI test and the Hyper Abduction test.

#### Disclosure of interest

The authors declare that they have no competing interest.

#### Acknowledgements

We thank Véronique Ladret for performing the statistical analysis, Dr. Yousef Shishani for valuable help with this study and Mark Stradiot ([markstradiot@gmail.com](mailto:markstradiot@gmail.com)) for illustrations.

#### References

- [1] Gagey OJ, Gagey N. The hyperabduction test, an assessment of the laxity of the inferior glenohumeral ligament. *J Bone Joint Surg Br* 2001;83:69–74.

- [2] Walch G. How to deal with hyperlaxity in shoulder instability? *Orthop Traumatol Surg Res* 2011;97:S453–8.
- [3] Diederichs G, Seim H, Meyer H, Issever AS, Link TM, Schröder RJ, et al. CT-based patient-specific modeling of glenoid rim defects: a feasibility study. *AJR Am J Roentgenol* 2008;191:1406–11.
- [4] Bigliani LU, Newton PM, Steinmann SP, Connor PM, McIlveen SJ. Glenoid rim lesions associated with recurrent anterior dislocation of the shoulder. *Am J Sports Med* 1998;26:41–5.
- [5] Itoi E, Yamamoto N, Kurokawa D, Sano H. Bone loss in anterior instability. *Curr Rev Musculoskelet Med* 2013;6:88–94.
- [6] Field LD, Bokor DJ, Savoie III FH. Humeral and glenoid detachment of the anterior inferior glenohumeral ligament: a cause of anterior shoulder instability. *J Shoulder Elbow Surg* 1997;6:6–10.
- [7] Pouliart N, Gagey O. Simulated humeral avulsion of the glenohumeral ligaments: a new instability model. *J Shoulder Elbow Surg* 2006;15:728–35.
- [8] Pouliart N, Marmor S, Gagey O. Simulated capsulolabral lesion in cadavers: dislocation does not result from a Bankart lesion only. *Arthrosc J Arthrosc Relat Surg* 2006;22:748–54.
- [9] Yamamoto N, Itoi E, Abe H, Minagawa H, Seki N, Shimada Y, et al. Contact between the glenoid and the humeral head in abduction, external rotation, and horizontal extension: a new concept of glenoid track. *J Shoulder Elbow Surg* 2007;16:649–56.
- [10] Saito H, Itoi E, Sugaya H, Minagawa H, Yamamoto N, Tuoheti Y. Location of the glenoid defect in shoulders with recurrent anterior dislocation. *Am J Sports Med* 2005;33:889–93.
- [11] Drury NJ, Ellis BJ, Weiss JA, McMahon PJ, Debski RE. Finding consistent strain distributions in the glenohumeral capsule between two subjects: Implications for development of physical examinations. *J Biomech* 2011;44:607–13.
- [12] Wolf EM, Cheng JC, Dickson K. Humeral avulsion of glenohumeral ligaments as a cause of anterior shoulder instability. *Arthrosc J Arthrosc Relat Surg* 1995;11:600–7.
- [13] Pouliart N, Gagey O. Reconciling arthroscopic and anatomic morphology of the humeral insertion of the inferior glenohumeral ligament. *Arthrosc J Arthrosc Relat Surg* 2005;21:979–84.
- [14] Valentine RE, Lewis JS. Intraobserver reliability of 4 physiologic movements of the shoulder in subjects with and without symptoms. *Arch Phys Med Rehabil* 2006;87:1242–9.
- [15] Ropars M, Fournier A, Campillo B, Bonan I, Delamarche P, Crétuel A, et al. Clinical assessment of external rotation for the diagnosis of anterior shoulder hyperlaxity. *Orthop Traumatol Surg Res* 2010;96:S84–7.