

DISEASES OF THE PERITONEUM AND RETROPERITONEUM

Amanda K. Arrington, MD, and Joseph Kim, MD

Anatomy and Physiology: Peritoneum

ANATOMY

The word *peritoneum* is derived from the Greek terms *peri* (“around”) and *tonos* (“stretching”). The peritoneum, which lines the innermost surface of the abdominal wall and the majority of the abdominal organs, consists of a layer of dense stroma covered on its inner surface by a single sheet of mesothelial cells. In men, the peritoneum is completely enclosed, whereas in women, the peritoneum is open to the exterior only at the ostia of the fallopian tubes. The peritoneum is divided into two components: the parietal and the visceral peritoneum [see Figure 1]. The parietal peritoneum covers the innermost surface of the abdominal walls, the inferior surface of the diaphragm, and the pelvis. The visceral peritoneum, on the other hand, covers the majority of the intraperitoneal organs [see Table 1] and the anterior aspect (only) of the retroperitoneal organs [see Table 1]. As shown in Figure 1, the intraperitoneal organs are suspended by ligaments of peritoneum within the abdomen that have previously been identified by Meyers and colleagues [see Figure 1 and Table 1].¹ The spread of infection, as well as the spread of a primary tumor or metastatic disease, can be predicted based on subdivisions of the abdominal compartments created by these peritoneal ligamentous structures of the abdomen.

The omentum (greater and lesser omentum) is a well-vascularized double fold of peritoneum with fat that contributes to the control of intra-abdominal infection and inflammation. The omentum aids in sealing off perforations (as in perforated ulcer or perforated appendicitis) and controls inflammation (i.e., unruptured appendicitis). Additionally, the omentum delivers phagocytes that destroy unopsonized bacteria. Thus, the omentum has multiple functions in the body’s defense system against infection.

The small bowel mesentery and transverse mesocolon are also complex peritoneal folds that originated from the dorsal and ventral midline mesenteries early in development and are considered part of the peritoneum. The small bowel mesentery suspends the jejunum and ileum from the posterior abdominal wall. This mesentery contains the superior mesenteric vessels, lymph nodes, nerves, and fat tissue. Its root originates at the duodenojejunal junction and extends downward in an oblique direction across the aorta, inferior vena cava, right ureter, and psoas muscle to the right iliac fossa at the ileocecal junction. Across the mesenteric root, the small bowel mesentery is in anatomic continuity with the extraperitoneal anterior pararenal space, thus providing a channel for the spread of disease.² As a result of its shorter length (15 cm) in comparison with the much longer length of the small bowel itself (6 to 8 m), the small bowel mesentery has a pleated appearance along its intestinal border. The

transverse mesocolon, on the other hand, is the mesentery of the transverse colon and suspends this structure from the posterior abdominal wall. The root of the transverse mesocolon extends across the descending duodenum and the head of the pancreas and continues along the inferior border of the body and tail of the pancreas. The transverse mesocolon is continuous with the duodenocolic ligament on the right and with the phrenicocolic and splenorenal ligaments on the left. Finally, the sigmoid mesocolon attaches the sigmoid colon to the posterior pelvic wall. This mesentery, which has an inverted V-shape configuration, with its apex lying anterior to the bifurcation of the left common iliac artery, contains both sigmoid and hemorrhoidal vessels, lymph nodes, nerves, and abundant fat tissue.³

PHYSIOLOGY

The blood supply and innervation of the peritoneum depend on whether it is visceral peritoneum or parietal peritoneum. The blood flow to the visceral peritoneum is supplied by the splanchnic blood vessels, whereas the parietal peritoneum is supplied by intercostal, subcostal, lumbar, and iliac vessels. Correspondingly, the innervation of the two components is divided: the visceral peritoneum is supplied by nonsomatic nerves, whereas the parietal peritoneum is supplied by somatic nerves. This detail is important when evaluating for pain. Visceral pain is poorly localized and vague and is generally caused by stretching, distention, torsion, and twisting motion. On the other hand, parietal pain is caused by direct stimulation of nerve fibers and is described as sharp and well localized.

The peritoneum is a bidirectional, semipermanent bi-membrane that controls the amount of fluid in the peritoneal cavity. The peritoneal cavity typically contains less than 100 mL of sterile peritoneal fluid. This peritoneal fluid may act as both part of the local defense system and a lubricant for intraperitoneal organs. In certain disease states, such as nephrotic syndrome, congestive heart failure, cirrhosis, or portal hypertension, the amount of peritoneal fluid may increase from the normal less than 100 cc protective amount to several liters in volume [see Ascites, below].

Circulation of peritoneal fluid is driven in part by the movement of the diaphragm. The peritoneal cavity can absorb peritoneal fluid through two different systems. Substances smaller than 2 kDa are absorbed through the peritoneal mesothelial venous pores directly into the portal circulation.⁴ Conversely, larger particles (> 2 kDa) are absorbed through the peritoneal mesothelial lymphatics and enter the lymphatic system via the thoracic duct. This particular route of absorption plays an important role in controlling abdominal infections and has been shown to propagate the metastatic spread of certain cancers.

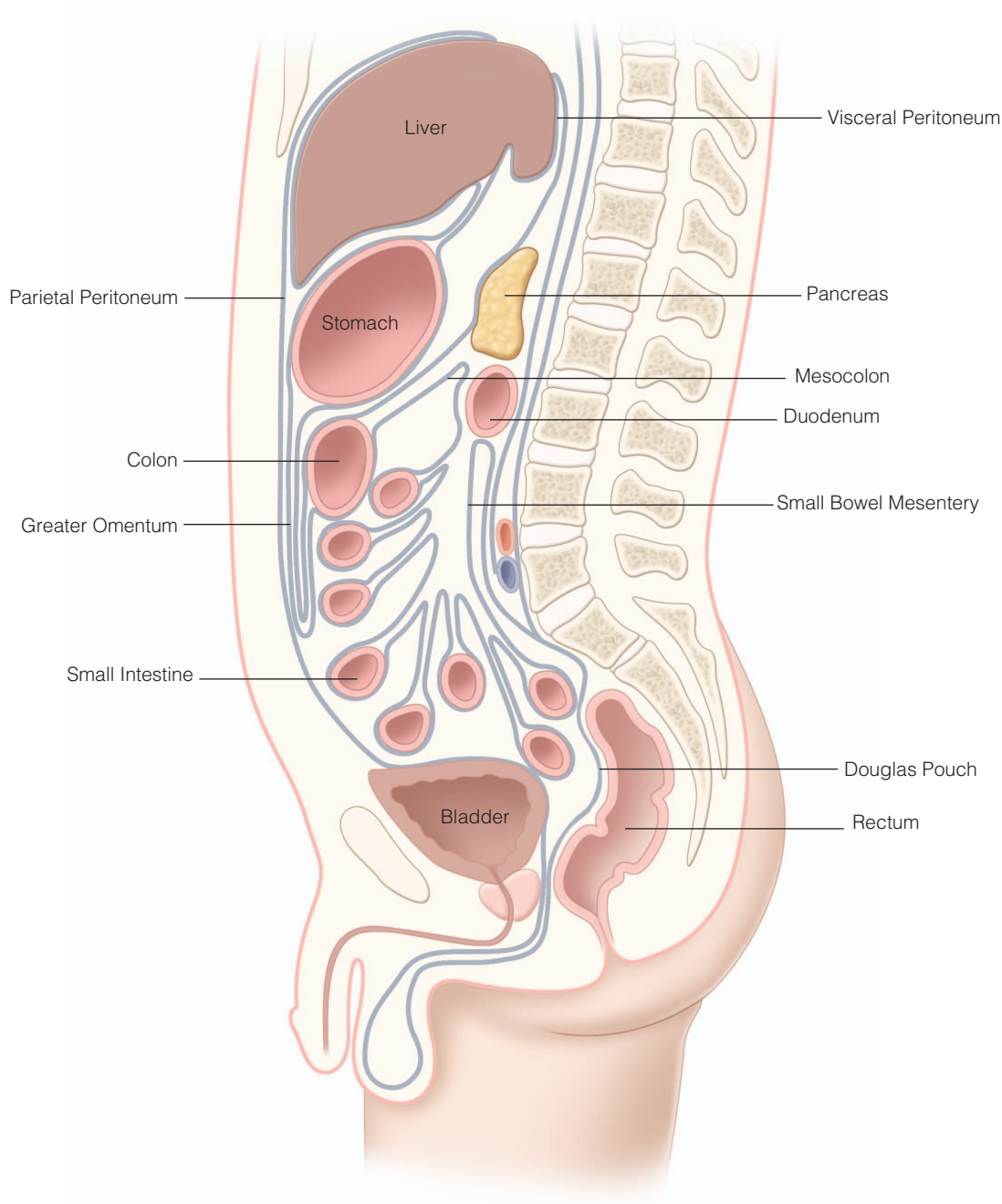


Figure 1 Peritoneal components. The peritoneum consists of parietal peritoneum and visceral peritoneum. Visceral peritoneum covers the surface of intraperitoneal organs. The omentum and mesentery are also peritoneal structures.

Anatomy and Physiology: Retroperitoneum

The retroperitoneum is defined as the space between the posterior parietal peritoneum and the posterior body wall. Although it has no specific delineating anatomic structures, the retroperitoneal space is bound anteriorly by the posterior reflection of the peritoneum, superiorly by the diaphragm, and inferiorly by the levator ani muscles. This space also includes the lumbar fossa, extending from the 12th thoracic spine superiorly to the base of the sacrum and

iliac crest inferiorly. Organs are classified as retroperitoneal in location if they have no peritoneal lining whatsoever or have peritoneum on their anterior surface only [see Table 1]. Furthermore, structures that are not suspended by mesentery in the abdominal cavity and that lie between the parietal peritoneum and the abdominal wall are also classified as retroperitoneal in location; this includes the duodenum, ascending colon, and descending colon [see Figure 2]. Because of the compliance of the anterior border of the

Table 1 Abdominal Components

| |
|--------------------------------------|
| Intraperitoneal organs |
| Gastrointestinal |
| Stomach |
| Small intestine |
| Transverse colon |
| Liver |
| Endocrine |
| Spleen |
| Retroperitoneal structures |
| Gastrointestinal |
| Duodenum |
| Ascending colon |
| Descending colon |
| Pancreas |
| Vascular |
| Inferior vena cava |
| Aorta |
| Lymphatics |
| Iliac arteries |
| Renal |
| Kidneys |
| Ureters |
| Bladder |
| Endocrine |
| Adrenals |
| Sexual |
| Seminal vesicles |
| Vas deferens |
| Ovaries |
| Vagina |
| Other |
| Nerves |
| Peritoneal ligaments and mesenteries |
| Ligaments |
| Splenorenal |
| Gastrohepatic |
| Coronary |
| Hepatoduodenal |
| Falciform |
| Gastrocolic |
| Duodenocolic |
| Gastric splenic |
| Phrenocolic |
| Mesenteries |
| Transverse mesocolon |
| Small bowel mesentery |

retroperitoneum (the posterior parietal peritoneum), retroperitoneal tumors tend to expand anteriorly toward the peritoneal cavity.

The retroperitoneal space is divided into three spaces: the anterior, the posterior, and the retrofascial spaces. The anterior space consists of the second and third segments of the duodenum, the pancreas, and the ascending and descending branches of the colon, whereas the kidneys, the adrenal glands, the aorta, and the inferior vena cava are located in the posterior space.^{5,6} Finally, the retrofascial space, which extends between the transversalis fascia and posterior parietal wall, contains the vertebral column and paravertebral musculature.

Structures contained in the retroperitoneal space, in particular the aorta, the inferior vena cava, the iliac vessels, the kidneys, and the adrenals, can be operatively approached transabdominally or via the retroperitoneal approach.

Retroperitoneal operative approaches may be beneficial for a number of reasons. First, it avoids entrance in to the peritoneum and, thus, decreases manipulation and the risk of injury to intra-abdominal organs. Minimal manipulation of the small intestine, for instance, significantly decreases complications such as postoperative ileus. Given successful avoidance of entering the peritoneum, intra-abdominal adhesions are also minimized.⁷

Diseases of the Peritoneum

ASCITES

Pathophysiology and Etiology

Ascites is the pathologic accumulation of fluid within the peritoneal cavity. The primary cause of nonmalignant ascites accumulation is liver disease (cirrhosis and portal hypertension), which accounts for 85% of cases of ascites in the United States. Other causes of ascites are listed in Table 2 [see Table 2]. In cirrhotic patients, the onset of ascites is an overall poor prognostic factor as patients are more likely to develop spontaneous bacterial peritonitis (SBP), renal (hepatorenal) failure, decreased quality of life, and decreased overall survival.⁸

Accumulation of ascites in patients with cirrhosis is secondary to the combination of renal sodium and water retention with portal hypertension [see Figure 3]. Driven by activation of the renin-angiotensin-aldosterone system, renal sodium retention is the result of proximal and distal renal tubule sodium reabsorption. The renin system is activated in response to decreased circulating blood volume secondary to the redistribution of fluid and accumulation of ascites within the abdomen. Furthermore, in cirrhotic patients, the accumulation and deposition of collagen lead to postsinusoidal vascular obstruction, which eventually results in portal hypertension [search the publication for information on portal hypertension]. Increased hydrostatic pressure within the hepatic sinusoids and the splanchnic vasculature drives the extravasation of fluid from the microvasculature into the extracellular compartment. Ascites then results when the capacity of the lymphatic system to return this accumulation of fluid within the extracellular compartment to the systemic circulation is overloaded.⁹

Although cirrhosis is, by far, the most common cause of ascites, Table 2 lists a number of other etiologies of ascites [see Table 2]. Of note, patients with malignancies develop ascites by one of three mechanisms. First, occlusion of the portal venous system by compression from malignancies, as in liver metastases from colorectal cancer, can cause portal hypertension with resultant ascites. Next, diffuse peritoneal malignancies or metastases (carcinomatosis) can release protein-rich fluid into the peritoneal cavity, which accumulates as ascites. Finally, when tumor burden obstructs the lymphatic drainage system (thoracic duct), resulting in rupture of major lymphatic channels, the leakage of chyle into the peritoneal cavity results in an accumulation of a chylous ascites. This can be seen in cancers such as lymphomas and retroperitoneal tumors, including sarcomas, or due to iatrogenic injury after extensive retroperitoneal dissection.

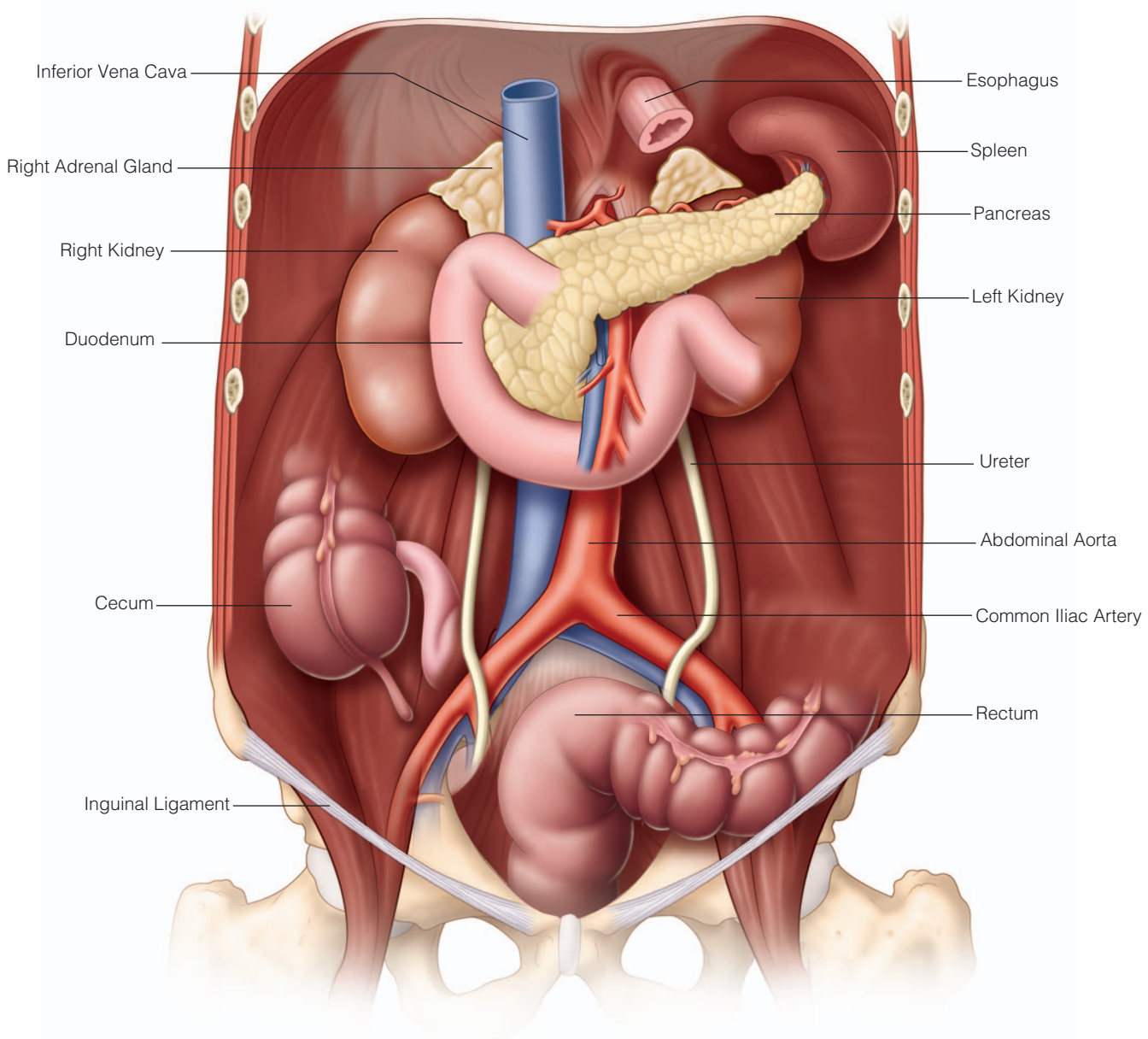


Figure 2 Retroperitoneal structures.

Diagnosis

The diagnosis of ascites is made on the basis of the medical history and the appearance of the abdomen. Approximately 1.5 L of fluid must be present before dullness can be detected by percussion. Because cirrhosis is the most common cause of ascites, evaluation of any physical evidence of cirrhosis is important, such as palmar erythema, dilated abdominal wall collateral veins (varicosities), and multiple spider angiomas. Other systemic causes of ascites, such as congestive heart failure, may also have signs on physical examination (i.e., jugular venous distention).

Paracentesis is beneficial in both diagnosis and treatment. First, paracentesis allows for symptomatic relief of pressure

and/or pain secondary to ascites. Perhaps more importantly, paracentesis for ascitic fluid analysis is the most rapid and cost-effective method of determining the etiology of ascites. Paracentesis can be performed safely in most patients, including those with cirrhosis and mild coagulopathy. Only clinically evident disseminated intravascular coagulation and fibrinolysis are contraindications to paracentesis in patients with ascites.¹⁰

The serum-ascites albumin gradient (SAAG) is the most reliable method for quickly categorizing the various causes of ascites [see Table 3]. This gradient is the difference between serum albumin concentration and ascitic fluid albumin concentration. SAAG values greater than 1.1 g/dL represent

Table 2 Principal Causes of Ascites

| |
|---|
| Portal hypertension |
| Cirrhosis |
| Secondary to alcohol |
| Secondary to hepatitis |
| Secondary to primary sclerosing cholangitis |
| Noncirrhotic causes |
| Portal venous obstruction |
| Multiple hepatic metastases causing obstruction |
| Budd-Chiari syndrome |
| Malignancies |
| Peritoneal carcinomatosis |
| Primary peritoneal malignancies |
| Peritoneal mesothelioma |
| Metastatic disease |
| Pseudomyxoma peritonei |
| Gastrointestinal cancers (gastric, colon, pancreatic) |
| Ovarian cancer |
| Retroperitoneal obstruction of lymphatic system |
| Lymphoma |
| Lymph node metastases |
| Compression from retroperitoneal tumors |
| Cardiac |
| Congestive heart failure |
| Chronic pericardial tamponade |
| Infections |
| Tuberculous peritonitis |
| Other common causes |
| Nephrotic syndrome |
| Bile ascites |
| Pancreatic ascites |
| Pancreatitis |
| Chylous ascites |
| Rare causes |
| Meigs syndrome |
| Vasculitis |
| Hereditary angioedema |
| Kwashiorkor |

ascites in patients with portal hypertension. In addition to analyzing the ascitic fluid albumin level, routine tests sent on ascitic fluid from a paracentesis include cell count, total protein, glucose, Gram stain, and fluid culture [see Table 3]. In the case of suspected malignancy, ascitic fluid should be sent for cytologic examination. Other studies to consider sending on ascitic fluid are shown in Table 3 and are based on the individual case [see Table 3].

PERITONEAL INFECTIONS

Intraperitoneal Abscesses

An intraperitoneal abscess is a contained pocket of infection within the abdominal cavity. Intraperitoneal abscess may be caused by gastrointestinal (GI) perforations, postoperative complications, penetrating trauma, and genitourinary (GU) infections [see Table 4]. The areas in which abscesses commonly occur are defined by the configuration of the peritoneal cavity as compartmentalized by the peritoneal ligaments, small bowel mesentery, and transverse and sigmoid mesocolons. The supracolic compartment, located above the transverse mesocolon, broadly defines the subphrenic spaces, consisting of both the subdiaphragmatic

(suprahepatic) space and the subhepatic space. Possible etiologies of abscesses in this compartment include GI sources (diverticulitis, perforated peptic ulcer), trauma, postoperative complications, and biliary causes. The right subdiaphragmatic space consists of the concavity between the right hemidiaphragm and the dome of the liver, with the inferior limits of this space being the attachments of the coronary and triangular ligaments of the liver. The left subdiaphragmatic space, on the other hand, is the space between the left hemidiaphragm and the spleen. Trauma, postoperative complications after upper abdominal or colon surgery, and gross GI perforations can cause abscesses in this location. The right subhepatic space is located between the undersurfaces of the liver and gallbladder superiorly and the right kidney and mesocolon inferiorly. Perforated appendicitis and gallstone or other biliary disease are frequent causes of abscesses in this space. The left subhepatic space is essentially the lesser sac and is situated behind the lesser omentum and stomach, lying anterior to the pancreas, duodenum, transverse mesocolon, and left kidney. Perforated peptic ulcers and pancreatitis can cause abscesses in the left subphrenic space. The infracolic compartment is located below the transverse mesocolon and includes the pericolic and pelvic cavity. Each lateral paracolic gutter and lower quadrant area communicates freely with the pelvic cavity. However, whereas right paracolic collections may track upward into the subhepatic and subdiaphragmatic spaces, the phrenicocolic ligament hinders fluid migration along the left paracolic gutter into the left subdiaphragmatic area.

An intraperitoneal abscess should be suspected in any patient with a predisposing condition. The typical presenting symptoms of fever, tachycardia, and pain may be mild or absent, especially in patients receiving antibiotics. Prolonged ileus in a patient who has had recent abdominal surgery or peritoneal sepsis, worsening leukocytosis, or nonspecific radiologic abnormality may provide the initial or only sign of an intraperitoneal abscess.

Treatment for an intraperitoneal abscess consists of immediate recognition, initiation of broad-spectrum antibiotics, prompt drainage of the abscess, and identification and control of the primary cause of the abscess (such as GI perforation). Percutaneous drainage is the preferred route for localized intraperitoneal abscesses that are approachable via image guidance. Operative drainage is reserved for intraperitoneal abscesses for which percutaneous drainage is inappropriate or unsuccessful. Drainage may be inappropriate or unsuccessful if there is not a safe radiographic window through which to approach the abscess. Operative drainage may be indicated in cases where there is a persistent focus of infection (e.g., diverticulitis or anastomotic dehiscence) after attempted percutaneous drainage. In cases without evidence of continued soiling, the percutaneous route has the advantage of establishing dependent drainage without contaminating the rest of the peritoneal cavity.

Primary Peritonitis

SBP is the most common cause of primary peritonitis and typically occurs in patients with underlying cirrhosis or portal hypertension and resultant ascites. SBP is defined as an infection of previously sterile ascitic fluid without an apparent intra-abdominal source of infection, in particular,

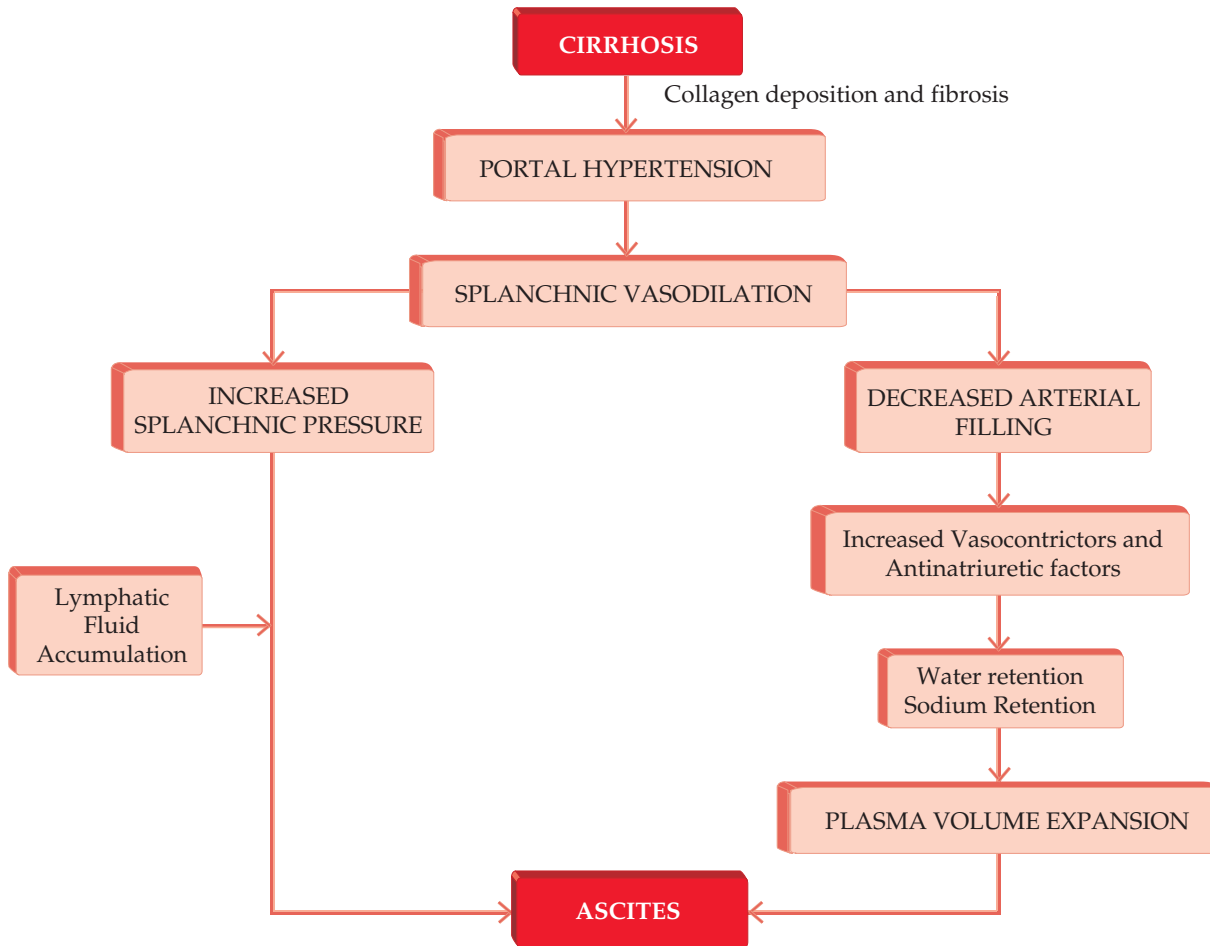


Figure 3 Development of ascites in cirrhotic patients.

without obvious GI perforation. Patients with ascites unrelated to cirrhosis, such as nephrotic syndrome or congestive heart failure, may also develop SBP. SBP results from bacterial, chlamydial, fungal, or mycobacterial infection in the absence of a perforation of the GI or GU tract. This bacterial translocation is facilitated by depression of the hepatic reticuloendothelial system, commonly seen in cirrhotic patients.

SBP can occur in patients with asymptomatic ascites; therefore, the diagnosis should be suspected in all hospitalized cirrhotic patients with ascites exhibiting any symptoms of abdominal pain or abdominal tenderness. SBP should also be considered in patients with fever, leukocytosis, signs of sepsis, renal insufficiency, or a history of hepatic encephalopathy. Diagnosis is made by diagnostic paracentesis and is established by an elevated neutrophil count of the ascitic fluid greater than 250 cells/mL. Peritoneal fluid from the paracentesis should be sent for Gram stain and cultures at the same time. If the neutrophil count is greater than 250 cells/mL, broad-spectrum antibiotics including coverage of gram-negative aerobes and anaerobes (particularly *Escherichia coli* and *Klebsiella*) should be initiated. Antibiotic coverage, such as a third-generation cephalosporin, should

be started and then tailored once peritoneal fluid culture results reveal the specific organism causing SBP. Surgical intervention is rarely indicated.

Secondary or Surgical Peritonitis

Secondary (surgical) peritonitis is a result of an inflammatory process in the peritoneal cavity due to inflammation, perforation, or gangrene of the GI or GU tract. It is defined as the presence of pus or frank GI contents in the peritoneal cavity. Diagnosis and early treatment of certain GI diseases, such as appendicitis or gangrenous cholecystitis, prior to the development of secondary peritonitis significantly decreases morbidity. Once peritonitis develops, surgical intervention is typically required because in most cases, secondary peritonitis will lead to septic shock and death if left untreated.

Diagnosis of secondary peritonitis is based on the history, physical examination, and radiologic findings [see Figure 4]. Secondary peritonitis has a number of potential causes [see Table 5], including perforated peptic ulcer, perforated appendicitis, perforated diverticulitis, acute cholecystitis, and/or postsurgical complications. Of note, blood within the peritoneum can cause symptoms similar to those of SBP. Blood is locally highly irritating to the peritoneum and, thus,

Table 3 Ascitic Fluid Analysis: Typical Laboratory Studies to Order on Ascitic Fluid Obtained by Paracentesis

| |
|--|
| Always ordered |
| Cell count |
| Albumin |
| Total protein |
| Routinely ordered for definitive diagnosis |
| Gram stain |
| Fluid culture |
| Glucose |
| LDH |
| Amylase (pancreatic ascites) |
| Ordered in difficult cases |
| Triglycerides (chylous ascites) |
| Cytology (malignancy) |
| Bilirubin (bile ascites) |
| TB culture, PCR test |
| Unhelpful tests |
| Lactate |
| pH |
| Serum-ascites albumin gradient (SAAG) |
| High (transudate) (> 1.1 g/dL) |
| Cirrhosis |
| Alcoholic hepatitis |
| Congestive heart failure |
| Obstructive liver metastases |
| Fulminant liver failure |
| Budd-Chiari syndrome |
| Portal venous thrombosis |
| Fatty liver disease of pregnancy |
| Myxedema |
| Low (exudate) (< 1.1g/dL) |
| Nephrotic syndrome |
| Peritoneal carcinomatosis |
| Peritoneal mesothelioma |
| Tuberculous peritonitis |
| Chylous ascites |
| Pancreatic ascites |
| Bile ascites |
| Bowel |
| Obstruction/infarction/perforation |
| Serositis |

LDH = lactate dehydrogenase; PCR = polymerase chain reaction; TB = tuberculosis.

mimics the signs and symptoms of bacterial peritonitis. Therefore, sources that introduce blood into the peritoneal cavity, such as gynecologic causes, including rupture of an ectopic pregnancy or ruptured ovarian cyst, can also lead to peritoneal signs and should be included in the differential diagnosis.

As with SBP, secondary peritonitis can be caused by a number of bacterial organisms but is generally the result of gram-negative and *Enterococcus* bacterial species. Because of the specific anatomy of the peritoneal cavity, patients with generalized secondary peritonitis may become very ill. The large surface area of the peritoneal cavity can lead to massive fluid loss as well as the sequestration or accumulation of peritoneal fluid secondary to bacteremia. Furthermore, peritoneal circulation provides a route for rapid absorption of bacteria, endotoxin (in the case of gram-negative bacteria), and inflammatory cytokines into the systemic circulation, which can lead to sepsis.

Table 4 Causes of Abscesses

| |
|--|
| Intraperitoneal |
| Renal disease |
| Postoperative |
| Trauma |
| Cancer |
| GI causes |
| Appendicitis |
| Diverticulitis |
| Biliary tract lesions (cholecystitis) |
| Peptic ulcer perforation |
| Inflammatory bowel disease (Crohn disease) |
| Pancreatitis |
| Other |
| Retroperitoneal |
| Renal disease |
| Pyelonephritis |
| Urinary tract infection |
| Trauma |
| Spinal column infections |
| Osteomyelitis |
| Disk space infections |
| Cancer |
| GI causes |
| Pancreatitis |
| Duodenal injury/perforation |
| Peptic ulcer perforation |
| Appendicitis |
| Diverticulitis |
| Inflammatory bowel disease (Crohn disease) |
| Primary psoas abscesses |
| Hematogenous origin (<i>Staphylococcus aureus</i>) |

GI = gastrointestinal.

Broad-spectrum antibiotic therapy is required preoperatively, during surgery, and postoperatively. The microorganism causing secondary peritonitis varies by the perforation site and underlying source of sepsis. In general, colonic perforations necessitate coverage for gram-negative aerobic and anaerobic bacteria, whereas a peptic ulcer perforation may require additional antifungal coverage. Although antibiotic coverage is necessary in generalized SBP, the condition will not be resolved without operative intervention. Operative intervention should occur as soon as possible after the patient is stabilized and antibiotics have been initiated. Laparotomy remains the standard of care in the treatment of SBP. Source control is the ultimate goal of any surgical intervention and may require repair or resection of the perforated organ and/or débridement of necrotic or infected tissues. Patients may benefit from staged surgical procedures, with the first surgery geared only toward source control and subsequent surgeries geared at verification of source control and definitive surgical repair or plan of the diseased organ.

If the omentum is able to contain and wall off the source of generalized bacterial peritonitis, antibiotics alone will typically fail without further intervention, but operative exploration may not be necessary. In this situation, an intraperitoneal abscess develops and can be treated as described above with localized drainage and antibiotic therapy.

The response rate to prompt and adequate treatment (antibiotic administration and definitive source control) for bacterial peritonitis is now approaching 70% in the literature, which is a significant improvement from historical

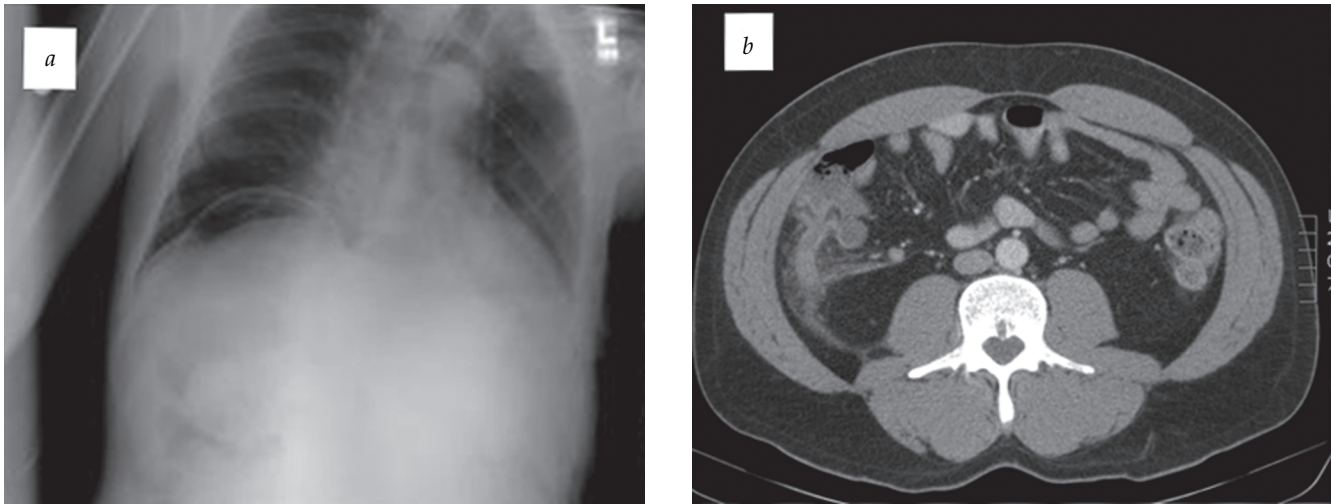


Figure 4 Representative radiologic findings that can result in bacterial peritonitis. (a) Free air can be evaluated by chest x-ray and found as pneumoperitoneum between the right hemidiaphragm and liver. (b) When the appendix is ruptured, appendicitis can lead to peritonitis.

response rates. Despite advances in the management, recognition, and subsequent treatment of SBP, morbidity and mortality remain particularly high in the elderly and in the diabetic population. In fact, peritoneally related mortality ranges anywhere from 14% in low-risk patients with isolated perforations to greater than 50% in patients with multiple comorbidities.¹¹

Tuberculous Peritonitis

Although less common in the United States than in third world countries, tuberculosis (TB) remains prevalent in the United States, with an incidence of 3.2 per 100,000 people (approximately 10,000 new cases) in 2012.¹² One of the major challenges in the treatment of TB, particularly in the United States, is the development of multiresistant strains of *Mycobacterium tuberculosis*, especially in vulnerable (homeless), confined (incarcerated), and immunocompromised (HIV/AIDS) populations.¹³ In these at-risk populations, therefore, extrapulmonary TB should be given particular consideration. Tuberculous peritonitis is seen in 0.5% of new cases of

TB and is the sixth most common site of extrapulmonary TB just after lymphatic, GU, bone and joint, miliary, and meningeal TB.

Tuberculous peritonitis presents as a primary infection without active pulmonary, renal, or intestinal involvement. Nonspecific chronic symptoms can be present for weeks to months prior to recognition and can include low-grade fever, night sweats, weight loss, anorexia, and malaise. Abdominal tenderness is present in only half of patients with TB peritonitis.¹⁴ A positive tuberculin skin test is typically present, and ascitic fluid will have an elevated white blood cell count with a lymphocytic predominance.¹⁵ Microscopic examination of ascitic fluid may be unhelpful as acid-fast bacilli are identified in less than 3% of the cases. Lymphocytic ascites is not necessarily pathognomonic of TB peritonitis as patients with lymphocytic ascites without fever typically have a malignancy-related ascites.¹⁶ In fact, cancer is the underlying cause of lymphocytic ascites 10 times more often than TB. However, if carcinomatosis is present, cytology from a paracentesis should be positive for malignancy, differentiating it from TB peritonitis in the majority of cases.¹⁷

In cases where peritoneal cytology is negative and cancer is not the etiology, a diagnostic laparoscopy can confirm TB peritonitis with the specific findings of scattered whitish peritoneal nodules [see Figure 5]. Any nodules visualized should be biopsied. Histologic examination of these nodules will demonstrate caseating granulomas in more than 90% of cases. Additionally, laparoscopy will typically reveal multiple adhesions between the abdominal organs and parietal peritoneum.

Treatment of TB peritonitis consists of at least a 6-month course of anti-TB medication starting with an 8-week course of isoniazid, rifampin, and pyrazinamide followed by isoniazid and rifampin for at least another 4 months.¹⁴ Depending on susceptibilities, a longer course of antituberculous medications may be necessary.

Table 5 Causes of Secondary Bacterial Peritonitis

| Severity | Causes | Estimated Mortality Rate (%) |
|----------|---|------------------------------|
| Mild | Appendicitis Perforated gastroduodenal ulcers Acute salpingitis | < 10 |
| Moderate | Diverticulitis Small bowel perforation Cholecystitis (gangrenous) | < 20 |
| Severe | Colonic perforations Ischemic bowel Necrotizing pancreatitis | 20–50 |

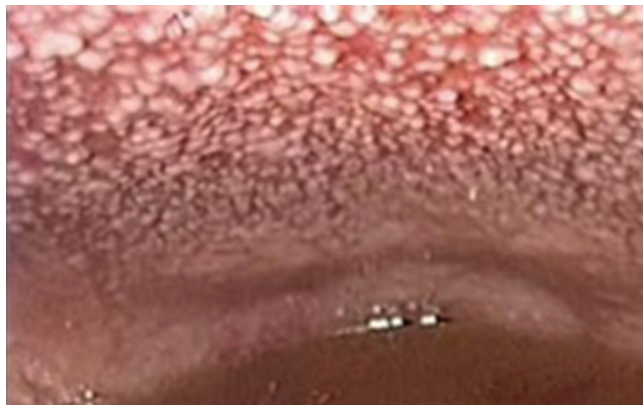


Figure 5 Tuberculosis peritonitis on laparoscopy. Nodules should be biopsied and sent for pathology and culture.

BENIGN PERITONEAL TUMORS

Peritoneal Cysts

Peritoneal cysts are extremely rare but can arise in many forms. For example, benign cystic mesotheliomas occur in adult women and are typically manifested by pain. These cystic lesions generally recur after resection. On the other hand, peritoneal inclusion cysts, also referred to as peritoneal pseudocysts, are cystlike structures that result from a nonneoplastic reactive mesothelial proliferation. Peritoneal inclusion cysts occur almost exclusively in premenopausal women who have had a history of pelvic/abdominal surgery, pelvic/abdominal trauma, or pelvic inflammatory disease. The primary presentation includes pelvic pain or a pelvic mass that is secondary to the accumulation of ovarian fluid contained within peritoneal adhesions. Thus, the development of peritoneal inclusion cysts depends on the presence of an active ovary and peritoneal adhesions. The cysts can range in size from several millimeters to centimeters in diameter. Conservative treatment includes the use of gonadotropin-releasing hormone (GnRH) antagonists or oral contraceptives to suppress ovulation and pain medication for symptomatic relief. Surgical resection is recommended only in select cases and has a 30 to 50% risk of recurrence.

Lipomatosis

Lipomatosis is a rare disease involving an overgrowth of pelvic fat found in the perirectal and perivesical spaces. It occurs predominantly in African-American men between the ages of 40 and 60 years.^{18,19} The underlying etiology remains unclear. Fogg and Smyth initially suggested that lipomatosis was comparable to Weber-Christian disease, a generalized mesenteric panniculitis characterized by increased tissue density and fibrosis within the mesentery.¹⁹ Obesity and fat overproduction by an inflammatory process such as proliferative cystitis, urinary tract obstruction, or a GI inflammatory process are postulated to be possible mechanisms of pelvic lipomatosis.¹⁸ The symptoms are variable and generally related to differing degrees of fibrous reaction secondary to abnormal proliferation. Approximately 50% of

patients present with urinary symptoms and 25% present with GI symptoms (most commonly constipation).

Computed tomography (CT) is often the best imaging study for diagnosing lipomatosis and readily demonstrates the abundance of pelvic fat as well as any extrinsic compression of surrounding pelvic organs (rectum, bladder). Furthermore, CT is helpful in differentiating between pelvic lipomatosis and liposarcomas. Evaluation should also include cystoscopy as 75% of patients with lipomatosis will have some degree of proliferative cystitis and nearly 40% will have cystitis glandularis.¹⁸

Medical treatment for pelvic lipomatosis has ranged from steroids to chemotherapy to radiation. However, these treatment strategies rarely improve the symptoms or the overall condition. Complete surgical resection of pelvic lipomatosis is difficult, and as such, surgery is not routinely recommended. Improvement in symptoms after surgery is rare. Fortunately, the disease is not progressive in most patients. Surgical intervention in patients with urinary obstruction (ureteral stenting, percutaneous nephrostomy, urinary diversion) may be required to alleviate obstructive symptoms.

Torsed Omentum

Torsion of the omentum is a condition in which the omentum twists on its long axis to the extent that its vascularity is compromised. First described in 1899 by Eitel, few case reports exist. Although rarely diagnosed preoperatively, knowledge of the entity is important because its symptoms may mimic the common causes of acute surgical abdomen. Omental torsion is usually discovered during laparotomy for presumed appendicitis or another surgical cause of peritonitis. When identified at the time of laparotomy, the torsed segment should be resected.

Desmoids

Desmoid tumors are soft tissue tumors that arise from the connective tissue and present as a single, slow-growing mass. Desmoids are benign, and their fibrous tissue appears much like scar tissue. Despite their benign nature, desmoids can be locally invasive into surrounding tissue. Most desmoid tumors are sporadic and, therefore, not inherited. Their incidence in the general population is two to four cases per million people per year in the United States, but the incidence is much higher in certain disease states, such as familial adenomatous polyposis (FAP), in which the risk of developing a desmoid tumor is increased 1,000-fold compared with the general population.²⁰ Although most patients present with an asymptomatic mass, symptoms (most commonly pain) are related to mass effect from the tumor. Other signs and symptoms are often caused by growth of the tumor into the surrounding tissue or neighboring organs.

Biopsy of the mass is required for definitive diagnosis of desmoid and will demonstrate spindle cells in a bed of abundant fibrous stroma on histologic examination. On further histologic workup, desmoids stain positive for β -catenin, actin, and vimentin. Treatment for desmoid tumors is widely variable and may include systemic therapy, radiation therapy, and/or surgery. Surgery is typically the mainstay

of therapy, with the goal of surgery being negative microscopic (R0) margins. For large lesions, neoadjuvant radiotherapy may be given to shrink the tumor prior to surgery. Radiation is typically administered postoperatively to reduce the risk of recurrence, especially in cases of positive margins. Radiation therapy alone is an acceptable treatment option in the case of surgically unresectable tumors.

Medical management is usually reserved for those desmoids that have failed surgical and radiation treatment or those that are deemed initially unresectable. Medical therapy typically involves combinations of antiestrogenic agents (tamoxifen or an aromatase inhibitor), nonsteroidal antiinflammatory medications (ibuprofen or naproxen), or targeted chemotherapy such as imatinib.²¹

MALIGNANT PERITONEAL TUMORS

Peritoneal Metastases and Peritoneal Carcinomatosis

Primary malignancies of the peritoneum are rare. Instead, most cancers that involve the peritoneum are transperitoneal metastases originating from intra-abdominal carcinomas. Peritoneal carcinomatosis occurs when metastatic nodules diffusely coat the peritoneum. Carcinomatosis is commonly associated with GI cancer metastases (colorectal or stomach) or the GU tract (ovarian). In fact, carcinomatosis can be the primary presentation in patients with malignancies such as ovarian cancer; therefore, in the setting of carcinomatosis in females, ovarian cancer should be high on the differential diagnosis. Other cancers that are known to cause peritoneal carcinomatosis include breast, pancreatic, colon, and lung cancer. Noncarcinoma malignancies such as sarcomas and subsets of lymphomas can also diffusely metastasize to peritoneal surfaces.

The signs and symptoms of peritoneal metastatic disease vary widely and can include weight loss, abdominal pain, and early satiety. Although ascites can also be present, this is usually seen in patients with large tumor burden and not in the setting of initial primary manifestation of carcinomatosis. Compared with non-malignancy-related ascites, malignant ascites is not well tolerated and can cause significant pain and symptoms even at low volumes. This intolerance may be due to decreased compliance of the abdominal wall secondary to the metastatic peritoneal deposits. These patients may benefit from repeated paracenteses for symptomatic palliation. In addition, malignant ascites with high serum-ascites albumin ratios (> 1.1 g/dL) may respond well to diuretic medications.²² Unfortunately, patients with malignant ascites develop progressive symptoms with accumulation of fluid; the ascitic fluid can also be replaced by a solid tumor component, which can lead to a malignant obstruction.

Given the inherent metastatic nature of the underlying primary cancer, the response to routine therapies (chemotherapy and/or radiation) is generally poor, with a median survival without treatment on the order of 5 to 8 months (in the case of colon cancer).^{23,24} Therefore, newer treatments have been suggested, such as peritonectomy and cytoreductive surgery (CRS) combined with hyperthermic intraperitoneal chemotherapy (HIPEC). CRS-HIPEC has been approved for peritoneal metastases secondary to colorectal, ovarian,

and, in rare instances, gastric cancers. Patients with disseminated carcinomatosis should not be considered for this procedure. Instead, eligible patients have limited peritoneal disease that can be safely resected [see Cytoreductive Surgery and Hyperthermic Intraperitoneal Chemotherapy, *below*].

Pseudomyxoma Peritonei

Pseudomyxoma peritonei (PMP) is characterized by the intraperitoneal dissemination of a large volume of mucinous ascites. Unlike peritoneal carcinomatosis, in which the peritoneum is coated in metastatic cancer, in PMP, the peritoneum becomes coated with cells that secrete mucin that can fill the peritoneal cavity with semisolid mucin. The mucinous material may arise from diffuse peritoneal adenomucinosis (DPAM), which consists of lesions composed of scant simple to focally proliferative mucinous epithelium with little cytologic atypia or mitotic activity. On the other hand, PMP can also arise from more aggressive peritoneal lesions composed of more abundant mucinous epithelium with the architectural and cytologic features of carcinoma, typically seen in a ruptured appendiceal adenocarcinoma or ovarian cancer. PMP is a rare condition with an incidence of approximately one in 1,000,000 per year.²⁵ The degree of malignant potential is variable in PMP. The histology of the cells causing PMP is an important predictor of survival, with adenomucinosis (DPAM) having the best survival rate (75% at 5 years) and peritoneal mucinous carcinomatosis (PMCA) the worst (14% at 5 years).²⁶

Due to the underlying normal peritoneal circulation, neoplastic cells and the resultant mucinous ascites spread freely to two main areas in the abdominal cavity.²⁷ The first area of accumulation is the upper abdomen at the typical peritoneal fluid absorption sites: the undersurface of the diaphragm (especially the right upper abdomen) and the omentum. The second area of accumulation includes the dependent peritoneal areas (the pelvic and lateral abdominal gutters). Distant metastases and extraperitoneal spread of PMP are rare.

PMP is most often diagnosed in women between the ages of 40 and 60 years. The degree of malignant potential is variable and can range from a low-grade PMP (DPAM, grade 1) to the malignant variant, high-grade PMP (DMCA, grade 3). Low-grade PMP is a benign disease at a microscopic level; however, even this slow-growing disease can cause significant accumulation of mucin if not adequately treated. The outcome is eventually fatal without treatment.

PMP patients are often asymptomatic until the development of significant mucin accumulation that occurs late in the course of the disease process. In retrospect, patients often elicit a chronic deterioration in their health status months to years before the actual diagnosis. Presenting symptoms include abdominal pain and abdominal distention. Although not diagnostic, a CT scan may provide telltale signs, such as low-attenuating, and often loculated, fluid throughout the peritoneum and omentum, scalloping of the visceral surfaces (particularly the liver surface), and scattered calcifications throughout the abdomen [see *Figure 6*]. Definitive diagnosis is made with percutaneous biopsy of the gelatinous material or, more frequently, at the time of laparotomy.

The standard treatment of PMP is surgery. CRS alone was the initial mainstay of treatment; however, relapses occur in

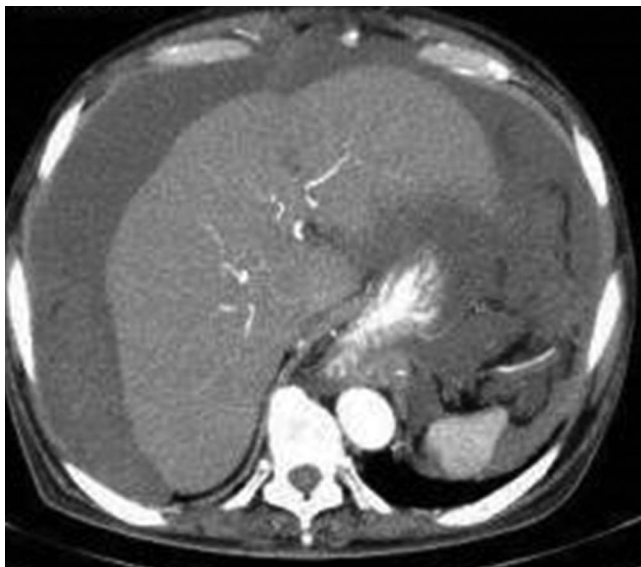


Figure 6 Scalloping of liver surface secondary to mucin accumulation in pseudomyxoma peritonei.

most cases and require repeated debulking surgeries. Currently, the optimal treatment for PMP is now CRS-HIPEC [see *Cytoreductive Surgery and Hyperthermic Intraperitoneal Chemotherapy, below*].²⁸ A literature review of patients undergoing CRS-HIPEC reported an operative mortality of 2% and a morbidity of 40%, with a mean survival of 13 years.²⁹ Historically, patients with PMP had 10-year survival rates of up to 20 to 30% only with the addition of debulking surgeries with each subsequent recurrence of disease. In cases of PMP treated with optimal CRS-HIPEC, 10-year overall survival has been reported up to 85%.^{25,30} In cases in which the appendix is the primary PMP site, a right hemicolectomy is generally performed, although there is now debate on whether this is necessary given an adequate negative resection margin with appendectomy.²⁵

Mesothelioma

Although rare, with an incidence of 300 to 500 cases/year in the United States, peritoneal mesothelioma is the most common primary peritoneal tumor.³¹ Most mesotheliomas are malignant and are directly related to asbestos exposure. Development of peritoneal mesothelioma typically occurs 35 to 40 years after initial asbestos exposure. The differentiation of malignant mesotheliomas from cystic mesotheliomas and well-differentiated papillary mesotheliomas in women is essential because the latter two disease states are generally considered benign and carry a better prognosis. Malignant peritoneal mesothelioma is more often seen in men, with the median age at presentation in the mid-50s.

The typical presenting symptoms include weight loss, crampy abdominal pain, a large mass or distention secondary to ascites, and a history of asbestos exposure. Less than half of patients with peritoneal mesothelioma have asbestosis of the lungs demonstrated on plain chest films. In contrast to peritoneal carcinomatosis, malignant peritoneal mesotheliomas are associated with a lower volume ascites

than the degree of abdominal distention would suggest. The ascites, abdominal distention, and pain associated with peritoneal mesothelioma are typically intractable. Furthermore, cytologic studies of ascitic fluid are rarely positive. Radiologic findings can include the presence of ascites, peritoneal and mesenteric thickening, pleural plaques, and soft tissue masses involving the omentum and peritoneum on CT scan. Percutaneous biopsies or laparoscopy can establish the diagnosis.

The traditional treatment strategy for peritoneal mesothelioma is CRS. Unlike PMP, peritoneal mesothelioma can locally invade surrounding tissues and organs, which may lead to unresectability of disease. Encasement of the small bowel mesentery and the small bowel itself can lead to a malignant bowel obstruction. Given this, complete tumor debulking may not be possible. However, in those cases of resectable disease, peritoneal mesothelioma is now treated with CRS-HIPEC, with significant improvements in survival compared with CRS alone. In multiple studies, the 5-year overall survival approaches 50%, and the median overall survival is now reported at 30 to 60 months.^{32,33}

Cytoreductive Surgery and Hyperthermic Intraperitoneal Chemotherapy

With proper patient selection and the use of standard surgical techniques and HIPEC administration, the complex CRS and HIPEC procedure can be performed with acceptable morbidity and mortality [see *Figure 7*]. Complete cytoreductive resection of all tumor burden to macroscopically negative disease is the mainstay of this treatment modality. The disease burden may be estimated prior to surgical consideration by determining the peritoneal cancer index (PCI). The PCI is a scoring system evaluating the extent of metastasis in the peritoneal cavity. The abdomen and pelvis are divided into 13 distinct regions [see *Table 6*] in which a lesion size (LS) score is determined for the largest tumor in that area. The significance of the PCI will vary with the type of peritoneal surface malignancy treated. In a study of sarcomatosis by Berhet and colleagues, a PCI less than 13 was associated with a 74% 5-year survival, whereas a PCI of 13 or greater was associated with an 11% 5-year survival.³⁴ Sugarbaker reported in colorectal carcinomatosis that a PCI of 10 or less was associated with a 50% 5-year survival, a PCI of 11 to 20 was associated with a 20% 5-year survival, and an index greater than 20 was associated with a 0% 5-year survival.³⁵

At the time of laparotomy, CRS should include omentectomy, stripping of the involved peritoneum (peritonectomy), resection of any involved organs, and appendectomy if the appendix is still present. No residual tumor nodules greater than 2 mm in diameter should be present after adequate tumor resection. CRS is then followed by administration of HIPEC, typically in the form of mitomycin C or a platinum-based chemotherapy [see *Figure 8*]. The rationale for application of intraperitoneal chemotherapy is that it allows for larger local concentrations of the chemotherapeutic drugs to directly reach tumor cells, whereas the hyperthermic temperature is cytotoxic itself and also potentiates the chemotherapeutic agents. Furthermore, intraperitoneal administration decreases the overall systemic effects and side effects

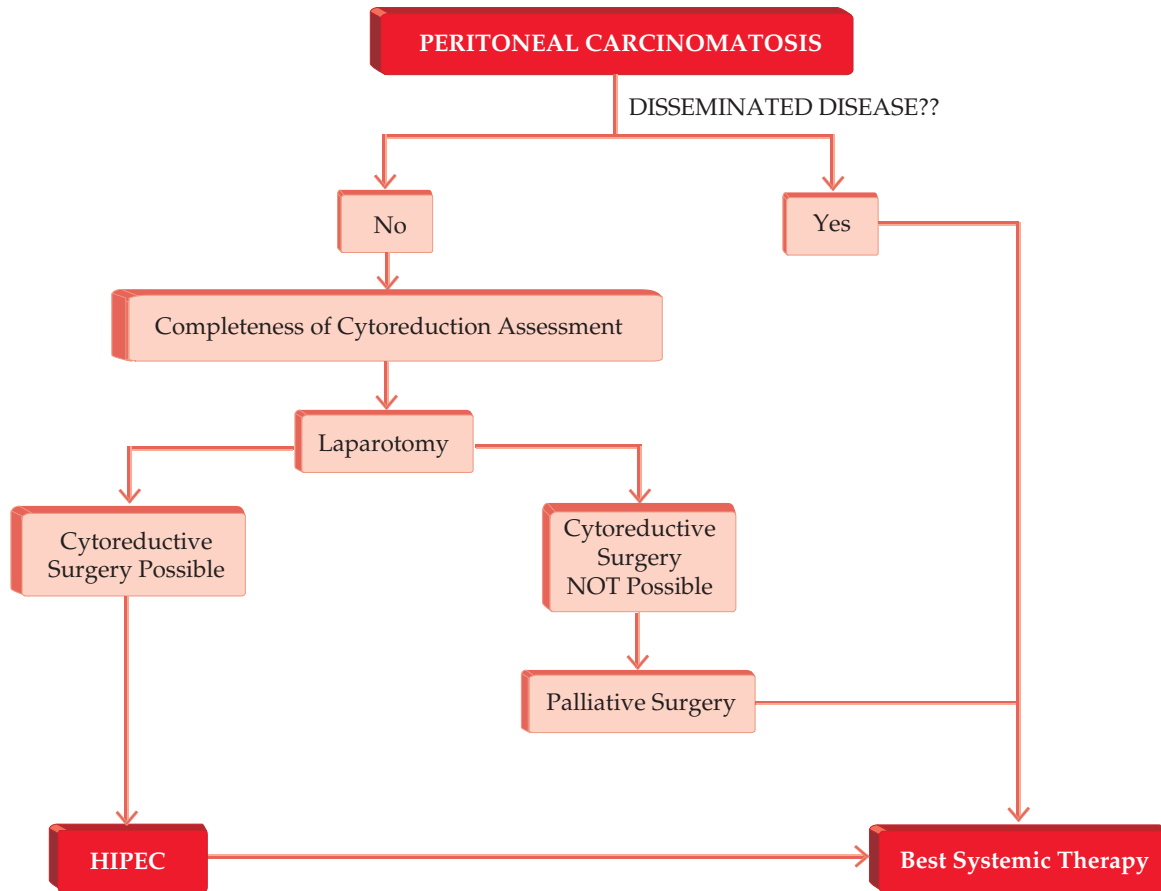


Figure 7 Evaluation for cytoreductive surgery and hyperthermic intraperitoneal chemotherapy (HIPEC).

of the chemotherapy. Mitomycin C is the chemotherapeutic agent now recommended by the American Society of Peritoneal Surface Malignancies (ASPSM), with oxaliplatin being the next most common for colorectal cancer. A recent ASPSM consensus statement not only recommended standardization of patient selection and delivery of HIPEC in the setting

of peritoneal carcinomatosis secondary to colorectal cancer but also reported significant improvement in survival, as noted by multiple studies.³⁶⁻⁴⁰

HIPEC can be performed using an open technique, in which the abdomen is left open to ensure adequate chemotherapy distribution throughout the abdominal cavity. The more common technique, however, is a closed HIPEC procedure, in which inflow and outflow cannulas attached to temperature probes are placed in the abdomen, which is then closed prior to administration of the chemotherapy [see Figure 9, Figure 10, Figure 11, Figure 12, and Figure 13]. A comparison of the benefits of the open technique to the closed technique is shown in Table 7 [see Table 7]. Once closed, the abdomen is warmed with hyperthermic saline until the intra-abdominal temperature approaches 40°C, and then hyperthermic chemotherapy is infused into the abdomen and circulated for up to 90 minutes. The closed technique allows for easier maintenance of a hyperthermic temperature (40°C). Next, the hyperthermic chemotherapeutic fluid is drained from the abdomen and the procedure is completed by performing any necessary anastomoses and/or ostomies, followed by definitive abdominal closure. Some institutions are evaluating laparoscopic HIPEC administration, although the results are mixed.⁴¹⁻⁴³

Table 6 Peritoneal Cancer Index Scoring to Determine Eligibility for HIPEC

| Peritoneal cancer index (PCI) | |
|--|------------------------------------|
| Abdomen divided into 13 regions For each region, a lesion size (LS) score is calculated from largest lesion | |
| LS-0 | No tumor nodules |
| LS-1 | Tumor nodules < 0.5 cm |
| LS-2 | Tumor nodules 0.5–5.0 cm in size |
| LS-3 | Tumor nodules > 5.0 cm in size |
| Total PCI score | |
| PCI < 10 | Resection recommended |
| PCI 11–20 | Resection may be considered |
| PCI > 20 | Resection should not be considered |

HIPEC = hyperthermic intraperitoneal chemotherapy.

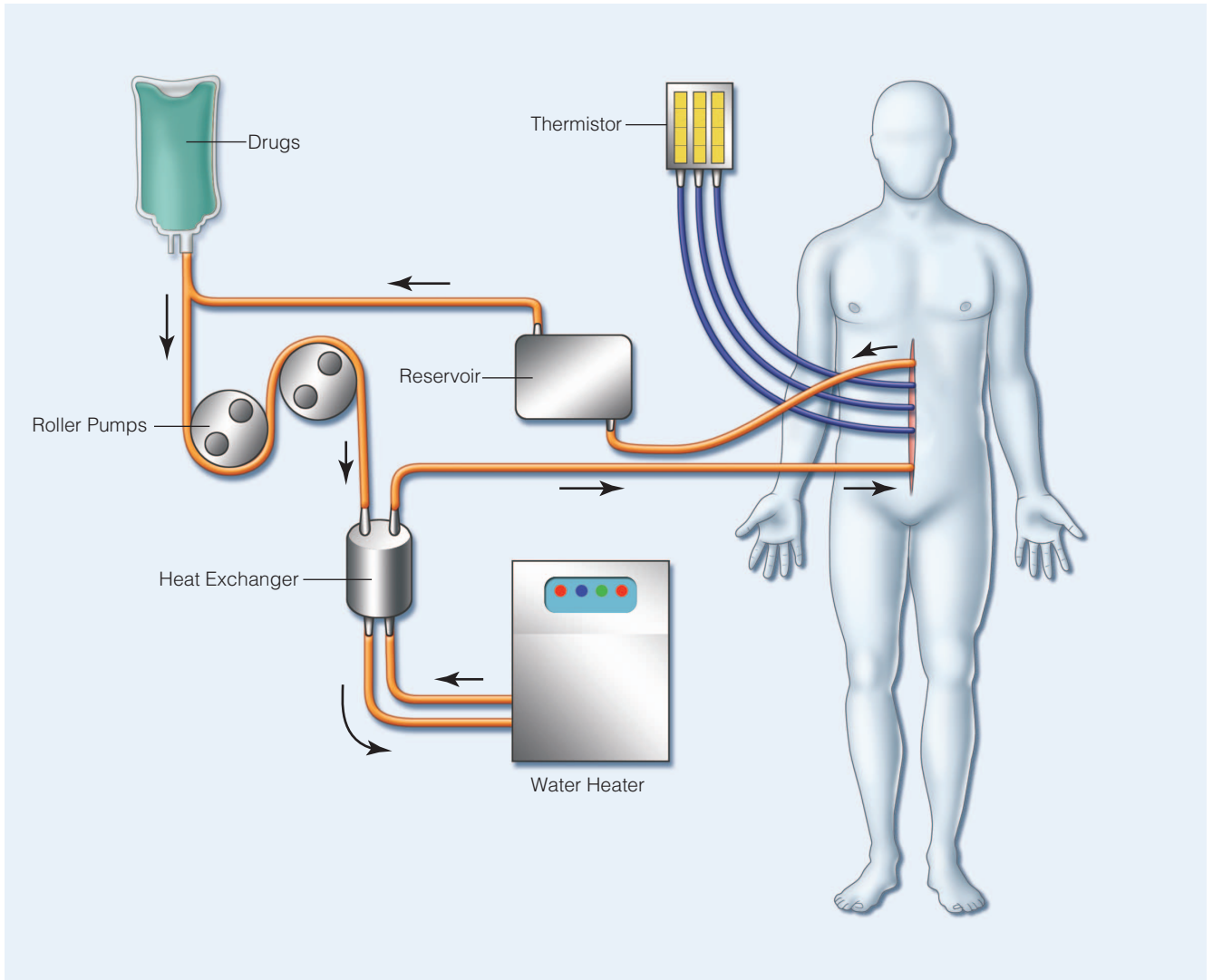


Figure 8 Diagram of the closed hyperthermic intraperitoneal chemotherapy (HIPEC) system.

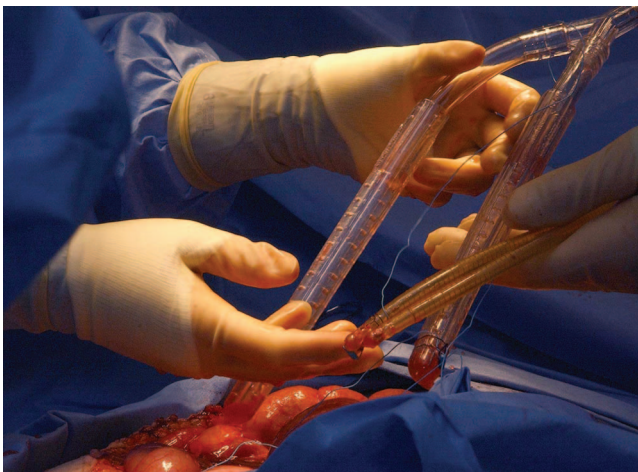


Figure 9 Cytoreductive surgery and hyperthermic intraperitoneal chemotherapy: placement of cannulas for the closed abdominal hyperthermic intraperitoneal chemotherapy (HIPEC) procedure. Both inflow and outflow cannulas have temperature probes to adequately determine intraperitoneal temperature and maintain it at least as 40°C.

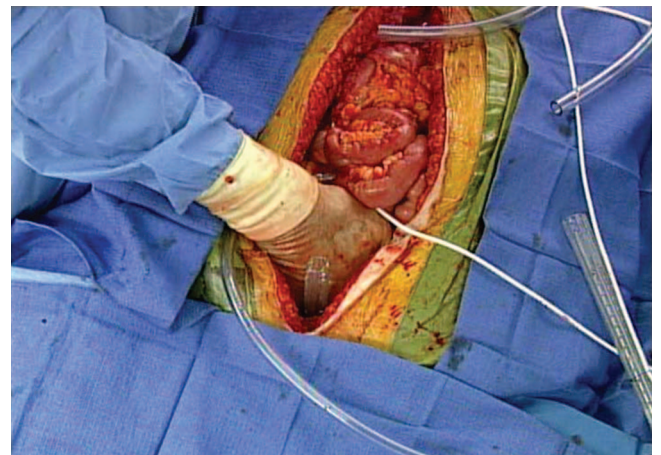


Figure 10 Cytoreductive surgery and hyperthermic intraperitoneal chemotherapy (HIPEC): placement of cannulas and temperature probes for the closed abdominal HIPEC procedure.

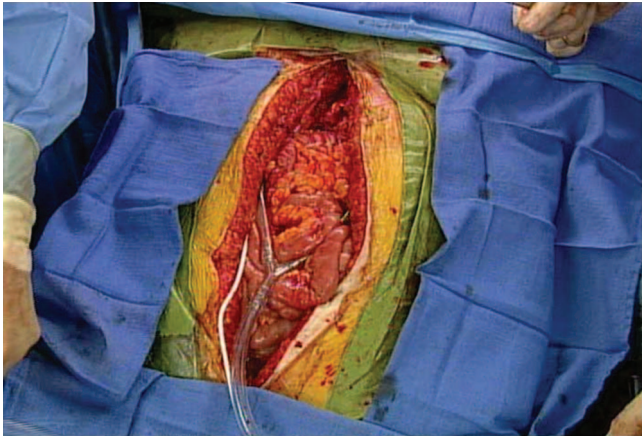


Figure 11 Both inflow and outflow cannulas are placed intra-abdominally through the midline incision.

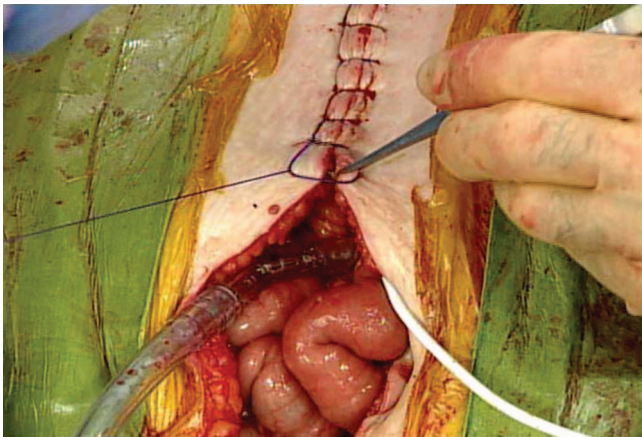


Figure 12 A watertight skin closure is required in the closed hyperthermic intraperitoneal chemotherapy (HIPEC) technique to maintain intra-abdominal hyperthermia.

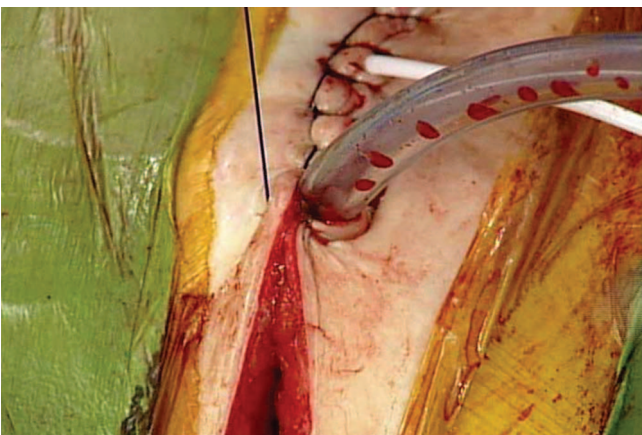

Figure 13 The watertight skin closure includes the area around inflow and outflow cannulas to maintain intraperitoneal hyperthermia and a closed chemotherapy circulation system.

Diseases of the Retroperitoneum

RETROPERITONEAL ABSCESSSES

Retroperitoneal infections are typically contained abscesses and may be caused by hematogenous spread (primary) or, more typically, are due to infection from a neighboring organ (secondary). Abscesses occur less commonly in the retroperitoneum than in the peritoneal cavity. Specific examples include retrocecal appendicitis, perforated duodenal ulcers, pancreatitis, perinephric abscesses (secondary to pyelonephritis or urinary tract infection), and diverticulitis [see Table 4]. The underlying etiology of the bacterial organism is related to the offending organ. For example, cultures of a retroperitoneal abscess secondary to GI disease may grow a combination of gram-negative anaerobes or aerobes (*Enterobacter*, *E. coli*, or *Bacteroides*), whereas abscesses caused by a GU process are often secondary to a single organism (*Proteus* or *E. coli*). Specific cases of intrasplenic abscesses may be the result of hematogenous spread, typically of *Staphylococcus aureus*. Other causes of intrasplenic abscesses can include osteomyelitis or disk space infections of the thoracic or lumbar spine.

Typical symptoms of retroperitoneal abscesses include pain, fevers, chills, and malaise that have usually been present for a prolonged period of time. Given that this infection is contained within the retroperitoneal space, large abscesses can develop prior to the development of any symptoms. The location of the pain may vary depending on the location of the abscess and the offending organ. Laboratory values will include a leukocytosis. The diagnostic imaging of choice, CT, will show the location of the abscess, size, and involvement of surrounding tissue. As with abscesses in other sites of the body, treatment includes broad-spectrum antimicrobial coverage and adequate percutaneous drainage. If percutaneous drainage is not feasible by image guidance, operative drainage may be necessary and should be done through a retroperitoneal approach to avoid peritoneal contamination. Operative drainage may also be necessary in a multiloculated retroperitoneal abscess. Antibiotic coverage should be tailored to the offending organisms once cultures provide definitive results.

RETROPERITONEAL FIBROSIS

Retroperitoneal fibrosis is a relatively uncommon disease characterized by extensive fibrotic encasement of retroperitoneal structures secondary to hyperproliferation of fibrous tissue.^{44,45} Primary idiopathic retroperitoneal fibrosis, commonly referred to as Ormond disease,⁴⁶ affects approximately one in 200,000 people annually. Ormond disease is the underlying diagnosis in 70% of patients presenting with retroperitoneal fibrosis, whereas the other 30% of cases are secondary to medications, infections (most commonly GU infections), trauma, malignancies, retroperitoneal hemorrhage, or iatrogenic causes (radiation therapy or surgical interventions).⁴⁷ This disease affects men more than women (2:1) and is usually diagnosed in individuals 40 to 60 years old.

Many cases of Ormond disease are associated with inflammatory abdominal aortic aneurysms and, in these cases, may be considered a form of chronic periaortitis.⁴⁴ Retroperitoneal fibrosis is usually confined to the central and paravertebral spaces between the renal arteries and

Table 7 Hyperthermic Intraperitoneal Chemotherapy (HIPEC): Open versus Closed Technique Comparisons

| | <i>Open</i> | <i>Closed</i> |
|--|-------------|------------------|
| Abdominal pressure | Normal | Raised |
| Continued surgery | Yes | No |
| Aerosol contamination | Yes | Reduced |
| Distribution of heat and chemotherapy agent | Uniform | Variable |
| Simultaneous perfusion of thoracic cavity | Yes | No |
| Management of technical problems | Easy | May be difficult |
| Detection and management of occult bowel perforation | Easier | Difficult |

tends to lead to encasement of the aorta, inferior vena cava, and ureters. The underlying pathogenesis is likely multifactorial. There is considerable evidence to suggest that Ormond disease is a manifestation of an overall systemic autoimmune disease.^{44,48}

Secondary retroperitoneal fibrosis is caused by a broad range of factors. The most common cause is use of certain drugs, although in these cases, the underlying reasons are still debated.^{47,49–52} Some medications, such as methysergide and ergot alkaloids, are known to cause fibrotic reactions that can affect not only the retroperitoneum but also other anatomic structures (pericardium, lungs) as well.⁵³ Secondary retroperitoneal fibrosis due to malignancy results from the desmoplastic reaction to either metastases in the retroperitoneum or to the primary cancer itself. For example, carcinoids via a serotonin-mediated mechanism can induce a desmoplastic reaction that could involve the retroperitoneum.⁵⁴ On the other hand, radiation therapy may lead to a sclerosing fibrosis that is isolated to the radiation field itself.

The macroscopic appearance of retroperitoneal fibrosis is a white, hard retroperitoneal plaque of varying thickness. Again, this plaque develops between the origin of the renal arteries and the pelvic brim. Microscopically, this process is seen as sclerotic tissue infiltrated by a mixture of mononuclear cells. Symptoms of retroperitoneal fibrosis are nonspecific. Localized symptoms may include back or abdominal pain that is dull and constant in nature and not exacerbated by movement. Constitutional symptoms may include fatigue, low-grade fever, nausea, anorexia, and malaise. Physical examination is unhelpful in diagnosis for most circumstances.

Diagnostic studies, including laboratory studies, are consistent with inflammatory disease. For example, 80 to 100% of patients will have both an elevated erythrocyte sedimentation rate (ESR) and elevated C-reactive protein level.⁵⁵ Of the autoimmune disease studies, positive antinuclear antibodies are most frequently found and are seen in approximately 60% of patients. Imaging studies are essential in diagnosis. Ultrasonography is the best first-line noninvasive study as most patients will have urologic obstruction secondary to the underlying fibrotic reaction. If available, magnetic resonance imaging (MRI) can also be used and provides better definition of surrounding soft tissues and organs.

The goals of treatment of retroperitoneal fibrosis are to stop the progression of the fibrous hyperproliferation, to inhibit or relieve any obstructive symptoms, and to prevent recurrence. The first-line medical treatment is corticosteroids, which work by suppressing acute-phase reactants and decreasing the inflammatory reaction.⁵⁶ In the case of steroid-resistant disease or intolerance of steroid therapy, immunosuppressants (cyclophosphamide, azathioprine, methotrexate, or cyclosporine) have also been used commonly, with marginal results.⁵⁷ Antiestrogenic agents, in particular tamoxifen, have also been employed as second-line therapy.^{58,59} Surgical intervention is reserved for those cases of retroperitoneal fibrosis that lead to severe ureteral obstruction as surgery does not address or prevent the progression of disease.⁶⁰

RETROPERITONEAL SARCOMA

Soft tissue sarcomas are rare and unusual neoplasms accounting only for 1% of adult cancers, with approximately 10,000 sarcomas diagnosed in the United States each year. Soft tissue sarcomas consist of a wide range of diseases with over 50 histologic types and subtypes that can develop in any anatomic site. Thus, diagnosis, management, and subsequent treatment of sarcomas are extremely challenging. With an incidence of 1,000 cases per year, retroperitoneal sarcomas account for 10 to 15% of all soft tissue sarcomas. Most cases are thought to be sporadic, although a history of remote radiation therapy (> 10 years after exposure) and genetic factors have been shown to play a role.^{61,62} A few cases have been shown to be caused by genetically inherited diseases, including Li-Fraumeni syndrome, neurofibromatosis type 1, and hereditary retinoblastoma.⁶³

In contrast to sarcomas of other anatomic sites, retroperitoneal sarcomas often present as large masses (50% are greater than 20 cm in diameter) as they are typically asymptomatic until compressive symptoms of the surrounding structures develop. Abdominal pain is present in 50% of patients diagnosed with retroperitoneal sarcoma. CT of the abdomen and pelvis can provide vital details regarding the tumor size, the extent of the tumor, and its relationship to surrounding structures. MRI may be beneficial to delineate nerve involvement or details regarding local organ invasion. Percutaneous tissue biopsy and definitive diagnosis can typically be performed by CT guidance.

Histologically, the most common subtypes of retroperitoneal sarcoma are liposarcoma, malignant fibrous histiocytoma (MFH), and leiomyosarcoma. Given the nearly 50 subtypes of sarcoma, the diagnosis and staging of sarcomas are difficult at best. The 7th edition of the American Joint Commission on Cancer (AJCC) includes grade and depth to the fascia as part of the staging system for some soft tissue sarcomas [see Table 8]. In particular, grade is the main determinant for staging for retroperitoneal sarcomas as these malignancies are by definition deep to the fascia. Prognostic factors associated with poor survival include higher stage, higher histologic grade, and either unresectability or positive surgical margins.⁶⁴

When possible, complete surgical resection is the most effective treatment for retroperitoneal sarcomas. En bloc resections often include resection of neighboring organs due to local invasion of tumor. Lymph node dissection is generally not required as lymph node metastases for sarcomas are reported in less than 5% of cases. The essential part of surgical intervention is to achieve a negative margin (R0) resection. In a study of 500 patients with retroperitoneal sarcoma, median survival times were improved by over 7 years (85 months) with complete R0 resection.⁶⁵

Table 8 AJCC 7th Edition Staging System for Sarcoma

| T stage | | | | |
|---------|--|-------|----|--------|
| T0 | No evidence of primary tumor | | | |
| T1 | Tumor < 5 cm | | | |
| T1a | Superficial tumor | | | |
| T1b | Deep tumor (below fascia, retroperitoneal) | | | |
| T2 | Tumor > 5 cm | | | |
| T2a | Superficial tumor | | | |
| T2b | Deep tumor (below fascia, retroperitoneal) | | | |
| N stage | | | | |
| NX | Lymph nodes cannot be assessed | | | |
| N0 | No regional lymph node metastases | | | |
| N1 | Regional lymph node metastases | | | |
| Grade | | | | |
| GX | Grade cannot be assessed | | | |
| G1 | Grade 1 | | | |
| G2 | Grade 2 | | | |
| G3 | Grade 3 | | | |
| M stage | | | | |
| M0 | No distant metastases | | | |
| M1 | Distant metastases | | | |
| Stage | | | | |
| IA | T1a | N0 | M0 | G1, GX |
| | T1b | N0 | M0 | G1, GX |
| IB | T2a | N0 | M0 | G1, GX |
| | T2b | N0 | M0 | G1, GX |
| IIA | T1a | N0 | M0 | G2, G3 |
| | T1b | N0 | M0 | G2, G3 |
| IIB | T2a | N0 | M0 | G2 |
| | T2b | N0 | M0 | G2 |
| III | T2a, T2b | N0 | M0 | G3 |
| | Any T | N1 | M0 | Any G |
| IV | Any T | Any N | M1 | Any G |

AJCC = American Joint Committee on Cancer.

Unfortunately, neoadjuvant or adjuvant chemotherapy regimens have not been proven effective in soft tissue sarcomas. Most studies have failed to show a survival advantage of any chemotherapeutic regimen evaluated.⁶⁶ Due to significant local recurrence rates, radiation therapy has been proposed as a potential means of treating microscopic positive surgical margins. There are no consensus guidelines for the usual radiation dose or timing in patients with retroperitoneal sarcomas. The role for external-beam radiation is often limited by radiation tolerance and location of adjacent organs. Another factor that complicates radiation therapy of retroperitoneal sarcomas is the size of the tumor as larger tumors require much larger radiation fields. The timing of radiation therapy has also been evaluated. Preoperative radiation may be beneficial; however, it has not been well studied. For high-risk disease, 50 Gy preoperative radiation therapy followed by en bloc surgical resection has been suggested.⁶⁷

Regardless of treatment strategy, 5-year recurrence rates of retroperitoneal sarcomas are high (nearly 75%), whereas overall 5-year survival is less than 50%.^{65,68} Retroperitoneal sarcomas can recur locally or diffusely within the peritoneal cavity. Furthermore, retroperitoneal sarcomas can metastasize, with the most common sites being the lungs and the liver. If recurrent disease is resectable, surgery is once again the treatment modality of choice.

Financial Disclosures: Amanda K. Arrington, MD, and Joseph Kim, MD, have no relevant financial relationships to disclose.

8

References

- Meyers MA, Oliphant M, Berne AS, Feldberg MA. The peritoneal ligaments and mesenteries: pathways of intra-abdominal spread of disease. *Radiology* 1987;163:593–604.
- Oliphant M, Berne AS. Computed tomography of the subperitoneal space: demonstration of direct spread of intra-abdominal disease. *J Comput Assist Tomogr* 1982;6:1127–37.
- Healy JC, Reznick RH. The peritoneum, mesenteries and omentum: normal anatomy and pathological processes. *Eur Radiol* 1998;8:886–900.
- Dunn DL, Barke RA, Knight NB, et al. Role of resident macrophages, peripheral neutrophils, and translymphatic absorption in bacterial clearance from the peritoneal cavity. *Infect Immun* 1985;49:257–64.
- Harris LF, Sparks JE. Retroperitoneal abscess. Case report and review of the literature. *Dig Dis Sci* 1980;25:392–5.
- Ioannidis O, Kakoutis E, Katsifa H, et al. Streptococcus mutans: a rare cause of retroperitoneal abscess. *Adv Med Sci* 2011;56:113–8.
- Gardner GP, Josephs LG, Rosca M, et al. The retroperitoneal incision. An evaluation of postoperative flank ‘bulge.’ *Arch Surg* 1994;129:753–6.
- Sandhu BS, Sanyal AJ. Management of ascites in cirrhosis. *Clin Liver Dis* 2005;9:715–32, viii.
- Rosner MH, Gupta R, Ellison D, Okusa MD. Management of cirrhotic ascites: physiological basis of diuretic action. *Eur J Intern Med* 2006;17:8–19.
- Runyon BA, Canawati HN, Akriviadis EA. Optimization of ascitic fluid culture technique. *Gastroenterology* 1988;95:1351–5.

11. Seiler CA, Brugger L, Forssmann U, et al. Conservative surgical treatment of diffuse peritonitis. *Surgery* 2000;127:178–84.
12. Centers for Disease Control and Prevention. Tuberculosis incidence. 2012. Available at: <http://www.cdc.gov/tb/statistics/tbcases.htm>.
13. Hopewell PC. Impact of human immunodeficiency virus infection on the epidemiology, clinical features, management, and control of tuberculosis. *Clin Infect Dis* 1992;15:540–7.
14. Sanai FM, Bzeizi KI. Systematic review: tuberculous peritonitis—presenting features, diagnostic strategies and treatment. *Aliment Pharmacol Ther* 2005;22:685–700.
15. Runyon BA. Care of patients with ascites. *N Engl J Med* 1994;330:337–42.
16. Runyon BA. Malignancy-related ascites and ascitic fluid “humoral tests of malignancy.” *J Clin Gastroenterol* 1994;18:94–8.
17. Runyon BA, Hoefs JC, Morgan TR. Ascitic fluid analysis in malignancy-related ascites. *Hepatology* 1988;8:1104–9.
18. Heyns CF. Pelvic lipomatosis: a review of its diagnosis and management. *J Urol* 1991;146:267–73.
19. Fogg LB, Smyth JW. Pelvic lipomatosis: a condition simulating pelvic neoplasm. *Radiology* 1968;90:558–64.
20. Gurbuz AK, Giardiello FM, Petersen GM, et al. Desmoid tumours in familial adenomatous polyposis. *Gut* 1994;35:377–81.
21. Heinrich MC, McArthur GA, Demetri GD, et al. Clinical and molecular studies of the effect of imatinib on advanced aggressive fibromatosis (desmoid tumor). *J Clin Oncol* 2006;24:1195–203.
22. Pockros PJ, Esrason KT, Nguyen C, et al. Mobilization of malignant ascites with diuretics is dependent on ascitic fluid characteristics. *Gastroenterology* 1992;103:1302–6.
23. Chu DZ, Lang NP, Thompson C, et al. Peritoneal carcinomatosis in nongynecologic malignancy. A prospective study of prognostic factors. *Cancer* 1989;63:364–7.
24. Sadeghi B, Arvieux C, Glehen O, et al. Peritoneal carcinomatosis from non-gynecologic malignancies: results of the EVOCAPE 1 multicentric prospective study. *Cancer* 2000;88:358–63.
25. Gonzalez-Moreno S, Sugarbaker PH. Right hemicolectomy does not confer a survival advantage in patients with mucinous carcinoma of the appendix and peritoneal seeding. *Br J Surg* 2004;91:304–11.
26. Ronnett BM, Yan H, Kurman RJS, et al. Patients with pseudomyxoma peritonei associated with disseminated peritoneal adenomucinosis have a significantly more favorable prognosis than patients with peritoneal mucinous carcinomatosis. *Cancer* 2001;92:85–91.
27. Mann WJ Jr, Wagner J, Chumas J, Chalas E. The management of pseudomyxoma peritonei. *Cancer* 1990;66:1636–40.
28. Youssef H, Newman C, Chandrakumaran K, et al. Operative findings, early complications, and long-term survival in 456 patients with pseudomyxoma peritonei syndrome of appendiceal origin. *Dis Colon Rectum* 2011;54:293–9.
29. Yan TD, Welch L, Black D, Sugarbaker PH. A systematic review on the efficacy of cytoreductive surgery combined with perioperative intraperitoneal chemotherapy for diffuse malignancy peritoneal mesothelioma. *Ann Oncol* 2007;18:827–34.
30. Vaira M, Cioppa T, De Marco G, et al. Management of pseudomyxoma peritonei by cytoreduction+HIPEC (hyperthermic intraperitoneal chemotherapy): results analysis of a twelve-year experience. *In Vivo* 2009;23:639–44.
31. Boffetta P. Epidemiology of peritoneal mesothelioma: a review. *Ann Oncol* 2007;18:985–90.
32. Yan TD, Yoo D, Sugarbaker PH. Significance of lymph node metastasis in patients with diffuse malignant peritoneal mesothelioma. *Eur J Surg Oncol* 2006;32:948–53.
33. Yan TD, Deraco M, Baratti D, et al. Cytoreductive surgery and hyperthermic intraperitoneal chemotherapy for malignant peritoneal mesothelioma: multi-institutional experience. *J Clin Oncol* 2009;27:6237–42.
34. Berthet B, Sugarbaker TA, Chang D, Sugarbaker PH. Quantitative methodologies for selection of patients with recurrent abdominopelvic sarcoma for treatment. In: 8th World Congress of the International Gastro-Surgical Club. Bologna: Monduzzi Editore; 1998. p. 899–903.
35. Sugarbaker PH. Successful management of microscopic residual disease in large bowel cancer. *Cancer Chemother Pharmacol* 1999;43 Suppl:S15–25.
36. Verwaal VJ. Results of cytoreduction followed by HIPEC in carcinomatosis of colorectal origin. *Cancer Treat Res* 2007;134:291–301.
37. Turaga K, Levine E, Barone R, et al. Consensus guidelines from the American Society of Peritoneal Surface Malignancies on standardizing the delivery of hyperthermic intraperitoneal chemotherapy (HIPEC) in colorectal cancer patients in the United States. *Ann Surg Oncol* 2013. [Epub 2013 June 25]
38. Esquivel J, Sticca R, Sugarbaker P, et al. Cytoreductive surgery and hyperthermic intraperitoneal chemotherapy in the management of peritoneal surface malignancies of colonic origin: a consensus statement. *Society of Surgical Oncology. Ann Surg Oncol* 2007;14:128–33.
39. Elias D, Di Pietrantonio D, Boulet T, et al. “Natural history” of complete cytoreductive surgery with hyperthermic intraperitoneal chemotherapy. *Eur J Surg Oncol* 2009;35:434–8.
40. Elias D, Pocard M, Goere D. HIPEC with oxaliplatin in the treatment of peritoneal carcinomatosis of colorectal origin. *Cancer Treat Res* 2007;134:303–18.
41. Esquivel J, Averbach A. Laparoscopic cytoreductive surgery and HIPEC in patients with limited pseudomyxoma peritonei of appendiceal origin. *Gastroenterol Res Pract* 2012;2012:981245.
42. Esquivel J, Averbach A, Chua TC. Laparoscopic cytoreductive surgery and hyperthermic intraperitoneal chemotherapy in patients with limited peritoneal surface malignancies: feasibility, morbidity and outcome in an early experience. *Ann Surg* 2011;253:764–8.
43. Ong E, Diven C, Abrams A, et al. Laparoscopic hyperthermic intraperitoneal chemotherapy (HIPEC) for palliative treatment of malignant ascites from gastrointestinal stromal tumours. *J Palliat Care* 2012;28:293–6.
44. Vaglio A, Salvarani C, Buzio C. Retroperitoneal fibrosis. *Lancet* 2006;367:241–51.
45. Gilkeson GS, Allen NB. Retroperitoneal fibrosis. A true connective tissue disease. *Rheum Dis Clin North Am* 1996;22:23–38.
46. Ormond JK. Bilateral ureteral obstruction due to envelopment and compression by an inflammatory retroperitoneal process. *J Urol* 1948;59:1072–9.

47. Koep L, Zuidema GD. The clinical significance of retroperitoneal fibrosis. *Surgery* 1977;81:250–7.
48. Martorana D, Vaglio A, Greco P, et al. Chronic periaortitis and HLA-DRB1*03: another clue to an autoimmune origin. *Arthritis Rheum* 2006;55:126–30.
49. Agarwal P, Fahn S, Frucht SJ. Diagnosis and management of pergolide-induced fibrosis. *Mov Disord* 2004;19:699–704.
50. Ahmad S. Methyl dopa and retroperitoneal fibrosis. *Am Heart J* 1983;105:1037–8.
51. Demko TM, Diamond JR, Groff J. Obstructive nephropathy as a result of retroperitoneal fibrosis: a review of its pathogenesis and associations. *J Am Soc Nephrol* 1997;8:684–8.
52. Finan BF, Finkbeiner AE. Renal papillary necrosis and retroperitoneal fibrosis secondary to analgesic abuse. *J Urol* 1981;126:533–4.
53. Kottra JJ, Dunnick NR. Retroperitoneal fibrosis. *Radiol Clin North Am* 1996;34:1259–75.
54. Chander S, Ergun EL, Chugani HT, et al. High 2-deoxy-2-[18F]fluoro-D-glucose accumulation in a case of retroperitoneal fibrosis following resection of carcinoid tumor. *Mol Imaging Biol* 2002;4:363–8.
55. Vaglio A, Corradi D, Manenti L, et al. Evidence of autoimmunity in chronic periaortitis: a prospective study. *Am J Med* 2003;114:454–62.
56. Oikarinen AI, Vuorio EI, Zaragoza EJ, et al. Modulation of collagen metabolism by glucocorticoids. Receptor-mediated effects of dexamethasone on collagen biosynthesis in chick embryo fibroblasts and chondrocytes. *Biochem Pharmacol* 1988;37:1451–62.
57. Marcolongo R, Tavolini IM, Laveder F, et al. Immunosuppressive therapy for idiopathic retroperitoneal fibrosis: a retrospective analysis of 26 cases. *Am J Med* 2004;116:194–7.
58. Tonietto G, Agresta F, Della Libera D, Bittesini L. Treatment of idiopathic retroperitoneal fibrosis by tamoxifen. *Eur J Surg* 1997;163:231–5.
59. Clark CP, Vanderpool D, Preskitt JT. The response of retroperitoneal fibrosis to tamoxifen. *Surgery* 1991;109:502–6.
60. Velcirov S, Gluhovschi C, Petrica L, Gluhovschi A. A patient with retroperitoneal fibrosis treated with tamoxifen who develops pancreatic carcinoma: remarks regarding the presence of estrogen receptors—a relationship between fibrosis and neoplastic processes? *Pancreas* 2013;42:174–5.
61. Malkin D, Li FP, Strong LC, et al. Germ line p53 mutations in a familial syndrome of breast cancer, sarcomas, and other neoplasms. *Science* 1990;250:1233–8.
62. Gladdy RA, Qin LX, Moraco N, et al. Do radiation-associated soft tissue sarcomas have the same prognosis as sporadic soft tissue sarcomas? *J Clin Oncol* 2010;28:2064–9.
63. Berner JM, Forus A, Elkahoulou A, et al. Separate amplified regions encompassing CDK4 and MDM2 in human sarcomas. *Genes Chromosomes Cancer* 1996;17:254–9.
64. Chiappa A, Zbar AP, Bertani E, et al. Primary and recurrent retroperitoneal soft tissue sarcoma: prognostic factors affecting survival. *J Surg Oncol* 2006;93:456–63.
65. Lewis JJ, Leung D, Woodruff JM, Brennan MF. Retroperitoneal soft-tissue sarcoma: analysis of 500 patients treated and followed at a single institution. *Ann Surg* 1998;228:355–65.
66. Glenn J, Sindelar WF, Kinsella T, et al. Results of multimodality therapy of resectable soft-tissue sarcomas of the retroperitoneum. *Surgery* 1985;97:316–25.
67. Ballo MT, Zagars GK, Pollock RE, et al. Retroperitoneal soft tissue sarcoma: an analysis of radiation and surgical treatment. *Int J Radiat Oncol Biol Phys* 2007;67:158–63.
68. Porter GA, Baxter NN, Pisters PW. Retroperitoneal sarcoma: a population-based analysis of epidemiology, surgery, and radiotherapy. *Cancer* 2006;106:1610–6.

Acknowledgment

Figures 1, 2, and 8 Christine Kenney

AMANDA K. ARRINGTON, MD cr, Assistant Professor, Division of General Surgery, Department of Surgery, University of South Carolina, Columbia, SC

JOSEPH KIM, MD, Associate Professor of Surgical Oncology, Department of Surgery, City of Hope Cancer Center, Duarte, CA