

# Current Status of Percutaneous Cholecystostomy for the Management of Cholecystitis

Ying Dai, MD<sup>1,2</sup> Ronald S. Arellano, MD<sup>2</sup>

<sup>1</sup>Beijing Cancer Hospital, Beijing Institute for Cancer Research, Peking University School of Oncology, Beijing, China

<sup>2</sup>Division of Interventional Radiology, Department of Radiology, Massachusetts General Hospital, Harvard Medical School, Boston, Massachusetts

Address for correspondence Ronald S. Arellano, MD, Division of Interventional Radiology, Department of Radiology, Massachusetts General Hospital, Harvard Medical School, 55 Fruit Street, GRB 293, Boston, MA 02114 (e-mail: rarellano@mgh.harvard.edu).

Dig Dis Interv 2017;1:22–27.

## Abstract

### Keywords

- ▶ acute calculous cholecystitis
- ▶ acalculous cholecystitis
- ▶ cholecystostomy
- ▶ percutaneous drainage

Acute cholecystitis is a disease frequently encountered in daily practice. As an inflammatory disease of the gallbladder, > 90% of acalculous cholecystitis (AC) cases are associated with gallstones. In the remaining 10% of cases, cholecystitis occurs in the absence of gallstones, which is termed AC.

Acute cholecystitis can arise in two distinct patient populations: (1) the relatively healthy ambulatory patient who develops acute inflammation of the gallbladder as a result of gallstones and (2) the critically ill, hospitalized patient who may or may not have gallstones. For most patients with acute calculous cholecystitis, surgical removal of the gallbladder is the preferred treatment option. Surgical intervention is less certain for the critically ill, elderly, or debilitated patients with calculous or acalculous cholecystitis (AC). For these patients, less invasive but equally effective means of alleviating clinical symptoms of acute gallbladder plays an increasingly important role in patient management. This review will discuss the current role of percutaneous cholecystostomy (PC) in the management acute cholecystitis.

## Clinical Features and Diagnosis

Acute AC tends to occur in the critically ill or debilitated patients, such as those hospitalized in the intensive care.<sup>1</sup> Acute AC is a manifestation of a systemic response as compared with acute calculous cholecystitis, which is

more likely due to a local inflammatory process and is more commonly encountered in young, otherwise healthy women.<sup>2,3</sup> The exact pathogenesis of AC is unclear but biliary stasis can be caused by fasting, alterations in gallbladder blood flow, activation of factor XII, prostaglandins, and endotoxin.<sup>1</sup>

Patients with right upper quadrant (RUQ) mass, pain, tenderness, positive Murphy's sign, and systemic signs of inflammation (fever, elevated C-reactive protein, or white blood cell count) are suspected to have AC. Definitive diagnosis is confirmed by characteristic imaging findings using either ultrasound (US) (▶ Fig. 1), computed tomography (CT) (▶ Fig. 2), magnetic resonance imaging, or rarely, technetium hepatobiliary iminodiacetic acid scans. The presence of gallstones and thickening of the gallbladder wall ( $\geq 5$  mm), gallbladder distension, pericholecystic fluid, and/or failure of the gallbladder to fill within 60 minutes after administration of the technetium-labeled analogs of iminodiacetic acid are regarded as radiological signs of AC.<sup>4</sup>

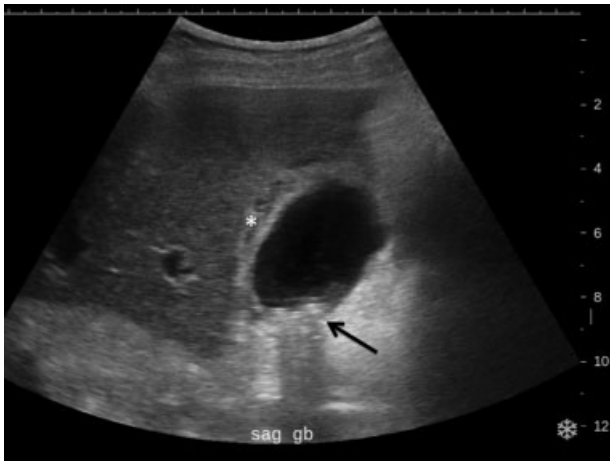The diagnosis of AC is more challenging due to the nonspecific clinical findings and the frequent clinical

received  
November 12, 2016  
accepted after revision  
January 30, 2017  
published online  
March 20, 2017

Issue Theme Biliary Diseases and Interventions; Guest Editor, Ronald S. Arellano, MD

Copyright © 2017 by Thieme Medical Publishers, Inc., 333 Seventh Avenue, New York, NY 10001, USA  
Tel: +1(212) 584-4662.

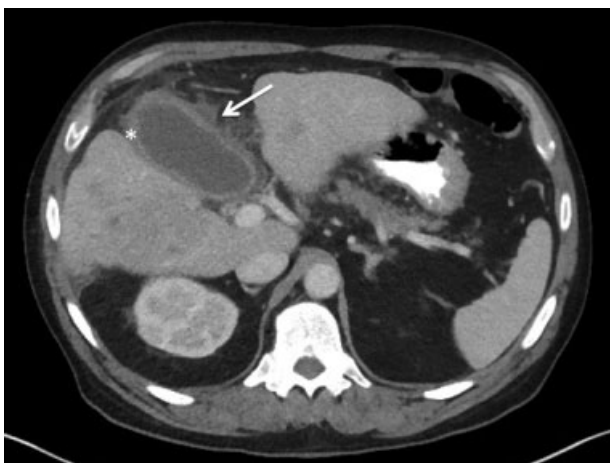DOI <https://doi.org/10.1055/s-0037-1599274>.  
ISSN 2472-8721.



**Fig. 1** Ultrasound image demonstrated gallbladder wall thickening (white asterisk) and gallstones (black arrow) consistent with acute calculous cholecystitis. Clinically, patient had a positive sonographic Murphy's sign.

scenario of an intubated, sedated patient in the intensive care unit. By the time the diagnosis has been made, at least half of the patients experience a cholecystitis-related complication such as gangrene or a confined perforation of the gallbladder.<sup>5</sup> The mortality rate of acute AC is high, ranging from 10 to 50%, compared with a 1% mortality rate in patients with calculous cholecystitis.<sup>6,7</sup> Since AC may present with a spectrum of disease stages ranging from a mild self-limited illness to a fulminant potentially life-threatening illness, appropriate management based on appropriate severity assessment is necessary for improved prognosis.

Cholecystectomy has been regarded as the gold standard treatment for AC. With the advent of laparoscopic cholecystectomy, early surgery is considered safe and cost-effective for the management of AC with complication rates of < 1%.<sup>8,9</sup> Optimal management of AC in the elderly or criti-



**Fig. 2** Axial contrast material-enhanced computed tomography scan that shows gallbladder wall thickening (white asterisk) with adjacent inflammatory changes (white arrow). No radiodense stones are present, consistent with acalculous cholecystitis.

cally ill patients who are high surgical risk patients, however, is controversial. Early cholecystectomy could result in morbidity up to 41%, and perioperative mortality of up to 19%.<sup>10-13</sup> Hence, PC is recommended as a less invasive alternative to open procedures or a temporary means to relieve symptoms until intervening cholecystectomy can be safely performed.

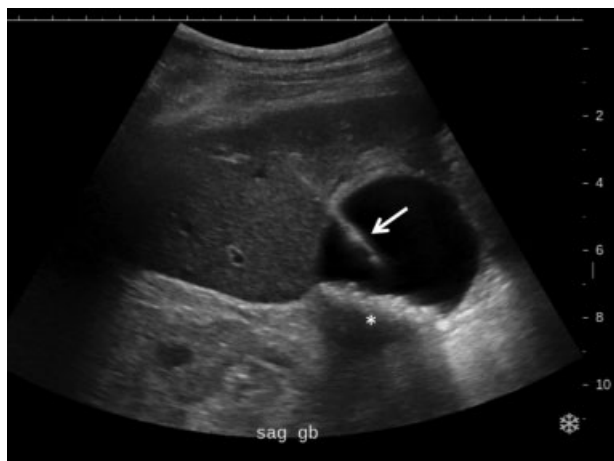## Techniques of Percutaneous Cholecystostomy

PC is a minimally invasive procedure to decompress the acutely inflamed gallbladder. It has the advantages of bedside applicability and can often be performed with local anesthesia, especially in the intubated critically ill patients. PC was first reported by Radder in 1980, who successfully treated a patient with empyema of the gallbladder by percutaneous drainage.<sup>14</sup>

The procedure of PC involves sterile placement of a needle or a drainage catheter into the gallbladder to drain the bile. It is indicated in high surgical risk patients with moderate to severe cholecystitis (calculous or acalculous) who are not improving with conservative management (generally within 72 hours). It should be emphasized that the indication for percutaneous drainage is the patient's high surgical risk rather than the severity of the acute cholecystitis or appearance of the gallbladder on imaging studies.<sup>1</sup> The primary clinical indications for PC are (1) to decompress the gallbladder for management of cholecystitis or (2) to provide a portal of access to the biliary tract for therapeutic purposes.<sup>15,16</sup> There are few absolute contraindications for PC.

Interposed bowel may preclude safe access to the gallbladder. Coagulopathy is a relative contraindication, and a severe bleeding diathesis may not allow transhepatic (TH) access. Other relative contraindications include gallbladder tumor that may be seeded by percutaneous access, or a gallbladder completely distended by calculi that prevents drainage tube formation and locking. Finally, it may be difficult or impossible to place a PC tube in a perforated decompressed gallbladder.<sup>17</sup>

PC can be performed under image guidance with US, fluoroscopy, or CT, by a dedicated interventional radiologist. Catheter placement is performed through either a TH or transperitoneal (TP) approach, according to the preference of the radiologist, the accessibility of the gallbladder, and the coagulation status of the patient. The TH approach is used more frequently because of the greater stability of the catheter, more rapid tract maturation, lower theoretical risk of bile peritonitis, and lesser risk of bowel injury. The TP approach may be used in patients with liver disease or coagulopathy.<sup>18</sup> Also, the TP route should be used when the gallbladder is grossly distended and adherent to the abdominal wall, or when unfavorable anatomy renders TH access difficult.<sup>19</sup> Although there does not appear to be a significant difference, the frequency of complications and recurrence of cholecystitis with TP approach may be higher than those reported with TH approach.<sup>20-22</sup> The TP approach has also been associated with an increased risk of colon perforation,



**Fig. 3** Ultrasound-guided cholecystostomy with an 8-French drainage catheter (white arrow) placed into the gallbladder using the trocar technique (same patient with ► **Fig. 1**). White asterisk indicates posterior acoustic shadowing from gallstones.

portal vessel injury, and displacement of the catheter after decompression of the gallbladder as the decompressed gallbladder retracts away from the catheter tip.<sup>23</sup> The methods for PC catheter placements include the Seldinger's technique and the Trocar technique.<sup>24</sup>

The Trocar technique has the advantage of a single step and access to the gallbladder with no exchanges over a guide wire (► **Fig. 3**). The Seldinger's technique is often better suited for circumstances with difficult access or a small gallbladder (► **Fig. 4**).

## Outcomes

The technical success of PC is defined as a successful placement of the cholecystostomy tube and is reported as high as 95 to 100%.<sup>25–27</sup> Technical failures occur with thick biliary aspirate not amenable for drainage, decompressed gallbladders, porcelain gallbladders, and pronounced gallbladder

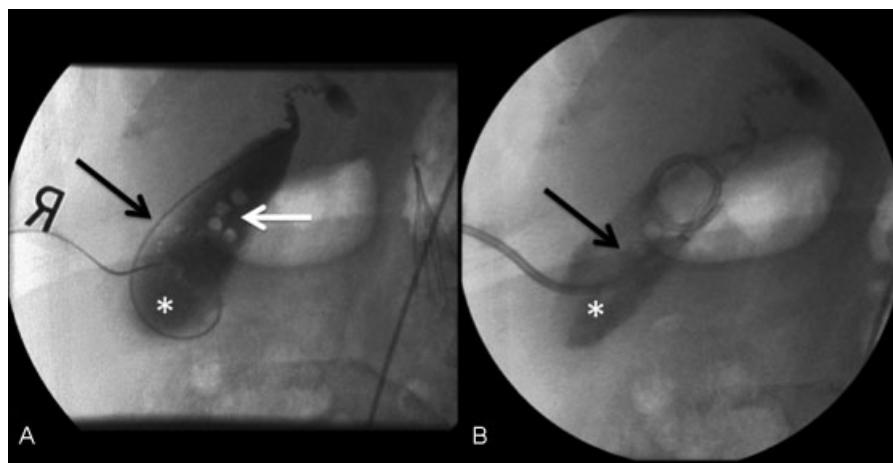
wall thickening.<sup>28</sup> The clinical success of PC is determined by improvement in clinical parameters (including fever, leukocytosis, pain) within 2 to 3 days. The reported clinical success rates range from 68 to 100%.<sup>24,25,29–34</sup> The wide range is, in large measure, due to the wide variation in patient clinical status and patient selection. Outcomes after PC for AC are better when the disease is primary and not precipitated by concurrent illness. It has been reported that in studies with strictly acute calculous cholecystitis, the success rate of PC was higher than that among patients with mixed acalculous and calculous cholecystitis but with no statistical difference.<sup>25</sup>

For patients who do not show signs of improvement within 48 to 72 hours after a cholecystostomy, cholecystectomy should be considered.

Procedure-related complications may be seen in 0 to 26.3% of cases within the first few days and are usually minor.<sup>25,35,36</sup> Published rates for individual types of complications are highly dependent on patient selection. Major complications such as bile peritonitis or bile leak, sepsis, significant hemorrhage, hemo- or pneumothorax, bowel injury, and liver abscesses, affect less than 5% of patients. Minor complications such as catheter displacement and minor bleeding comprise most procedure-related events.<sup>15,19,22,25,37,38</sup>

The catheter dislodgment (6.1–14%) is reported to be the most common late complications.<sup>24,36,39</sup>

Procedure-related mortality includes deaths that are directly linked to drainage-related complications (bowel perforation, leakage, or bleeding) ranging from 0 to 0.36%.<sup>15,25,29</sup> Mortality caused by biliary infection (deaths to be related to or due to cholecystitis) range from 1.5 to 17.3%.<sup>26,30,40</sup> The 30-day postprocedural mortality rate or in-hospital mortality has a wide range (3.8–22.6%) depending on the population studied.<sup>19,22,28,35,40–43</sup> The vast majority of 30-day mortality cases are related to patient comorbidities and not directly the result of PC. AC and shock on admission were reported to be independent risk factors for in-hospital death.<sup>44</sup>



**Fig. 4** Percutaneous cholecystostomy using Seldinger's technique. (A) Fluoroscopic image demonstrates guidewire (black arrow) in gallbladder lumen (white asterisk). White arrow indicates gallstones. (B) Fluoroscopic image demonstrates 8-French catheter (black arrow) within the gallbladder lumen (white asterisk).

Clinically, acute AC often occurs in critically ill patients and it is especially related to sepsis and shock with a high mortality. High Charlson's comorbidity index and a longer interval between diagnosis of AC and PC may predict in-hospital and 30-day mortalities.<sup>39,45,46</sup> Other factors including profound low mean arterial pressure and higher serum creatinine levels have also been reported to be independent risk factors that negatively impact in-hospital mortality.<sup>45</sup> Early PC is the key to lower mortality rates and is recommended once the diagnosis of AC is made in a high surgical risk patient who is unfit for primary cholecystectomy. The overall mortality rates of 15.4 to 42.3% have been reported with a median follow-up of 4 to 37 months.<sup>25,26,29,30,36</sup> The high total mortality rate probably reflects the poor long-term prognosis of elderly and critically ill patients in general, unrelated to cholecystitis.

There have been no recommendations proposed for the optimal duration of PC drainage. Reported duration of drainage range from 3 to 6 weeks with an average of 1 month.<sup>19</sup> According to previous reports,  $\geq 2$  weeks were required for tract maturation for the TH approach and 3 weeks were required for the TP approach.<sup>47,48</sup> Regression analyses including 50 studies showed no correlation between length of tube maintenance and the considered outcomes (morbidity, mortality, and disease recurrence).<sup>49</sup> However, a drainage duration of  $> 2$  weeks was reported to be associated with increased recurrence within 2 months of the initial AC attack.<sup>20</sup> Also, another study showed that the PC drainage duration longer than 1 month was associated with 1-year recurrence.<sup>50</sup> This was likely due to irritation of the gallbladder mucosa by the PC or bacterial colonization of the tube.<sup>51,52</sup>

The removal of PC tubes can be considered after temporary clamping of the drain is shown to be well tolerated by the patient, with no recurrent signs or symptoms of RUQ pain, fever, or leukocytosis. Performing a cholangiogram via the drain before withdrawal to ensure the absence of leakage or an obstructed cystic duct is recommended to reduce the recurrence of cholecystitis.<sup>22</sup>

## Recurrence after Percutaneous Cholecystostomy

In patients who did not have subsequent cholecystectomy after PC, the recurrent biliary symptoms ranged from 0 to 46% with most recurrence within 1 year, especially within 2 months.<sup>31,32,44,50,53</sup> In some studies, the actual recurrence rate might be underestimated due to inclusion of patients with interval cholecystectomy (IC) and in-hospital mortality in the denominator for calculation.<sup>19,39</sup> Complicated cholecystitis and PC drainage duration  $> 32$  days were reported to be positively correlated with 1-year recurrence, while parenteral antibiotics duration  $> 10$  days was inversely associated with 1-year and 2-month recurrence.<sup>50</sup> Other reported predictors of recurrence were stone size  $\geq 1$  cm, higher serum alkaline phosphatase at diagnosis, and acute myocardial infarction during index.<sup>36,44</sup>

## Subsequent Cholecystectomy

Usually, PC has been used as a preoperative management modality before IC. According to the Tokyo guidelines, elective cholecystectomy after improvement of the acute inflammatory process is the first-line treatment for grade II (moderate) AC and is also recommended after the improvement of acute illness in patients with grade III AC.<sup>4</sup> In the era of modern medicine and advances in surgery, anesthesiology and perioperative care; cholecystectomy (early or delayed) is still a good option in these patients to achieve better long-term outcome.<sup>26,30,54</sup>

An increasing number of studies have indicated that PC might not only serve as a bridge to IC but could probably serve as definitive treatment for AC, especially for patients with high operative risks, including advanced age and multiple comorbidities.<sup>29,39,50,55-60</sup> In actuality, 54.3 to 88.3% of patients demonstrated control of AC with PC alone without recurrence.<sup>22,36,55,61,62</sup> Another study even showed there was no difference in 1-year and 3-year overall survival between patients with or without cholecystectomy after PC.<sup>44</sup> Furthermore, after PC, it is possible to perform diagnostic cholangiography to study the biliary system and serves as an access for intervention to eliminate common bile duct stones, thereby avoiding endoscopic retrograde cholangiopancreatography and surgical exploration of the common bile duct.<sup>26</sup>

The role of PC as a definitive treatment in high surgical risk patients, however, remains debatable. There are arguments that current evidence on the benefit of PC in the management of AC is weak because most data are from retrospective series with comparatively small case numbers. Partly because of this controversy, published numbers on the proportion of patients undergoing IC after PC are extremely variable, with percentages ranging from 2 to 78.2%.<sup>26,55,58</sup> Furthermore, the later elective (laparoscopic) cholecystectomy might result in longer operative times, greater rates of conversion to open surgery, and increased incidence of biliary-related complications, mostly because of adhesions.<sup>63,64</sup>

A longitudinal analysis showed that mortality among patients with cholecystostomy or no procedure is higher than cholecystectomy and patients with cholecystectomy (with or without prior cholecystostomy) had significantly improved survival.<sup>65</sup> Some systematic reviews have found that there were no statistically significant differences in terms of morbidity when late cholecystectomy after cholecystostomy was compared with simple conservative treatment.<sup>25,66</sup> The improved cholecystectomy outcomes could possibly be attributed to the better comorbidity profiles of patient population.

Even with attempts to adjust for the morbidity of each patient, there may have been other variables that could have further affected this risk adjustment analysis to ensure equal comparison.<sup>66</sup> There is a need for adequately powered randomized clinical trials of low risk of bias on this issue. An ongoing prospective, controlled study is underway that compares laparoscopic cholecystectomy with percutaneous

drainage to determine the best treatment for acute calculous cholecystitis in high-risk patients.<sup>67</sup>

## Conclusion

PC is a low-mortality procedure that is associated with a high success rate. It is indeed a safe and effective alternative procedure for the treatment of calculous cholecystitis and AC in critically ill patients and/or those with prohibitive surgical risks. Patients with AC might have less favorable outcomes due to the poor comorbidity profiles of the affected patient population. Cholecystectomy after the resolution of cholecystitis and optimization of associated medical illnesses is always advisable to prevent recurrent cholecystitis, although PC alone can be considered as a definitive treatment.

## References

- Wang D, Afdhal N. Gallstone disease. Feldman M, Friedman L, Brandt L. Sleisenger and Fordtran's Gastrointestinal and Liver Disease. Philadelphia: Saunders/Elsevier; 2016:1100–1133
- Owen CC, Jain R. Acute acalculous cholecystitis. *Curr Treat Options Gastroenterol* 2005;8(2):99–104
- Pomerantz BJ. Biliary tract interventions. *Tech Vasc Interv Radiol* 2009;12(2):162–170
- Yokoe M, Takada T, Strasberg SM, et al; Tokyo Guidelines Revision Committee. TG13 diagnostic criteria and severity grading of acute cholecystitis (with videos). *J Hepatobiliary Pancreat Sci* 2013;20(1):35–46
- Barie PS, Eachempati SR. Acute acalculous cholecystitis. *Gastroenterol Clin North Am* 2010;39(2):343–357, x
- Kalliafas S, Ziegler DW, Flancbaum L, Choban PS. Acute acalculous cholecystitis: incidence, risk factors, diagnosis, and outcome. *Am Surg* 1998;64(5):471–475
- Laurila J, Syrjälä H, Laurila PA, Saarnio J, Ala-Kokko TI. Acute acalculous cholecystitis in critically ill patients. *Acta Anaesthesiol Scand* 2004;48(8):986–991
- Steiner CABE, Bass EB, Talamini MA, Pitt HA, Steinberg EP. Surgical rates and operative mortality for open and laparoscopic cholecystectomy in Maryland. *N Engl J Med* 1994;330(6):403–408
- Gurusamy K, Samraj K, Gluud C, Wilson E, Davidson BR. Meta-analysis of randomized controlled trials on the safety and effectiveness of early versus delayed laparoscopic cholecystectomy for acute cholecystitis. *Br J Surg* 2010;97(2):141–150
- Margiotta SJ Jr, Willis IH, Wallack MK. Cholecystectomy in the elderly. *Am Surg* 1988;54(1):34–39
- Huber DF, Martin EW Jr, Cooperman M. Cholecystectomy in elderly patients. *Am J Surg* 1983;146(6):719–722
- Houghton PWJL, Jenkinson LR, Donaldson LA. Cholecystectomy in the elderly: a prospective study. *Br J Surg* 1985;72(3):220–222
- Decker G, Goergen M, Philippart P, Mendes da Costa P. Laparoscopic cholecystectomy for acute cholecystitis in geriatric patients. *Acta Chir Belg* 2001;101(6):294–299
- Radder RW. Ultrasonically guided percutaneous catheter drainage for gallbladder empyema. *Diagn Imaging* 1980;49(6):330–333
- Saad WEWM, Wallace MJ, Wojak JC, Kundu S, Cardella JF. Quality improvement guidelines for percutaneous transhepatic cholangiography, biliary drainage, and percutaneous cholecystostomy. *J Vasc Interv Radiol* 2010;21(6):789–795
- Akhan O, Akinci D, Ozmen MN. Percutaneous cholecystostomy. *Eur J Radiol* 2002;43(3):229–236
- Fahrback T, Wyse G, Lawler L, Kim H. *Percutaneous Cholecystostomy*. Philadelphia: Saunders/Elsevier; 2014:1008–1013
- Katabathina VS, Zafar AM, Suri R. Clinical presentation, imaging, and management of acute cholecystitis. *Tech Vasc Interv Radiol* 2015;18(4):256–265
- Sanjay P, Mittapalli D, Marioud A, White RD, Ram R, Alijani A. Clinical outcomes of a percutaneous cholecystostomy for acute cholecystitis: a multicentre analysis. *HPB (Oxford)* 2013;15(7):511–516
- Hsieh YC, Chen CK, Su CW, et al. Outcome after percutaneous cholecystostomy for acute cholecystitis: a single-center experience. *J Gastrointest Surg* 2012;16(10):1860–1868
- Melloul E, Denys A, Demartines N, Calmes JM, Schäfer M. Percutaneous drainage versus emergency cholecystectomy for the treatment of acute cholecystitis in critically ill patients: does it matter? *World J Surg* 2011;35(4):826–833
- Horn T, Christensen SD, Kirkegård J, Larsen LP, Knudsen AR, Mortensen FV. Percutaneous cholecystostomy is an effective treatment option for acute calculous cholecystitis: a 10-year experience. *HPB (Oxford)* 2015;17(4):326–331
- Malone DEBH, Burhenne HJ. Advantages and disadvantages of the newer “interventional” procedures for the treatment of cholelithiasis. *Hepatogastroenterology* 1989;36(5):317–326
- Browning PDMJ, McGahan JP, Gerscovich EO. Percutaneous cholecystostomy for suspected acute cholecystitis in the hospitalized patient. *J Vasc Interv Radiol* 1993;4(4):531–537, discussion 537–538
- Winbladh A, Gullstrand P, Svanvik J, Sandström P. Systematic review of cholecystostomy as a treatment option in acute cholecystitis. *HPB (Oxford)* 2009;11(3):183–193
- Atar E, Bachar GN, Berlin S, et al. Percutaneous cholecystostomy in critically ill patients with acute cholecystitis: complications and late outcome. *Clin Radiol* 2014;69(6):e247–e252
- Hatzidakis AA, Prassopoulos P, Petinarakis I, et al. Acute cholecystitis in high-risk patients: percutaneous cholecystostomy vs conservative treatment. *Eur Radiol* 2002;12(7):1778–1784
- Viste A, Jensen D, Angelsen J, Hoem D. Percutaneous cholecystostomy in acute cholecystitis; a retrospective analysis of a large series of 104 patients. *BMC Surg* 2015;15:17–22
- Zerem E, Omerović S. Can percutaneous cholecystostomy be a definitive management for acute cholecystitis in high-risk patients? *Surg Laparosc Endosc Percutan Tech* 2014;24(2):187–191
- Joseph T, Unver K, Hwang GL, et al. Percutaneous cholecystostomy for acute cholecystitis: ten-year experience. *J Vasc Interv Radiol* 2012;23(1):83–8.e1
- Chung YH, Choi ER, Kim KM, et al. Can percutaneous cholecystostomy be a definitive management for acute acalculous cholecystitis? *J Clin Gastroenterol* 2012;46(3):216–219
- McKay A, Abulfaraj M, Lipschitz J. Short- and long-term outcomes following percutaneous cholecystostomy for acute cholecystitis in high-risk patients. *Surg Endosc* 2012;26(5):1343–1351
- Davis CA, Landerasper J, Gundersen LH, Lambert PJ. Effective use of percutaneous cholecystostomy in high-risk surgical patients: techniques, tube management, and results. *Arch Surg* 1999;134(7):727–731, discussion 731–732
- Kiviniemi H, Mäkelä JT, Autio R, et al. Percutaneous cholecystostomy in acute cholecystitis in high-risk patients: an analysis of 69 patients. *Int Surg* 1998;83(4):299–302
- Byrne MF, Suhocki P, Mitchell RM, et al. Percutaneous cholecystostomy in patients with acute cholecystitis: experience of 45 patients at a US referral center. *J Am Coll Surg* 2003;197(2):206–211
- Pang KW, Tan CH, Loh S, et al. Outcomes of percutaneous cholecystostomy for acute cholecystitis. *World J Surg* 2016;40(11):2735–2744
- Ginat D, Saad WE. Cholecystostomy and transcholecystic biliary access. *Tech Vasc Interv Radiol* 2008;11(1):2–13
- vanSonnenberg E, D'Agostino HB, Goodacre BW, Sanchez RB, Casola G. Percutaneous gallbladder puncture and cholecystostomy: results, complications, and caveats for safety. *Radiology* 1992;183(1):167–170

- 39 Yeo CS, Tay VW, Low JK, Woon WW, Punamiya SJ, Shelat VG. Outcomes of percutaneous cholecystostomy and predictors of eventual cholecystectomy. *J Hepatobiliary Pancreat Sci* 2016; 23(1):65–73
- 40 Welschbillig-Meunier K, Pessaux P, Lebigot J, et al. Percutaneous cholecystostomy for high-risk patients with acute cholecystitis. *Surg Endosc* 2005;19(9):1256–1259
- 41 Teoh WM, Cade RJ, Banting SW, Mackay S, Hassen AS. Percutaneous cholecystostomy in the management of acute cholecystitis. *ANZ J Surg* 2005;75(6):396–398
- 42 Smith TJMJ, Manske JG, Mathiason MA, Kallies KJ, Kothari SN. Changing trends and outcomes in the use of percutaneous cholecystostomy tubes for acute cholecystitis. *Ann Surg* 2013; 257(6):1112–1115
- 43 Hatzidakis A, Venetucci P, Krokidis M, Iaccarino V. Percutaneous biliary interventions through the gallbladder and the cystic duct: what radiologists need to know. *Clin Radiol* 2014;69(12): 1304–1311
- 44 Ha JP, Tsui KK, Tang CN, Siu WT, Fung KH, Li MK. Cholecystectomy or not after percutaneous cholecystostomy for acute calculous cholecystitis in high-risk patients. *Hepatogastroenterology* 2008; 55(86–87):1497–1502
- 45 Chou CK, Lee KC, Chan C-C, et al. Early Percutaneous Cholecystostomy in Severe Acute Cholecystitis Reduces the Complication Rate and Duration of Hospital Stay. *Medicine (Baltimore)* 2015; 94:e1096
- 46 Abi-Haidar Y, Sanchez V, Williams SA, Itani KM. Revisiting percutaneous cholecystostomy for acute cholecystitis based on a 10-year experience. *Arch Surg* 2012;147(5):416–422
- 47 Wise JN, Gervais DA, Akman A, Harisinghani M, Hahn PF, Mueller PR. Percutaneous cholecystostomy catheter removal and incidence of clinically significant bile leaks: a clinical approach to catheter management. *AJR Am J Roentgenol* 2005;184(5):1647–1651
- 48 Hatjidakis AA, Karampekios S, Prassopoulos P, et al. Maturation of the tract after percutaneous cholecystostomy with regard to the access route. *Cardiovasc Intervent Radiol* 1998;21(1):36–40
- 49 Macchini D, Degrate L, Oldani M, et al. Timing of percutaneous cholecystostomy tube removal: systematic review. *Minerva Chir* 2016;71(6):415–426
- 50 Wang CH, Wu CY, Yang JC, et al. Long-term outcomes of patients with acute cholecystitis after successful percutaneous cholecystostomy treatment and the risk factors for recurrence: a decade experience at a single center. *PLoS One* 2016;11(1):e0148017
- 51 Roslyn JJ, DenBesten L, Thompson JE Jr, Silverman BF. Roles of lithogenic bile and cystic duct occlusion in the pathogenesis of acute cholecystitis. *Am J Surg* 1980;140(1):126–130
- 52 Wang CH, Chou HC, Liu KL, Lien WC, Wang HP, Wu YM. Long-term outcome of patients with acute cholecystitis receiving antibiotic treatment: a retrospective cohort study. *World J Surg* 2014;38(2): 347–354
- 53 Cha BH, Song HH, Kim YN, et al. Percutaneous cholecystostomy is appropriate as definitive treatment for acute cholecystitis in critically ill patients: a single center, cross-sectional study. *Korean J Gastroenterol* 2014;63(1):32–38
- 54 Akyürek N, Salman B, Yüksel O, et al. Management of acute calculous cholecystitis in high-risk patients: percutaneous cholecystostomy followed by early laparoscopic cholecystectomy. *Surg Laparosc Endosc Percutan Tech* 2005;15(6):315–320
- 55 Chang YR, Ahn YJ, Jang JY, et al. Percutaneous cholecystostomy for acute cholecystitis in patients with high comorbidity and re-evaluation of treatment efficacy. *Surgery* 2014;155(4): 615–622
- 56 Chok KS, Chu FS, Cheung TT, et al. Results of percutaneous transhepatic cholecystostomy for high surgical risk patients with acute cholecystitis. *ANZ J Surg* 2010;80(4):280–283
- 57 Sugiyama M, Tokuhara M, Atomi Y. Is percutaneous cholecystostomy the optimal treatment for acute cholecystitis in the very elderly? *World J Surg* 1998;22(5):459–463
- 58 Leveau P, Andersson E, Carlgren I, Willner J, Andersson R. Percutaneous cholecystostomy: a bridge to surgery or definite management of acute cholecystitis in high-risk patients? *Scand J Gastroenterol* 2008;43(5):593–596
- 59 Hultman CS, Herbst CA, McCall JM, Mauro MA. The efficacy of percutaneous cholecystostomy in critically ill patients. *Am Surg* 1996;62(4):263–269
- 60 Popowicz A, Lundell L, Gerber P, et al. Cholecystostomy as bridge to surgery and as definitive treatment or acute cholecystectomy in patients with acute cholecystitis. *Gastroenterol Res Pract* 2016; 2016:3672416
- 61 Shirai Y, Tsukada K, Kawaguchi H, Ohtani T, Muto T, Hatakeyama K. Percutaneous transhepatic cholecystostomy for acute acalculous cholecystitis. *Br J Surg* 1993;80(11):1440–1442
- 62 Kirkegård J, Horn T, Christensen SD, Larsen LP, Knudsen AR, Mortensen FV. Percutaneous cholecystostomy is an effective definitive treatment option for acute acalculous cholecystitis. *Scand J Surg* 2015;104(4):238–243
- 63 Mizrahi I, Mazeh H, Yuval JB, et al. Perioperative outcomes of delayed laparoscopic cholecystectomy for acute calculous cholecystitis with and without percutaneous cholecystostomy. *Surgery* 2015;158(3):728–735
- 64 Suzuki K, Bower M, Cassaro S, Patel RI, Karpeh MS, Leitman IM. Tube cholecystostomy before cholecystectomy for the treatment of acute cholecystitis. *JSLs* 2015;19(1):00200
- 65 Anderson JE, Inui T, Talamini MA, Chang DC. Cholecystostomy offers no survival benefit in patients with acute acalculous cholecystitis and severe sepsis and shock. *J Surg Res* 2014; 190(2):517–521
- 66 Gurusamy KS, Rossi M, Davidson BR. Percutaneous cholecystostomy for high-risk surgical patients with acute calculous cholecystitis. *Cochrane Database Syst Rev* 2013;8(8):CD007088
- 67 Kortram K, van Ramshorst B, Bollen TL, et al. Acute cholecystitis in high risk surgical patients: percutaneous cholecystostomy versus laparoscopic cholecystectomy (CHOCOLATE trial): study protocol for a randomized controlled trial. *Trials* 2012;13:7